



# Paraspinal Desmoid Tumor in a Pediatric Patient with No Surgical History: A Case Report

Aneek Patel<sup>1,\*</sup> Gregory Varga<sup>1,\*</sup> Arka N. Mallela<sup>1</sup> Hussam Abou-Al-Shaar<sup>1</sup> Andrew Bukowinski<sup>3</sup>  
Erica Mamauag<sup>3</sup> Eduardo V. Zambrano<sup>4</sup> Stephanie Greene<sup>1,2</sup>

<sup>1</sup> Department of Neurological Surgery, University of Pittsburgh Medical Center, Pittsburgh, Pennsylvania, United States

<sup>2</sup> Department of Neurological Surgery, Children's Hospital of Pittsburgh, Pittsburgh, Pennsylvania, United States

<sup>3</sup> Department of Hematology/Oncology, UPMC Children's Hospital of Pittsburgh, Pittsburgh, Pennsylvania, United States

<sup>4</sup> Department of Pathology, Children's Hospital of Pittsburgh, Pittsburgh, Pennsylvania, United States

**Address for correspondence** Arka N. Mallela, MD, MS, Department of Neurological Surgery, University of Pittsburgh Medical Center, 200 Lothrop Street, Suite B-400, Pittsburgh, PA 15213, United States (e-mail: mallelaan@upmc.edu).

AJNS

## Abstract

Desmoid tumors are locally aggressive, benign neoplasms originating in connective tissues. Although the exact pathophysiology remains unknown, antecedent trauma or surgery are believed to be important contributing factors. The occurrence of paraspinal desmoid tumor in pediatric patients is extremely uncommon. Here, we present an exceedingly rare case of a pediatric patient with no surgical or family history who developed a paraspinal desmoid tumor.

A 9-year-old female patient presented with 4 months of progressive back pain, right lower extremity weakness, and numbness. Spinal imaging revealed a left epidural paraspinal mass compressing her thoracic spinal cord and extending into the left thoracic cavity. A multidisciplinary approach with neurosurgery and thoracic surgery enabled gross total resection of the lesion. The patient had complete resolution of her symptoms with no signs of residual tumor on postoperative imaging. Pathology revealed a desmoid tumor that avidly stained for beta-catenin. On her last follow-up, she developed a recurrence, to which she was started on sorafenib therapy.

Desmoid tumors are rare connective tissue neoplasms that often occur after local tissue trauma, such as that caused by surgery. This report presents a rare case of a pediatric paraspinal desmoid tumor that occurred in a patient with no surgical or family history. Such tumors should undergo surgical resection for symptomatic relief and tissue diagnosis. Close clinical and radiographic surveillance are essential in these patients due to the high recurrence rates of desmoid tumor.

## Keywords

- ▶ desmoid tumor
- ▶ epidural mass
- ▶ wound healing
- ▶ WNT pathway
- ▶ beta-catenin
- ▶ familial adenomatous polyposis
- ▶ sorafenib

\* These authors contributed equally and retain the first authorship.

DOI <https://doi.org/10.1055/s-0043-1771366>.  
ISSN 2248-9614.

© 2024. Asian Congress of Neurological Surgeons. All rights reserved.

This is an open access article published by Thieme under the terms of the Creative Commons Attribution-NonDerivative-NonCommercial-License, permitting copying and reproduction so long as the original work is given appropriate credit. Contents may not be used for commercial purposes, or adapted, remixed, transformed or built upon. (<https://creativecommons.org/licenses/by-nc-nd/4.0/>)

Thieme Medical and Scientific Publishers Pvt. Ltd., A-12, 2nd Floor, Sector 2, Noida-201301 UP, India

## Introduction

Desmoid tumors, or aggressive fibromatosis, are benign locally aggressive myofibroblastic neoplasms originating in deep connective tissues. They have an incidence of 2 to 4 per million people per year, occurring most commonly between the ages of 30 to 40 years, and are at approximately twice as common in females.<sup>1,2</sup> Histopathologically, these tumors often have unclear margins and histological patterns similar to those of the proliferation stage of wound healing, with collagen deposition and spindle-shaped fibroblasts.<sup>2,3</sup>

Desmoid tumors are typically slow-growing tumors; they can occasionally go into remission but rarely become sufficiently invasive to warrant intervention.<sup>2</sup> Symptoms vary based on the tumor location, size, and relationship to adjacent neurovascular structures. Desmoids are most commonly found in the abdomen, pelvis, and extremities.<sup>2,4</sup> While the exact etiology is unknown, up to 85% of desmoids are associated with a mutation in the CTNNB1 gene, which codes for beta-catenin.<sup>2,3,5</sup> In another 10% of cases, desmoid tumor growth is associated with a germline mutation of the adenomatous polyposis coli gene among patients with familial adenomatous polyposis (FAP). Desmoid tumor have been found in 10 to 20% of FAP patients, representing a thousand-fold increased incidence compared to the general population.<sup>6,7</sup>

Surgical resection continues to be the mainstay treatment for patients with desmoid tumor, although the rate of recurrence can be as high as 50%, especially if complete resection cannot be achieved.<sup>8</sup> Desmoid tumor is not commonly encountered in children, with the peak incidence between 5 and 8 years. Approximately half of all pediatric desmoid tumors are found in the extremities, 17 to 30% in the head and neck, and 8 to 19% in the abdominal wall.<sup>9</sup> Paraspinal pediatric desmoid tumors are exceedingly rare. To the best of our knowledge, there are only 7 reported cases of paraspinal desmoids in

pediatric patients.<sup>10–16</sup> Here, we present a rare case of a pediatric extradural paraspinal desmoid tumor in a patient with no prior surgical or familial history.

## Case Report

### Clinical Presentation

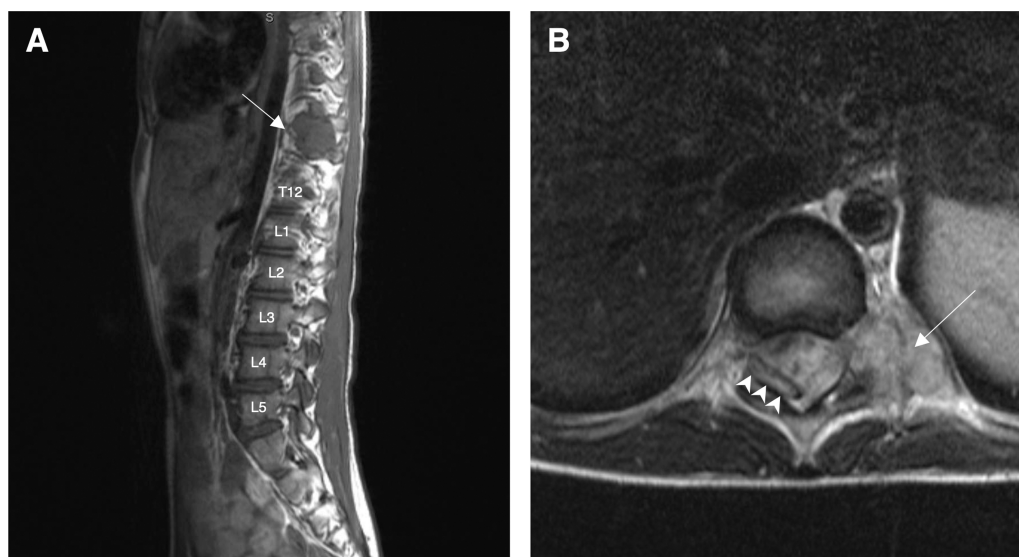
A 9-year-old female presented to our institution with 4 months of mild intermittent midthoracic pain, numbness, and weakness in the right lower extremity resulting in recurrent falls. Prior to presenting to our institution, she underwent spinal X-rays that were unremarkable, and she was managed conservatively with physical therapy and pain control without significant relief.

Five days prior to presentation, her parents noticed that she had developed an abnormal gait, avoiding bearing weight on her right leg. She also had increased back pain, causing her to wake up crying during the night. The patient had no known medical conditions, familial history, or previous surgeries.

Her neurological exam was notable for diffuse, nondermatomal numbness in the entire right lower extremity. She had 4/5 strength in right hip flexion, and 4+/5 in knee extension, foot dorsiflexion, and foot plantar flexion as well as a right monoparetic gait. The remainder of her physical exam, as well as laboratory workup, were unremarkable.

### Imaging

Magnetic resonance imaging (MRI) with contrast of her spine demonstrated a large T1 isointense, T2 mixed density, and heterogeneously enhancing mass centered in and extending through the T10-T11 foramen into the thoracic cavity, with mass effect on the spinal cord extending from T8-T12 (►Fig. 1). MRI brain was negative for intracranial pathology. Given the patient's complaints, examination findings, and imaging features, surgical resection was recommended.



**Fig. 1** (A) Preoperative T1-weighted postcontrast imaging demonstrating an epidural mass (arrow). (B) Preoperative T2-weighted axial image demonstrating the mass extending via the neural foramen from the thoracic cavity (arrow) and compressing the spinal cord (arrowheads) to the right. T, thoracic; L, lumbar.

### Surgical Intervention

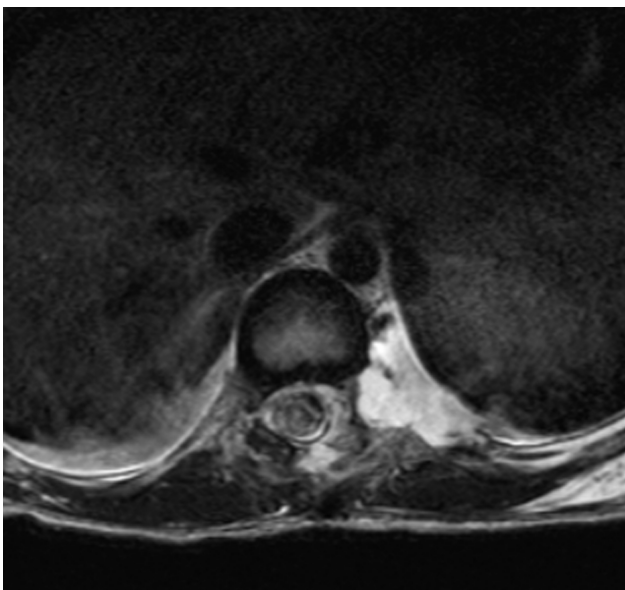
The patient was taken to the operating room for a multidisciplinary resection of her paraspinal mass extending into the thoracic cavity by neurosurgery and thoracic surgery. The patient was placed in the prone position. Neuromonitoring of somatosensory evoked potentials and motor evoked potentials was utilized. T10-T12 laminectomies were performed. The mass was noted to be completely extradural on the left side of the spinal canal, displacing the thecal sac to the right. The intradural tumor was resected completely. To allow complete resection of the mass, the left T10 nerve root was ligated and sectioned. Following the neurosurgical component of the surgery, thoracic surgery resected the intrathoracic paraspinal component of the mass using thoracoscopic technique. Of note, there was a dense inflammatory reaction in the pleura overlying the mass.

### Hospital Course

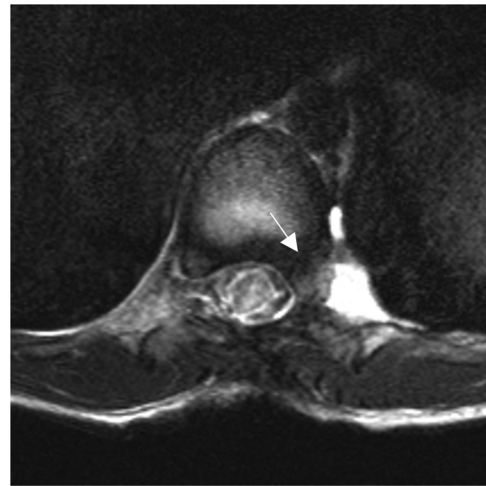
Postoperatively, the patient had significant improvement in her symptoms including her back pain, numbness, and weakness. On postoperative day 4, she was noted to have cerebrospinal fluid egress from her chest tube, which was successfully treated with chest tube removal and lumbar drain placement for 3 days. She was discharged to home on postoperative day 10. On the day of discharge, she demonstrated full strength in all extremities and had no lower back pain or numbness. Postoperative MRI confirmed gross total resection of the mass (►Fig. 2).

### Follow-Up

Three months after the resection, the patient began experiencing mild, intermittent back pain. Follow-up MRI at this time revealed a small tumor recurrence lateral to the left T11 pedicle in the pleural space (►Fig. 3). This was



**Fig. 2** Postoperative T2-weighted turbo spin echo imaging demonstrating gross total resection of the thoracic paraspinal mass.



**Fig. 3** T2-weighted turbo spin echo imaging at 3 months postresection demonstrating a small hypointense focus of residual tumor at the T11 left pedicle (arrow) with narrowing of T10-T11 neural foramen.

monitored until the 6-month follow-up, which revealed an interval increase in the size of the residual mass with now progression through the foramen to abut the thecal sac with no mass effect. Therefore, she was started on sorafenib (a protein kinase inhibitor with known anti-desmoid tumor action<sup>17</sup>) to halt further growth.

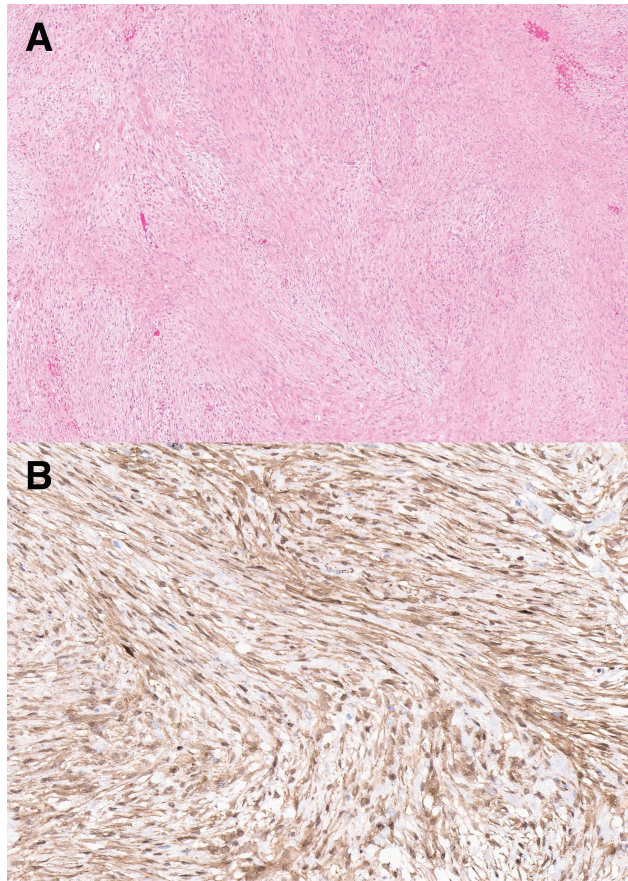
### Pathology

Histopathological analysis revealed an infiltrative, cytologically bland lesion composed of spindle to stellate cells arranged in intersecting long sweeping fascicles set within a collagenous to focally myxoid stroma (►Fig. 4A). No significant cytologic atypia or areas of necrosis were present. Mitotic figures were rare, with no atypical mitoses seen, and Ki-67 staining revealed a low proliferative index. Lesional cells were focally and weakly positive for smooth muscle actin, with frequent beta-catenin nuclear expression (►Fig. 4B), while negative for desmin, STAT6, CD34, EMA, S-100, neurofilament, MUC4, and SOX10 immunohistochemical stains.

### Discussion

In this report, we describe a rare case of a noniatrogenic, nontraumatic, paraspinal desmoid tumor in a pediatric patient. MRI completed due to complaints of numbness, weakness, and gait abnormality revealed the paraspinal mass. Gross total resection was achieved in a single two-stage procedure by a multidisciplinary team of neurosurgery and thoracic surgery, after which the patient's weakness and numbness completely improved by the time of hospital discharge.

The differential diagnosis of paraspinal tumors includes schwannoma, neurofibroma, or neuroblastoma compressing the spinal cord. All of these tumors are extradural, can be sporadic, and commonly manifest as benign, slow-growing masses that impinge on the spinal cord similar to desmoid



**Fig. 4** Representative histopathology. (A) Hematoxylin and eosin stain demonstrating an infiltrative, cytologically bland lesion composed of spindle to stellate cells arranged in intersecting long sweeping fascicles set within a collagenous to focally myxoid stroma. Mitotic figures were rare with no atypical mitotic figures. No areas of necrosis or cytologic atypia were observed. (B) Beta-catenin immunohistochemistry. Frequent beta-catenin nuclear expression is apparent.

tumor. Additionally, all of these tumors share common imaging features being well circumscribed in a similar fashion to desmoid tumor. This tumor was heterogeneously enhancing, which is commonly seen in neurofibroma or neuroblastoma cases. Schwannomas, on the other hand, tend to enhance vividly following contrast administration. Given that the median age of neuroblastoma diagnosis is 2 years, the preoperative differential diagnosis was primarily schwannoma versus neurofibroma.<sup>18</sup> Moreover, surgical resection was necessary to obtain tissue diagnosis and decompress the patient's spinal cord. Only 25 known cases of paraspinal desmoid tumors have been reported, among which only 6 were in pediatric patients (–Table 1),<sup>10–14,16,19–36</sup>

Desmoid tumors typically occur in the abdomen or extremities with surgery often being an antecedent.<sup>2,4</sup> The tumor's slow growing, benign course in our case is typical of desmoid tumor.<sup>9,15,19,37,38</sup> The gradual compression of the spinal cord produced increasing numbness, weakness, paresthesia, and abnormal gait, all consistent with published reports of paraspinal desmoid tumor. The present case is unique not only because of the tumor's rare paraspinal location, but also because most previously reported para-

spinal desmoid tumor patients had previous surgery or trauma in the area of the tumor.<sup>19,39–41</sup> Approximately a third of desmoid tumors in any location are associated with antecedent trauma at the site.<sup>42</sup>

The pathogenesis of trauma-induced desmoid tumor remains elusive but is likely related to dysregulated wound healing. Indeed, the gene encoding beta-catenin, which is actively transcribed in fibroblasts during the proliferative stage of wound healing as a critical part of the WNT signaling pathway, is somatically mutated in a majority of patients with desmoid tumors.<sup>43,44</sup> In this case, too, beta-catenin was highly expressed among neoplastic cells, suggesting that perhaps this tumor was a reaction to an unreported local nonsurgical trauma or developed secondary to spontaneous somatic gene mutation.

Standard of care therapy for patients with desmoid tumor is gross total resection, if feasible. Close surveillance is warranted, as desmoid tumors are highly recurrent largely due to their local invasiveness. Approximately 60% of desmoid tumors have been found to recur within 5 years.<sup>45</sup> Management of recurrent tumors is also complicated by the fact that cases of spontaneous remission have been reported within the first year. Additionally, adjuvant therapy at the time of resection has not showed a difference in outcomes, and importantly did not demonstrate a difference in morbidity in patients that were treated after showing radiographic progression.<sup>46</sup> A generally accepted standard for starting treatment is persistent growth over a period of months or development of symptoms.<sup>46,47</sup> In our case, a recurrence was identified on routine follow-up imaging at 3 months and demonstrated continued interval growth at 6 months. Given the location of the lesion and interval growth, the decision was made to begin treatment. A generally accepted standard for treatment of pediatric desmoid tumor consists of vinblastine and methotrexate with a prolonged treatment course of nearly a year resulting in a progression-free survival (PFS) rate of 29% at 43 months.<sup>48</sup>

Recently, treatment of desmoid tumors with tyrosine kinase inhibitors (TKIs) has gained interest. Though the mechanism of action of TKI on desmoid tumors is not completely understood, alterations in the WNT-beta-catenin pathway have been implicated in tumorigenesis of desmoid tumors. TKIs target vascular endothelial growth factor receptors 1, 2, 3, platelet-derived growth factor receptor alpha and beta, and C-kit tyrosine kinases.<sup>49</sup> Additionally, TKI may have off stream target effects including AKT, B-RAF, and RET, which have been implicated in desmoid tumorigenesis.<sup>49</sup>

The delivery of chemotherapy generally involves the need for indwelling central venous access as well as risks of development of myelosuppression and infection.<sup>48</sup> TKIs can be delivered orally with a favorable side effect profile, with the most common adverse events including hypertension, hypothyroidism, and skin and hair changes. In adult refractory desmoid tumor, sorafenib showed PFS of 89% compared to 46% in the placebo group.<sup>17</sup> To date, there is no large-scale study on the use of sorafenib in pediatric desmoid tumor; however, it has been studied in children with other oncologic diagnoses

**Table 1** Literature review of previously reported paraspinal desmoid tumors

Year	Author	Age	Sex	Location	Antecedent trauma	Management
1973	Wyler and Harris	39 y	Female	Cervicothoracic	Laminectomy	Surgery
1979	Friede and Pollak	11 y	Female	Thoracic	None	Surgery
1985	Graeber et al	34 y	Male	Thoracic	None	Surgery
1988	Oberthaler and Rhomberg	21 y	Male	Thoracic	Surgery	Surgery
1994	Kriss and Warf	19 mo	Female	Cervical	None	Surgery
1996	Maurer et al	18 y	Female	Thoracic	Surgery	Surgery
1996	Ko et al	3 y	Female	Thoracic	None	Surgery
1999	Lynch et al	49 y	Female	Thoracic	Laminectomy	Surgery
2000	Kawashima et al	12 y	Female	Thoracic	None	Surgery
2002	Shindle et al	12 y	Female	Thoracolumbar	None	Surgery
2006	Güzey et al	50 y	Female	Thoracolumbar	Laminectomy	Surgery
2007	Hara et al	50 y	Male	Thoracic	None	Chemotherapy/ radiotherapy
2008	Cohen et al	27 y	Female	Cervicothoracic	Motor vehicle accident	Surgery
2010	Lee and Lee	22 y	Female	Cervical	None	Surgery
2011	Sonmez et al	55 y	Female	Thoracolumbar	Laminectomy	Surgery
2013	Puvanesarajah et al	57 y	Female	Thoracic	Laminectomy	Surgery
2013	Furlan et al	41 y	Female	Lumbar	None	Surgery
2013	Chu et al	26 y	Male	Cervical	None	Surgery
2013	Shakur et al	45 y	Female	Cervicothoracic	Spinal excisional biopsy	Surgery
2013	Shakur et al	38 y	Female	Thoracic	Spinal excisional biopsy	Surgery
2015	Eksi et al	68 y	Female	Lumbar	None	Surgery
2018	Goldstein et al	67 y	Female	Cervical	None	Surgery
2019	Bohl et al	56 y	Female	Thoracolumbar	Spinal fusion	Surgery
2021	Lee et al	24 y	Female	Lumbosacral	None	Surgery
2021	Gupta et al	14 y	Female	Cervical	None	Surgery
2021	McCabe et al	16 y	Female	Cervicothoracic	Spinal fusion	Surgery

with proven safety.<sup>50</sup> Due to this lack of pediatric desmoid tumor data, duration of treatment, long-term PFS, and long-term side effects, the role of sorafenib in this population remains unclear.<sup>17,49</sup>

Sorafenib has also been shown to act relatively quickly, demonstrating radiological treatment effect within 2 weeks of treatment onset in the majority of patients.<sup>51</sup> While TKI can rarely lead to delayed wound healing, the incidence of poor wound healing is low.<sup>52</sup> In the event that additional surgery is needed in this patient, sorafenib should be stopped 24 hours before surgery and reestablished once the wound has healed sufficiently, but there are no significant considerations beyond that.<sup>53</sup> However, the recent double-blind clinical trial by Gounder et al<sup>17</sup> has demonstrated that it is an effective first-line treatment in cases in which the tumor is deemed inoperable or unreasonably high-risk. Further studies of the pediatric application of TKI have been proposed and are under investigation.<sup>49</sup>

## Conclusion

Desmoid tumors are rare, benign but locally aggressive connective tissue neoplasms that often occur after local tissue trauma, such as that caused by surgery. They most commonly occur in the abdomen or extremities but can rarely occur paraspinally. The majority of previously reported paraspinal desmoid tumor occurred following prior surgery or trauma at the site of the tumor. This case represents an exceedingly rare instance of a spontaneously arising paraspinal desmoid tumor in a pediatric patient with no surgical or family history. Surgery remains the mainstay of treatment for symptom control and tissue diagnosis. Due to the recurrent nature of desmoid tumor, close clinical and radiological monitoring of these patients is vital for early diagnosis and timely intervention.

## Conflict of Interest

None declared.

## References

- de Camargo VP, Keohan ML, D'Adamo DR, et al. Clinical outcomes of systemic therapy for patients with deep fibromatosis (desmoid tumor). *Cancer* 2010;116(09):2258–2265
- Master SR, Mangla A, Puckett Y, Shah C. *Desmoid Tumor*. Treasure Island, FL: StatPearls; 2021
- Skubitz KM. Biology and treatment of aggressive fibromatosis or desmoid tumor. *Mayo Clin Proc* 2017;92(06):947–964
- Martínez Trufero J, Pajares Bernad I, Torres Ramón I, Hernando Cubero J, Pazo Cid R. Desmoid-type fibromatosis: who, when, and how to treat. *Curr Treat Options Oncol* 2017;18(05):29
- Lazar AJ, Tuvin D, Hajibashi S, et al. Specific mutations in the beta-catenin gene (CTNNB1) correlate with local recurrence in sporadic desmoid tumors. *Am J Pathol* 2008;173(05):1518–1527
- Penel N, Chibon F, Salas S. Adult desmoid tumors: biology, management and ongoing trials. *Curr Opin Oncol* 2017;29(04):268–274
- Righetti AEM, Jacomini C, Parra RS, de Almeida ALNR, Rocha JJR, Fêres O. Familial adenomatous polyposis and desmoid tumors. *Clinics (São Paulo)* 2011;66(10):1839–1842
- Timbergen MJM, van de Poll-Franse LV, Grünhagen DJ, et al. Identification and assessment of health-related quality of life issues in patients with sporadic desmoid-type fibromatosis: a literature review and focus group study. *Qual Life Res* 2018;27(12):3097–3111
- Honeyman JN, Quaglia MP. Desmoid tumors in the pediatric population. *Cancers (Basel)* 2012;4(01):295–306
- Friede RL, Pollak A. Neurosurgical desmoid tumors: presentation of four cases with a review of the differential diagnoses. *J Neurosurg* 1979;50(06):725–732
- Gupta A, Batta NS, Batra V. Postoperative recurrent paraspinal fibromatosis after resection of cervical meningioma and review of literature. *Indian J Radiol Imaging* 2021;31(02):514–518
- Kawashima A, Fishman EK, Hruban RH, Kuhlman JE. Intrathoracic paraspinal desmoid with intracanalicular extension: computed tomography and magnetic resonance imaging findings. *Orthopedics* 2000;23(04):381–382
- Ko SF, Ng SH, Hsiao CC, et al. Juvenile fibromatosis of the posterior mediastinum with intraspinal extension. *AJNR Am J Neuroradiol* 1996;17(03):522–524
- Kriss TC, Warf BC. Cervical paraspinal desmoid tumor in a child: case report. *Neurosurgery* 1994;35(05):956–959, discussion 959
- McCabe FJ, Hussey AJ, McCabe JP. A rare paraspinal desmoid tumour following instrumented scoliosis correction in an adolescent. *Case Rep Orthop* 2021;6665330
- Shindle MK, Khanna AJ, McCarthy EF, O'Neill PJ, Sponseller PD. Desmoid tumor of the spinal canal causing scoliosis and paralysis. *Spine* 2002;27(12):E304–E307
- Gounder MM, Mahoney MR, Van Tine BA, et al. Sorafenib for advanced and refractory desmoid tumors. *N Engl J Med* 2018;379(25):2417–2428
- Alexander F. Neuroblastoma. *Urol Clin North Am* 2000;27(03):383–392
- Bohl MA, Leveque JC, Bayles S, Sethi R. Postoperative development of desmoid tumor after surgical correction of adult spinal deformity: case report and review of literature. *World Neurosurg* 2019;128:4–10
- Chu KF, Samara MS, Laver N, Wein RO. A rare presentation of a large extra-abdominal desmoid tumor of the posterior neck and back. *Am J Otolaryngol* 2013;34(06):727–730
- Cohen S, Ad-El D, Benjaminov O, Gutman H. Post-traumatic soft tissue tumors: case report and review of the literature a propos a post-traumatic paraspinal desmoid tumor. *World J Surg Oncol* 2008;6:28
- Eksi MS, Turkoz HK, Eksi E, Akakin A, Toktas ZO, Konya D. Locally aggressive de novo spinal fibromatosis: case report and review of the literature. *Turk Neurosurg* 2015;25(05):818–823
- Furlan JC, Valiante T, Dickson B, Kiehl TR. Paraspinal desmoid-type fibromatosis as a cause of low back pain. *Spine J* 2013;13(12):1958–1959
- Goldstein A, Hoang S, Miller DC, Mesfin FB. Extra-abdominal desmoid tumor mimicking cervical spine schwannoma. *Cureus* 2018;10(08):e3145
- Graeber GM, Seyfer AE, Shriver CD, Awan M. Desmoid tumor of the paraspinal muscle involving the chest wall. *Mil Med* 1985;150(08):458–461
- Güzey FK, Emel E, Bas NS, Ozkan N, Turgut H, Sel B. Aggressive postoperative lumbar fibromatosis after the placement of instrumentation for treatment of spondylolisthesis. Case report. *J Neurosurg Spine* 2006;4(04):338–341
- Hara R, Matsuguma H, Suzuki H, et al. Desmoid tumor presenting as a superior sulcus tumor: a unique bone change in the vertebral body. *Ann Thorac Surg* 2007;84(05):1752–1754
- Lee JH, Paeng SH, Cho HJ, Kim ST, Lee WH. Desmoid fibromatosis in the multifidus muscle misdiagnosed as intramuscular schwannoma by incisional biopsy: a case report. *Korean J Neurotrauma* 2021;17(02):212–216
- Lee YC, Lee JW. Innovative treatment for huge nuchal desmoid tumour: a case report with a 2-year follow-up. *J Plast Reconstr Aesthet Surg* 2010;63(08):e622–e626
- Lynch JJ, Parvizi J, Scheithauer BW, Krauss WE. Development of postoperative fibromatosis after resection of an intraspinal meningioma. Case report. *J Neurosurg* 1999;90(01):121–124
- Maurer F, Horst F, Pfannenberger C, Wehrmann M. Multifocal extra-abdominal desmoid tumor—diagnostic and therapeutic problems. *Arch Orthop Trauma Surg* 1996;115(06):359–362
- Oberthaler W, Rhomberg W. Aggressive fibromatosis. A rare cause for lumbar bulging. *Arch Orthop Trauma Surg* 1988;107(06):388–390
- Puvanesarajah V, Lina IA, Liauw JA, Hsu W, Burger PC, Witham TF. Desmoid tumor formation following posterior spinal instrumentation placement. *Evid Based Spine Care J* 2013;4(02):137–142
- Shakur SF, Takagi I, Jacobsohn JA, Golden BM, Karahalios DG. Spinal fibromatosis: a report of two cases and review of the literature. *Spine J* 2013;13(08):e1–e6
- Sonmez E, Altinors N, Gulsen S, Ozen O. Extraabdominal desmoid tumor appearing following resection of thoracolumbar schwannoma. *Turk Neurosurg* 2011;21(02):246–248
- Wyller AR, Harris AB. Recurrent desmoid tumor following cervical laminectomy. Case report. *J Neurosurg* 1973;39(01):114–116
- Ganeshan D, Amini B, Nikolaidis P, Assing M, Vikram R. Current update on desmoid fibromatosis. *J Comput Assist Tomogr* 2019;43(01):29–38
- Umer M, Saeed J, Zahid N. Aggressive fibromatosis in pediatric population—a case series. *Int J Surg Case Rep* 2018;52:45–48
- Lacayo EA, Glastonbury CM, Hoang JK, Magliocca KR, Hill KL, Hudgins PA. Deep neck fibromatosis after discectomy and cervical fusion: case series and review of the literature. *AJR Am J Roentgenol* 2016;206(05):1068–1072
- Mujtaba B, Call C, Rowland F, et al. Desmoid fibromatosis following surgical resection of spinal meningioma. *Radiol Case Rep* 2020;15(06):697–701
- Schlag H, Neuhoff J, Castein J, Hoffmann C, Kandziora F. Sporadic desmoid fibromatosis of the neck after dorsal spondylodesis of the cervical spine. *Surg Neurol Int* 2022;13:64
- Schlemmer M. Desmoid tumors and deep fibromatoses. *Hematol Oncol Clin North Am* 2005;19(03):565–571, vii–viii
- Cheon SS, Cheah AY, Turley S, et al. beta-Catenin stabilization dysregulates mesenchymal cell proliferation, motility, and invasiveness and causes aggressive fibromatosis and hyperplastic cutaneous wounds. *Proc Natl Acad Sci U S A* 2002;99(10):6973–6978
- Tejpar S, Nollet F, Li C, et al. Predominance of beta-catenin mutations and beta-catenin dysregulation in sporadic aggressive

- fibromatosis (desmoid tumor). *Oncogene* 1999;18(47):6615–6620
- 45 Peng PD, Hyder O, Mavros MN, et al. Management and recurrence patterns of desmoids tumors: a multi-institutional analysis of 211 patients. *Ann Surg Oncol* 2012;19(13):4036–4042
- 46 Orbach D, Brennan B, Bisogno G, et al. The EpSSG NRSTS 2005 treatment protocol for desmoid-type fibromatosis in children: an international prospective case series. *Lancet Child Adolesc Health* 2017;1(04):284–292
- 47 Desmoid Tumor Working Group. The management of desmoid tumours: A joint global consensus-based guideline approach for adult and paediatric patients. *Eur J Cancer* 2020;127:96–107
- 48 Skapek SX, Ferguson WS, Granowetter L, et al; Pediatric Oncology Group. Vinblastine and methotrexate for desmoid fibromatosis in children: results of a Pediatric Oncology Group Phase II Trial. *J Clin Oncol* 2007;25(05):501–506
- 49 Sparber-Sauer M, Orbach D, Navid F, et al. Rationale for the use of tyrosine kinase inhibitors in the treatment of paediatric desmoid-type fibromatosis. *Br J Cancer* 2021;124(10):1637–1646
- 50 Kim A, Widemann BC, Krailo M, et al. Phase 2 trial of sorafenib in children and young adults with refractory solid tumors: a report from the Children's Oncology Group. *Pediatr Blood Cancer* 2015;62(09):1562–1566
- 51 Gounder MM, Lefkowitz RA, Keohan ML, et al. Activity of Sorafenib against desmoid tumor/deep fibromatosis. *Clin Cancer Res* 2011;17(12):4082–4090
- 52 Shah DR, Dholakia S, Shah RR. Effect of tyrosine kinase inhibitors on wound healing and tissue repair: implications for surgery in cancer patients. *Drug Saf* 2014;37(03):135–149
- 53 Brose MS, Frenette CT, Keefe SM, Stein SM. Management of sorafenib-related adverse events: a clinician's perspective. *Semin Oncol* 2014;41(Suppl 2):S1–S16