

Wilson's Disease

Manida Wungjiranirun, MD¹ Kaveh Sharzehi, MD, MS¹

¹Division of Gastroenterology, Department of Medicine, Oregon Health and Science University, Portland, Oregon

Semin Neurol 2023;43:626–633.

Address for correspondence Manida Wungjiranirun, MD, Division of Gastroenterology, Department of Medicine, Oregon Health and Science University, 3161 SW Pavilion Loop, Mail Code: L461 Portland, OR 97239 (e-mail: Wungjira@ohsu.edu).

Abstract

Wilson's disease (WD) can present with liver disease, neurological deficits, and psychiatric disorders. Results of genetic prevalence studies suggest that WD might be much more common than previously estimated. Early recognition of WD remains challenging because it is a great imitator and requires a high index of suspicion for correct and timely diagnosis. Early diagnosis of WD is crucial to ensure that patients can be started on adequate treatment. In association with other clinical and biochemical tests, liver biopsy results and molecular genetic testing can also be used for diagnosing WD. Medical therapy is effective for most patients; liver transplant can rescue those with acute liver failure or those with advanced liver disease who fail to respond to or discontinue medical therapy. Although novel therapies, such as gene therapy, are on the horizon, screening and prevention of delayed diagnosis remains paramount.

Keywords

- ▶ Wilson's disease
- ▶ acute liver failure

Prevalence and Incidence

Wilson's disease (WD) is a rare, inherited, progressive, severely debilitating disorder of copper metabolism. It was first described in 1912 by Kinneer Wilson as "progressive lenticular degeneration," a familial, lethal neurological disease accompanied by chronic liver disease leading to cirrhosis.¹ WD has an autosomal recessive inheritance and is caused by mutations in the *ATP7B* gene. The dysfunction in the *ATP7B* protein leads to impaired copper excretion into the bile and causes a combination of hepatic, neurologic, and psychiatric dysfunction. In 1968, Sternlieb and Scheinberg estimated the worldwide prevalence to be 1:200,000 based on data available at the time.² In 1984, they updated their estimate to be 1:30,000 to 1:50,000. They regarded this estimate to be universal, except for small isolated populations with higher frequencies.³ Most high prevalence estimates are from regions in the world where first-cousin marriage is common. In 2020, Sandahl et al reviewed the prevalence of WD systematically, using high-quality nationwide databases. They estimated the prevalence to remain unchanged at 1:40,000 to 1:50,000.⁴ The assumption has been that WD has 100% penetrance for affected individuals; hence, the frequency of disease-causing mutated alleles is ~1:180 to 1:300. However, studies from France and Italy

(Sardinia) suggested that the genetic prevalence may be three to four times higher than the clinical disease prevalence. This raises the possibility that the penetrance may not be 100%, as is generally assumed.

Pathophysiology

The past two decades have seen major advances in our understanding of the pathogenesis, cellular biology, and molecular genetics of WD. Mutations in the ATPase copper-transporting β (*ATP7B*) gene, located on chromosome 13, lead to impaired function of the copper-transporting protein. The *ATP7B* gene is highly expressed in the liver, kidney, and placenta. The *ATP7B* gene encodes a transmembrane protein ATPase, which functions as a copper-dependent ATPase. Dietary copper is absorbed in the stomach and duodenum and transported via the portal vein to the liver, which is the main organ responsible for copper homeostasis. Copper is taken up into the hepatocyte via copper transporter 1 on the sinusoidal aspect of the hepatocyte. A specific copper chaperone, ATOX1, delivers copper to *ATP7B* by copper-dependent protein-protein interaction. *ATP7B* brings about transport of copper into the trans-Golgi and holo-ceruloplasmin and, under conditions of copper loading, into vesicles for export of copper into bile. The biliary excretion

process includes another protein, called MURR1, which interacts directly with ATP7B (→Fig. 1). Therefore, the ATP7B transporter has dual synthetic and excretory roles, functioning in the transport of copper into the trans-Golgi compartment, for incorporation into the plasma ceruloplasmin, and into the bile for excretion of excess stores. Hepatobiliary excretion is the primary mechanism for removal of excess copper from the body, whereas urinary excretion is negligible in healthy persons.^{3,5,6} In WD, dysfunction of the ATP7B protein leads to copper accumulation in multiple organs, most notably in the liver and brain, resulting in hepatic, neurological, and psychiatric dysfunction.⁷

The histological changes of early stage hepatic copper accumulation include macrosteatosis, microsteatosis, and glycogenated nuclei. These changes are nonspecific and can be seen in various other disorders, such as nonalcoholic steatohepatitis.⁸ Intermediate stages of the disease are characterized by periportal inflammation, mononuclear cellular infiltrates, lobular necrosis, and bridging fibrosis. Mallory bodies can be seen in up to 50% of biopsy specimens.⁹ Advanced liver disease is characterized as micronodular or a mixed of macronodular–micronodular cirrhosis. In patients with acute liver failure (ALF), parenchymal apoptosis and necrosis is seen on the background of cirrhosis.¹⁰

Clinical Manifestations

With current genetic and laboratory diagnostic capabilities, WD may sometimes be diagnosed during the preclinical or asymptomatic stage. Most often, however, diagnosis does not occur until after symptoms have appeared. The most frequent clinical manifestations of WD can be divided into three

modes of appearance: hepatic, neurological, and psychiatric. Hepatic impairment commonly occurs during the first decade of life, whereas neuropsychiatric symptoms more frequently appear during the second through fourth decades of life.¹¹ However, neurological manifestations may be the initial presentation in 40 to 60% of individuals, with a broad reported range that extends from as early as age 6 years to as late as 72 years.¹²

Hepatic Dysfunction

Hepatic WD has a variable clinical presentation that ranges from asymptomatic abnormalities in liver function tests to ALF that is fatal without emergent liver transplant.^{13,14} WD accounts for ~5% of ALF cases worldwide.¹⁵ ALF is defined by coagulopathy with an international normalized ratio (INR) of >1.5, any degree of encephalopathy, in patients without cirrhosis, with an illness of <26 weeks.¹⁶ Patients with an acute presentation of WD may be categorized as ALF if they develop hepatic encephalopathy in the setting of coagulopathy and alterations in liver tests.¹⁴ Precipitants of ALF in patients with WD include a viral infection or nonadherence to medical management. Despite having underlying WD, these patients are still considered as having ALF due to the poor prognosis without liver transplant, and because their clinical presentation is similar to that of ALF, with liver failure, coagulopathy, and hepatic encephalopathy.¹⁴ Other classic findings in ALF due to WD include the following: a patient <20 years of age, with Coombs negative hemolytic anemia, a high bilirubin to alkaline phosphatase ratio, relatively modest rise in transaminases (< 2,000 IU/L), and rapid progression to renal failure.^{13,14} Hemolysis, the consequence of copper-induced damage to erythrocyte membranes, is a

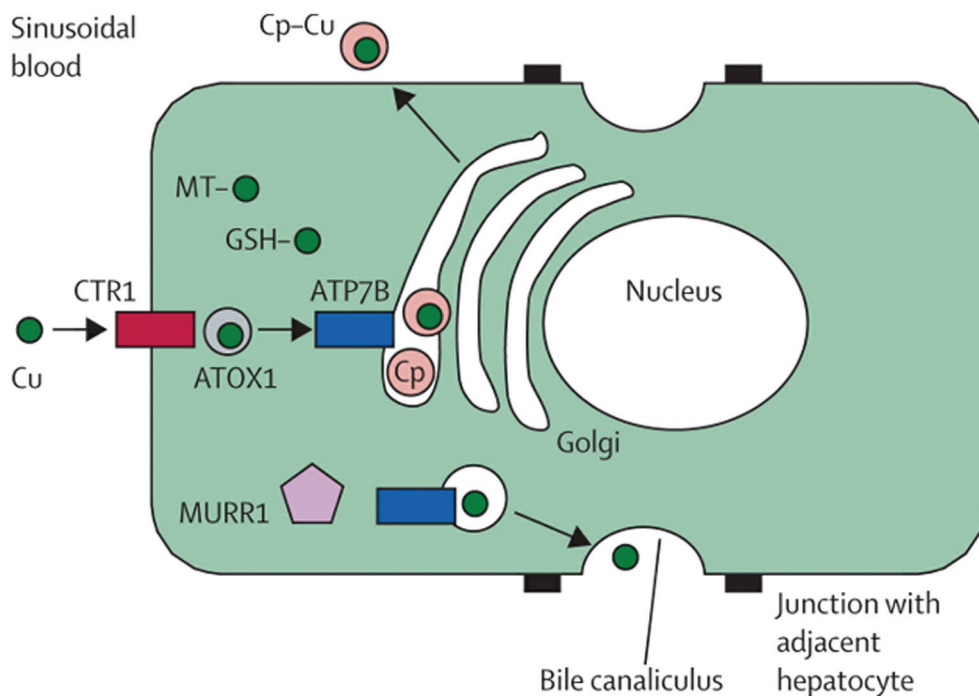


Fig. 1 Pathways of copper metabolism in the hepatocyte. Cp, caeruloplasmin; CTR1, copper transporter 1; Cu, copper; GSH, glutathione; MT, metallothioneins. (With permission from Ala A et al. *Lancet* 2007;369(9559):397–408.)

distinguishing characteristic of ALF due to WD. Patients may present with a sudden and marked drop in hemoglobin with an unconjugated hyperbilirubinemia.¹³

Outside of ALF, patients with WD may present with asymptomatic hepatomegaly, isolated splenomegaly, elevated aminotransferase, fatty liver, acute hepatitis with acute liver injury, and cirrhosis with or without decompensation.¹⁷ Other patients may present with intermittent episodes of jaundice secondary to hemolysis without clinically apparent liver disease. Autoimmune hepatitis (AIH) and WD can be clinically indistinguishable due to the mutual presence of immunoglobulins and autoantibodies. Thus, patients with AIH who are not responding to medical management should be evaluated for WD.¹³ Patients with cirrhosis due to WD may develop hepatic decompensation including ascites, variceal bleeding, hepatocellular carcinoma, and encephalopathy. These patients need standard cirrhosis management including abdominal imaging to screen for hepatocellular carcinoma, and may need an upper endoscopy for varices screening and management.

Neurological Dysfunction

Basal ganglia–based movement abnormalities are hallmarks of WD; therefore, impaired coordination, handwriting changes, and slurred speech with drooling are reported frequently in WD. The most common heralding symptom of neurological WD is dysarthria (57.6%), followed by dystonia (42.4%), abnormal gait (37.8%), tremor (36.2%), parkinsonism (17.3%), choreoathetosis (15.3%), and seizures (4.7%).^{11,18} In a recent study of recently diagnosed patients with WD, 62% of the patients exhibited tremors and ataxia, whereas only 15% demonstrated dystonia.¹⁹ Even though the neurological manifestation of WD is heterogenous, the neurologic variant has been grouped (in order of frequency) into parkinsonian, pseudosclerotic (tremor), dystonic, and choreic subtypes.²⁰

Tremor is a common neurologic feature, present in 22 to 55% of patients with WD. The wing-beating tremor (proximal tremor, appearing when the patient holds arms semiflexed and outstretched) has been suggested to be a hallmark type of tremor in WD.^{19,21} Patients also may exhibit a typical postural and action tremor that can be easily confused with essential tremor.²²

Another common neurologic finding in WD patients is dystonia, which is seen in 10 to 65% of all patients.²³ Dystonic symptoms vary from focal to generalized dystonia. Focal dystonia in the craniofacial region can manifest as severe dysphonia, dysarthria, risus sardonicus, and dysphagia. Generalized dystonia can cause debilitating symptoms with secondary skeletal changes and inability to walk.^{18,19} Hypokinetic features, which become evident in 20 to 60% of patients, include masked face, hypophonic soft voice, micrographia, and shuffling gait. The parkinsonian symptoms tend to be symmetrical, but unilateral tremor can be observed, which should be distinguished from idiopathic Parkinson's disease.^{11,18,19,24,25}

Choreoathetosis and other hyperkinetic movement are encountered less frequently in WD and often are seen in

younger individuals. Incoordination and balance problems are more often the result of basal ganglia dysfunction, rather than manifestations of true cerebellar ataxia.^{18,26}

Psychiatric Dysfunction

WD can present with such a variety of psychiatric and cognitive symptoms that it has been named the “great masquerader.”²⁷ The psychiatric form of WD typically appears in the second decade of life. The reported prevalence of psychiatric disturbance in WD ranges between 4 and 15%, but up to 20% of affected individuals report having seen a psychiatrist prior to the diagnosis.^{28–30} In this variant, the median time between the onset of psychiatric symptoms and diagnosis of WD averages 2.42 years.³¹ In comparison, the time between initial symptoms and diagnosis of WD is 1.5 years for the neurologic variant and 0.5 years for hepatic disease.²⁵ The most common psychopathological features with which WD presents at onset are a decrease in scholastic performance, behavioral problems, affective disorders, and psychosis.^{27,32–34}

Frank psychosis is present in ~10% of these patients, and frequently is misdiagnosed as schizophrenia or bipolar disease. Psychosis or schizophrenia-like syndrome in WD is characterized most often by persecutory delusion, hallucinations, or a very complex schizophrenia-like syndrome.^{29,34} Behavioral disturbances (disinhibition, agitation, and aggression) and personality change are frequently reported, but these are nonspecific and can overlap with other psychiatric disorders. Clinical depression has been reported with a low prevalence of 2 to 3% in multiple studies.^{11,25,35,36} Suicide attempts have been disclosed with a prevalence of 3 to 15%.^{25,29} Cognitive impairment typically is mild and reported in a low percentage of patients.^{18,29,34} However, the prevalence of cognitive impairment is higher among WD patients with neurological dysfunction (45%).³² Dementia is infrequent in WD, but may become apparent in individuals with advanced disease.³⁷

Sleep and Autonomic Dysfunction

Frequent nocturnal awakening, poor nocturnal sleep quality, delayed morning wake-up, and sleepiness during the day have been reported in patients with WD. A recent study indicated that individuals with WD experience more frequent and more severe insomnia than normal individuals. Insomnia was more severe in neurologic variant than hepatic form of the disease, and more severe in patients with depression. REM sleep behavior disorder is more frequent in WD than in the normal population.³⁸ Anticopper therapies may improve REM sleep behavior disorder in patients with WD by reducing the copper overload in the subcoeruleus region responsible for REM sleep atonia.³⁹

The autonomic nervous system (ANS) may be affected in patients with WD. The exact pathophysiology of ANS damage is not clear, but may result from central nervous system, peripheral nervous system, or cardiac involvement.⁴⁰ Both sympathetic and parasympathetic nervous systems may be impaired in WD.⁴⁰ ANS dysfunction is present in almost one-third of WD patients; however, these abnormalities often are

asymptomatic and diagnosed only via testing.^{41,42} ANS dysfunction may precede the development of other neurological abnormalities, with orthostatic hypotension being the most frequently observed feature of ANS dysfunction.⁴¹

Other Clinical Features

Hematologic

Coombs-negative hemolytic anemia may be the initial manifestation of WD in 10 to 15% of cases.^{12,43} Low bone density and bone fractures are also common in WD. Low bone density may be related to inadequate food intake, liver disease, and poorly understood neuroendocrinological mechanisms.⁴⁴ Higher fracture rates may be the consequence of low bone density and frequent falls due to neurological motor dysfunction.

Cardiac

Myocardial involvement in WD is not widely recognized, but also is surprisingly common and may include both cardiac hypertrophy and electrocardiographic abnormalities.¹²

Ophthalmologic

Ophthalmologic evaluation is part of the diagnostic workup for WD. Ophthalmologic changes observed include Kayser-Fleischer rings, which are the result of copper deposition within Descemet's membrane, and sunflower cataracts due to copper deposition in the anterior capsule.¹³ Kayser-Fleischer rings appear as a reddish/greenish band 1 to 3 mm in width, starting with an arc in the superior pole, followed by an arc in the inferior pole, which eventually merge to form a ring around the cornea (► Fig. 2).⁴⁵ Both findings are seen via slit lamp examination.^{13,46}

Diagnosis

The diagnosis of WD is accomplished using serologic data, physical examination findings, clinical history, and more recently, genetic testing. Advances in the diagnostic tools have allowed for earlier diagnosis when patients have mild disease.¹³ Patients with WD typically have abnormal aminotransferase levels even at a young age. They may also have transient, unconjugated hyperbilirubinemia due to hemolysis.¹³

Ceruloplasmin is a glycoprotein synthesized by hepatocytes that contains copper atoms. Ceruloplasmin as a screening tool for WD has limitations. Several factors may affect the concentration of ceruloplasmin since it is an acute phase reactant and increases with inflammation. Additionally, ceruloplasmin is elevated by hyperestrogenemia in pregnancy, with oral contraceptive pills, and with estrogen supplementation, and may be decreased in absolute copper deficiency.^{13,47} Thus, a serum ceruloplasmin within the normal laboratory range does not exclude the diagnosis of WD.¹³

Serum copper is primarily a reflection of the serum ceruloplasmin level and therefore is not typically used in the diagnosis of WD. One exception is in ALF due to WD,

when the serum copper level is significantly elevated (>200 µg/dL) due to hepatic necrosis and release of copper from hepatocytes.⁴⁸ In general, however, a 24-hour urinary copper test is a more valuable test for diagnosing WD. This test helps quantify non-ceruloplasmin-bound copper. A cut-off of >100 µg/24 hours of urinary copper is the typical value used to diagnose WD in symptomatic patients.^{21,49}

A liver biopsy is a more invasive diagnostic test for WD. However, it is helpful in evaluating for other etiologies of liver disease and assessing for liver fibrosis and progression to cirrhosis. Findings on liver biopsy in WD are nonspecific and may include steatosis and inflammatory infiltrates, with interface hepatitis similar to AIH.¹³ Hepatic copper quantification on liver biopsy is also useful in diagnosing WD. However, copper is patchily deposited, which may result in negative copper staining in small biopsy samples.¹³ Normal hepatic copper content is <50 µg/g dry weight, whereas in WD the hepatic copper content typically is >250 µg/g dry weight.¹³ Hepatic copper content is also elevated in cirrhosis and cholestatic liver disease, though typically not to the degree present in WD.⁵⁰

European societies (European Association for the Study of the Liver in 2012 and European Society for Pediatric Gastroenterology, Hepatology and Nutrition in 2018) have advocated for using the Leipzig score to establish a diagnosis of WD.^{51,52} The components of this scoring system include presence or absence of Kayser-Fleischer rings, neurological symptoms, level of serum ceruloplasmin, the presence or absence of Coombs-negative hemolytic anemia, liver copper quantification, urinary copper excretion over 24 hours, and mutation analysis for ATP7B gene. The diagnosis of WD is deemed "unlikely," "probable," or "highly likely" based on the number of points accrued. The Leipzig scoring system is limited by the fact that it is derived by expert opinion, without specific data to support the weighting ascribed to individual components.⁵³

Treatment

Treatment of WD consists of lifelong oral pharmacotherapy in addition to dietary copper avoidance (► Table 1). If treatment is started early, and taken consistently, patients with WD have a survival similar to the general populations.¹³ The main treatments consist of D-penicillamine and trientine, which are copper chelators, and zinc, which inhibits intestinal copper absorption. Patients without symptoms should remain asymptomatic with treatment. Patients with hepatic dysfunction may begin to see improvement in synthetic function, jaundice, and ascites after 2 to 6 months of treatment with continued improvement a possibility.¹³ A retrospective observational study suggests that discontinuation of oral treatment for WD leads to rapid clinical deterioration and potential death.⁵⁴

Penicillamine induces renal excretion of copper but carries the potential for several serious adverse effects. Early sensitivity includes fever, cutaneous eruptions, proteinuria, thrombocytopenia, and neutropenia that can occur in the first 1 to 3 weeks of treatment. Later toxicities may include

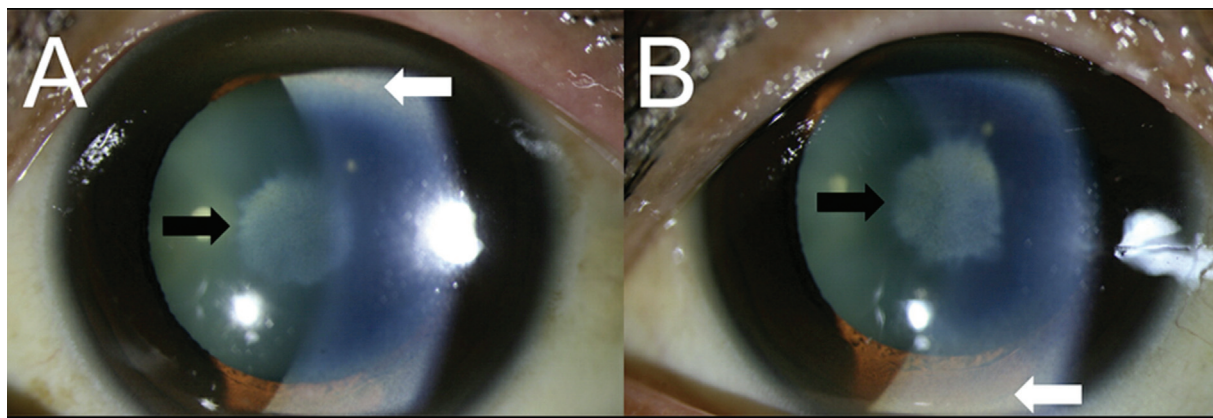


Fig. 2 Kayser-Fleischer ring was seen in the peripheral cornea (white arrow). A sunflower cataract was observed on the anterior lens capsule in both eyes (black arrow) (A—right eye, B—left eye). (With permission from Jang HJ, Kim JM, Choi CY. Elemental analysis of sunflower cataract in Wilson's disease: a study using scanning transmission electron microscopy and energy dispersive spectroscopy. *Exp Eye Res* 2014;121, 58–66.

Table 1 Wilson's disease treatment^{13,51}

Treatment	Mechanism of action	Side effects	Treatment goals	Additional notes
D-penicillamine	Induces urinary excretion of copper via chelation	Early sensitivity reactions <ul style="list-style-type: none"> • Fever • Cutaneous eruptions • Lymphadenopathy • Neutropenia • Thrombocytopenia Later reactions <ul style="list-style-type: none"> • Bone marrow toxicity • Dermatological toxicity • Lupus-like syndrome • Hepatotoxicity Very late side effects <ul style="list-style-type: none"> • Nephrotoxicity • Myasthenia gravis • Polymyositis • Loss of taste • Serous retinitis • Immunoglobulin A depression 	Clinical and biochemical improvement Urinary copper excretion of 200–500 µg/24 h on stable treatment	10–20% of patients may experience neurological worsening in the initial phase of treatment Dose reduction needed during surgery for wound healing and during pregnancy Supplemental pyridoxine is recommended as D-penicillamine interferes with pyridoxine action
Trientine	Induces urinary excretion of copper via chelation Also chelates iron	Pancytopenia Colitis Esophageal irritation Reversible sideroblastic anemia occurs with overtreatment due to copper deficiency	Clinical and biochemical improvement Urinary copper excretion of 150–500 µg/24 h on stable treatment	10–15% of patients may experience neurological worsening in the initial phase of treatment Dose reduction needed during surgery for wound healing and during pregnancy Avoid coadministration of Trientine with iron due to potential toxicity
Zinc	Induces metallothionein which inhibits intestinal uptake of copper	Gastric irritation Gastritis Immunosuppressant effects Reduction in leukocyte chemotaxis Elevation in lipase/amylase without clinical or radiologic evidence of pancreatitis	Clinical and biochemical improvement Urinary excretion of copper <100 µg/24 h on stable treatment	Neurologic worsening may occur during the initial phase of treatment but is uncommon No dosage reduction needed during surgery or pregnancy Unknown if high-dose zinc is safe with impaired renal function

nephrotoxicity, bone marrow toxicity, lupus-like syndrome, and dermatologic toxicities, including lichen planus and pemphigoid lesions. Because of these toxicities, incremental dosing is recommended.¹³

Trientine also induces renal excretion of copper, and is recommended in patients intolerant of penicillamine. Unlike penicillamine, trientine has few side effects, with rare cases of pancytopenia and colitis reported.^{13,55} Of note, both penicillamine and other chelators including trientine may provoke potentially irreversible neurological deterioration due to a sudden increase in free copper.⁵⁶ Thus, patients must be monitored very closely during treatment, particularly when initiating treatment with chelation therapy.

Zinc is an alternative treatment option from penicillamine and trientine that is typically used as maintenance therapy, but can be used as first-line treatment, typically in patients who are asymptomatic. Zinc inhibits the intestinal uptake of copper and is relatively well tolerated, with gastritis being the most frequently occurring adverse effect.¹³

Patients with hepatic decompensation due to WD including jaundice, ascites, encephalopathy, and varices may respond to medical treatments. However, in these patients who do not respond to, or are unable to tolerate medical therapy, liver transplantation should be considered. Liver transplantation as a treatment for WD corrects the hepatic metabolic defects in copper metabolism, and eliminates the need for medical therapy. Indications for liver transplant in WD are ALF, acute liver injury progressing to ALF, and decompensated cirrhosis.¹³ Survival after liver transplant for WD is excellent, with possibly better outcomes in patients undergoing transplant for decompensated liver disease than for ALF.^{13,51}

Liver transplantation is not recommended as primary treatment of neurologic symptoms in WD, since the hepatic manifestations are stabilized with medical management. Some data, however, suggest that neuropsychiatric symptoms improve after liver transplant.⁵⁷ Similarly, in a small study of patients with severe neurologic symptoms of dystonia and parkinsonism who underwent liver transplantation, statistically significant improvement in the modified Rankin scale, a scale used to quantify the degree of disability in daily activities, was evident in some individuals.⁵⁸ However, further prospective, multicentered studies are needed to demonstrate improvement in neurologic and psychiatric symptoms related to WD after liver transplant before this can be considered standard treatment.

Targeted molecular therapies that restore the localization and/or function of ATP7B are also being developed. A 20-residue peptide derived from α B-crystallin, a heat-shock protein, has been shown to restore localization of ATP7B in cells transfected with ATP7B-H1069Q. Whether this approach translates into a clinically meaningful restoration of ATP7B function remains to be seen.⁵⁹ Gene therapy using an adeno-associated viral vector has shown encouraging results in animal models of WD. In this model, a dose-dependent restoration of biliary copper excretion with normalization of urinary copper output, hepatic copper content, and liver function was found.⁶⁰ An open-label phase I/II trial was initiated in 2021 (NCT04537377).

Prognosis

Before the development of medical therapy, WD was considered an inevitably fatal disease. Early diagnosis in WD is key and is associated with reduced mortality and need for liver transplantation.⁶¹ The use of anticopper agents in preclinical or early disease allows clinically overt disease to be effectively prevented. Life expectancy and quality of life in treated patients with WD is similar to that in the general population.⁶² Most evidence suggests that both neurologic and hepatic symptoms improve with appropriate therapy in most patients, although dystonia is the least likely of the neurologic symptoms to respond to treatment.^{18,61,63} Psychiatric symptoms are also expected to improve with anticopper treatment, although there may be a plateau in response.⁶⁴

Prevention and Screening

Appropriate screening of individuals for WD enables timely initiation of treatment. The American Association for the Study of Liver Diseases recommends that first-degree relatives of patients who are newly diagnosed with WD should be screened for the disease. Screening should include genetic testing if available. Other options for screening are basic history and physical examinations, with particular attention to information regarding a history of liver disease, neurologic and psychiatric symptoms, and evaluation for Kayser-Fleischer rings. Additional workup should include serum copper, serum ceruloplasmin and albumin levels, basal 24-hour urinary copper excretion level, aminotransferase levels, and conjugated and unconjugated bilirubin levels.¹³ Additionally, any individual with a family member with WD, regardless of their degree of closeness to each other, who also exhibits signs or symptoms of the disease should be screened for WD.¹³

Conclusion

WD is a rare genetic disorder of copper metabolism affecting multiple organs. Its multitude of hepatic, neurological, and psychiatric manifestations can mimic other diseases often resulting in delayed diagnosis. WD should be among the differential diagnosis of a young individual with unexplained liver or neuropsychiatric disease. Early diagnosis is key to prevent end-organ damage, some which are irreversible. Copper chelating agents and zinc remain mainstay of therapy. Liver transplantation could be necessary in advanced liver disease. Targeted molecular and gene therapy are in the horizon. Ongoing monitoring for treatment compliance and screening family members are other important facets of disease management.

Conflict of Interest

None declared.

References

- 1 Wilson S. Progressive lenticular degeneration: a familial nervous disease associated with cirrhosis of the liver. *Brain* 1912;34(04): 295–507

- 2 Sternlieb I, Scheinberg IH. Prevention of Wilson's disease in asymptomatic patients. *N Engl J Med* 1968;278(07):352–359
- 3 Scheinberg IH, Sternlieb I. Wilson's disease. In: *Major Problems in Internal Medicine Series*. Philadelphia: W. B. Saunders; 1984:192
- 4 Sandahl TD, Laursen TL, Munk DE, Vilstrup H, Weiss KH, Ott P. The prevalence of Wilson's disease: an update. *Hepatology* 2020;71(02):722–732
- 5 Gitlin JD. Wilson disease. *Gastroenterology* 2003;125(06):1868–1877
- 6 Ala A, Walker AP, Ashkan K, Dooley JS, Schilsky ML. Wilson's disease. *Lancet* 2007;369(9559):397–408
- 7 Sandahl TD, Gormsen LC, Kjaergaard K, et al. The pathophysiology of Wilson's disease visualized: a human ⁶⁴Cu PET study. *Hepatology* 2022;75(06):1461–1470
- 8 Alt ER, Sternlieb I, Goldfischer S. The cytopathology of metal overload. *Int Rev Exp Pathol* 1990;31:165–188
- 9 Müller T, Langner C, Fuchsibichler A, et al. Immunohistochemical analysis of Mallory bodies in Wilsonian and non-Wilsonian hepatic copper toxicosis. *Hepatology* 2004;39(04):963–969
- 10 Strand S, Hofmann WJ, Grambihler A, et al. Hepatic failure and liver cell damage in acute Wilson's disease involve CD95 (APO-1/Fas) mediated apoptosis. *Nat Med* 1998;4(05):588–593
- 11 Machado A, Chien HF, Deguti MM, et al. Neurological manifestations in Wilson's disease: report of 119 cases. *Mov Disord* 2006;21(12):2192–2196
- 12 Pfeiffer RF. Wilson disease. *Continuum (Minneapolis)* 2016;22(4 Movement Disorders):1246–1261
- 13 Schilsky ML, Roberts EA, Bronstein JM, et al. A multidisciplinary approach to the diagnosis and management of Wilson disease: 2022 practice guidance on Wilson disease from the American Association for the Study of Liver Diseases. *Hepatology* 2022;0:1–49
- 14 Wendon J, Cordoba J, Dhawan A, et al; European Association for the Study of the Liver. Electronic address: easloffice@easloffice.eu Clinical practice guidelines panel Panel members EASL Governing Board representative. EASL Clinical Practical Guidelines on the management of acute (fulminant) liver failure. *J Hepatol* 2017;66(05):1047–1081
- 15 Ostapowicz G, Fontana RJ, Schiødt FV, et al; U.S. Acute Liver Failure Study Group. Results of a prospective study of acute liver failure at 17 tertiary care centers in the United States. *Ann Intern Med* 2002;137(12):947–954
- 16 Trey C, Davidson CS. The management of fulminant hepatic failure. *Prog Liver Dis* 1970;3:282–298
- 17 Schilsky ML, Roberts EA, Bronstein JM, et al. A multidisciplinary approach to the diagnosis and management of Wilson disease: executive summary of the 2022 practice guidance on Wilson disease from the American Association for the Study of Liver Diseases. *Hepatology* 2023;77(04):1428–1455
- 18 Burke JF, Dayalu P, Nan B, Askari F, Brewer GJ, Lorincz MT. Prognostic significance of neurologic examination findings in Wilson disease. *Parkinsonism Relat Disord* 2011;17(07):551–556
- 19 Członkowska A, Litwin T, Dzieżyc K, Karliński M, Bring J, Bjartmar C. Characteristics of a newly diagnosed Polish cohort of patients with neurological manifestations of Wilson disease evaluated with the Unified Wilson's Disease Rating Scale. *BMC Neurol* 2018;18(01):34
- 20 Walshe JM, Yealland M. Wilson's disease: the problem of delayed diagnosis. *J Neurol Neurosurg Psychiatry* 1992;55(08):692–696
- 21 Merle U, Schaefer M, Ferenci P, Stremmel W. Clinical presentation, diagnosis and long-term outcome of Wilson's disease: a cohort study. *Gut* 2007;56(01):115–120
- 22 Hedera P. Wilson's disease: a master of disguise. *Parkinsonism Relat Disord* 2019;59:140–145
- 23 Pellicchia MT, Crisculo C, Longo K, Campanella G, Filla A, Barone P. Clinical presentation and treatment of Wilson's disease: a single-centre experience. *Eur Neurol* 2003;50(01):48–52
- 24 Starosta-Rubinstein S, Young AB, Kluin K, et al. Clinical assessment of 31 patients with Wilson's disease. Correlations with structural changes on magnetic resonance imaging. *Arch Neurol* 1987;44(04):365–370
- 25 Oder W, Grimm G, Kollegger H, Ferenci P, Schneider B, Deecke L. Neurological and neuropsychiatric spectrum of Wilson's disease: a prospective study of 45 cases. *J Neurol* 1991;238(05):281–287
- 26 Stremmel W, Meyerrose KW, Niederau C, Hefter H, Kreuzpaintner G, Strohmeyer G. Wilson disease: clinical presentation, treatment, and survival. *Ann Intern Med* 1991;115(09):720–726
- 27 Soltanzadeh A, Soltanzadeh P, Nafissi S, Ghorbani A, Sikaroodi H, Lotfi J. Wilson's disease: a great masquerader. *Eur Neurol* 2007;57(02):80–85
- 28 Mura G, Zimbrea PC, Demelia L, Carta MG. Psychiatric comorbidity in Wilson's disease. *Int Rev Psychiatry* 2017;29(05):445–462
- 29 Denning TR, Berrios GE. Wilson's disease. Psychiatric symptoms in 195 cases. *Arch Gen Psychiatry* 1989;46(12):1126–1134
- 30 Litwin T, Gromadzka G, Członkowska A. Gender differences in Wilson's disease. *J Neurol Sci* 2012;312(1-2):31–35
- 31 Zimbrea PC, Schilsky ML. Psychiatric aspects of Wilson disease: a review. *Gen Hosp Psychiatry* 2014;36(01):53–62
- 32 Kumar R, Datta S, Jayaseelan L, Gnanmuthu C, Kuruville K. The psychiatric aspects of Wilson's disease—a study from a neurology unit. *Indian J Psychiatry* 1996;38(04):208–211
- 33 Lowette KF, Desmet K, Witters P, et al. Wilson's disease: long-term follow-up of a cohort of 24 patients treated with D-penicillamine. *Eur J Gastroenterol Hepatol* 2010;22(05):564–571
- 34 Srinivas K, Sinha S, Taly AB, et al. Dominant psychiatric manifestations in Wilson's disease: a diagnostic and therapeutic challenge!. *J Neurol Sci* 2008;266(1-2):104–108
- 35 Prashanth LK, Taly AB, Sinha S, Arunodaya GR, Swamy HS. Wilson's disease: diagnostic errors and clinical implications. *J Neurol Neurosurg Psychiatry* 2004;75(06):907–909
- 36 Lin LJ, Wang DX, Ding NN, Lin Y, Jin Y, Zheng CQ. Comprehensive analysis on clinical features of Wilson's disease: an experience over 28 years with 133 cases. *Neurol Res* 2014;36(02):157–163
- 37 Frota NA, Barbosa ER, Porto CS, et al. Cognitive impairment and magnetic resonance imaging correlations in Wilson's disease. *Acta Neurol Scand* 2013;127(06):391–398
- 38 Cochen De Cock V, Lacombe S, Woimant F, Poujois A. Sleep disorders in Wilson's disease. *Sleep Med* 2021;83:299–303
- 39 Tribl GG, Bor-Seng-Shu E, Trindade MC, Lucato LT, Teixeira MJ, Barbosa ER. Wilson's disease presenting as rapid eye movement sleep behavior disorder: a possible window to early treatment. *Arq Neuropsiquiatr* 2014;72(09):653–658
- 40 Kłysz B, Bembenek J, Skowrońska M, Członkowska A, Kurkowska-Jastrzębska I. Autonomic nervous system dysfunction in Wilson's disease - a systematic literature review. *Auton Neurosci* 2021;236:102890
- 41 Meenakshi-Sundaram S, Taly AB, Kamath V, Arunodaya GR, Rao S, Swamy HS. Autonomic dysfunction in Wilson's disease—a clinical and electrophysiological study. *Clin Auton Res* 2002;12(03):185–189
- 42 Chu EC, Chu NS, Huang CC. Autonomic involvement in Wilson's disease: a study of sympathetic skin response and RR interval variation. *J Neurol Sci* 1997;149(02):131–137
- 43 Roberts EA, Schilsky ML. Division of Gastroenterology and Nutrition, Hospital for Sick Children, Toronto, Ontario, Canada. A practice guideline on Wilson disease. *Hepatology* 2003;37(06):1475–1492
- 44 Quemeneur AS, Troceno JM, Ea HK, et al. Bone status and fractures in 85 adults with Wilson's disease. *Osteoporos Int* 2014;25(11):2573–2580
- 45 Shah R, Amador C, Tormanen K, et al. Systemic diseases and the cornea. *Exp Eye Res* 2021;204:108455
- 46 Jang HJ, Kim JM, Choi CY. Elemental analysis of sunflower cataract in Wilson's disease: a study using scanning transmission electron microscopy and energy dispersive spectroscopy. *Exp Eye Res* 2014;121:58–65

- 47 Mezaki T, Matsumoto S, Hamada C, et al. Decreased serum ceruloplasmin and copper levels in cervical dystonia. *Ann Neurol* 2001;49(01):138–139
- 48 Korman JD, Volenberg I, Balko J, et al; Pediatric and Adult Acute Liver Failure Study Groups. Screening for Wilson disease in acute liver failure: a comparison of currently available diagnostic tests. *Hepatology* 2008;48(04):1167–1174
- 49 Tu JB, Blackwell RQ. Studies on levels of penicillamine-induced cupriuresis in heterozygotes of Wilson's disease. *Metabolism* 1967;16(06):507–513
- 50 Mounajjed T, Oxentenko AS, Qureshi H, Smyrk TC. Revisiting the topic of histochemically detectable copper in various liver diseases with special focus on venous outflow impairment. *Am J Clin Pathol* 2013;139(01):79–86
- 51 EASL Clinical Practice Guidelines: Wilson's disease. *J Hepatol* 2012;56(03):671–685
- 52 Saroli Palumbo C, Schilsky ML. Clinical practice guidelines in Wilson disease. *Ann Transl Med* 2019;7(Suppl 2):S65
- 53 Ferenci P, Caca K, Loudianos G, et al. Diagnosis and phenotypic classification of Wilson disease. *Liver Int* 2003;23(03):139–142
- 54 Scheinberg IH, Jaffe ME, Sternlieb I. The use of trientine in preventing the effects of interrupting penicillamine therapy in Wilson's disease. *N Engl J Med* 1987;317(04):209–213
- 55 Boga S, Jain D, Schilsky ML. Trientine induced colitis during therapy for Wilson disease: a case report and review of the literature. *BMC Pharmacol Toxicol* 2015;16:30
- 56 Rodriguez-Castro KI, Hevia-Urrutia FJ, Sturniolo GC. Wilson's disease: a review of what we have learned. *World J Hepatol* 2015;7(29):2859–2870
- 57 Weiss KH, Schäfer M, Gotthardt DN, et al. Outcome and development of symptoms after orthotopic liver transplantation for Wilson disease. *Clin Transplant* 2013;27(06):914–922
- 58 Poujois A, Sobesky R, Meissner WG, et al. Liver transplantation as a rescue therapy for severe neurologic forms of Wilson disease. *Neurology* 2020;94(21):e2189–e2202
- 59 Allocca S, Ciano M, Ciardulli MC, et al. An α B-crystallin peptide rescues compartmentalization and trafficking response to Cu overload of ATP7B-H1069Q, the most frequent cause of Wilson disease in the Caucasian population. *Int J Mol Sci* 2018;19(07):1892
- 60 Murillo O, Luqui DM, Gazquez C, et al. Long-term metabolic correction of Wilson's disease in a murine model by gene therapy. *J Hepatol* 2016;64(02):419–426
- 61 Beinhardt S, Leiss W, Stättermayer AF, et al. Long-term outcomes of patients with Wilson disease in a large Austrian cohort. *Clin Gastroenterol Hepatol* 2014;12(04):683–689
- 62 Dzieżyc K, Karliński M, Litwin T, Członkowska A. Compliant treatment with anti-copper agents prevents clinically overt Wilson's disease in pre-symptomatic patients. *Eur J Neurol* 2014;21(02):332–337
- 63 Schilsky ML, Scheinberg IH, Sternlieb I. Prognosis of Wilsonian chronic active hepatitis. *Gastroenterology* 1991;100(03):762–767
- 64 Akil M, Schwartz JA, Dutchak D, Yuzbasiyan-Gurkan V, Brewer GJ. The psychiatric presentations of Wilson's disease. *J Neuropsychiatry Clin Neurosci* 1991;3(04):377–382