



Orthotopic Heart Transplant Recipient Presenting with Sudden Onset Homonymous Hemianopia

Abraham L. Chawnchhim¹ Neha Sharma¹ Chetna Goel¹ Charu Mahajan¹

¹Department of Neuroanaesthesiology and Critical Care, All India Institute of Medical Sciences, New Delhi, India

Address for correspondence Charu Mahajan, MD, DM, Department of Neuroanaesthesiology and Critical Care, Neurosciences Centre, All India Institute of Medical Sciences, New Delhi 110029, India (e-mail: charushrikul@gmail.com).

J Neuroanaesthesiol Crit Care 2023;10:212–214.

Abstract

Infectious complications are common among heart transplant recipients due to immune suppressive therapy mandatorily given to prevent organ rejection. We share our experience regarding an orthotopic heart transplant recipient who underwent craniotomy and evacuation of intracerebral abscess under general anesthesia in our operation theater. An orthotopic heart transplant recipient presented with headache, fever, and left-sided homonymous hemianopia. Noncontrast computed tomography (NCCT) of the head showed a right occipital space-occupying lesion suggestive of an abscess. Craniotomy and evacuation of abscess was successfully performed under general anesthesia. There are several concerns pertinent to orthotopic heart transplant recipients mainly due to denervated heart status and immune suppressive therapy, which poses perioperative challenge. We report successful anesthetic management of this case.

Keywords

- ▶ orthotopic heart transplant recipient
- ▶ cerebral abscess
- ▶ homonymous hemianopia
- ▶ craniotomy

Introduction

Approximately, 5,000 to 10,000 cardiac transplant surgeries are performed annually across the globe.¹ The average rate of heart transplantation in India was 0.2 per million from 2016 to 2018 and is expected to increase steadily as more hospitals are joining the transplant program.² Infectious complications are common among organ recipients, due to immune suppression therapy administered mandatorily to prevent transplant rejection.³ We report the case of an orthotopic heart transplant recipient who underwent craniotomy and evacuation of intracerebral abscess under general anesthesia. With an increasing number of successful heart transplant, it is likely that we will come across similar cases in the future. This makes it important for us to understand the related concerns. There are reports of fungal brain abscess in solid organ recipients posttransplantation,³ but anesthetic management of such a patient for emergency craniotomy has

not been discussed earlier. Written consent for publication of this report was obtained from the patient.

Case Report

A 52-year-old male patient, weighing 60 kg, having a history of orthotopic heart transplant 4 years back, presented with complaint of difficulty in reading for past 2 weeks followed by development of continuous dull right-sided headache and mild intermittent fever. He was on tab tacrolimus 0.5 mg and prednisolone 20 mg orally, twice daily. He suffered diabetes mellitus secondary to steroids, for which he was receiving metformin 500 mg orally, twice daily. His baseline vitals were within normal limits with a heart rate of 56 to 65 beats per minute. On neurological examination, he had left homonymous hemianopia, and noncontrast computed tomography (NCCT) of the head showed a space-occupying lesion suggestive of an abscess in right occipital lobe with

article published online
February 23, 2024

DOI <https://doi.org/10.1055/s-0043-1772682>.
ISSN 2348-0548.

© 2024. The Author(s).

This is an open access article published by Thieme under the terms of the Creative Commons Attribution License, permitting unrestricted use, distribution, and reproduction so long as the original work is properly cited. (<https://creativecommons.org/licenses/by/4.0/>)

Thieme Medical and Scientific Publishers Pvt. Ltd., A-12, 2nd Floor, Sector 2, Noida-201301 UP, India

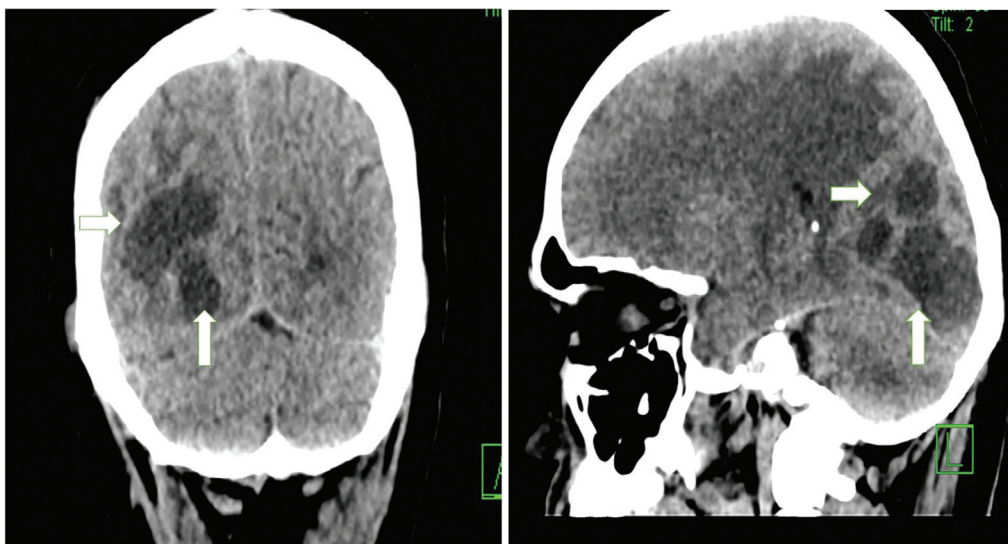


Fig. 1 Noncontrast computerized tomography (NCCT) of the head showing space occupying lesion (white arrows) suggestive of abscess in the right occipital lobe.

surrounding cerebral edema (►Fig. 1). Routine blood investigations, electrocardiogram (ECG), and echocardiogram (ECHO) were within normal limits. He was started on intravenous mannitol (20%) and tab dexamethasone 4 mg twice a day for decreasing cerebral edema. Empirical treatment with intravenous liposomal amphotericin B 300 mg/day, tab voriconazole 300 mg twice a day, and tab cotrimoxazole 960 mg twice a day was initiated. Immunosuppressive and antidiabetic medications were continued and insulin had to be added to control the blood sugar level. He was planned for emergency craniotomy and evacuation of cerebral abscess. Preoperative anesthetic checkup included elaborate assessment of the patient including evaluation of graft function, side effects of medications used, risk of infection, control of diabetes, and assessment of other organs.

In the operation theater, in addition to the standard monitoring, arterial cannulation was done under local anesthesia for establishing invasive blood pressure recording. Drugs including isoprenaline (1:50,000) and adrenaline (1:50,000) were prepared beforehand. Transcutaneous pacing pads were placed on the chest anterolaterally in view of possible intraoperative bradycardia or asystole. After preloading with 200 mL of balanced salt solution, slow anesthetic induction was done using intravenous fentanyl 150 µg and propofol 100 mg followed by endotracheal intubation using injection rocuronium 50 mg. Ultrasound-guided right internal jugular vein cannulation was done for possible need for infusion of isoprenaline or other inotropes. Intraoperatively, partial pressure of arterial carbon dioxide was maintained at 33 to 35 mm Hg. Minimally invasive cardiac output (CO) monitoring was established using arterial pressure waveform analysis for facilitation of goal-directed fluid therapy. Anesthesia was maintained using oxygen, nitrous oxide, and sevoflurane along with fentanyl and cis-atracurium boluses. The patient was positioned prone for surgery. There was an episode of intraoperative bradycardia (drop from 84 to 45 beats/min; CO decreased from 5.1 to 3.5 L/min)

around an hour after start of surgery. Isoprenaline infusion at 0.05 µg/kg/min was started and titrated to target heart rate between 80 and 90 beats/min till the end of surgery. Total input/output was 2.0 L/550 mL with blood loss of around 200 mL. Blood glucose was maintained below 180 mg/dL with insulin infusion. Surgery lasted for 3 hours and after neuromuscular blockade reversal with neostigmine and atropine, the trachea was extubated and the patient was shifted to neurosurgical intensive care unit (ICU) for close monitoring and further management. The patient had an uneventful recovery and after a day of ICU stay, was shifted to the ward and discharged 2 weeks later. The pus potassium hydroxide mount showed fungal hyphae (aspergillosis), but fungal culture was sterile.

Discussion

Fungal infection is common among heart transplant recipients, and the brain is commonly involved due to a hematogenous spread.⁴ Incidence of complicated fungal infections increased during the recent COVID-19 pandemic resulting in increasing morbidity and mortality.⁵ Multiple abscess loculi are typical of a fungal abscess, while bacterial abscess is likely to have a single-site lesion. Inflammatory response and immune status of the patient largely determine the organ involved and the extent of involvement.⁶

Specific anesthetic concerns in this patient were mainly in view of the denervated heart's susceptibility to bradycardia unresponsive to atropine. Direct acting chronotropic agent like isoprenaline (pharmacological pacemaker) or electrical pacing can be needed intraoperatively.⁷ However, the transplanted hearts may acquire parasympathetic reinnervation following a long and variable period. During the surgery, low-dose isoprenaline infusion had to be administered to our patient to prevent further hemodynamic compromise, and possible sudden cardiac arrest. As the abscess was multiloculated, surgery was carried out in the prone position.

However, had the heart function been suboptimal, change in position to lateral would have been preferable. The physiological changes in a transplanted heart include functional valvular regurgitation, larger right and left atrial end-diastolic and end-systolic volumes, and larger right atrial pressure and higher resting heart rate.⁸ As the heart becomes preload dependent, a perioperative goal-directed fluid therapy can be quite helpful in these patients.⁷

There are no clear recommendations on the use of inhalational versus intravenous anesthesia in such postcardiac transplanted patients. We used nitrous oxide to avoid adverse hemodynamic effects of using a high dose of sevoflurane. Moreover, as preoperative ECHO and ECG were normal, there was no clear contraindication for nitrous oxide use. The patient was on mannitol in the preoperative period and we did not repeat it intraoperatively. Although mannitol can cause fluid overload and intensify or precipitate heart failure, our patient had normal heart function and was closely watched for signs of heart failure. These patients have impaired reflex responses including blunted tachycardia response to noxious stimuli, so adequate analgesia should be ensured perioperatively. The possibility of arrhythmias is high and management can be challenging.

Other concerns in our case included worsening of diabetes secondary to steroid administration for which perioperative titration of insulin infusion was done. All measures to decrease the risk of nosocomial infection were enforced perioperatively. Measures to prevent nosocomial infection by strict aseptic precautions during surgery and other invasive procedures were enforced and strict hand hygiene was maintained in this patient. At the time of neuromuscular blockade reversal, one should remain vigilant for neostigmine-induced bradycardia, and for this, concurrent administration of atropine may be preferred over glycopyrrolate. Sugammadex is devoid of direct cholinergic effects, making it a suitable option. However, in a retrospective analysis of 185 heart transplant recipient patients who underwent noncardiac operations, no significant differences in bradycardia and hypotension were observed in groups that received either a combination of neostigmine and antimuscarinic agents or sugammadex.⁹ The interaction of immunosuppressants and perioperative drugs also requires special mention. Tacrolimus can lower seizure threshold, accentuate hypertension and diabetes, and can affect renal function. Most of the anesthetic drugs do not have any known major interaction with tacrolimus, except for increase in blood level of benzodiazepines, which may require dose modification. There is no evidence that tacrolimus prolongs neuromuscular blockade; still we used

cisatracurium boluses for maintenance of anesthesia, and patient recovery was uneventful. Few antibiotics, antiarrhythmics, calcium channel blockers, nonsteroidal anti-inflammatory drugs, prokinetics, and antipsychotics can alter the tacrolimus blood level.¹⁰

Conclusion

Cases of fungal occipital abscess presenting with hemianopia in a post-heart transplant patient are rare. It requires understanding of physiological and pharmacological changes after heart transplantation, optimization of cardiac status, as well as cerebral hemodynamics during an emergency craniotomy. With an increasing number of successful heart transplantations, it is important for us, neuroanesthesiologists, to understand the related concerns.

Conflict of Interest

None declared.

References

- 1 Toyoda Y, Guy TS, Kashem A. Present status and future perspectives of heart transplantation. *Circ J* 2013;77(05):1097–1110
- 2 Shroff S, Mittal K, Navin S. Heart transplantation in India-looking back as we celebrate 25 years of the transplant law. *Indian J Thorac Cardiovasc Surg* 2020;36(Suppl 2):215–223
- 3 Esposito S, Renzulli A, Agozzino L, et al. Late complications of heart transplantation: an 11-year experience. *Heart Vessels* 1999;14(06):272–276
- 4 Lange N, Wantia N, Jörger AK, et al. Fungal brain infection-no longer a death sentence. *Neurosurg Rev* 2021;44(04):2239–2244
- 5 Khatri A, Chang KM, Berlinrut I, Wallach F. Mucormycosis after coronavirus disease 2019 infection in a heart transplant recipient: case report and review of literature. *J Mycol Med* 2021;31(02):101125
- 6 Gavito-Higuera J, Mullins CB, Ramos-Duran L, Olivas Chacon CI, Hakim N, Palacios E. Fungal infections of the central nervous system: a pictorial review. *J Clin Imaging Sci* 2016;6:24
- 7 Choudhury M. Post-cardiac transplant recipient: implications for anaesthesia. *Indian J Anaesth* 2017;61(09):768–774
- 8 Navas-Blanco JR, Modak RK. Perioperative care of heart transplant recipients undergoing non-cardiac surgery. *Ann Card Anaesth* 2021;24(02):140–148
- 9 Paredes S, Torres VH, Chaves-Cardona H, Matus M, Porter S, Renew JR. An appraisal of neostigmine versus sugammadex for neuromuscular blockade reversal in patients with a prior heart transplant. *Anaesthesiol Intensive Ther* 2023;55(01):46–51
- 10 Brusich KT, Acan I. Anesthetic considerations in transplant recipients for nontransplant surgery [Internet]. In: *Organ Donation and Transplantation: Current Status and Future Challenges*. InTech; 2018. Accessed July 20, 2023 at: <http://dx.doi.org/10.5772/intechopen.74329>