

ULNAR FASCIOCUTANEOUS FLAP FOR LOWER FOREARM DEFECTS

R.P. SINGH, A.K. SINGH AND P. TIWARI

SUMMARY

A case is reported in which ulnar fasciocutaneous flap was used to cover the volar wrist defect after the excision of an osteoclastoma of the lower end of radius.

(*Key Words* : Fascio-cutaneous flap, lower forearm defect.)

Various flaps used to cover exposed tendons/ bone over the lower forearm are either local or distant flaps. Local flaps are difficult to design due to paucity of skin. Hence multistaged distant flaps are often used. Elliot et al (1988) have used ulnar fasciocutaneous flap to cover exposed tendons. We have also used a similar flap for a defect of the lower forearm. The lower end of the radius and tendons were exposed following cryoexcision of a case having osteoclastoma of the left radius.

Case Report

R.K. a 37 years old male farmer, had osteoclastoma of the lower end of left radius. Cryoexcision was done. Subsequently, patient had skin necrosis and developed skin defect with exposed bone and tendons which required a flap cover (Fig. 1). The defect was covered by an ulnar fasciocutaneous flap. The donor defect was closed partly by V-Y advancement and partly by split skin grafting. There was no flap necrosis.

The flap is vascularised by two perforators which are the branches of the ulnar artery to the volar fascia of the forearm. The flap can survive on either of them, the distal one is constant and is situated 8 cm. proximal to the distal wrist crease.

The skin markings are as shown in Fig. 1. Skin incision is deepened upto the deep fascia and the skin is anchored to it. The incision is extended proximally almost upto the antecubital fossa and then a back cut is made towards the ulnar side. The flap is raised while preserving the ulnar perforators and corresponding venae comitantes. The ulnar artery is not ligated. The venous drainage is along the accompanying vessels.

Discussion

The skin defect of the volar aspect of the wrist is a challenging area for resurfacing (Fenton and Robert 1985, Mc Gregor 1987). Lovie et al (1984) have used a local ulnar artery forearm flap for the coverage of volar wrist defect. The perforators to the ulnar fasciocutaneous flap are clearly shown in Fig. 2. Lovie et al (1984), in their original description of the ulnar forearm free flap have also demonstrated these perforators. Ulnar fasciocutaneous flap does not depend upon the integrity of the plamar arches and its harvesting does not hamper the blood supply of the hand. A positive Allen test is not a contraindication for the use of this flap. Patient does not require immobilisation and the hand movements are less restricted when compared to distant flaps. By narrowing the base, the arc of rotation of the flap can be increased. The forearm skin gets denervated during elevation of the flap but protective sensations return with time. Lymphatic oedema of the flap is a theoretical possibility but it was not observed in our patient.

When skin availability in the proximal forearm does not allow primary V-Y closure comfortably, split skin grafting can be used to cover the remaining raw area Fig. 3. The fleshy bellies of the flexor muscles provide a good graft bed. This flap provides good skin for the volar aspect of the wrist Fig. 4.

Conclusions

A ulnar fascio-cutaneous flap has been successfully utilised for covering a defect on the volar aspect of the wrist.

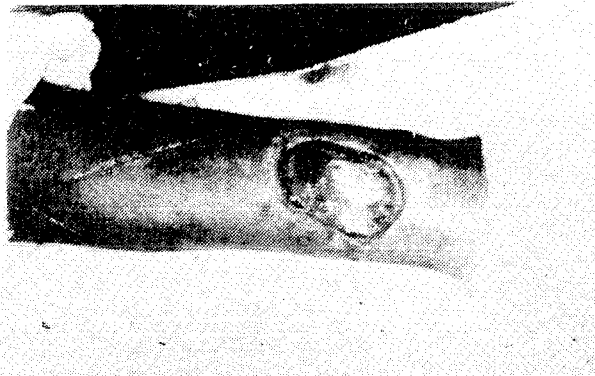


Fig. 1. Showing the defect over the volar aspect of left wrist and marking of the flap.

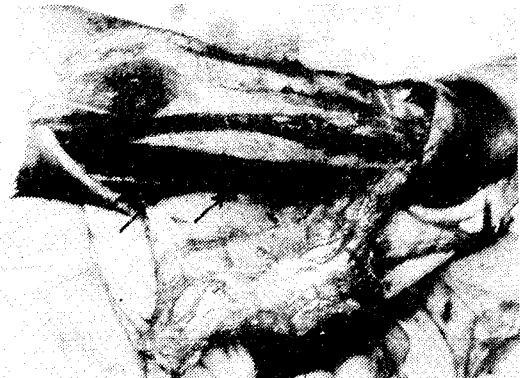

Fig. 2. Showing the elevation of the flap and position of the two perforators (arrows).

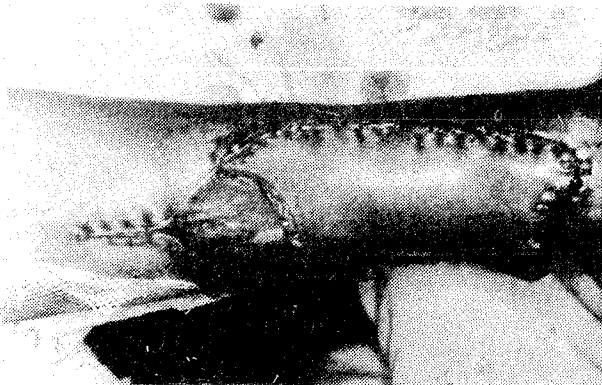


Fig. 3. Flap transposed over the defect, proximal closure by V-Y advancement and remaining raw area skin grafted.

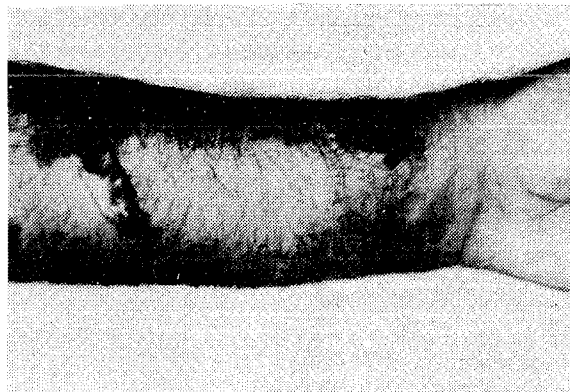


Fig. 4. Postoperative result after 1 year. The size of the grafted area has reduced considerably.

REFERENCES

1. ELLIOT, D. AND BAINBRIDGE, L.C. : Ulnar fasciocutaneous flap of the Wrist. *J. of Hand Surg.* 1988 ; 138 : 311-312.
2. ELLIOT, D., BARDSLEY, A.F., BATCHELOR, A.G. AND SOUTAR, D.S. : Direct closure of the radial forearm flap donor defect. *Brit. J. Plastic Surgery*, 1988 ; 41 : 358-360.
3. FENTON, O.M. AND ROBERT, S.O. : Improving the donor site of the radial forearm flap. *Brit. J. Plastic Surgery*. 1985; 38 : 504-505.
4. LOVIE, M.J., DUNCAN, G.M. AND GLASSON, D.W. : The ulnar artery forearm free flap. *British J. Plastic Surgery*, 1984; 37 : 486-492.
5. MC GREGOR, A.D. : The free radial forearm flap. The management of secondary defect. *Brit. J. Plas. Surgery*, 1987; 40 : 83-85.

Request for Reprints

DR. A.K. SINGH, M.S., M.Ch., *Lecturer*, P.G. Deptt. of Plastic Surgery, King George's Medical College, Lucknow-226003.