



Papillon Flap—Design Modification of ALT Flap for Circumferential Laryngopharyngeal Defect

Sukhdeep Singh¹ Vimalendu Brajesh¹ Aditya Aggarwal¹

¹Department of Plastic, Aesthetic and Reconstructive Surgery, Medanta- The Medicity, Gurgaon, Haryana, India

Indian J Plast Surg 2023;56:457–460.

Address for correspondence Sukhdeep Singh, MBBS, MS, MCh, Department of Plastic, Aesthetic and Reconstructive Surgery, Medanta- The Medicity, Gurgaon 122001, Haryana, India (e-mail: docsukhdeep.singh@gmail.com).

Abstract

Keywords

- ▶ pharyngeal reconstruction
- ▶ tubed anterolateral thigh (ALT) free flap
- ▶ papillon flap

Anterolateral thigh (ALT) free flap is a commonly used flap for reconstruction of circumferential laryngopharyngeal defects. The flap is harvested as an ellipse and tubed along its length. We would like to present a design modification of the ALT flap where the tubing of the flap is done along the width of the flap. This design has advantages as it allows for a two-layered closure without the harvest of additional tissue and provides skin for neck coverage also. After inset, the flap resembles a butterfly, hence the name “Papillon Flap.”

Introduction

The primary objectives of reconstruction in cases involving a circumferential defect after total laryngopharyngectomy are to restore the continuity of the digestive tract and facilitate speech rehabilitation. Many of these patients have received prior radiotherapy and require tissues to cover their neck as well. Various types of flaps, such as the free radial artery forearm flap, anterolateral thigh (ALT) free flap, free jejunal flap, and pedicled pectoralis major muscle flap, are employed for such reconstructions.¹ Among these, the ALT flap is the most widely used.¹ The flap is harvested in an elliptical shape and fashioned into a tube along its length, enabling the creation of a pharyngeal conduit. Here, we present a case where a modified design of the ALT flap was employed for circumferential pharyngeal reconstruction and neck coverage. This modification, first described by Hayden et al,² offers advantages such as simplified monitoring, a two-layered closure, and provision of skin for neck coverage.

Case Report

A 45-year-old male with no known underlying health conditions presented with a recurrent laryngeal carcinoma. The patient had a history of prior radiotherapy for a laryngeal

lesion. The treatment plan involved performing a total laryngopharyngectomy followed by reconstruction using a tubed free ALT flap. After the resection, the dimensions of the required conduit were determined: a length of 7 cm, a pharyngeal end diameter of 3.2 cm, and an esophageal end diameter of 2.5 cm (▶ Fig. 1). The ALT flap was harvested in an elliptical shape based on a single perforator, measuring approximately 15 cm in length and 7 cm in width, as depicted in ▶ Fig. 2. The central portion of the flap was intended for tubularization, while the 2 cm wide strips on both sides were to be de-epithelialized. The triangular portions at the ends of the ellipse were reserved for providing skin coverage to the neck area (▶ Fig. 2). The harvested flap was positioned horizontally on the prevertebral fascia, with the skin facing forward, ensuring that the perforator did not align with the vertebral column's midpoint to avoid compression. Suturing began at the oropharyngeal margins, starting from the posterior region and moving anteriorly, using polyglactin 3–0 sutures with the knots directed toward the created lumen. Similarly, suturing of the inferior margin of the flap was performed on the esophageal margins, progressing from posterior to anterior until the two edges of the flap met (▶ Fig. 3). A 2 cm area of the flap on each side of the meeting edges was de-epithelialized, and tubularization was completed by suturing the inner edges of the de-epithelialized

article published online
September 20, 2023

DOI <https://doi.org/10.1055/s-0043-1774383>.
ISSN 0970-0358.

© 2023. Association of Plastic Surgeons of India. All rights reserved. This is an open access article published by Thieme under the terms of the Creative Commons Attribution-NonDerivative-NonCommercial-License, permitting copying and reproduction so long as the original work is given appropriate credit. Contents may not be used for commercial purposes, or adapted, remixed, transformed or built upon. (<https://creativecommons.org/licenses/by-nc-nd/4.0/>)

Thieme Medical and Scientific Publishers Pvt. Ltd., A-12, 2nd Floor, Sector 2, Noida-201301 UP, India

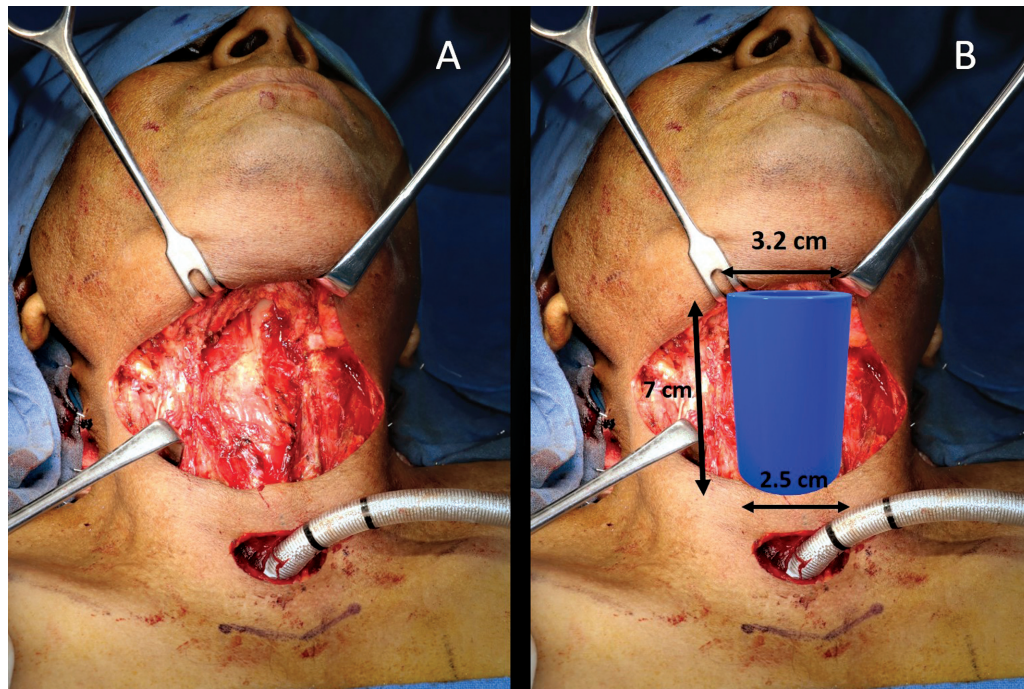


Fig. 1 (A) The defect after resection of the specimen. (B) The planning for the reconstruction of the defect using a tubed flap.

section with the knots directed toward the lumen of the tube (→ **Fig. 4**). The de-epithelialized sections were then sutured using a few interrupted sutures to create a second reinforcing

layer. The two ends of the elliptical skin paddle now resembled triangular wings, facilitating tension-free closure of the neck (→ **Fig. 5**). Postoperatively, the standard protocol for flap reconstruction in the head and neck region was followed. Monitoring of the flap was uncomplicated since it was clearly visible. The patient received Ryles tube feeding in the immediate postoperative period. On the 10th postoperative day, a Gastrografin study was performed, revealing no leakage from the reconstructed tube. The patient's diet progressed gradually from liquids to a normal diet. One year follow-up demonstrated successful speech rehabilitation with the use of a laryngeal prosthesis, and the patient did not encounter any complications (→ **Fig. 6**; → **Supplementary Video 1** [online only]).

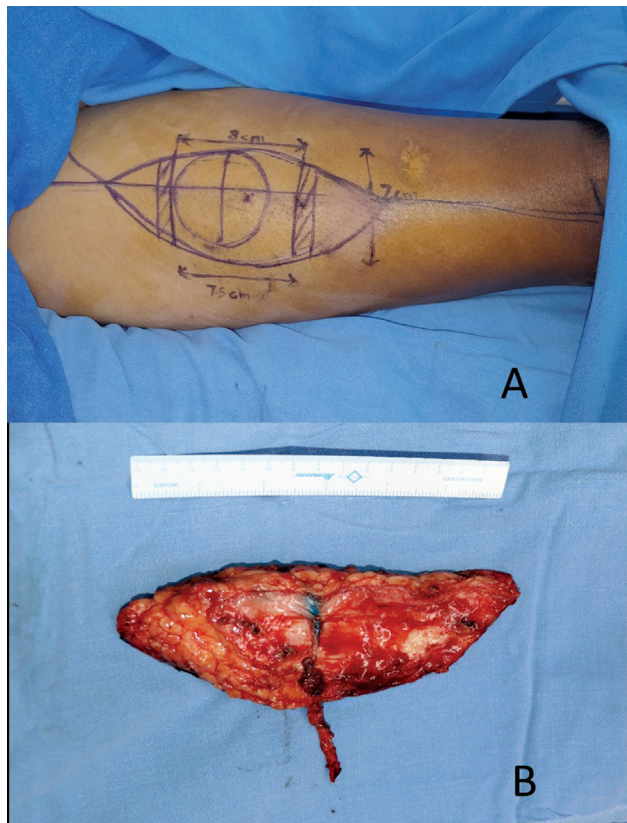


Fig. 2 (A) Markings of the anterolateral thigh flap showing the plan of reconstruction. (B) The harvested flap based on a single perforator.

Supplementary Video 1

Video of the patient speaking with his laryngeal prosthesis at 1-year follow-up. Online content including video sequences viewable at: <https://www.thieme-connect.com/products/ejournals/html/10.1055/s-0043-1774383>.

Discussion

The selection of a flap for reconstructing a complete laryngopharyngectomy defect relies on factors such as the defect's size, the surgeon's preference, and the patient's condition. Among the available choices, the tubed ALT free flap is frequently utilized for these types of reconstructions. In the conventional approach, the ALT flap is tubularized along the length of the elliptical skin paddle that has been harvested. However, this

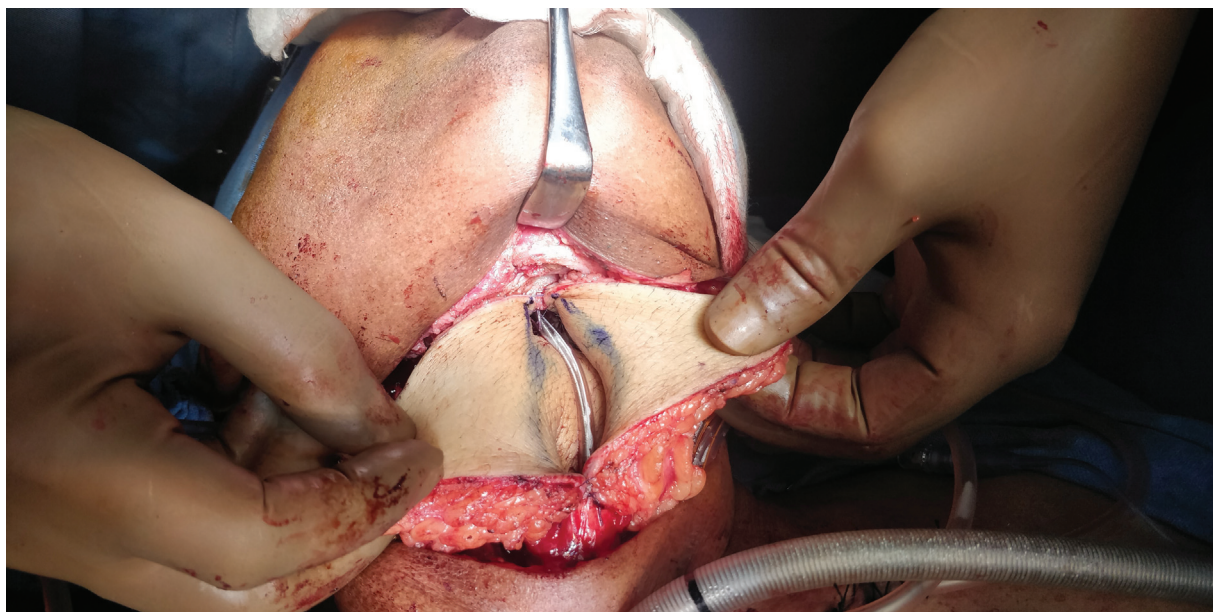


Fig. 3 Insetting of the flap after suturing at both the upper and lower ends.

approach makes postoperative monitoring challenging, as the flap is usually buried after closure of the neck skin over the insetted flap although design modifications have been described for this.^{3,4} In cases where the neck skin is insufficient, additional skin paddles on different perforators or additional tissues like muscle may need to be harvested, or a separate flap may be required. Anastomotic leaks are a known complication of such a reconstruction.⁵ The neck spaces are generally contaminated by the time an anastomotic leak is diagnosed. If any surgical intervention is needed, it will necessitate opening up the neck under general anesthesia.

To address these challenges, Hayden et al proposed a modification of the ALT flap design in 2012. In this modified design, the flap is tubed along the horizontal dimension of

the elliptical skin paddle.² This design allows for a two-layered closure of the reconstructed tube. The triangular ends of the elliptical skin paddle are utilized to compensate for the deficiency of neck skin. The final appearance of the inset resembles a butterfly, leading to the name “Papillon Flap” for this design. The visibility of the ends of the skin paddle makes monitoring of the flap easier. A two-layered

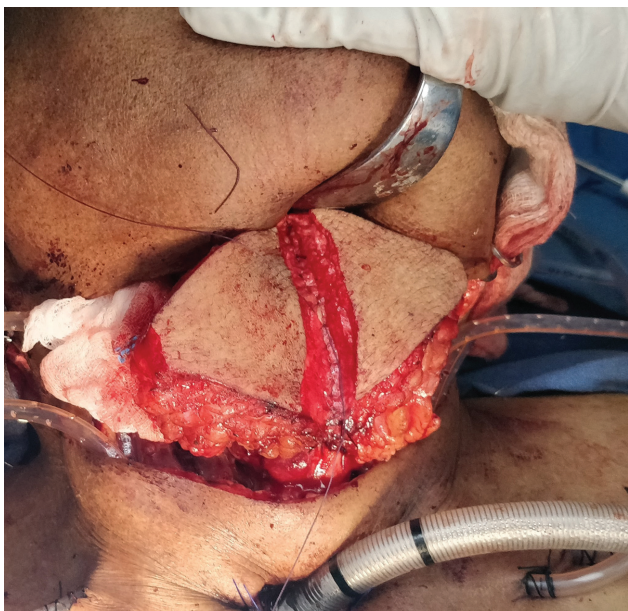


Fig. 4 Flap after completion of tubularization.

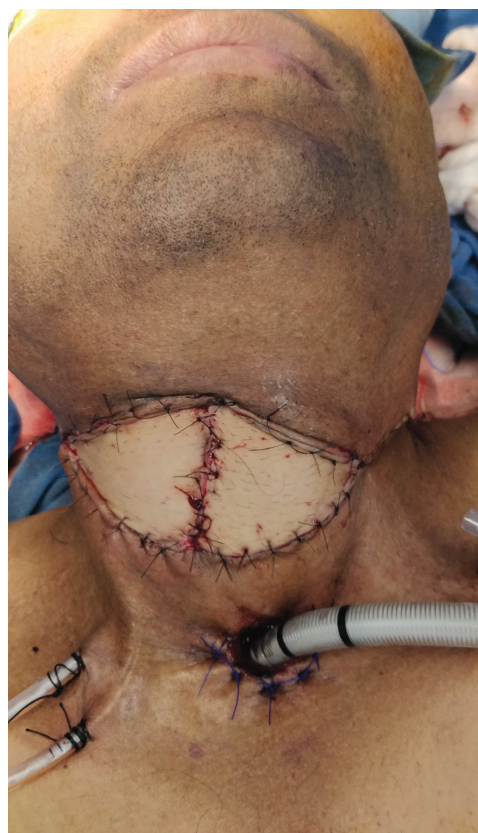

Fig. 5 Flap after suturing of second layer and final inset.

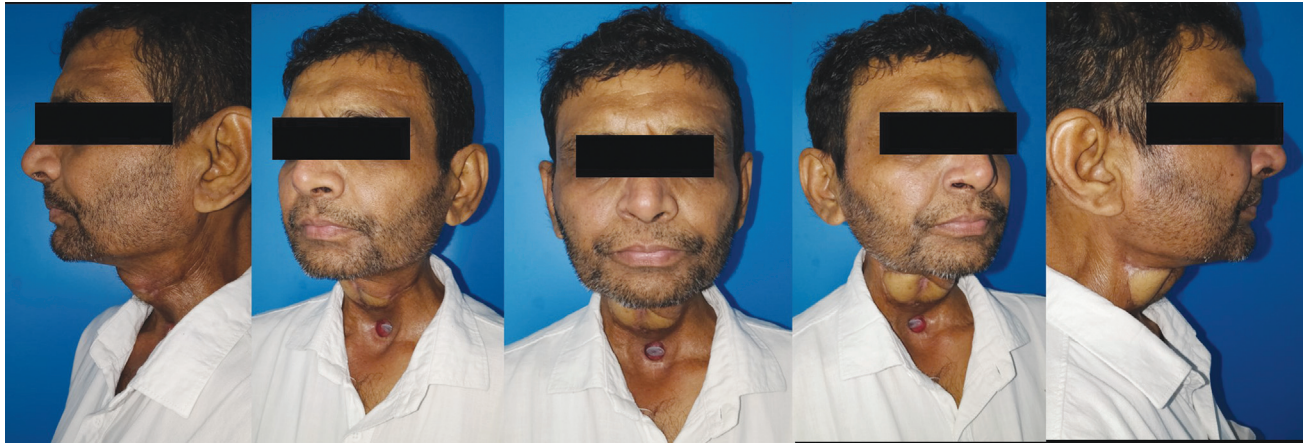

Fig. 6 Postoperative pictures of the patient at approximately 6 months.

closure helps reduce the risk of an anastomotic leak. Any leak, especially along the length of the tube, does not contaminate the neck and can be addressed on an outpatient basis. Ghazali et al published a retrospective case series in 2016, involving eight cases where this flap design was used, and none of the patients developed chronic fistulas.⁶ All patients were able to tolerate oral feeds, although one patient experienced a stricture. One disadvantage of this design is that closure of the primary donor site may be challenging if the required length of the tube exceeds 7 to 8 cm.

Conclusion

The papillon flap design offers many advantages over the traditional ALT flap design for total laryngopharyngectomy defects. The published literature about this modification, although scarce, attests to these benefits. Larger studies are, however, needed to validate these findings.

Conflict of Interest

This research has been presented as a Video Presentation in the Dr. C. R. Sudarajan Video Workshop at APSICON 2022 at Amritsar.

References

- 1 Patel RS, Goldstein DP, Brown D, Irish J, Gullane PJ, Gilbert RW. Circumferential pharyngeal reconstruction: history, critical analysis of techniques, and current therapeutic recommendations. *Head Neck* 2010;32(01):109–120
- 2 Hayden Richard E, Patel Andrew, Mullin D, Hinni M, Kim N. The 'papillon' flap for pharyngoesophageal reconstruction: a new technique. Poster presented at the 8th International Conference on Head and Neck Cancer. July 21–25, 2012; Metro Toronto Convention Centre Toronto, ON, Canada
- 3 Kadam D, Gatty RR. Monitoring buried flap in pharyngeal defect reconstruction. *Indian J Plast Surg* 2023;56(01):94–96
- 4 Hsu S-Y, Hausien O, Liao TY, Cheng HT. A simple technical modification for the creation of an external monitoring skin paddle for tubed ALT flap reconstruction after circumferential hypopharyngeal resection. *Plast Reconstr Surg Glob Open* 2017;5(05):e1344
- 5 Balasubramanian D, Subramaniam N, Rathod P, et al. Outcomes following pharyngeal reconstruction in total laryngectomy - institutional experience and review of literature. *Indian J Plast Surg* 2018;51(02):190–195
- 6 Ghazali N, Hanna TC, Dyalram D, Lubek JE. The value of the "Papillon" anterolateral thigh flap for total pharyngolaryngectomy reconstruction: a retrospective case series. *J Oral Maxillofac Surg* 2016;74(02):406–414