



# Histological Compatibility in Distal Neurotizations: A Systematic Review

Cristina Schmitt Cavalheiro<sup>1,2</sup> João Carlos Nakamoto<sup>1</sup> Teng Hsiang Wei<sup>2</sup> Luiz Sorrenti<sup>1</sup>  
Erick Yoshio Wataya<sup>1</sup>

<sup>1</sup> Department of Hand, Wrist and Microsurgery, Instituto Vita, São Paulo, SP, Brazil

<sup>2</sup> Institute of Orthopedic and Traumatology, Faculdade de Medicina, Universidade de São Paulo, São Paulo, SP, Brazil

Address for correspondence Cristina Schmitt Cavalheiro, MD, Praça Roberto Gomes Pedrosa, Portão 1 - Morumbi, São Paulo - SP, 05653-070, Brazil (e-mail: cristinaschmitt1@gmail.com).

Indian J Plast Surg 2023;56:405–412.

## Abstract

Considering the importance of defining the minimum number of axons between recipient and donor branches, that is, the definition of histological compatibility in distal neurotizations for the success of the procedure and the surgeon's freedom to choose individualized strategies for each patient, this systematic review was conducted to find out the most recent studies on the subject. The objective of this systematic review was to determine the importance of the number of axons and the relationship between axon counts in the donor and recipient nerves in the success of nerve transfer. A literature review was performed on five international databases: Web of Science, Scopus, Wiley (Cochrane Database), Embase, and PubMed. The Preferred Reporting Items for Systematic Reviews and Meta-Analyses (PRISMA) guidelines were followed (2020 version), a guide designed to guide the elaboration of systematic literature reviews. One hundred and fifty-seven studies were found, and 23 were selected based on the eligibility criteria. The articles presented were conclusive in determining the importance of the number of axons in the success of nerve transfer. Still, the relationship between the number of axons in the donor and recipient nerves seems more relevant in the success of transfers and is not always explored by the authors. The review of the articles has provided compelling evidence that the number of axons is a critical determinant of the success of nerve transfer procedures. However, the relationship between the number of axons in the donor nerve and that in the recipient nerve appears to be even more crucial for successful transfers, a factor that is not always adequately explored by authors in the existing literature.

**Level of evidence:** Level IV, therapeutic study

## Keywords

- ▶ axon count
- ▶ nerve transfer
- ▶ systematic review
- ▶ donor and recipient nerve.

article published online  
September 25, 2023

DOI <https://doi.org/10.1055/s-0043-1774385>.  
ISSN 0970-0358.

© 2023. Association of Plastic Surgeons of India. All rights reserved. This is an open access article published by Thieme under the terms of the Creative Commons Attribution-NonDerivative-NonCommercial-License, permitting copying and reproduction so long as the original work is given appropriate credit. Contents may not be used for commercial purposes, or adapted, remixed, transformed or built upon. (<https://creativecommons.org/licenses/by-nc-nd/4.0/>)  
Thieme Medical and Scientific Publishers Pvt. Ltd., A-12, 2nd Floor, Sector 2, Noida-201301 UP, India

## Introduction

Many important parameters are used in planning nerve transfers, such as location, number of branches, nerve transfer of synergistic muscles, and axon count of the donor and recipient nerves.<sup>1,2</sup> These parameters are directly related to the success of a neurotization procedure, which depends fundamentally on three conditions: (1) the available donor nerve must be able to reach the recipient nerve without strain to ensure direct coaptation, allowing a short distance of reinnervation and early motor recovery; (2) transferring the nerve branch from a donor's muscle should not result in loss of function—minimizing morbidity typically requires that the donor's muscle be losable or that a single muscle branch with multiple primary nerve branches is used as a donor; and (3) donor nerves must have enough axons to reinnervate the recipient nerves properly.

Nerve transfer surgery has revolutionized the management of traumatic lesions to the brachial plexus. However, the optimal ratio of axons between donor and recipient nerves has not yet been precisely elucidated,<sup>3</sup> although it is a crucial criterion, particularly in challenging cases where donor nerve options are often limited.<sup>4</sup>

Axon counting, knowledge of the location, and the number of primary nerve branches can help surgeons create unique distal nerve transfers to meet each patient's needs.<sup>1</sup>

Outgrowth of collateral sprouts from both afferent and motor axons is a natural process that arises during the development of and regeneration in the peripheral nervous system. When a nerve is injured, the proximal stump of damaged axons sends out numerous sprouts to reach endoneurial tubes in the distal nerve stump. In this process, some sprouts remain viable, while others may go astray, eventually being eliminated. This means that the greater the number of nerve fibers and growth sprouts, the greater the chance they occupy the distal nerve tubes and reach the target organ, favoring greater efficacy in the reconstructive procedure.<sup>4</sup>

Counts are obtained from various sources and performed in different methods such as manual quantitative histomorphometry, chemical counting, and imaging software. Due to the importance of axon counting for the success of nerve transfer procedures and considering the relatively small number of studies on human material, Costa et al presented a review involving several research groups active in the subject. The main objective was to make comparisons aiming at a protocol to reduce the variability of results. Preferred methods were discussed, and different alternatives and methods that could be used indifferently by the groups involved were sought according to their experience and availability of resources.<sup>5</sup>

The evaluation of the potential for relative correspondence between donor and recipient nerves may point to maximum reinnervation with minimal chances of morbidity at the donor site.

Considering the importance of the minimum number of axons between recipient and donor branches, that is, the definition of histological compatibility in distal neurotizations so the procedure succeeds and the surgeon has the

freedom to choose individualized strategies for each patient, this systematic literature review was performed, aiming to find out the most recent studies on the subject.

The research question and purpose of this review are to investigate the significance of the number of axons and the relationship between axon counts of the donor and recipient nerves in the success of nerve transfer surgeries. The aim is to find out the most recent studies on this topic and determine the optimal axon ratio for effective neurotization, allowing surgeons to tailor individualized strategies for each patient and ensure proper histological compatibility between the nerves involved. By addressing these factors, the study aims to enhance the outcomes of nerve transfer procedures, particularly in challenging cases with limited donor nerve options, and ultimately improve the management of traumatic lesions to the brachial plexus.

## Methods

### Databases and Literature Search

The Preferred Reporting Items for Systematic Reviews and Meta-Analyses (PRISMA) guidelines were followed (2020 version), a guide designed to guide the elaboration of systematic literature reviews.<sup>6</sup>

The literature review was performed on five international databases: Web of Science, Scopus, Wiley (Cochrane Database), Embase, and PubMed. The search period was selected to cover as many studies as possible, considering the relatively small number of articles on the subject. Thus, the research period was from 1900 to December 2022, using the longest time interval available in each database.

The keywords were combinations of the terms histology (all fields) and nerve (all fields) and nerve transfer (all fields) and axon count. The research was not limited to any language or study design.

### Articles Selection

The studies included in the review were selected according to the following eligibility criteria: articles involving the number of axons, whether they are only by anatomical and histological description or associated with a specific nerve transfer. In addition, these studies were grouped into two categories: cadaver studies that performed axon counts associated or not associated with the performance of the nerve transfer procedure and *in vivo* studies that performed the transfers and axon count. The articles selected were classified in scientific evidence levels between I and III; therefore, all the articles selected presented high-quality information guaranteeing that the present review is also of high level of evidence.<sup>7</sup>

Studies that made only anatomical descriptions of nerve transfers without axon count and those that contained incomplete data or insufficient information related to the review were excluded.

Two investigators independently reviewed the search results to select eligible studies using the preestablished inclusion and exclusion criteria. Any disagreements on the inclusion or exclusion of the study were solved by

**Table 1** Total articles found and selected from searches considering duplicates

Database	Total articles	
	Found	Selected
Web of Science	90	6
Scopus	28	9
Wiley	19	6
Embase	7	5
PubMed	13	6
Subtotal	157	32
Duplicates	10	-
Selected	-	22

discussion among the investigators until consensus was reached.

### Results

A summary of the quantitative results obtained in the literature search is shown in ► **Table 1**. In all, 157 studies were found, and 22 were selected based on the eligibility criteria.

These articles were organized into two groups. The first group included articles involving the anatomical description, including axon count in cadavers (18 studies). The second group included articles contemplating nerve transfer, with anatomical description and axon count in vivo (4 studies). A literature review on standardization was also included in the first group.

► **Fig. 1** illustrates the search and filtering processes associated with the literature search and article selection.

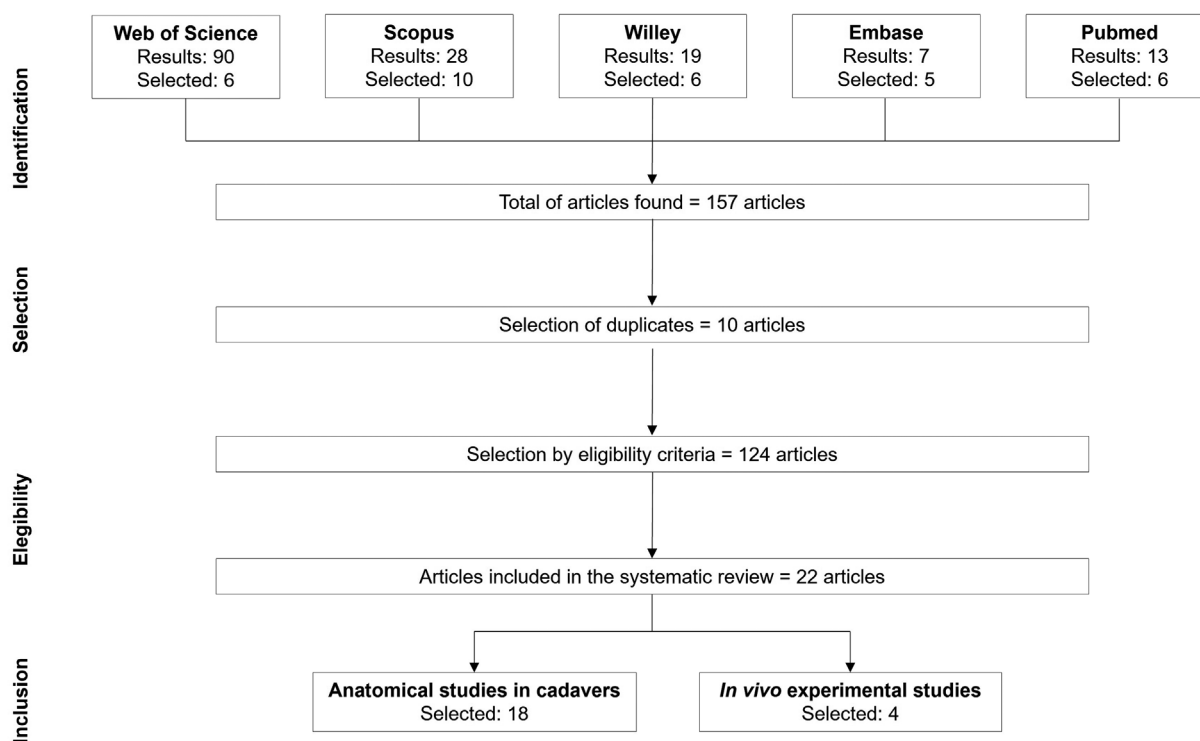
### Discussion

#### Anatomical Studies in Cadavers

Studies involving axon counts are performed to assess compatibility between the donor and recipient nerves. The material of the study is usually obtained from cadavers and subjected to microscopic analysis on slides in which it is fixed and dyed, usually applied in tissue analysis. The details involved in these studies are demonstrated in ► **Supplementary Material** (available in online version only).

The counting methods involve manual histomorphometric procedures<sup>1</sup> using photographs and assisted by free computer programs such as ImageJ or Fiji<sup>8,9</sup> or semiautomated software such as Bioquant Osteo,<sup>2,3,10</sup> in addition to electron transmission microscopy data for calculations of areas and sheath thicknesses with greater accuracy.<sup>11</sup> Results are subjected to statistical analysis using analysis of variance (ANOVA) or the Shapiro–Wilk test in commercial programs. Details of the procedures used in the articles selected for this review are demonstrated in ► **Table 1**. Only 8 of these articles present the axon count, while another 10 present axons in the donor nerve in relation to the recipient.

The optimal proportions of axons in the donor and recipient nerves are also relevant to the procedure's success, depending on the lesion to be treated. In this study, a count in the donor-to-recipient axon ratio greater than 0.7:1 was proposed as being ideal for restoring elbow flexion through



**Fig. 1** Flowchart depicting the literature search and selection of articles.

transfers to the musculocutaneous nerve according to the study by Schreiber et al,<sup>3</sup> based on results obtained in transfers of the following donor nerves: medial pectoral, accessory spinal, intercostal, thoracodorsal, ulnar, and median fascicular.<sup>3</sup>

When nerve transfer is not possible due to the time of lesion or inadequate donors in complete lesions, muscle transfer from the gracilis remains an option to restore elbow flexion. In these cases, the most commonly used donors are free muscle transfer from the gracilis, intercostal nerves, and accessory spinal cord. In the spinal nerve accessory, three and two intercostal nerves would all be sufficient for nerve transfer to the gracilis with donor-to-recipient ratios of 1.7:1, 1.3:1, and 0.9:1, respectively.<sup>8</sup>

Frank et al investigated nerve coaptations between the anterior interosseous nerve and the thenar branch of the median nerve in 15 fresh frozen specimens of the upper limbs. The axonic ratio between the anterior interosseous nerve and the thenar branch was 1:4.2, 25% below the threshold of successful donor-recipient rates. Therefore, it was impossible to conclude the feasibility of this nerve transfer option.<sup>12</sup>

The evaluation by Khair et al, based on axon counts involving the anatomical feasibility of transferring multiple branches of the radial nerve that supply the medial, lateral, and sometimes the long head triceps branches to the axillary nerve destined for the deltoid and teres minor branches, proved to be feasible.<sup>2</sup>

Cheah et al studied the neuromuscular anatomy of the upper limb for reconstructive surgery, and the primary nerve branches in the arm muscles presented a higher mean axon count than those in the forearm.<sup>1</sup>

In the case of sensory reanimation of fingers and thumbs, Schenck et al evaluated the transfer of the superficial branch of the radial nerve to the median and ulnar nerve, based on measures of proportions of axon quantity, fascicular area, and axon density between the donor and recipient nerves. The results indicate success in the proposed transfer at the wrist level.<sup>13</sup>

The proximal stump of the extratemporal facial nerve trunk was evaluated as a recipient for coaptation after characterization in relation to the axonal loads, morphology, and morbidity of different donor nerves. However, after the axon count, no nerve donor corresponded to the axonal load or the fascicle number of the extratemporal facial nerve main trunk. However, the masseteric nerve can be coaptated for neurotizations of facial muscles.<sup>6</sup> Still, in long-term facial paralysis, the possibility of using the posterior auricular nerve to improve cross-face nerve grafting technique results was evaluated, revealing that the posterior auricular nerve is a suitable donor candidate.<sup>11</sup>

The axon count allowed Mohan et al to conclude that the secondary intercostal nerves present adequate characteristics to be used as a recipient for coaptation of sensory nerves, considering the reinnervation of autologous flaps in breast reconstructions.<sup>9</sup>

Similarly, Colonna et al evaluated the potentiality of using the first and second lumbrical nerves as donors of nerve

fibers for the deep motor branch of ulnar nerve, aiming to avoid intrinsic atrophy in high ulnar nerve lesions. The transfer of the first lumbrical nerve to the deep motor branch of the ulnar nerve was considered adequate because the axon ratio was 1:1.86 in the distal portion of the opponens tunnel and 1:1.67 in the terminal branch.<sup>14</sup>

The transfer of the accessory spinal nerve to the suprascapular nerve in the posterior approach technique was evaluated by Pruksakorn et al as an alternative to the anterior approach as it leads to satisfactory results in cases of suprascapular double crush lesion. Anatomical and histomorphometric studies revealed that brachial plexus reconstructive surgery by transfer of the accessory spinal nerve to the suprascapular nerve in the posterior approach is satisfactory.<sup>15</sup>

Sensory recovery of the median nerve (common digital nerve) using transfer of the dorsal cutaneous branch of the ulnar nerve was evaluated by Luo et al based on the anatomical and histological studies in human specimens. Nerve transfer was simulated between the dorsal cutaneous branches of the ulnar and median nerves (common digital nerve), combining two or four branches of the ulnar nerve due to its smaller thickness than the median nerve (common digital nerve).<sup>16</sup>

The ulnar nerve has been the subject of several transfer proposals since the lesions to this nerve lead to severe motor consequences due to loss of intrinsic muscle function. In an attempt to promote the restoration of the intrinsic muscle function of the hand, Namazi and Haji Vandí performed a histological study in cadavers evaluating the transfer of the radial nerve from the extensor digiti minimi and extensor carpi ulnaris to the deep branches of ulnar nerve and recurrent branch of the median nerve at the wrist level. However, they found an incomplete recovery taking into account the number of axons found in the study, which revealed that summed, the nerve branches to the extensor digiti minimi and extensor carpi ulnaris present only 37 and 42% of the number of axons found in the deep branch of the ulnar nerve and recurrent branch of the median nerve, respectively, suggesting that another donor with a higher axon count should be used for better results.<sup>17</sup> In turn, a similar study also performed by Namazi and Haji Vandí revealed a favorable axon count for transferring nerve branches from the supinator to the motor branches of the ulnar nerve through a bridge using the anterior interosseous nerve in situ.<sup>18</sup>

To preserve the ulnar nerve, Hong et al proposed an alternative contralateral C7 nerve transfer to repair the avulsed C7 nerve root in which only the dorsal and superficial branches of the ulnar nerve on the paralyzed side were collected for grafting into the collateral C7 nerve on the opposite side, using the medial cutaneous antebrachial nerve as a bridge between donors and recipients. According to this proposal, the collateral C7 nerve could be transferred to the median nerve and to the deep branch of the ulnar nerve with the advantage of preserving the potential recovery of the deep branch of the ulnar nerve. The study was limited to an anatomical investigation and required clinical procedures for a complete evaluation.<sup>19</sup>

Saltzman et al studied the hypothesis that the levator scapulae motor nerve to the suprascapular nerve or long thoracic nerve could be used in nerve transfer in brachial plexus lesions, with the appropriate coaptation tension and axon count. They found the levator scapulae motor nerve to be a potential donor for direct transfer to the suprascapular nerve and the long thoracic nerve.<sup>20</sup>

Nerve transfer is also a valid surgical procedure for restoring lower limb function after lumbosacral plexus nerve root avulsion, which was investigated by Gang et al. In conclusion, it was pointed out that both obturator and genitofemoral nerves are suitable candidates to repair lumbosacral plexus nerve root avulsion.<sup>21</sup>

Domeshek et al presented a new treatment for corneal denervation based on the transfer of healthy donor nerves to the affected limb. Anatomical dissections could determine the distance between the supraorbital and supratrochlear nerves, observing more myelinated axons in the studied nerves more proximal to the orbital edge.<sup>22</sup>

Comparison between the results obtained in these studies is not a simple task once different protocols are used, as pointed out by Costa et al<sup>5</sup> and presented in **Supplementary Material** (available in the online version only), and the different branches of the nerves are used. Examples of these differences in similar samples can be seen for biceps and brachialis branches of the musculocutaneous nerve.<sup>1,3</sup> On the other hand, very close results were found for the spinal nerve accessory.<sup>10,15,20</sup>

**In Vivo Experimental Studies**

Treating high-grade nerve lesions in the upper limbs continues to be a surgical challenge. Several studies have been developed based on axon counts and the execution of procedures to evaluate the efficacy of nerve transfer to restore motor functions of the upper limbs. Some of these contributions, whose authors applied this knowledge in clinical practice, are reviewed in this section based on the eligibility criteria established in the “Methods” section. The experimental details involved in these studies are demonstrated in **Table 2**.

Nerve transfer procedures were used to recover finger movements impaired by the lesions to the cervical spinal cord. Sananpanich et al demonstrated the feasibility of using the brachialis branch of the musculocutaneous nerve and the extensor carpi radialis brevis branches of the radial nerve as donors and the anterior interosseous nerve and the flexor digitorum profundus branch of ulnar nerve as recipients, in a double nerve transfer. A recovery of all finger flexion was reported. However, it was impossible to transfer the brachialis branch to the ulnar flexor digitorum profundus.<sup>23</sup>

Melamed et al proposed a selective transfer between the motor branches of the supinator muscle to the extensor carpi ulnaris, extensor digiti quinti, and extensor digitorum communis in a 28-year-old patient with central cord syndrome. Restoration of finger extension reached the M4 score (Medical Research Council score, which classifies the degrees of force

**Table 2** Summaries of the main methodological aspects and results obtained in articles that present the axon count to evaluate the feasibility of using nerve transfer in surgical procedures

Study	Sample	Procedures performed	Results
Sananpanich et al <sup>23</sup>	Anatomical study: 22 fresh cadavers Clinical case: 18-year-old patient with a cervical spine fracture dislocation for 8 mo M0: elbow extension M4: wrist extension M0: finger and thumb motion (Medical Research Council System)	The extensor carpi radialis brevis was transferred to the anterior interosseous nerve and to branches of the ulnar flexor digitorum profundus below the elbow The brachialis branch was transferred to the anterior interosseous nerve and to the branches of the ulnar flexor digitorum profundus at the elbow (Combination stain of hematoxylin and eosin and Luxol fast blue and semiautomatic counting) There were four simultaneous transfers: 1. Posterior deltoid branch to the triceps branch 2. Supinator nerve branch to the posterior interosseous nerve 3. Brachialis branch to the anterior interosseous nerve 4. Extensor carpi radialis brevis to the ulnar flexor digitorum profundus	Axon ratio between transferred nerves: Extensor carpi radialis brevis to anterior interosseous nerve: 0.24 ± 0.15 Brachialis branch to anterior interosseous nerve: 0.55 ± 0.38 Extensor carpi radialis brevis to ulnar flexor digitorum profundus: 0.98 ± 0.60 10 mo after surgery, the patient had recovered: Elbow extension M4 finger and thumb extension Finger flexion M2 thumb flexion (up to 18 mo, the thumb flexion had improved to M4)

(Continued)

**Table 2** (Continued)

Study	Sample	Procedures performed	Results
Melamed et al <sup>24</sup>	Anatomical study: 7 fresh cadavers 14 members Clinical case: 18-year-old patient with a cervical fracture for 8 mo diagnosed with spinal cord trauma M0 finger extension (Medical Research Council System)	Branch dissection to the extensor digitorum communis and supinator superficial and deep branches, anatomical and histological measurements Staining with hematoxylin and eosin manual counting Supinator transfer to the extensor carpi ulnaris, extensor digiti quinti, and extensor digitorum communis	Number of axons Extensor digitorum communis = 401 ± 190 Supinator superficial and deep branches = 398 ± 75 After 15 mo of surgery: M3 finger extension
Lin et al <sup>25</sup>	30 randomized rats (3 groups, 10 rats each)	Group A: rats underwent total root avulsion of the left brachial plexus and performed contralateral C7 transfer to the avulsed C7 root Group B: rats underwent total root avulsion of the left brachial plexus and performed a contralateral C7 transfer to the damaged radial nerve Group C: rats underwent total root avulsion of the left brachial plexus and were not treated with any nerve transfer	Six months after surgery: Increased amplitude and decreased latency of muscle action potentials, larger maximum tetanic contractile tension, heavier muscle mass, larger cross-sectional area of muscle fibers in the triceps, extensor carpi radialis, and extensor digitorum in groups A and B when compared with group C ( $p < 0.01$ ). There were no significant differences between groups A and B ( $p > 0.05$ ) Contralateral C7 nerve transfer to repair the avulsed C7 nerve root was feasible and effective in this rat model. It should be considered an option for the treatment of brachial plexus injuries
Yan et al <sup>26</sup>	18 randomized rats (3 groups, 6 rats each)	Group A: helicoid end-to-side with distal oblique repairs of musculocutaneous utilizing the vagus nerve as the donor source Group B: saphenous nerve interposition graft between the phrenic nerve and the musculocutaneous nerve Group C (control): the musculocutaneous nerve was transected and did not receive repair	Responses on electrophysiology, tetanus force, and histology were evaluated after 3 mo Each mean value tested in group A was significantly higher than that in group B or C There was no statistical difference ( $p > 0.5$ ) between the mean numbers of vagus nerve fibers in the segments proximal (2,237 ± 134) and distal (2,150 ± 156) to the graft attachment site Histological analysis revealed no axon injury or intraneural scarring at any point along the vagus nerve The study showed that the vagus nerve is a practical and reliable donor nerve for end-to-end nerve transfer

from M0 to M5, with M0 = complete paralysis; M1 = minimal muscle contraction; M2 = absence of active movement against gravity; M3 = weak contraction against gravity; M4 = active movement against gravity and resistance; and M5 = normal force), after 48 months and with preservation of elbow flexion.<sup>24</sup>

On another front, studies such as Lin et al show the usefulness and efficacy of contralateral C7 nerve transfer to repair the avulsed C7 nerve root, which has become an option for treating

brachial plexus lesions. The initial studies were performed in three groups of rats. The first group underwent total avulsion of the left brachial plexus and received transfer from the contralateral C7 root to the avulsed C7 nerve, the second group underwent total avulsion and transfer from the contralateral C7 root to the radial nerve, and the third group (controls) did not undergo nerve transfer. The groups submitted to the transfer procedure showed better muscle responses in several aspects after 6 months (► **Table 2**).<sup>25</sup>



Yan et al demonstrated that the vagus nerve could be used as a donor to repair brachial plexus lesions, using rats divided into three groups submitted to musculocutaneous nerve transection and different repair procedures. The first group was submitted to helicoid envelopment of the saphenous nerve by the saphenous nerve by the vagus nerve and the distal stump of the saphenous nerve was coaptated with the musculocutaneous in an end-to-side repair. The second group underwent an interposition graft of the saphenous nerve between the phrenic nerve and the musculocutaneous nerve. The third group (control) had the musculocutaneous nerve transected and received no repair. The results showed that the first group had the best results and that the vagus nerve is a reliable donor in this procedure.<sup>26</sup>

In the articles presented in this review, two approaches were identified to evaluate the histological compatibility in distal neurotizations. The first approach was based only on nerve count endings present in the donor and recipient nerves, strictly anatomical, performed in cadavers, and lacking experimental studies for their validation. The second approach involves studies in which transfer surgeries are performed in addition to simple axon count, which had their results evaluated. Some studies in both groups still make a correlation between the axon ratio of the donor-to-recipient nerves, but these data are not found in all studies. However, this information is extremely relevant in discussing the feasibility of a given transfer.

A proposal regarding neural density was also detected, which would be more significant than simple axon count.

Finally, there was a concern about the need to standardize the counting procedures, referring to the use of blade staining, counting method, and other procedures, for better reproducibility and comparability of the results obtained in different studies.

Highlighting of new trends represented by calculation of neural densities instead of simply counting the number of axons to claim the histological compatibility in a certain nerve transfer can be pointed out as one of the main contributions of this study.

## Conclusion

The review of the articles has provided compelling evidence that the number of axons is a critical determinant of the success of nerve transfer procedures. However, the relationship between the number of axons in the donor nerve and that in the recipient nerves appears to be even more crucial for successful transfers, a factor that is not always adequately explored by authors in the existing literature. It is evident from the reviewed studies that there is no consensus on the ideal axon ratio, underscoring the need for further investigation into the concept of axonal density through experimental studies. By shedding light on the importance of axon count and its relationship with nerve transfers, this review provides valuable insights into the field, empowering surgeons to adopt personalized approaches for patients and ensuring histological compatibility between the nerves

involved. This knowledge will prove invaluable, especially in complex cases with limited donor nerve options, ultimately advancing the management of traumatic brachial plexus lesions and improving the overall outcomes of nerve transfer surgeries.

### Note

This study was performed at the Instituto Vita, São Paulo, SP, Brazil.

### Author Contributions

C.S.C. wrote the original draft of the article, participated in the review, editing process data curation, conducting the research; investigation process; and approval of the final article. J.C.N. contributed to the methodology, and participated in the review, editing process, supervision, and approval of the final article. T.H.W. participated in the review, supervision, and approval of the final article. L.S. contributed to the editing process, validation, and approval of the final article. E.Y.W. contributed to the editing process, validation, and approval of the final article.

### Conflict of Interest

None declared.

### Acknowledgments

The authors thank Professor Edie Benedito Caetano, who inspired this study, Professor Eder Tadeu Gomes Cavalheiro, who gave appropriate suggestions during the revision process, and Professor Marco Martins Amatuzzi for all his contributions to this field in life (in memoria).

## References

- Cheah A, Lee EY, Lim AYT. Upper extremity axon counts and clinical implications for motor nerve transfer. *Plast Reconstr Surg* 2019;144(06):1044e–1050e
- Khair MM, Schreiber JJ, Rosenblatt L, Byun DJ, Lee SK, Wolfe SW. Axon counts yield multiple options for triceps fascicular nerve to axillary nerve transfer. *J Hand Surg Am* 2016;41(11):e405–e410
- Schreiber JJ, Byun DJ, Khair MM, Rosenblatt L, Lee SK, Wolfe SW. Optimal axon counts for brachial plexus nerve transfers to restore elbow flexion. *Plast Reconstr Surg* 2015;135(01):135e–141e
- Jiang BG, Yin XF, Zhang DY, Fu ZG, Zhang HB. Maximum number of collaterals developed by one axon during peripheral nerve regeneration and the influence of that number on reinnervation effects. *Eur Neurol* 2007;58(01):12–20
- Costa AL, Papadopoulos N, Porzionato A, et al. Studying nerve transfers: searching for a consensus in nerve axons count. *J Plast Reconstr Aesthet Surg* 2021;74(10):2731–2736
- Page MJ, McKenzie JE, Bossuyt PM, et al. The PRISMA 2020 statement: an updated guideline for reporting systematic reviews. *BMJ* 2021;372(71):n71
- Ackley BJ, Swan BA, Ladwig G, Tucker S. *Evidence-Based Nursing Care Guidelines: Medical-Surgical Interventions*. St. Louis, MO: Mosby Elsevier; 2008
- Kehrer A, Engelmann S, Ruewe M, et al. Perfusion maintains functional potential in denervated mimic muscles in early persistent facial paralysis which requires early microsurgical treatment: the histoanatomic basis of the extratemporal facial nerve trunk assessing axonal load in the context of possible nerve transfers. *Clin Hemorheol Microcirc* 2018;70(01):1–13

- 9 Mohan AT, Suchyta M, Vyas KS, Lachman N, Mardini S, Saint-Cyr M. A cadaveric anatomical and histological study of recipient intercostal nerve selection for sensory reinnervation in autologous breast reconstruction. *J Reconstr Microsurg* 2021;37(02):136–142
- 10 Mahmood B, Marshall DC, Wolfe SW, Lee SK, Fufa DT. cadaveric evaluation of myelinated nerve fiber count in the nerve to the gracilis muscle in relation to use as a free functional muscle transfer for elbow flexion. *J Reconstr Microsurg* 2020;36(05):311–315
- 11 Kara M, Bitik O, Üstün GG, Ülker M, Sargon MF, Aksu AE. A supportive donor nerve for long-term facial paralysis: anatomical analysis of the posterior auricular nerve and micro-anatomical comparison with zygomatic nerve. *J Plast Reconstr Aesthet Surg* 2022;75(02):773–781
- 12 Frank K, Englbrecht M, Koban KC, et al. Nerve transfer of the anterior interosseous nerve to the thenar branch of the median nerve: an anatomical and histological analysis. *J Plast Reconstr Aesthet Surg* 2019;72(05):751–758
- 13 Schenck TL, Lin S, Stewart JK, et al. Sensory reanimation of the hand by transfer of the superficial branch of the radial nerve to the median and ulnar nerve. *Brain Behav* 2016;6(12):e00578
- 14 Colonna MR, Pino D, Battiston B, et al. Distal nerve transfer from the median nerve lumbrical fibers to the distal ulnar nerve motor branches in the palm: an anatomical cadaveric study. *Microsurgery* 2019;39(05):434–440
- 15 Pruksakorn D, Sananpanich K, Khunamornpong S, Phudhichareonrat S, Chalidapong P. Posterior approach technique for accessory-suprascapular nerve transfer: a cadaveric study of the anatomical landmarks and number of myelinated axons. *Clin Anat* 2007;20(02):140–143
- 16 Luo TD, Wigton MD, Berwick BW, et al. Transfer of the dorsal cutaneous branch of the ulnar nerve for restoration of median nerve sensation: a cadaveric study. *Clin Anat* 2018;31(07):1006–1012
- 17 Namazi H, Haji Vandi S. Transfer of extensor digiti minimi and extensor carpi ulnaris nerve branches to the intrinsic motor nerve branches: a histological study on cadaver. *Orthop Traumatol Surg Res* 2017;103(04):509–511
- 18 Namazi H, HajiVandi S. Supinator to ulnar nerve transfer via in situ anterior interosseous nerve bridge to restore intrinsic muscle function in combined proximal median and ulnar nerve injury: a novel cadaveric study. *J Surg Res* 2017;211:95–99
- 19 Hong GH, Liu JB, Liu YZ, Gao KM, Zhao X, Lao J. Modified contralateral C7 nerve transfer: the possibility of permitting ulnar nerve recovery is confirmed by 10 cases of autopsy. *Neural Regen Res* 2019;14(08):1449–1454
- 20 Saltzman EB, Krishnan K, Winston MJ, Das De S, Lee SK, Wolfe SW. A cadaveric study on the utility of the levator scapulae motor nerve as a donor for brachial plexus reconstruction. *J Hand Surg Am* 2021;46(09):812.e1–812.e5
- 21 Gang Y, Wang T, Sheng J, Hou C, Lin H. Anatomical feasibility of transferring the obturator and genitofemoral nerves to repair lumbosacral plexus nerve root avulsion injuries. *Clin Anat* 2014;27(05):783–788
- 22 Domeshek LF, Hunter DA, Santosa K, et al. Anatomic characteristics of supraorbital and supratrochlear nerves relevant to their use in corneal neurotization. *Eye (Lond)* 2019;33(03):398–403
- 23 Sananpanich K, Kraissarin J, Siriwittayakorn W, Tongprasert S, Suwansirikul S. Double motor nerve transfer for all finger flexion in cervical spinal cord injury: an anatomical study and a clinical report. *J Hand Surg Am* 2018;43(10):920–926
- 24 Melamed E, Patel N, Duarte ECW, Nascimento ASCQ, Bertelli JA. Selective transfer of nerve to supinator to restore digital extension in central cord syndrome: an anatomical study and a case report. *Microsurgery* 2022;42(04):352–359
- 25 Lin H, Sheng J, Hou C. The effectiveness of contralateral C7 nerve root transfer for the repair of avulsed C7 nerve root in total brachial plexus injury: an experimental study in rats. *J Reconstr Microsurg* 2013;29(05):325–330
- 26 Yan JG, Shen FY, Thayer J, et al. Repair of the musculocutaneous nerve using the vagus nerve as donor by helicoid end-to-side technique: an experimental study in rats. *J Neurosci Res* 2017;95(12):2493–2499