



# Letter: Primary Cyst of Spleen Mimicking the Echinococcal Cyst: A Rare Splenic Space Occupying Lesion

Ashish Gupta<sup>1</sup> Prabhjot Kaur<sup>1</sup> Puja Saxena<sup>2</sup> Ashish Jindal<sup>3</sup> Priyanka Khuttan<sup>4</sup>  
Navdeep Singh Saini<sup>1</sup>

<sup>1</sup> Department of General Surgery, Dr. B R Ambedkar State Institute of Medical Sciences, Mohali, Punjab, India

<sup>2</sup> Department of Anesthesia, Dr. B R Ambedkar State Institute of Medical Sciences, Mohali, Punjab, India

<sup>3</sup> Department of Internal Medicine, Dr. B R Ambedkar State Institute of Medical Sciences, Mohali, Punjab, India

<sup>4</sup> Department of Radiology, Dr. B R Ambedkar State Institute of Medical Sciences, Mohali, Punjab, India

Address for correspondence Ashish Gupta, MS, Department of General Surgery, Dr. B R Ambedkar State Institute of Medical Sciences, Mohali, Punjab 160055, India (e-mail: drashish0403@gmail.com).

J Gastrointest Infect 2023;13:99–100.

Splenic space occupying lesions are a rare clinical diagnosis.<sup>1</sup> The spleen cyst is seen as a part of traumatic or inflammatory infection of the pancreas.<sup>2</sup> These cysts are usually pseudocysts. Out of primary lesions, hydatid cyst forms 60% of the total cases. True noninfective cysts are rare and usually congenital.<sup>2</sup> Splenectomy is proposed to be the definitive treatment.<sup>3</sup>

A 32-year-old female presented to surgical outpatient department with the complaints of pain in the left hypochondrium for the past 2 months. With above complaints, she was subjected to ultrasonogram of the abdomen that showed a thin-walled cyst with floating echoes and membranes. The diagnosis was further confirmed by subjecting the patient to hydatid serology that was negative. She underwent contrast-enhanced computerized tomogram (CECT) abdomen that confirmed the cystic lesion involving only the spleen and other viscera were found to be unremarkable (► **Fig. 1**). After establishing the diagnosis with radiological and hematological tests, she was put on oral albendazole 15 mg/kg therapy for three cycles. The patient was given prophylactic pneumococcal vaccine 3 weeks prior to the surgery.

After optimization, the patient underwent open splenectomy through a midline incision. There was no intraoperative spillage of the cyst contents. On cutting open the specimen,

a clear fluid was aspirated. The postoperative course was uneventful. The resected spleen was subjected to histopathology examination that revealed a 120-gram spleen with cystic lesion 6 × 5.8 × 3 cm in the size involving the entire central splenic parenchyma. On microscopy, the splenic capsule shows the foci of dystrophic calcification. No ectocyst or endocyst could be identified. The patient is doing well after 7 months of surgery.

Spleen is an important viscera that is involved in various hematopoietic, malignant as well as benign pathologies.<sup>4</sup> Patients with splenic cysts present with a vague abdominal pain that is dragging in sensation. The primary splenic cysts present as more subtle symptoms like pain abdomen<sup>2</sup> and vomiting in case it is compressing upon the stomach. These patients run an indolent course and are usually asymptomatic.

The true cysts have multiple overlap radiologically and hydatid cyst may mimic the primary splenic cysts especially in endemic areas. The ultrasound of the splenic hydatid may show the presence of floating membranes, hydatid sand, and multiple daughter cysts. However, the simple cyst lacks all these signs. The simple cyst of hydatid which is classified as a class I hydatid that typically mimics the noninfective cysts. Calcification, although rare in true cysts, was present in the index patient.<sup>5</sup> The CECT will also confirm the findings. The aspiration of the cyst fluid and subjecting it to fluid amylase, hydatid

received

April 21, 2023

first decision

May 31, 2023

accepted

August 19, 2023

article published online

October 12, 2023

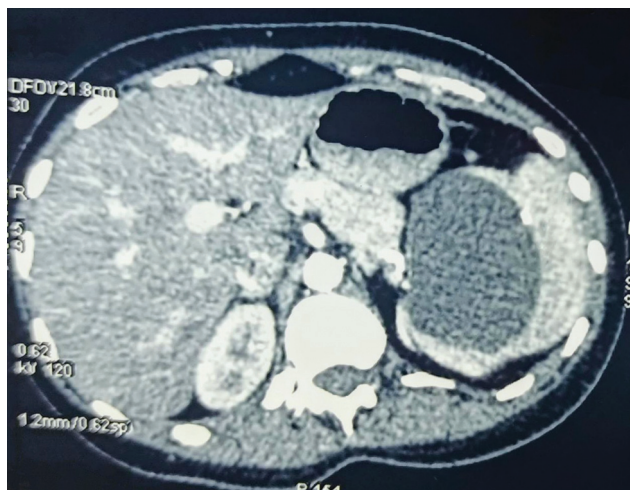
DOI <https://doi.org/10.1055/s-0043-1775728>.

ISSN 2277-5862.

© 2023. Gastrointestinal Infection Society of India. All rights reserved.

This is an open access article published by Thieme under the terms of the Creative Commons Attribution-NonDerivative-NonCommercial-License, permitting copying and reproduction so long as the original work is given appropriate credit. Contents may not be used for commercial purposes, or adapted, remixed, transformed or built upon. (<https://creativecommons.org/licenses/by-nc-nd/4.0/>)

Thieme Medical and Scientific Publishers Pvt. Ltd., A-12, 2nd Floor, Sector 2, Noida-201301 UP, India



**Fig. 1** Contrast-enhanced computed tomography image showing the splenic cyst.

scotices examination, and tumor markers will be helpful to establish the definitive diagnosis.<sup>3</sup> The serum immunoglobulin G hydatid serology is a preoperative test that can be used to establish the diagnosis of echinococcosis.

The splenectomy has emerged as definitive treatment in these cases.<sup>3</sup> Preservation of 25% of the splenic parenchyma for retained splenic function can be tried wherever feasible.

#### Ethical Statement

Not applicable.

#### Authors' Contribution

All authors contributed equally to the article.

#### Data Availability Statement

There is no data associated with this work.

#### Funding

None.

#### Conflict of Interest

None declared.

#### Acknowledgments

None.

#### References

- 1 Karfis EA, Roustanis E, Tsimoyiannis EC. Surgical management of nonparasitic splenic cysts. *JSL* 2009;13(02):207–212
- 2 Golmohammadzadeh H, Maddah G, Shams Hojjati Y, Abdollahi A, Shabahang H. Splenic cysts: analysis of 16 cases. *Caspian J Intern Med* 2016;7(03):217–221
- 3 Hansen MB, Moller AC. Splenic cysts. *Surg Laparosc Endosc Percutan Tech* 2004;14(06):316–322
- 4 Lewis SM, Williams A, Eisenbarth SC. Structure and function of the immune system in the spleen. *Sci Immunol* 2019;4(33): eaa6085
- 5 Dachman AH, Ros PR, Murari PJ, Olmsted WW, Lichtenstein JE. Nonparasitic splenic cysts: a report of 52 cases with radiologic-pathologic correlation. *AJR Am J Roentgenol* 1986;147(03): 537–542