



# Endovascular Management of Falcine Dural Arteriovenous Fistula—A Case Report and Review of Literature

Batuk Diyora<sup>1</sup> Kavin Devani<sup>1</sup> Anup Purandare<sup>1</sup> Ravi Wankhade<sup>1</sup> Prakash Palave<sup>1</sup> Pallavi Shukla<sup>1</sup>  
Gagan Dhall<sup>1</sup>

<sup>1</sup>Department of Neurosurgery, LTMG Hospital, Sion, Mumbai, Maharashtra, India

Asian J Neurosurg 2023;18:818–822.

Address for correspondence Batuk Diyora, DNB (Neurosurgery), Department of Neurosurgery, Second Floor, College Building, LTMG Hospital, Sion, Mumbai 400020, Maharashtra, India (e-mail: bddiyora@gmail.com; batuk73@yahoo.co.in).

## Abstract

Cranial dural arteriovenous (AV) fistulas are abnormal connections between the branches of dural arteries to dural veins or venous sinuses. They are most frequently located at the transverse sinus and cavernous sinus. They can occur at every cranial dural sinus. Dural AV fistula of falx cerebri is rare. A 62-year-old female presented with signs and symptoms of raised intracranial pressure. Radiological imaging revealed a dural AV fistula at the posterior one-third falx cerebri. She underwent transarterial embolization, and complete obliteration of the fistula was achieved. A detailed digital subtraction angiography study is warranted in patients with seemingly benign complaints like recurrent headaches, and falcine dural AV fistula should be identified and treated in the nick of time. We describe a very rare falcine dural AV fistula case and its management.

## Keywords

- ▶ dural AV fistula
- ▶ falx cerebri
- ▶ falcine sinus
- ▶ Onyx embolization

## Introduction

Cranial dural arteriovenous fistulas (AVF) are the abnormal connection between the branches of dural arteries to dural veins or dural venous sinuses. They represent about 10 to 15% of intracranial vascular malformations.<sup>1</sup> These lesions are most commonly located in the posterior fossa or around the cavernous sinus. The uncommon location includes the sagittal sinus, anterior cranial fossa, and craniocervical junction.<sup>2</sup> Dural AVF located at the falx cerebri is very rare, and to date, only six cases have been reported (▶ **Table 1**).<sup>3–8</sup> We report a rare and interesting case of falcine dural AVF and describe its management.

## Case Report

A 62-year-old female patient was referred to manage signs and symptoms of raised intracranial pressure. Earlier, she had headaches, vomiting, and gait ataxia for the last 2 weeks, requiring hospitalization. Her symptoms improved with antiedema measures, so she was discharged. Her symptoms resurfaced after 10 days, and she was readmitted. She was conscious and oriented and had bilateral papilloedema grade II. Her computed tomography (CT) scan of the brain revealed abnormal small hyperdense lesions around the left perimesencephalic cistern with contrast enhancement (▶ **Fig. 1A, B**). Magnetic resonance imaging (MRI) of the brain

DOI <https://doi.org/10.1055/s-0043-1776302>.  
ISSN 2248-9614.

© 2023. Asian Congress of Neurological Surgeons. All rights reserved.

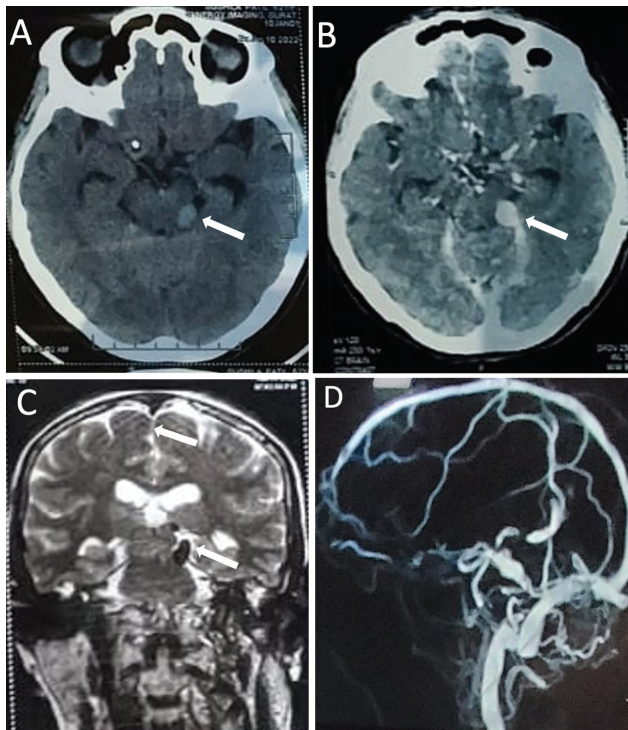
This is an open access article published by Thieme under the terms of the Creative Commons Attribution-NonDerivative-NonCommercial-License, permitting copying and reproduction so long as the original work is given appropriate credit. Contents may not be used for commercial purposes, or adapted, remixed, transformed or built upon. (<https://creativecommons.org/licenses/by-nc-nd/4.0/>)

Thieme Medical and Scientific Publishers Pvt. Ltd., A-12, 2nd Floor, Sector 2, Noida-201301 UP, India

**Table 1** Reported cases of falcine dural AVF

Sl. no	Authors	Age/Sex	Arterial feeder	Location	Venous drainage	Location	VP	CVR	Treatment	Outcome
1	Kosnik et al 1974 <sup>3</sup>	34/F	Headache	Anterior	ACA, AFA	ISS	No	No	DS	Excellent
2	Agawa et al 1991 <sup>4</sup>	62/M	SAH		MMA, AFA	FS, SSS	Yes	Yes	DS	Excellent
3	Kothbauer and Huber 1994 <sup>5</sup>	73/F	SAH	Posterior	MMA, OA	PPV, GV	Yes	Yes	NA	NA
4	Ratliff and Voorhies 1999 <sup>6</sup>	24/M	Headache	Anterior	ACA, VA	SSS, PPV GV	Yes	Yes	DS + RA	Excellent
5	Yoshioka et al 2013 <sup>7</sup>	60/M	Incidental	Anterior	ACA, MMA, AEA	FS, SSS/ISS	No	Yes	DS	Excellent
6	Yamaguchi et al 2016 <sup>8</sup>	67/M	Altered sensorium	Anterior	MMA, AFA and left pericallosal artery	SSS, posterior callosal vein, Vein of Galen	Yes	Yes	TAE + DS	Fair
7	Present case	62/F	Headache, gait ataxia	Posterior	MMA, VA	SSS	Yes	Yes	TAE	Excellent

Abbreviations: ACA, anterior cerebral artery; AEA, anterior ethmoidal artery; AFA, anterior falcine artery; CVR, cortical venous reflux; DS, direct surgery; F, female; FS, falcine sinus; GV, Galenic vein; ICH, intracranial hemorrhage; ISS, inferior sagittal sinus; M, male; MMA, middle meningeal artery; NA, not available; OA, occipital artery; PPV, posterior pericallosal vein; RS, radiosurgery; RVD, retrograde venous drainage; SAH, subarachnoid hemorrhage; SSS, superior sagittal sinus; TAE, transarterial embolization; VA, vertebral artery; VP, venous pouch.

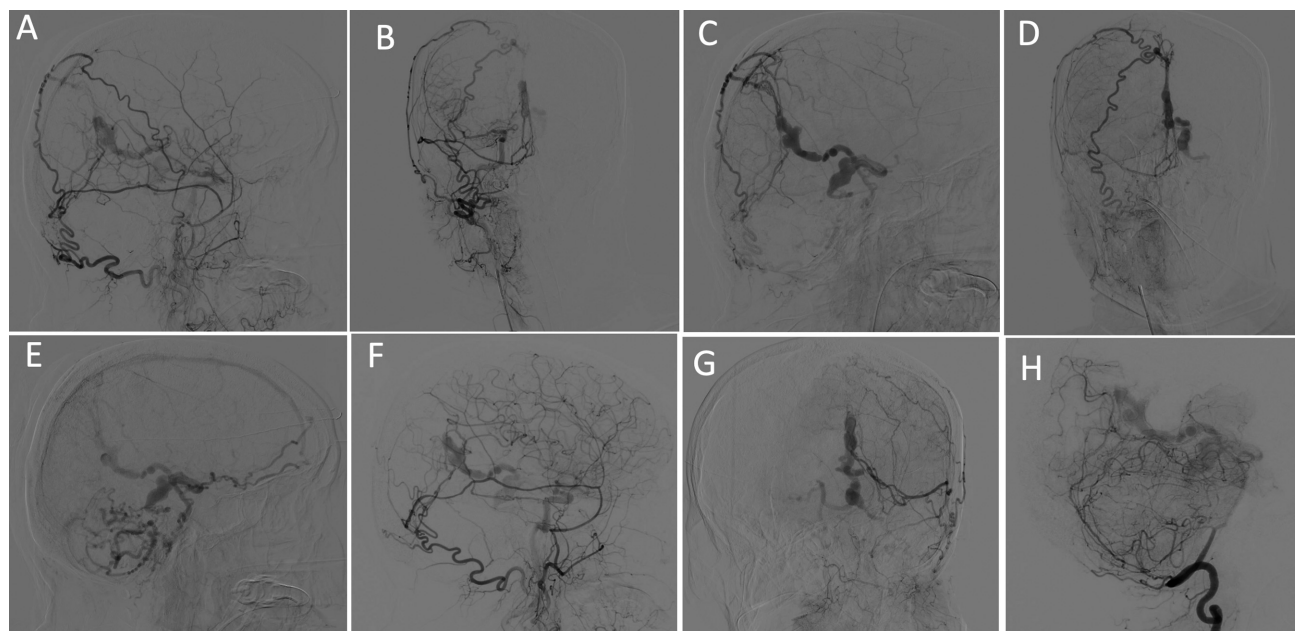


**Fig. 1** Computed tomography scan brain plain study showing abnormal small hyperdense lesion around left peri mesencephalic cistern (A, white arrow) which is enhancing on intravenous contrast administration (B, white arrow). Magnetic resonance imaging brain coronal T2-weighted images showing flow void located at the lateral aspect of the left side of the mid brain in relation to tentorium cerebelli (C, white arrow). Magnetic resonance venogram of the brain showing non-visualization of inferior sagittal sinus and straight sinus (D).

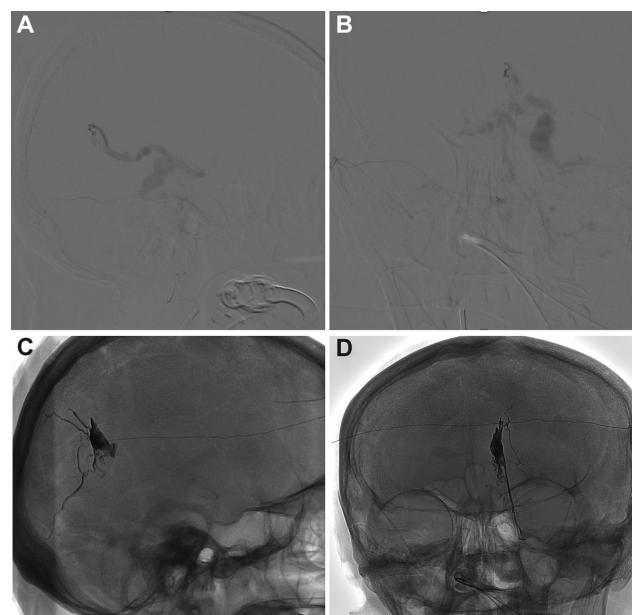
showed flow voids on T2-weighted images (→Fig. 1C). MR venogram of the brain showed nonvisualization of the inferior sagittal sinus and straight sinus (→Fig. 1D). Digital subtraction angiography (DSA) study of brain and neck

vessels revealed a posterior falcine dural AVF, getting supplied from the posterior branch of the middle meningeal artery, a branch of the occipital artery on both sides, and meningeal branch from the left vertebral artery. This resulted in significant cortical venous reflux in the infratentorial compartment and drained into the superior sagittal sinus at its anterior end through basifrontal veins (→Fig. 2A–H).

The patient underwent embolization of the posterior falcine dural AVF (Cognard Grade IV). Under general anesthesia, 6 French (F) arterial sheath was placed in the right femoral artery. About 7,000 units of heparin were given, and Activated Coagulation Time (ACT) was maintained at around 250 to 300 seconds throughout the procedure. With the help of a 5F angiography catheter, right external carotid angiography was performed. Under roadmap guidance, with the help of a double-length Terumo wire, a 5F angiography catheter was replaced with a 6F Envoy (Cerenovus, Johnson and Johnson Mexico) guiding catheter and positioned into the distal external carotid artery. Through 6F guiding catheter, Sonic 1.2 F (Balt, Montmorency, France) microcatheter (167 cm length with 15 mm detachable tip) advanced over 0.08" Mirage (Balt, Montmorency, France) microwire under digital roadmap guidance. The microcatheter tip was placed into the distal part of the posterior branch of the middle meningeal artery close to the mouth of the fistula. A super selective run was taken through the microcatheter (→Fig. 3A, B). The dead-space volume within the microcatheter was first filled with dimethyl-sulfoxide. Subsequently, under blank roadmap guidance, about 0.8 mL liquid embolic agent, Onyx (Medtronic), was injected very slowly in the fistula, and it was obliterated. The guide catheter and microcatheter were removed. An adequate glue penetration into the fistula was confirmed on fluoroscopic images (→Fig. 3C, D). Post Onyx injection angiography runs through the right external carotid artery, left external carotid artery, and left vertebral artery and revealed no filling of the fistula (→Fig. 4A–G). The postoperative course was uneventful. Her clinical symptoms significantly



**Fig. 2** (A) Right external carotid injection showing falcine dural arteriovenous fistula getting supplied from posterior branch of middle meningeal artery on lateral view (B) and anteroposterior (AP) view, and (C) from branch of right occipital artery on lateral view (D) and AP view. (E) Right external carotid injection delayed lateral view showing fistula along with venous pouch and significant cortical venous reflux. (F) Left external carotid artery injection also showing filling of the fistula from posterior branch of middle meningeal artery and branch from right occipital artery on lateral view (G) and AP view (H). Left vertebral artery injection showing filling of fistula through its meningeal branch on lateral view.



**Fig. 3** (A) Super selective contrast injection from the microcatheter showing filling of fistula on lateral (B) and anteroposterior (AP) view. (C) X-ray skull lateral (D) and AP view showing glue cast.

improved, and she was discharged on the 4th postprocedure day. At 1-year follow-up, she was asymptomatic.

## Discussion

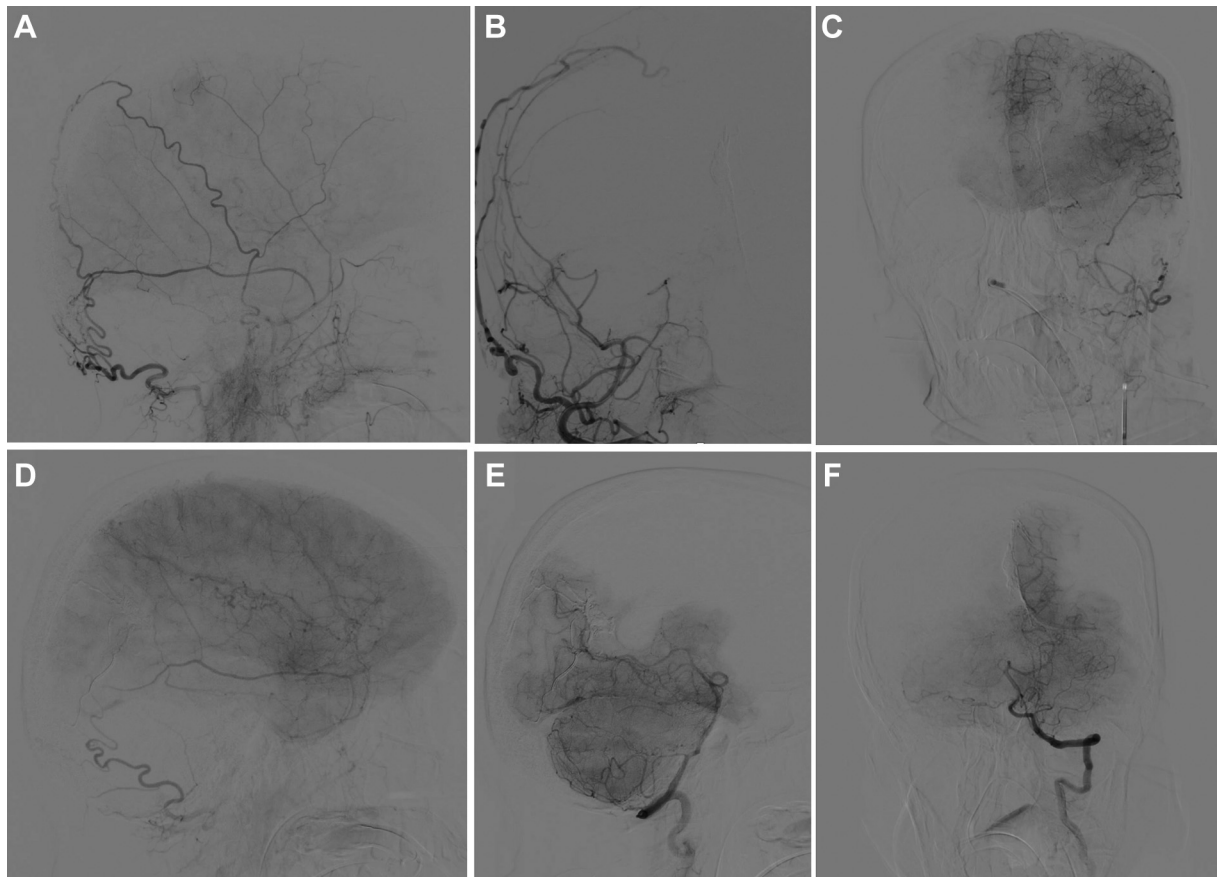
Dural venous sinuses arise from the mesenchyme located in the mesencephalic flexure. During the growth of the embryo, the sagittal plexus is seen in the falx cerebri with two ends.

Anterior superior sagittal sinus (SSS) arises from its dorsal end, and inferior sagittal sinus and straight sinus arise from its ventral end. Complete development of the occipital lobe results in the formation of the entire superior sagittal and straight sinus. Falcine sinus is formed by one of the caudal anastomotic loops of the sagittal plexus and disappears before birth after the complete development of SSS and straight sinus.<sup>9</sup>

Persistence of it can be a congenital or acquired phenomenon related to an abnormality of the straight sinus. According to an MRI-based study, persistent falcine sinus incidence is about 1% in pediatric patients and about 5.3% in a combined population. The incidence of recanalization of falcine sinuses is about 30%, and the etiological factors described are compression by tumor, cerebral venous sinus thrombosis, and hypertrophic meningitis. They demonstrate a strong association between falcine sinus recanalization and obliteration of major sinuses.<sup>10</sup> A review of the literature revealed the rarity of falcine dural AVF. Only seven cases have been reported, including our case.

There are no outstanding characteristics about age, gender, or symptoms at onset. Variable symptoms can be observed in these patients, ranging from severe refractory headache, which can be due to raised intracranial pressure or subarachnoid and intraventricular hemorrhage. The fistula having direct cortical venous drainage is more prone to present with intracerebral hematoma.

Persistent or recanalization of falcine sinus results in vascular variation or anomalies. It can be easily missed on routine CT scans and MRI brain images, including CT- and MRI-based angiography. Unless found with secondary insults



**Fig. 4** (A) Post glue embolization images showing complete obliteration of the fistula on right external carotid injection; lateral view (B) and anteroposterior (AP) view (C), on left common carotid artery injection; AP view (D) and lateral view (E), and left vertebral artery injection lateral view (F) and AP view.

like subarachnoid or intraparenchymal or intraventricular hemorrhage, these lesions are difficult to diagnose and often not sought after. MR or CT venogram studies in patients with features of raised intracranial pressure are instrumental in providing subtle hints of this uncommon pathology. Subsequently, they should be subjected to DSA. Patients presenting with hemorrhages should be directly subjected to DSA, which is the gold standard investigation for diagnosing this pathology, delineating its anatomy, and chalking out further management plans. It shows the exact morphology of the fistula, including its location, arterial supply, venous drainage, direction of the blood flow, and associated vascular abnormality. In view of significant cortical venous reflux and risk of hemorrhage, all the patients require treatment as early as possible.

Treatment options are endovascular, microsurgery, radiosurgery, or combination.<sup>3-8</sup> While the endovascular procedure aims to inject glue in the fistula selectively, microsurgery aims to disconnect the arterial supply and excision of the fistula in the falx.<sup>3</sup> In patients with secondary insults like a large intraparenchymal hemorrhage, a decompressive surgery is warranted in patients with compromised consciousness. It serves the purpose of clot evacuation, and one can aim to obliterate the fistulous points. Interhemispheric approaches are often used to target their obliteration. Most previous cases were subjected to direct surgical

obliteration of the fistulous point. The more recent form of their management is the transarterial embolization of the feeders. Only transarterial embolization has never been attempted for this pathology. Yamaguchi et al initially subjected their patient to partial transarterial embolization and was subsequently subjected to surgical occlusion.<sup>8</sup> Ratliff and Voorhies patient had a similar presentation to our patient, and they managed it with direct surgical obliteration followed by subjecting him to radiosurgery.<sup>6</sup> Ours was the first case where a complete obliteration was achieved with transarterial embolization.

## Conclusion

One should consider DSA for patients with raised intracranial pressure with evidence of vascular channels around the falx and peri mesencephalic cistern. Awareness of the falcine sinus and falcine venous plexus is crucial in managing these rare forms of dural AVF. Through various treatment options, transarterial Onyx embolization can completely cure the fistula.

## Funding

None.

## Conflict of Interest

None declared.

## References

- 1 Houser OW, Baker HL Jr, Rhoton AL Jr, Okazaki H. Intracranial dural arteriovenous malformations. *Radiology* 1972;105(01):55–64
- 2 Lasjaunias P, Manelfe C, Chiu M. Angiographic architecture of intracranial vascular malformations and fistulas—pretherapeutic aspects. *Neurosurg Rev* 1986;9(04):253–263
- 3 Kosnik EJ, Hunt WE, Miller CA. Dural arteriovenous malformations. *J Neurosurg* 1974;40(03):322–329
- 4 Agawa M, Kohno T, Sogabe K. [Dural arteriovenous malformation in the falx with subarachnoid hemorrhage]. *No Shinkei Geka* 1991;19(09):841–845
- 5 Kothbauer K, Huber P. Dural arteriovenous fistula in the falx cerebri. *Neuroradiology* 1994;36(08):616–618
- 6 Ratliff J, Voorhies RM. Arteriovenous fistula with associated aneurysms coexisting with dural arteriovenous malformation of the anterior inferior falx. Case report and review of the literature. *J Neurosurg* 1999;91(02):303–307
- 7 Yoshioka S, Moroi J, Kobayashi S, Furuya N, Ishikawa T. A case of falcine sinus dural arteriovenous fistula. *Neurosurgery* 2013;73(03):E554–E556
- 8 Yamaguchi T, Higaki A, Yokota H, Mashiko T, Oguro K. A case of dural arteriovenous fistula in the falx cerebri: case report and review of the literature. *NMC Case Rep J* 2016;3(03):67–70
- 9 Varma DR, Reddy BC, Rao RV. Recanalization and obliteration of falcine sinus in cerebral venous sinus thrombosis. *Neurology* 2008;70(01):79–80
- 10 Lin L, Lin JH, Guan J, Zhang XL, Chu JP, Yang ZY. Falcine sinus: incidence and imaging characteristics of three-dimensional contrast-enhanced thin-section magnetic resonance imaging. *Korean J Radiol* 2018;19(03):463–469