

The Varieties of Ignorance: Imaging of Congenital Variants of Pancreas and Its Ductal System—A Pictorial Review

Shaurya Sharma¹ Binit Sureka¹ Taruna Yadav¹ Ananya Panda¹ Pushpinder Singh Kherra¹

¹Departments of Diagnostic and Interventional Radiology, All India Institute of Medical Sciences (AIIMS), Basni, Jodhpur, Rajasthan, India

Address for correspondence Binit Sureka, MD, DNB, MBA, Department of Diagnostic and Interventional Radiology, All India Institute of Medical Sciences, Jodhpur 342005, Rajasthan, India (e-mail: binitSUREKAPGI@gmail.com).

Indian J Radiol Imaging 2024;34:324–331.

Abstract

Congenital variants of the pancreas are being increasingly detected with the widespread use of modern imaging techniques. The underlying embryologic aberration predicts the final appearance of pancreatic development. It is essential to recognize these congenital variants, as many of these have been proven to be associated with pancreatic diseases like recurrent pancreatitis and chronic abdominal pain. Cross-sectional techniques like multi-detector computed tomography and magnetic resonance cholangiopancreatography are the most used imaging techniques for the pancreas, where a radiologist comes across these variants. This pictorial aims to classify the type of variant anatomy of the pancreas, their imaging appearances, and their clinical significance.

Keywords

- ▶ congenital
- ▶ pancreas
- ▶ variations
- ▶ agenesis

Introduction

With the advent of multidetector computed tomography (MDCT) and magnetic resonance cholangiopancreatography, the modern radiologist comes across many imaging findings not pertaining to the primary diagnostic question. Such variants, albeit not commonly seen, impose important diagnostic dilemmas regarding their reporting and management. Many such variants are recognized in pancreatic imaging, which are discussed in the following sections.

Embryology of the Pancreas

As the embryonic development enters its 5th week, the pancreas starts developing. The main contribution occurs from dorsal (cranial) and ventral (caudal) buds that arise from the foregut.¹ In the 4th week, the ventral bud arises along with the hepatic diverticulum, while the dorsal bud arises somewhat rostral to it. During the 6th week, the dorsal

bud elongates and grows into the dorsal mesentery. The ventral pancreas and bile duct rotate counterclockwise posterior to the duodenum, and the two components fuse around 7 weeks (▶ **Fig. 1**). Each component has its own ductal drainage, draining into the duodenum. After the fusion of the buds, it is also followed soon by the fusion of the pancreatic ducts in the region of the pancreatic head. The whole of the ventral pancreatic duct and the distal part of the dorsal pancreatic duct in the body and tail form the main pancreatic duct (Wirsung), while the accessory duct (Santorini) forms the rest of the dorsal duct.

Congenital variants of the pancreas can be broadly divided into those involving the ductal system and those involving the pancreatic parenchyma (▶ **Fig. 2**).

Variation in Course

The pancreatic duct course can be of the following types—descending—most common, sigmoid course, and vertical and loop course (▶ **Figs. 3 and 4**).

article published online
November 20, 2023

DOI <https://doi.org/10.1055/s-0043-1776414>.
ISSN 0971-3026.

© 2023. Indian Radiological Association. All rights reserved.
This is an open access article published by Thieme under the terms of the Creative Commons Attribution-NonDerivative-NonCommercial-License, permitting copying and reproduction so long as the original work is given appropriate credit. Contents may not be used for commercial purposes, or adapted, remixed, transformed or built upon. (<https://creativecommons.org/licenses/by-nc-nd/4.0/>)
Thieme Medical and Scientific Publishers Pvt. Ltd., A-12, 2nd Floor, Sector 2, Noida-201301 UP, India

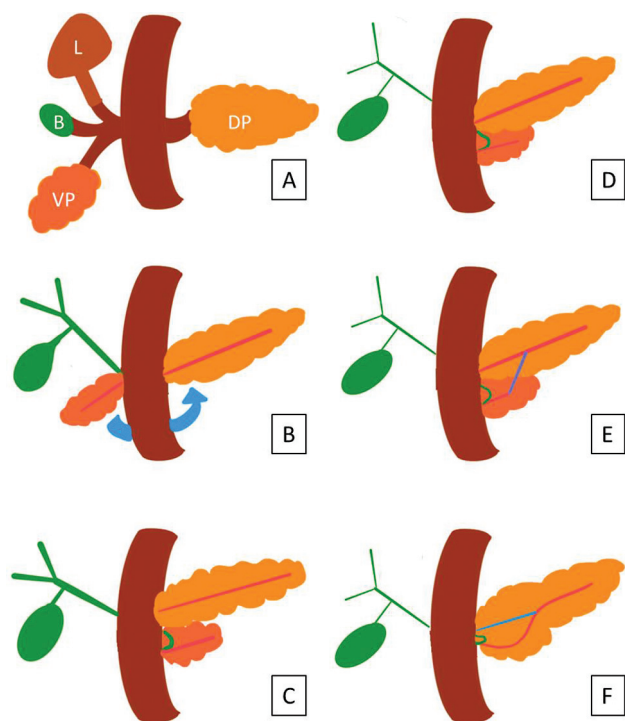


Fig. 1 (A) Development of ventral and pancreatic buds. The ventral bud differentiates into liver bud (L), biliary tree (B), and the ventral pancreatic bud (VP). Dorsal bud forms the dorsal pancreatic bud (DP). (B) Counterclockwise rotation of ventral pancreas, along with bile duct. (C) The ventral and dorsal pancreatic buds come to lie next to each other, with each having their own ductal system. (D) The buds fuse. (E) Communication develops between the two ductal systems. (F) The main pancreatic duct of Wirsung (pink) develops from the ventral duct while the proximal dorsal duct forms the duct of Santorini (blue).

Variations in Configuration

The configurations of the ductal system can be divided into the following types (► Fig. 5).

- Bifid pancreatic duct with dominant duct of Wirsung—the most common and classical configuration.
- Dominant duct of Santorini without divisum.
- Absent duct of Santorini.
- Pancreas divisum (PD).
- Bifid configuration of distal main pancreatic duct.
- Ansa pancreatica (► Fig. 6)—duct of Santorini hooks around the duct of Wirsung, which joins one of its side branches. Embryologically, instead of the two ducts merging, there is a loop that connects the inferior branches of the ventral and dorsal ducts.² Since the main pancreatic duct and side branch meet at a sloping angle in ansa pancreatica, there is inadequate pancreatic juice drainage, which leaves patients susceptible to pancreatitis.³

Pancreas Divisum

This anomaly occurs due to nonfusion of primitive ventral and dorsal ducts during the embryological development and is seen in 4 to 14% of autopsy specimens (► Fig. 7).^{3,4}

- Type 1 (Classic PD)—Failure of dorsal and ventral duct fusion, with each draining separately into minor and major papilla, respectively.
- Type 2—Absent ventral duct with the dominant duct of Santorini drainage.
- Type 3 (Incomplete PD)—small communicating branch between the dorsal and ventral ducts.

It is a clinically significant entity as its presence has been correlated with an increased incidence of recurrent acute pancreatitis (predominantly dorsal pancreatitis) and chronic abdominal pain.

Wirsungocele and Santorinicele

Wirsungocele and santorinicele are described as abnormal cystic dilation of the ventral or the dorsal ducts, respectively, near their terminal ends at the major or minor papillae (► Fig. 8).

These entities are commonly associated with anomalies like PD.

Santorinicele are thought to result from congenital or acquired weakness of the ductal walls, with chronic obstruction contributing to the acquired causes, and are associated with pancreatitis and chronic abdominal pain.⁵

Anomalous Pancreaticobiliary Junction

It is defined as the fusion of the common bile duct and pancreatic duct outside the extent of duodenal wall, with the formation of a long common channel, considered >15 mm in length (► Fig. 9).⁶ Pancreatic juice refluxes into the biliary tree, causing biliary epithelial injury, and is associated with choledochal cysts, bile duct strictures, pancreatic anomalies like divisum, and biliary malignancies.

Annular Pancreas

The annular pancreas develops because of a migration abnormality resulting from the failure of rotation of the ventral bud which consequently encases the second part of the duodenum wholly or partially.⁷ Previous cadaver-based studies have shown a prevalence of 5 to 15 cases per 1,00,000 adults,⁸ while endoscopic retrograde cholangiopancreatography-based studies have shown a prevalence of 1 in 250.⁹

It has been classified into the following two morphological types, broadly:

- Complete: Pancreatic tissue forming a complete ring around the duodenum (► Fig. 10).
- Partial (Incomplete): Incomplete encirclement, with “crocodile jaw sign” anterior and posterior extension of the pancreatic tissue relative to the second part of the duodenum.

Dorsal Pancreatic Agenesis

During embryological development, the dorsal anlage of pancreatic buds forms a portion of the head, neck, body,

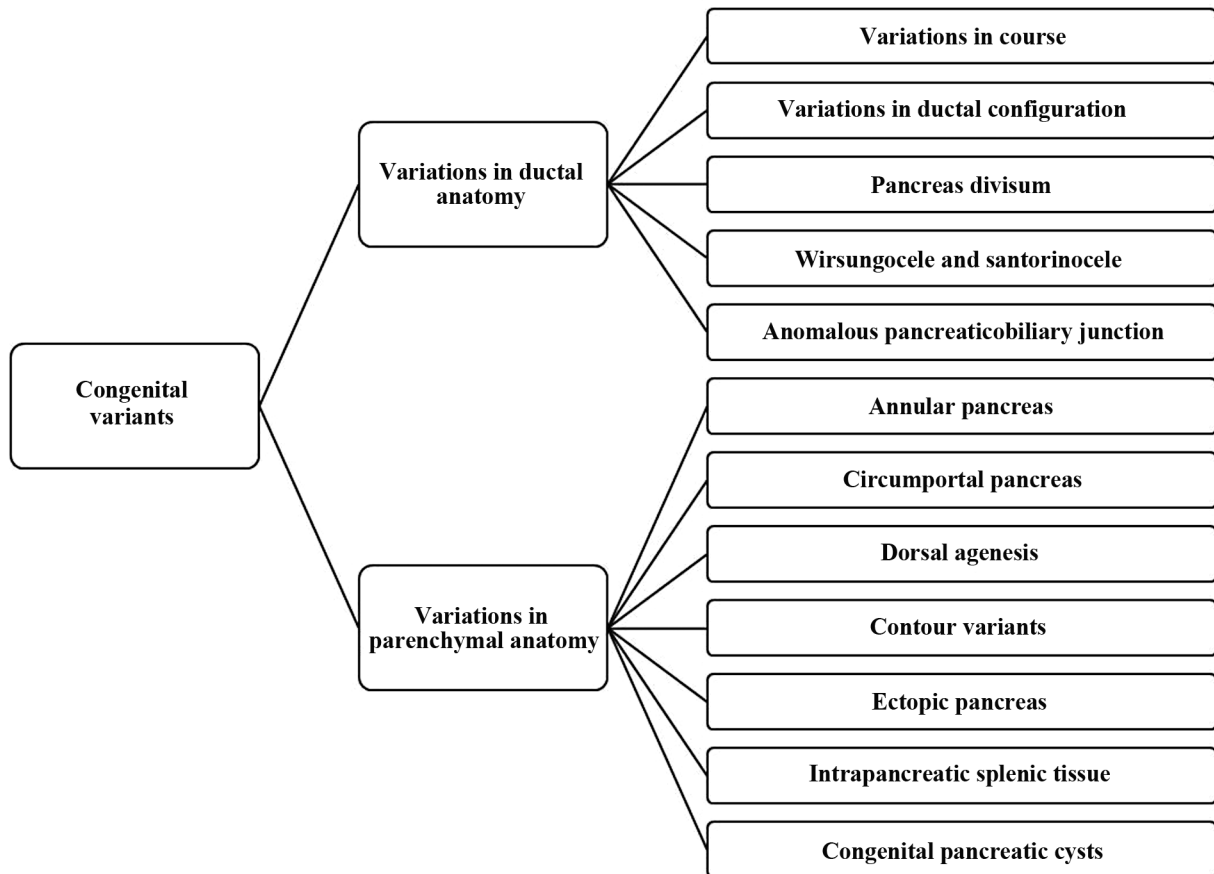


Fig. 2 Classification of congenital variants of pancreas.

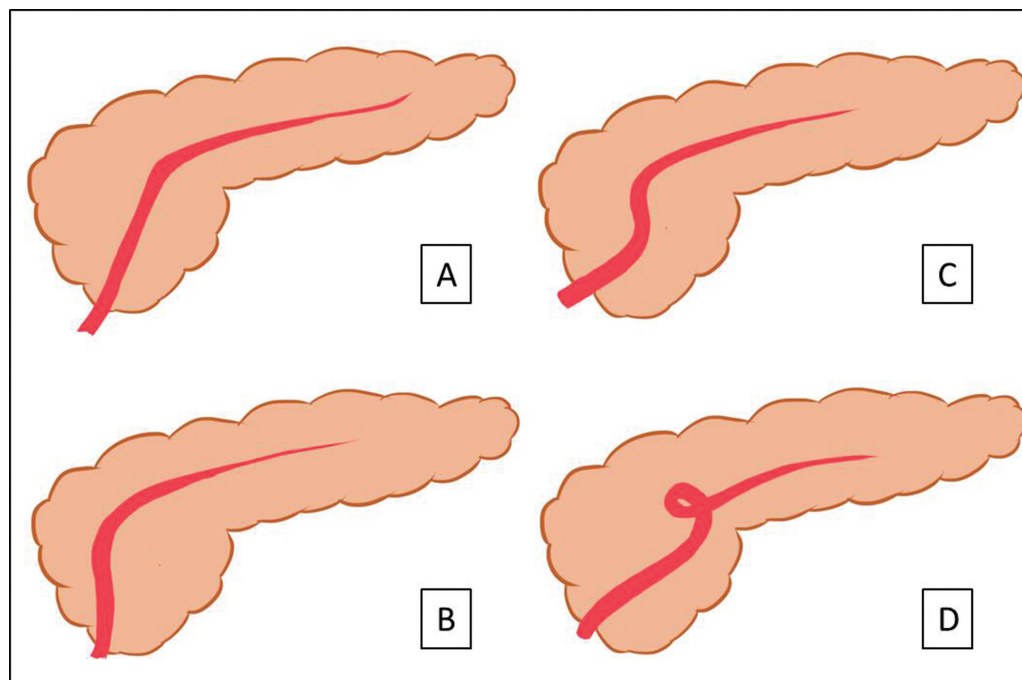


Fig. 3 Illustrations depicting types of course of main pancreatic duct. (A) Descending. (B) Vertical. (C) Sigmoid. (D) Loop.

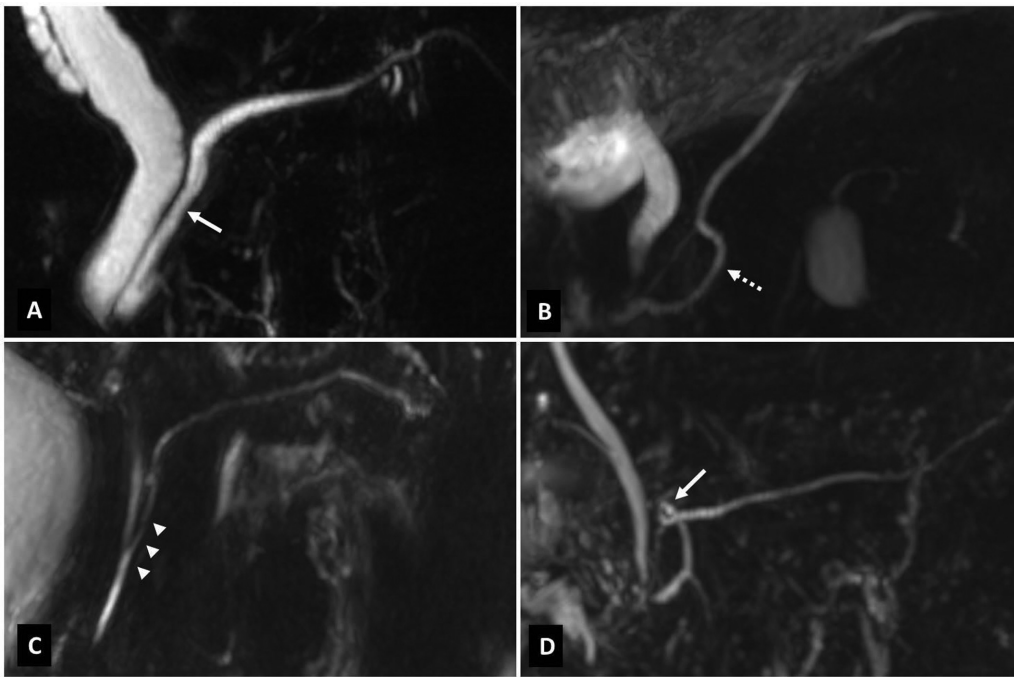


Fig. 4 Types of course of main pancreatic duct. (A) Descending course (*arrow*). (B) Sigmoid course (*dashed arrow*). (C) Vertical course (*arrowheads*) with long common channel. (D) Loop course (*arrow*)

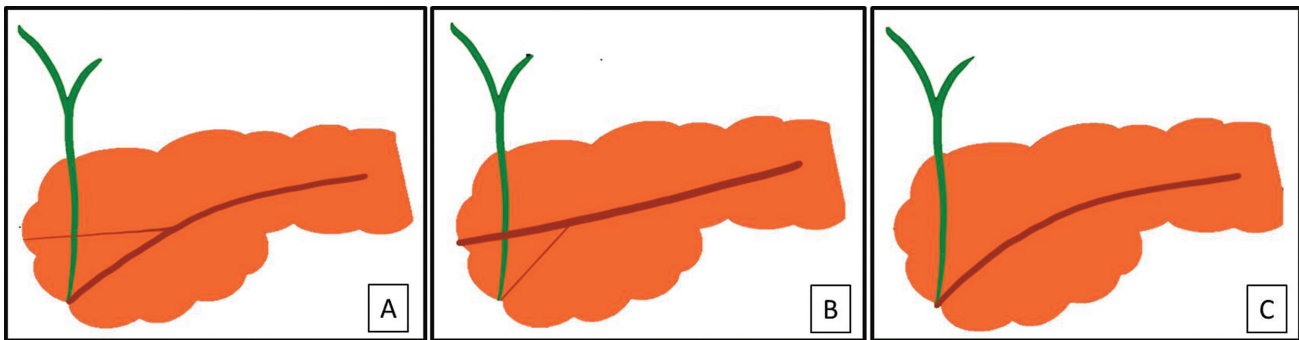


Fig. 5 Illustration showing pancreatic ductal configurations. (A) Bifid configuration with dominant duct of Wirsung. (B) Dominant duct of Santorini without divisum. (C) Absent duct of Santorini

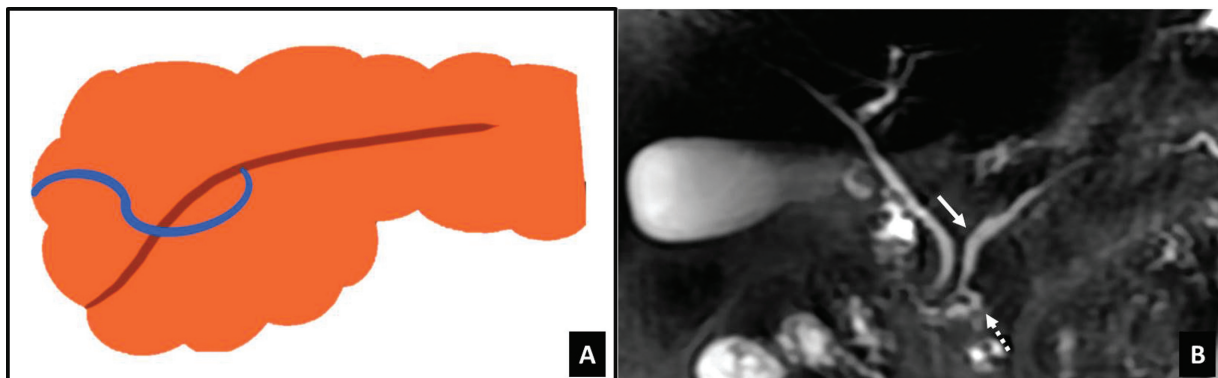


Fig. 6 Ansa pancreatica. (A) Illustration depicting minor pancreatic duct (*blue*) looping around main pancreatic duct (*brown*). (B) Coronal 3D MRCP MIP images showing ansa pancreatica (*dashed arrow*) looping around the main duct (*arrow*).

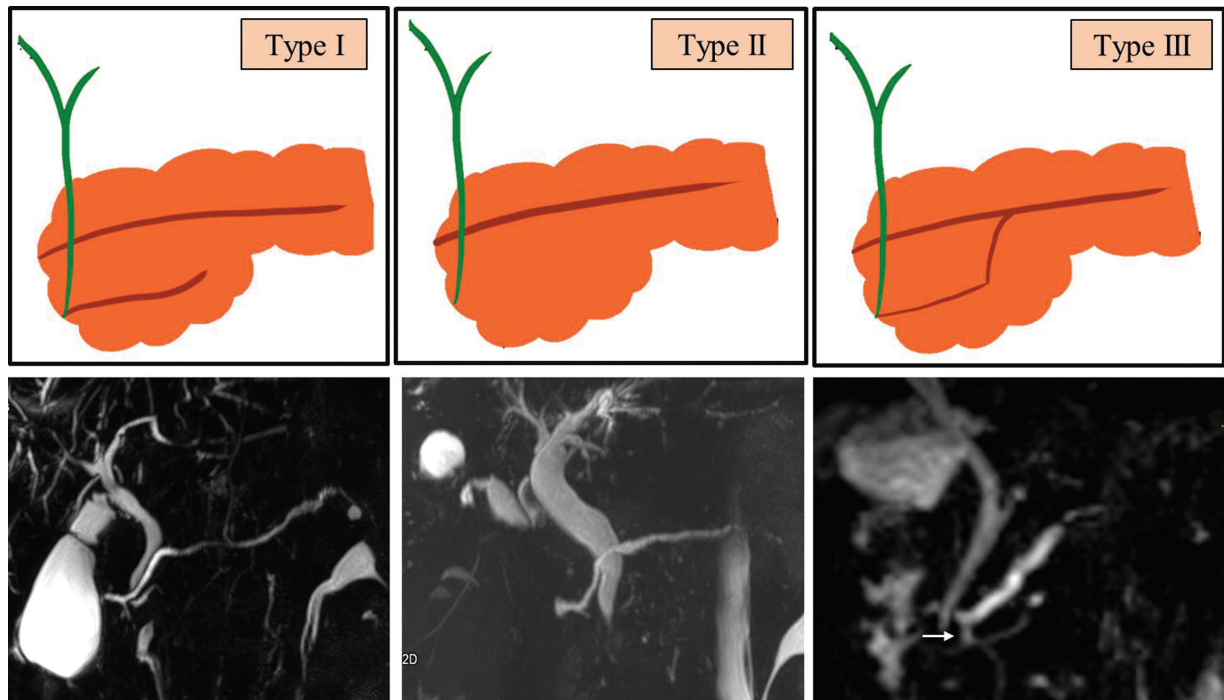


Fig. 7 Pancreas divisum. Type I: Classic PD. Type II: Absent ventral duct. Type III: Incomplete pancreas divisum with communicating duct (*arrow*).

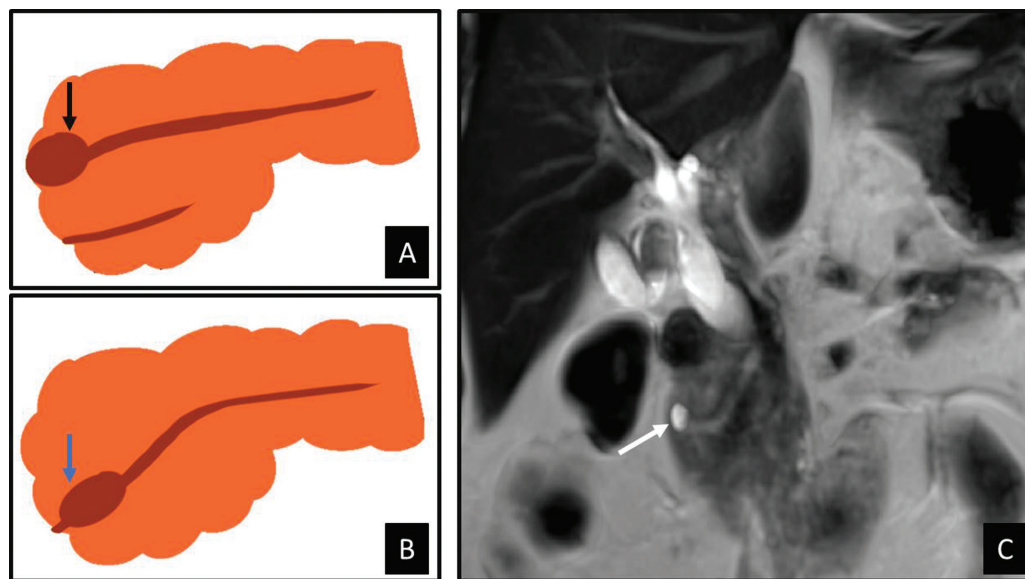


Fig. 8 (A) Illustration depicting Santorinicele (*arrow*). (B) Wirsungocele (*arrow*). (C) Coronal T2 MR showing cystic dilation of distal dorsal duct just before the minor papilla in a case of pancreas divisum.

and the tail of pancreas. Depending on the degree of nondevelopment, these structures will be absent to varying extents. An association with hepatocyte nuclear factor 1B (HNF1B) mutation has been found, which is involved in the development and differentiation of the dorsal pancreas.¹⁰

Imaging findings in partial dorsal pancreatic agenesis include an absence of pancreatic neck, body, and tail, where-

as in complete agenesis of dorsal pancreas the duct of Santorini is also absent.¹¹ A few signs have been described on imaging, namely the “dependent stomach sign” and “dependent intestine sign,” seen in dorsal pancreatic agenesis, where the normal position of the dorsal pancreas is replaced by stomach/bowel loops, which appear “dependent” on that position (► **Fig. 11**).¹²

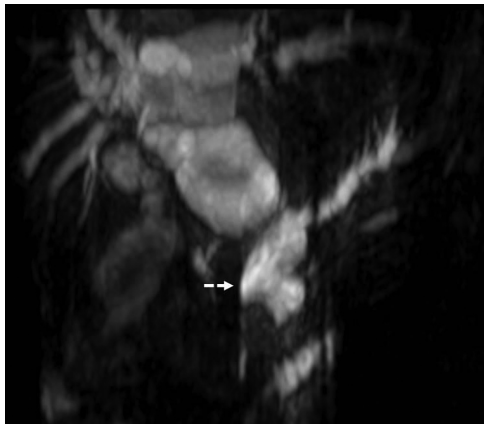

Fig. 9 Anomalous pancreaticobiliary junction. Coronal 3D MRCP MIP images showing long common channel (*dashed arrow*). The common channel, common bile duct, and the main pancreatic duct appear dilated.

Clinical relevance is the association with diabetes mellitus, as most of the endocrine β cells that produce insulin are in the dorsal pancreas.^{13,14}

Circumportal Pancreas (Portal Annular Pancreas)

It is defined as complete encasement of the portal vein above the splenoportal junction, by pancreatic parenchyma (**Fig. 12**).¹⁵ Joseph et al¹⁶ have classified portal annular pancreas into three types—Type-I: retroportal course of pancreatic duct, Type-II: associated with PD and retroportal pancreatic duct, and Type-III: anteportal course of pancreatic duct. This variation is clinically relevant in patients undergoing pancreatic head resection and at risk of developing pancreatic fistulas postoperatively.¹⁷

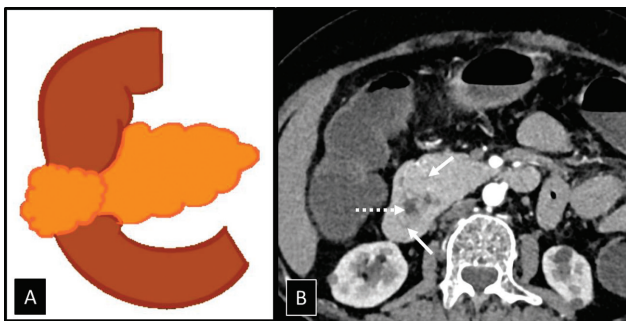


Fig. 10 Complete annular pancreas. (A) Illustration depicting annular pancreas, with pancreas completely encircling the duodenum. (B) Axial contrast enhanced CT images revealing pancreatic tissue (*arrow*) completely encircling the duodenal lumen (*dashed arrow*).

Arterial Annular Pancreas

In this extremely rare developmental anomaly, pancreatic tissue is seen to be completely encasing coursing arteries, most commonly seen with a replaced right hepatic artery.

Congenital Pancreatic Cysts

True epithelial cysts of the pancreas are exceedingly rare and usually occur with syndromic associations, such as von Hippel Lindau (most commonly), and rarely with autosomal dominant polycystic kidney disease and cystic fibrosis. Imaging wise, they are seen as simple unilocular cysts with no perceptible enhancement.

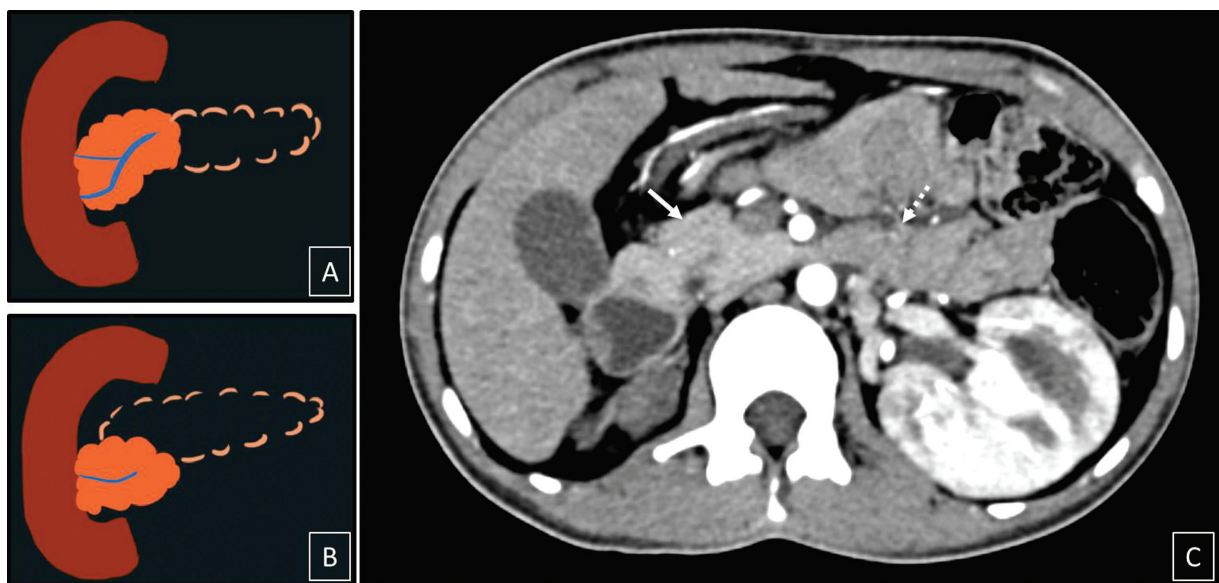


Fig. 11 Dorsal pancreatic agenesis. (A) Partial dorsal pancreatic agenesis. (B) Complete agenesis of dorsal pancreas. (C) Axial contrast enhanced CT image showing the presence of head and uncinete process (*arrow*), collapsed jejunal loops (*dashed arrow*) in a case of partial agenesis of dorsal pancreas. No dorsal pancreatic tissue visualized, giving the “dependent intestine” sign.

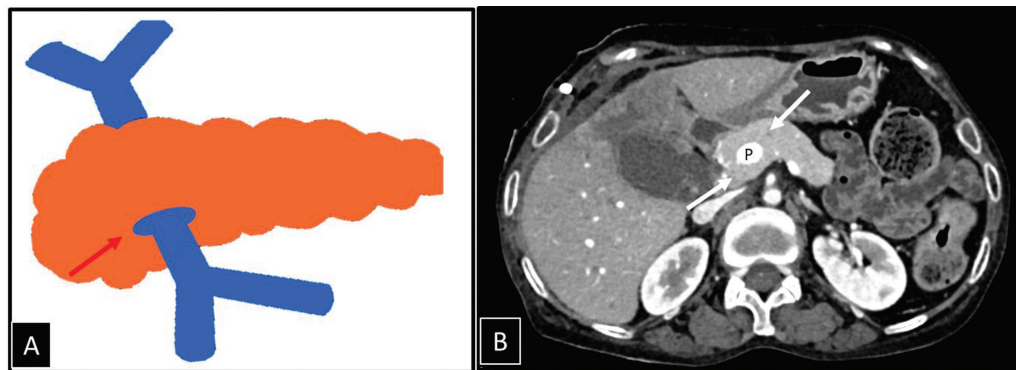


Fig. 12 Portal annular pancreas. (A) Illustration depicting encirclement of portal vein by pancreatic tissue (red arrow). (B) Axial contrast enhanced CT image showing complete encirclement of portal vein (P) by pancreatic tissue (red arrows).

Intrapancreatic Splenic Tissue

It is a type of ectopic pancreatic tissue, visualized most commonly surrounded entirely by the tail of the pancreas. They are usually incidental imaging findings, but it is essential to distinguish them from tumors or lymph nodes.¹⁸

MDCT demonstrates a hyper-enhancing nodule in the tail of pancreas, with a characteristic enhancement pattern similar to the main splenic tissue. The intrapancreatic splenic tissue can develop epidermoid cyst within it, which may be difficult to distinguish from cystic pancreatic lesions.¹⁹

Ectopic/Heterotopic Pancreatic Tissue

It is defined as the location of pancreatic tissue not within the confines of the pancreas, with a lack of any anatomic or vascular communication with the main pancreatic tissue. It is most frequently detected in stomach, duodenum, and proximal jejunum. Less common locations include Meckel diverticulum, ileum, and extremely rarely, esophagus, mediastinum, omentum, and lungs.²⁰

In barium studies, the classical appearance is that of a broad-based, smooth intramural lesion, with the typical central “umbilication.” On cross-sectional imaging, they present as intraluminal masses with endoluminal growth patterns. Depending on the type of microscopic tissue, those with more acinar structures show avid enhancement, while those with predominant ductal composition are hypoenhancing to the orthotropic pancreas.

Conclusion

The pancreas can thus demonstrate a broad spectrum of variant anatomical configurations ranging from parenchymal to ductal. Owing to the associations these entities show with conditions like recurrent acute pancreatitis, chronic abdominal pain, and neoplastic conditions like cholangiocarcinoma in anomalous pancreatico-biliary junction, their understanding and recognition are of paramount importance. Also, their ability to create a diagnostic dilemma by mimicking pathological conditions that would otherwise

require treatment cannot be undermined during diagnostic reporting.

Note

This article was previously presented at the 75th National Conference of IRIA at Amritsar and was selected as one of the 10 best posters.

Funding

None.

Conflicting Interest

None declared.

References

- Tadokoro H, Takase M, Nobukawa B. Development and congenital anomalies of the pancreas. *Anat Res Int* 2011;2011:351217
- Guerroum H, Rami A, Kassimi M, et al. Ansa pancreatica: a rare cause of acute recurrent episode in chronic pancreatitis. *BJR Case Rep* 2020;7(01):20200044
- Borghesi P, Sokhandon F, Shirkhoda A, Morgan DE. Anomalies, anatomic variants, and sources of diagnostic pitfalls in pancreatic imaging. *Radiology* 2013;266(01):28–36
- Wang DB, Yu J, Fulcher AS, Turner MA. Pancreatitis in patients with pancreas divisum: imaging features at MRI and MRCP. *World J Gastroenterol* 2013;19(30):4907–4916
- Nam KD, Joo KR, Jang JY, et al. A case of santorinicele without pancreas divisum: diagnosis with multi-detector row computed tomography. *J Korean Med Sci* 2006;21(02):358–360
- Arora A, Mukund A, Thapar S, Alam S. Anomalous pancreaticobiliary junction. *J Pediatr Gastroenterol Nutr* 2014;58(02):e13
- Aleem A, Shah H. Annular Pancreas. In: *StatPearls* [Internet]. Treasure Island, FL: StatPearls Publishing; 2023 [cited 2023 Apr 10]. Accessed October 18, 2023 at: <http://www.ncbi.nlm.nih.gov/books/NBK559236/>
- Sandrasegaran K, Patel A, Fogel EL, Zyromski NJ, Pitt HA. Annular pancreas in adults. *Am J Roentgenol* 2009;193(02):455–460
- Baggott BB, Long WB. Annular pancreas as a cause of extrahepatic biliary obstruction. *Am J Gastroenterol* 1991;86(02):224–226
- Haldorsen IS, Vesterhus M, Raeder H, et al. Lack of pancreatic body and tail in HNF1B mutation carriers. *Diabet Med* 2008;25(07):782–787

- 11 Lång K, Lasson A, Müller MF, Thorlacius H, Toth E, Olsson R. Dorsal agenesis of the pancreas—a rare cause of abdominal pain and insulin-dependent diabetes. *Acta Radiol* 2012;53(01):2–4
- 12 Lal H, Yadav P, Mourya C. Dependent stomach sign and dependent intestine sign of dorsal pancreatic agenesis. *Abdom Radiol (NY)* 2017;42(02):667–669
- 13 Schnedl WJ, Pischwanger-Soelkner C, Wallner SJ, et al. Agenesis of the dorsal pancreas and associated diseases. *Dig Dis Sci* 2009;54(03):481–487
- 14 Kapa S, Gleeson FC, Vege SS. Dorsal pancreas agenesis and polysplenia/heterotaxy syndrome: a novel association with aortic coarctation and a review of the literature. *JOP* 2007;8(04):433–437
- 15 Ishigami K, Tajima T, Nishie A, et al. The prevalence of circumportal pancreas as shown by multidetector-row computed tomography. *Insights Imaging* 2011;2(04):409–414
- 16 Joseph P, Raju RS, Vyas FL, Eapen A, Sitaram V. Portal annular pancreas. A rare variant and a new classification. *JOP* 2010;11(05):453–455
- 17 Hashimoto Y, Ross AS, Traverso LW. Circumportal pancreas with retroportal main pancreatic duct. *Pancreas* 2009;38(06):713–715
- 18 Kim SH, Lee JM, Han JK, et al. Intrapancreatic accessory spleen: findings on MR Imaging, CT, US and scintigraphy, and the pathologic analysis. *Korean J Radiol* 2008;9(02):162–174
- 19 Sonomura T, Kataoka S, Chikugo T, et al. Epidermoid cyst originating from an intrapancreatic accessory spleen. *Abdom Imaging* 2002;27(05):560–562
- 20 Rezvani M, Menias C, Sandrasegaran K, Olpin JD, Elsayes KM, Shaaban AM. Heterotopic pancreas: histopathologic features, imaging findings, and complications. *Radiographics* 2017;37:484–499