



# Patient Satisfaction of Porcelain Veneer at the Odonto-Stomatology Hospital, Vietnam

Chu Thi Quynh Huong<sup>1</sup> Trinh Dinh Hai<sup>2</sup>

<sup>1</sup>Department of Prosthodontics, Ha Noi National Hospital of Odonto-stomatology, Hoan Kiem District, Hanoi, Vietnam

<sup>2</sup>VNU School of Medicine and Pharmacy, Vietnam National University, Hanoi, Vietnam

Address for correspondence Chu Thi Quynh Huong, PhD, Department of Prosthodontics, Ha Noi National Hospital of Odonto-stomatology, Hoan Kiem District, Hanoi 100000, Vietnam (e-mail: quynhhuong@hmu.edu.vn).

Eur J Gen Dent 2024;13:25–29.

## Abstract

**Objective** The aim of this study was to study the clinical characteristics and patient satisfaction of the porcelain veneer aesthetic restoration at the Central Odonto-Stomatology Hospital, Vietnam.

**Materials and Methods** This is a cross-sectional descriptive study of 94 teeth in 12 patients with indications for glass-ceramic restorations at the Department of Prosthodontics at the Central Odonto-Stomatology Hospital during the period from July 2021 to December 2022. Porcelain veneer aesthetic restorations in patients were evaluated using FDI World Dental Federation clinical criteria for the evaluation of veneer restorations for the esthetic parameters, functional parameters, biological parameters, and reliability. The evaluation was done immediately after installation and after 3 months. Evaluation of aesthetics, function, biology, and satisfaction was done using a scale (Scale 1–5). Data were analyzed using SPSS 18 software and descriptive statistics were calculated.

**Results** It showed that the achieved results were good in terms of good to very good shape (100%) and good to very good color (98.8%). Three months after installation, the veneer restorations were stable in shape and color. The restorations were aesthetically and functionally satisfactory with no signs of broken or detachment.

**Conclusion** Porcelain veneer restorations helped to improve the tooth shape and color. The patients were satisfied with the veneer restorations.

## Keywords

- ▶ porcelain veneers
- ▶ veneer restoration
- ▶ satisfaction

## Introduction

In the past, teeth with abnormal shape and color were previously often restored with porcelain crowns that required grinding tooth tissue which resulted in weakened teeth, changing the feeling of chewing, and stimulating periodontal tissue. Veneers are substituted for a full crown with outstanding advantages: less tooth grinding saves tooth tissue, minimally invasive, intact tooth neckline, high aesthetics, good compatibility with soft tissues, sustainable in the long run.<sup>1,2</sup> Porcelain veneers have shown long-term

aesthetics,<sup>2</sup> and they also show a high survival rate with most failure cases resulting from fracture and debonding.<sup>3</sup> Ceramic materials also improve the periodontal health of patients.<sup>4</sup>

Currently, ceramic materials and technology are increasingly being improved and widely used in clinical practice with two types: oxide porcelain and glass porcelain.<sup>5–7</sup> The oxide porcelain is essentially zirconia oxide; this type is poor in light conductivity, so when indicated for front teeth are often chiseled, affecting aesthetics; moreover, they are very hard and cannot be worn and glued to tooth tissue, while the glass porcelain line that overcomes this disadvantage has the

article published online  
December 13, 2023

DOI <https://doi.org/10.1055/s-0043-1776739>.  
ISSN 2320-4753.

© 2023. The Author(s).

This is an open access article published by Thieme under the terms of the Creative Commons Attribution License, permitting unrestricted use, distribution, and reproduction so long as the original work is properly cited. (<https://creativecommons.org/licenses/by/4.0/>)

Thieme Medical and Scientific Publishers Pvt. Ltd., A-12, 2nd Floor, Sector 2, Noida-201301 UP, India

optical properties of the teeth. At present, translucent ceramic biomaterials are being developed increasing the esthetics.<sup>8-10</sup> They are natural and preserved by the chemical adhesive mechanism to increase the durability of the restoration.<sup>11</sup>

At present, glass porcelain such as Empress, Empress II, and Emax have been widely used at the Hospital of Odonto-Stomatology. But there has been no research on porcelain veneer restorations (VRs). Hence, it was important to study the clinical characteristics and patient satisfaction with the porcelain veneer aesthetic restoration in Vietnam. Therefore, the aim of this study was to study the clinical characteristics and patient satisfaction of the porcelain veneer aesthetic restoration at the Central Odonto-Stomatology Hospital, Vietnam.

## Materials and Methods

### Study Design

This is a cross-sectional descriptive study done on 94 teeth in 12 patients with indications for glass-ceramic restorations at the Department of Prosthodontics at the Central Odonto-Stomatology Hospital during the period from July 2021 to December 2022. Ethical approval was taken from the Ethics Committee of the Central Odonto-Stomatology Hospital (Approval number 1298/QD-BVRHMTW). Three researchers asked the questions with patients and evaluated the results. Patients voluntarily participated in the study and the patient information is kept confidential.

### Study Subjects

Patients who were indicated for porcelain VRs for various causes at the Department of Prosthetics, Central Hospital of Odonto-Stomatology were included in the study. Exclusion criteria included teeth with contraindications to porcelain veneers, patients with bad habits affecting prosthetics, and patients who do not cooperate or cannot be re-examined.

### Study Details

Following the patient examination, pictures were taken and marked. Initial casts were poured and wax-up was done in the casts. Then, mock-up simulations were done on the patient's mouth. Grinding and preparing teeth to make veneers were done as needed. Temporary restorations were made and inserted. Following the preparation of the final veneers from the dental laboratory, they were inserted in the patients and cemented using resin cement.

Porcelain veneer aesthetic restorations in patients were evaluated using FDI World Dental Federation clinical criteria<sup>12</sup> for the evaluation of VRs for the esthetic parameters, functional parameters, biological parameters, and reliability. Following items were used in terms of aesthetic, biological, and functional parameters.

### Aesthetics

- Natural color, similar to real teeth, in harmony with neighboring teeth.
- Surface gloss is similar to neighboring tooth enamel.

- The shape and size of the teeth are harmonious and commensurate with the neighboring teeth

## Biology

- Healthy gum line, rosy, natural color of the tooth neck area.
- Pillar teeth are not sensitive when chewing.

## Function

Restore chewing function and bite.

- Assessment of occlusion restoration: the occlusion must ensure the conditions in two states:

+ Bite in static state:

Touch evenly at the central occlusion. Overbite and overbite are within allowable limits.

+ Bite in dynamic state:

Instructions to bring the lower jaw forward with the participation of the incisors. When sliding the lower jaw forward until the head touches the head with many touching teeth, the back teeth disengage. Moving the jaw to the sides is guided by the canine teeth properly and does not cause trauma.

The occlusal restoration is both static and dynamic.

- Evaluate chewing function: The patient chews normally and does not have food pulled when using the scanner.
- The crown fits tightly to the finished line of the tooth base
- Good contact point with neighboring teeth.

## Patient Satisfaction with Treatment Results

Assessed by interviewing the patient immediately after tooth installation, after 3 months of follow-up, with a set of questions according to Sulaya and Guttal.<sup>13</sup>

1. How do you evaluate the chewing ability of your restoration?
2. How do you evaluate the color match of your restoration?
3. How do you evaluate the appearance of your restoration?
4. How would you rate the comfort of your restoration?

### Assessment

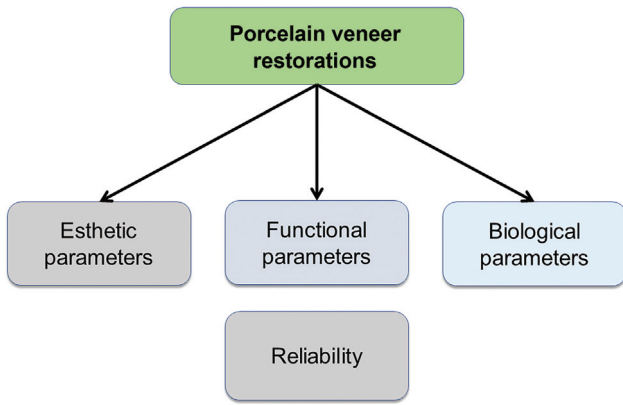
Evaluation of aesthetics, function, biology, and satisfaction was done (► Fig. 1) using a scale: Very good—good—average—poor—very poor = 5–4–3–2–1. The evaluation was done immediately after installation and after 3 months.

### Statistical Analysis

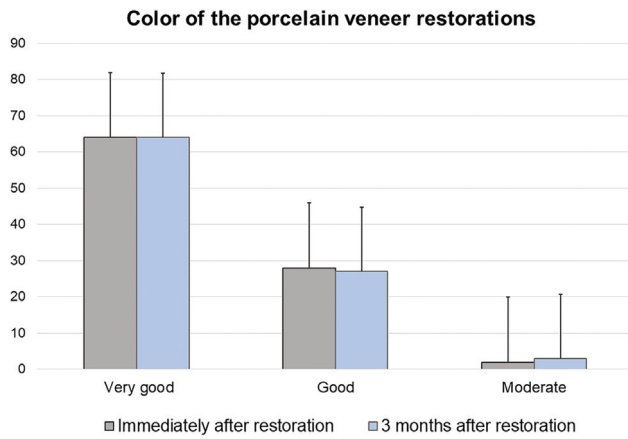
Data were analyzed using SPSS 18 software and descriptive statistics were calculated and compared. The results were compared using an independent *t*-test at a significant level at *p*-value = 0.05.

## Results

The demographic details of the study are shown in ► Table 1. The results of the assessment of porcelain VR immediately



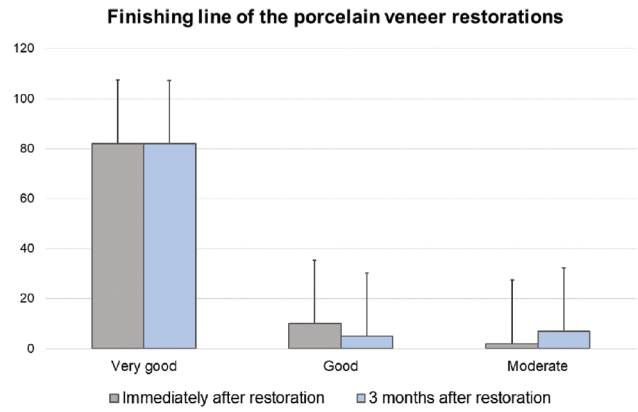
**Fig. 1** Study parameters of the veneer restorations; esthetic parameters, functional parameters, biological parameters, and reliability.



**Fig. 2** Results of the color of the porcelain veneer restorations.

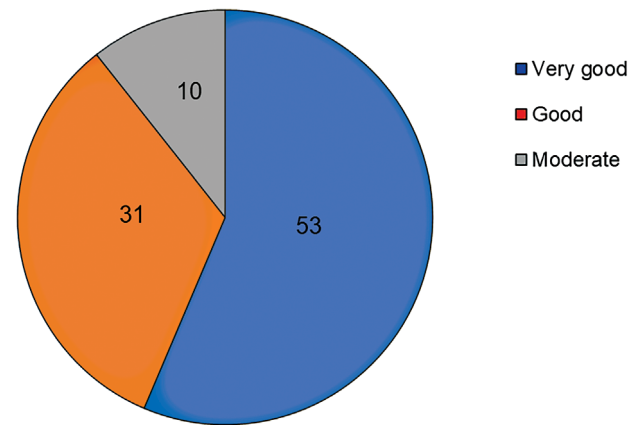
after the insertion were as follows: very good (83%) and good (17%). The results of color assessment immediately after the insertion were very good (64; 68.1%), good (28; 29.8), and moderate (2; 2.1%), whereas the results after 3 months were very good (64; 68.1%), good (27; 28.7), and moderate (3; 3.2%) (► Fig. 2). The results were no significant differences between immediately after the insertion and after 3 months ( $p$ -value >0.05).

The tightness of the finishing line of the VR was very good in both immediate insertion and after 3 months (87.3%). There was a decrease in the good level from 10 to 5% and a



**Fig. 3** Results of the finishing line of the porcelain veneer restorations.

**Porcelain veneer color stability and restoration contour after 3 months of insertion**



**Fig. 4** Results of the veneer color stability and restoration contour.

decrease in the moderate level from 2 to 7% in immediate insertion and after 3 months (► Fig. 3).

At 3 months of insertion, the results of the surface color stability and contour were very good 53 (56.4%), good 31 (33%), and moderate 10 (10.6%) (► Fig. 4). In addition, there was no change in physical structure 3 months after the insertion.

For the lateral contact and food intake results, the very good results were similar immediately after the insertion and at 3 months after the insertion (70.2%). And there was a slight difference in the good and moderate results (► Fig. 5).

**Table 1** The demographic detail of the study

Age	Gender				Total	
	Male		Female		Number	Percentage
	Number	Percentage	Number	Percentage		
< 30	1	8.3	2	16.7	3	25
30–50	2	16.7	7	58.3	9	75
<b>Total</b>	<b>3</b>	<b>25</b>	<b>9</b>	<b>75</b>	<b>12</b>	<b>100</b>

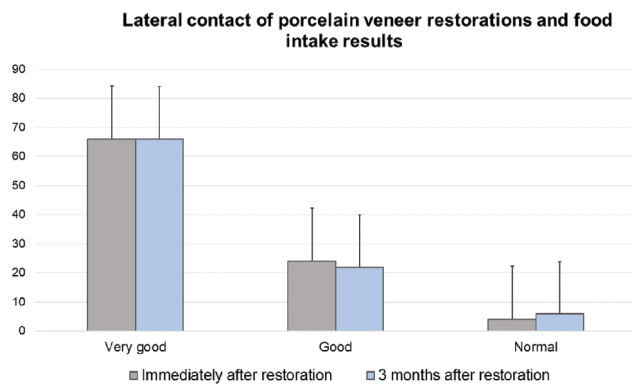


Fig. 5 Evaluation of lateral contact and food intake results.

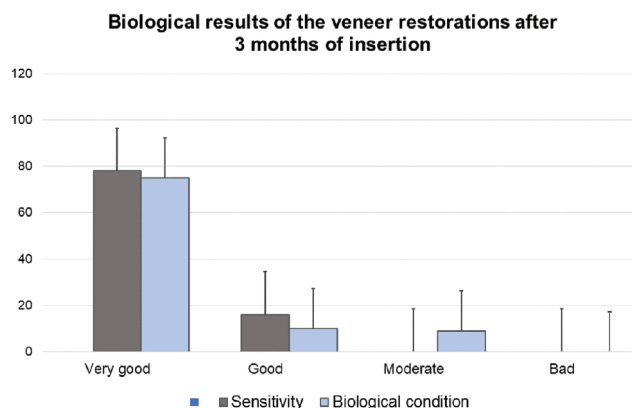


Fig. 6 Evaluation of biological results after 3 months.

The result of biological evaluation after 3 months of insertion of the VRs showed significant differences in the sensitivity between very good, good, and moderate/bad ( $p$ -value  $<0.01$ ; ►Fig. 6). Good conditions showed no differences between good and moderate.

►Fig. 7 shows the overall results of the porcelain VRs immediately after the insertion and 3 months after the insertion. The majority of the results show good results 82.2% immediately after the insertion and 76% 3 months after the insertion. There are no bad results.

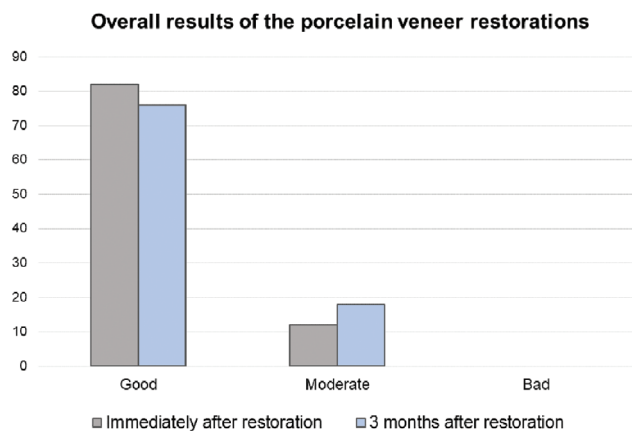


Fig. 7 Overall results according to the two evaluation time points.

Patient satisfaction with the veneer restoration treatments

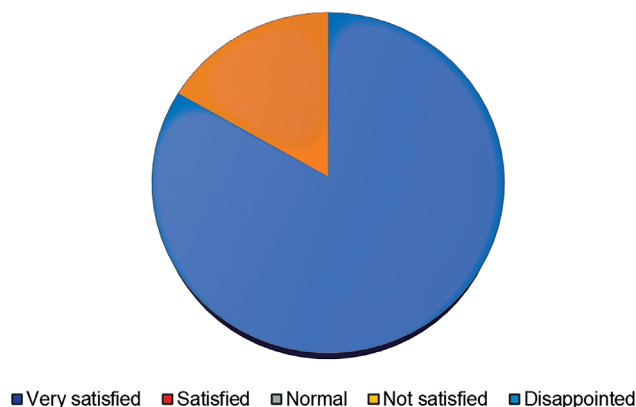


Fig. 8 Evaluation of patient satisfaction with treatment results.

Patient satisfaction is shown in ►Fig. 8. It showed that 83.3% of the patients were very satisfied and 16.7% were satisfied following the porcelain veneer treatment.

### Discussion

The porcelain VRs achieve good esthetic results with a more balanced harmony.<sup>3,9</sup> At present various newer ceramic biomaterials are being developed with various treatment modalities to produce esthetic results.<sup>2,10</sup> Our aim of this study was to study the clinical characteristics and patient satisfaction of the porcelain veneer aesthetic restoration at the Central Odonto-Stomatology Hospital, Vietnam. The overall results were very good, and the patients were satisfied with the porcelain VRs.

VRs can restore the teeth shape and color. In this study, immediately after insertion, the abnormal shape of the original teeth was covered with veneer producing esthetic results with very good assessment accounting for 83%. Porcelain veneers with good shape create contact between adjacent teeth to achieve horizontal stability for the dental arch and bring the patient's esthetics. Porcelain veneers can restore teeth colors, such as in fluorosis, and mild tetracycline contamination. In our study, the majority of the veneer restored the esthetic tooth color (68.1%) immediately after the restoration and at 3 months of the restoration. In one patient, there was tetracycline staining of teeth, and at 3 months of re-examination, there was a phenomenon of discoloration from the restoration edge, the average result (increased) was 3.2%, and the good results decreased by 1.1%. Therefore, when choosing the adhesive, it is necessary to adhere to the step of coating with an antioxidant after attaching and polishing carefully. The closer the adhesive surface is to the thin layer of cement, the less disintegration will be reduced of cement.<sup>14</sup> Furthermore, in this study, the surface color adhesion and restoration margins are mostly good and very good to ensure a good restoration border after attaching the restoration. It is necessary to completely clean the excess cement

and polish carefully with porcelain polishing tips to minimize gingivitis and color adhesion at the edge of the restoration.

For the restored teeth, the finishing line is under the gum to cover the stained color of the teeth, the restorative teeth due to gap or bad shape, and the finishing line is under the gum when making restorations.<sup>4</sup> During the cementation of the prosthesis, it is ensured a tight fit, and excess cement is removed to avoid causing gingivitis. Mandibular teeth are often difficult in finishing and grinding as the lower teeth are often small in size and often have a very narrow shape in the neck area, so technicians when designing machining often lack porcelain in this area.

Meijering et al<sup>1</sup> also studied to measure the satisfaction of patients with respect to the aesthetics of VRs and to identify potential factors influencing their satisfaction with three different types (direct composite, indirect composite, and porcelain) placed on anterior teeth. They found that at baseline the overall satisfaction was 76%; after 2 years this was 78%. At 2-year evaluation patients with porcelain, VRs were more satisfied than those with direct composite VRs ( $p$ -value <0.05).

The evaluation of the durability of the VRs must be done after a long time of follow-up; however, due to the limited time of the study, we could only evaluate it after 3 months of treatment. This is one of the limitations of this study because the research was conducted in the early stages of the coronavirus disease 2019 epidemic, so the number of patients was not enough. In this study with a total of 94 teeth performed for 12 patients, we did not detect any cases of broken, cracked, or broken porcelain. Therefore, the durability of the restoration is 100% in both groups of incisors, canines, and premolars. Over time, the patient's occlusion can change, hence regular follow-up is necessary.

## Conclusion

Porcelain VRs are less invasive esthetic restorations and help to improve the tooth shape and color. The patients were satisfied with the porcelain VRs.

### Conflicts of Interest

None declared.

## Acknowledgments

The authors would like to acknowledge the Department of Prosthodontics at the Central Odonto-Stomatology Hospital for the conduction of this research.

## References

- 1 Meijering AC, Roeters FJ, Mulder J, Creugers NH. Patients' satisfaction with different types of veneer restorations. *J Dent* 1997;25(06):493–497
- 2 Strassler HE. Minimally invasive porcelain veneers: indications for a conservative esthetic dentistry treatment modality. *Gen Dent* 2007;55(07):686–694, quiz 695–696, 712
- 3 Monaraks R, Leevailoj C. The longevity of ceramic veneers: clinical evaluation of mechanical, biologic and aesthetic performances of ceramic veneers, a 7-year retrospective study. *J Dent Assoc Thai* 2018;68(03):288–301
- 4 Srimaneepong V, Heboyan A, Zafar MS, et al. Fixed prosthetic restorations and periodontal health: a narrative review. *J Funct Biomater* 2022;13(01):15
- 5 Bajraktarova-Valjakova E, Korunoska-Stevkovska V, Kapusevska B, Gigovski N, Bajraktarova-Misevska C, Grozdanov A. Contemporary dental ceramic materials, a review: chemical composition, physical and mechanical properties, indications for use. *Open Access Maced J Med Sci* 2018;6(09):1742–1755
- 6 Vaiani L, Boccaccio A, Uva AE, et al. Ceramic materials for biomedical applications: an overview on properties and fabrication processes. *J Funct Biomater* 2023;14(03):146
- 7 Zhou M, Zhang X, Zhang Y, et al. Construction of nanostructured glass-zirconia to improve the interface stability of dental bilayer zirconia. *Nanomaterials (Basel)* 2023;13(04):678
- 8 Kongkiatkamon S, Booranasophone K, Tongtaksin A, Kiatthana-korn V, Rokaya D. Comparison of fracture load of the four translucent zirconia crowns. *Molecules* 2021;26(17):5308
- 9 Jurado CA, Villalobos-Tinoco J, Watanabe H, Sanchez-Hernandez R, Tsujimoto A. Novel translucent monolithic zirconia fixed restorations in the esthetic zone. *Clin Case Rep* 2022;10(03):e05499
- 10 Lee YK. Translucency of dental ceramic, post and bracket. *Materials (Basel)* 2015;8(11):7241–7249
- 11 Shi HY, Pang R, Yang J, et al. Overview of several typical ceramic materials for restorative dentistry. *BioMed Res Int* 2022;2022:8451445
- 12 Hickel R, Peschke A, Tyas M, et al. FDI World Dental Federation: clinical criteria for the evaluation of direct and indirect restorations-update and clinical examples. *Clin Oral Investig* 2010;14(04):349–366
- 13 Sulaya K, Guttal SS. Clinical evaluation of performance of single unit polyetheretherketone crown restoration-a pilot study. *J Indian Prosthodont Soc* 2020;20(01):38–44
- 14 Zhao J, Gao X, Chen S, Lin H, Li Z, Lin X. Hydrophobic or superhydrophobic modification of cement-based materials: a systematic review. *Compos B Eng* 2022;243:110104