




Biliary Ablation for Sectoral Duct Injury to Avoid Surgery

Almamoon I. Justaniah¹  Sami Boshnaq²

¹Radiology Department, King Faisal Specialist Hospital & Research Center, Jeddah, Saudi Arabia

²Department of Radiology, Annoor Specialist Hospital, Makkah, Saudi Arabia

Address for correspondence Almamoon I. Justaniah, MD, Vascular & Interventional Radiologist, Radiology Department, King Faisal Specialist Hospital & Research Center, 21499 Jeddah, Saudi Arabia (e-mail: ajustaniah@kfshrc.edu.sa).

Arab J Intervent Radiol 2024;8:43–45.

Abstract

Keywords

- ▶ sectoral duct
- ▶ biliary injuries
- ▶ ablation
- ▶ sclerotherapy
- ▶ interventional radiology
- ▶ bile leak
- ▶ percutaneous transhepatic biliary drainage

Bile duct injury is a common and serious complication of both laparoscopic and open cholecystectomy. The conventional treatment for isolated bile duct injury is hepaticojejunostomy or hepatectomy. We present a case of biliary leak from an isolated right posterior sectoral duct after cholecystectomy treated with percutaneous sclerotherapy using alcohol. Approval and consent waiver were obtained from the Institutional Review Board (IRB 2023-CR-18).

Introduction

Bile duct injury is a common and serious complication of both laparoscopic and open cholecystectomy. The conventional treatment for isolated bile duct injury is hepaticojejunostomy or hepatectomy. We present a case of biliary leak from an isolated right posterior sectoral duct (RPSD) after cholecystectomy treated with percutaneous sclerotherapy using alcohol. Approval and consent waiver were obtained from the Institutional Review Board (IRB 2023-CR-18).

Case Presentation

A 29-year-old female underwent cholecystectomy for acute calculus cholecystitis. On day 13 after cholecystectomy, she developed abdominal pain and fever. A computerized tomography scan of the abdomen, followed by magnetic resonance cholangiopancreatography, revealed a large perihepatic fluid collection extending to the gallbladder bed (**Fig. 1**). The

patient was referred to interventional radiology (IR) and the fluid was drained yielding bilious contents. An endoscopic retrograde cholangiopancreatography failed to identify the leak or the right posterior bile ducts, suggesting injury and clipping of the RPSD (**Fig. 2**). Therefore, an external percutaneous transhepatic biliary drainage (PTBD) was placed in the right posterior ducts to drain the system, which demonstrated a central leak from the RPSD (**Fig. 3**).

The patient improved clinically with no more abdominal pain or fever. There was no output from the perihepatic drain. A 1-week follow-up ultrasound of the liver demonstrated resolution of the collection; hence, the perihepatic drain was removed. However, the PTBD output was about 500 mL/day. Right posterior hepatectomy was offered to the patient to cease the biliary output and remove the PTBD. Due to the presence of an isolated RPSD injury, bile duct repair or hepaticojejunostomy was not offered.

As an alternative option to surgery, biliary sclerotherapy was suggested by IR to induce biliary fibrosis, diminish bile production, and limit bile output to allow for PTBD removal.

article published online
December 27, 2023

DOI <https://doi.org/10.1055/s-0043-1777269>.
ISSN 2542-7075.

© 2023. The Author(s).

This is an open access article published by Thieme under the terms of the Creative Commons Attribution License, permitting unrestricted use, distribution, and reproduction so long as the original work is properly cited. (<https://creativecommons.org/licenses/by/4.0/>)

Thieme Medical and Scientific Publishers Pvt. Ltd., A-12, 2nd Floor, Sector 2, Noida-201301 UP, India

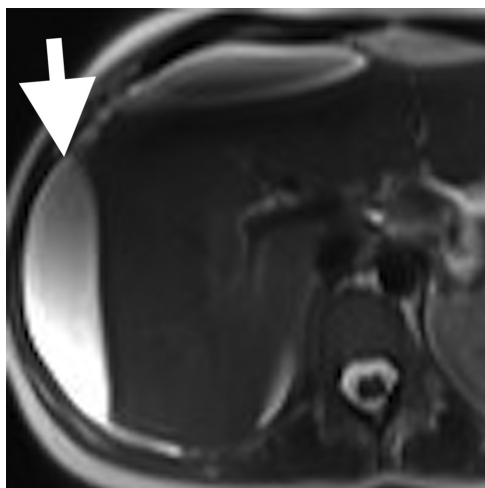


Fig. 1 Axial T2-weighted image at the level of the liver demonstrating perihepatic fluid (arrow). No intrahepatic ductal dilation.

Through the existing PTBD, a cholangiogram was performed under local anesthesia. A 5 mL of 1% lidocaine was injected and left to dwell for 5 minutes. The lidocaine was drained and a 5 mL mixture of absolute alcohol and contrast (80% alcohol) was slowly injected through the catheter under fluoroscopic guidance. The mixture was left to dwell for 15 minutes, then drained. The PTBD was flushed with saline and connected to a drainage bag.

Six similar additional sessions were performed at 2-week interval with gradual decrease in biliary output. After the seventh session, the output decreased to less than 25 mL/day. On the eighth and final session, a cholangiogram was performed demonstrating small, irregular right posterior hepatic ducts with strictures and no leak, consistent with central healing and ducts fibrosis (→**Fig. 4**). Therefore, the PTBD was removed. The patient was asymptomatic during the treat-

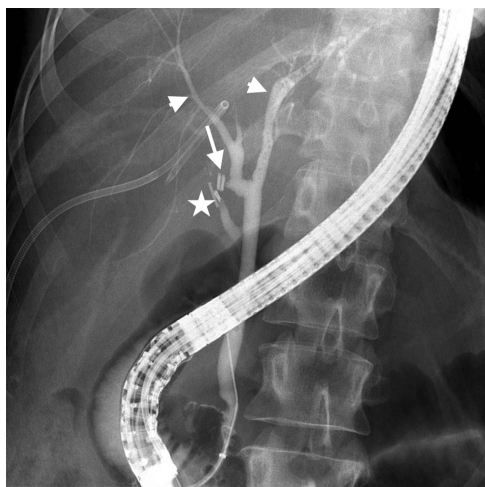


Fig. 2 Frontal radiograph of the abdomen during endoscopic retrograde cholangiopancreatography demonstrating contrast in the left and right anterior hepatic ducts (arrowheads). Note the surgical clips on the cystic duct (star), and at the site of the right posterior sectoral duct (arrow). Lack of visualization of the leak and the right posterior ducts due to clipping.

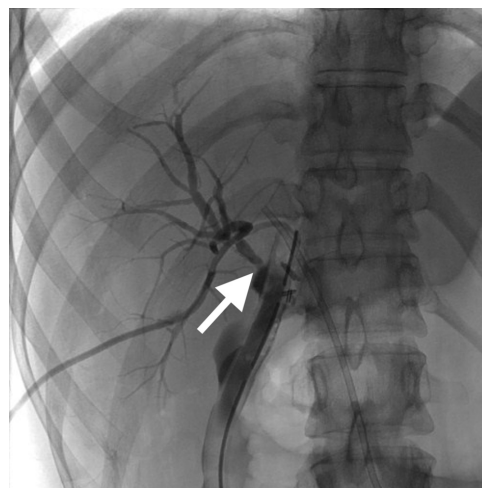


Fig. 3 Percutaneous transhepatic cholangiogram demonstrating the site of leak from an isolated right posterior sectoral duct (arrow). Lack of visualization of the right anterior and left ducts.

ment period and throughout the 2-year clinical follow-up visits. The patient refused cross-sectional follow-up imaging.

Discussion

Isolated bile duct injury can occur from the misidentification of aberrant right hepatic ducts. During laparoscopic cholecystectomy, common bile duct (CBD) injury and clipping can occur if the CBD is mistaken for the cystic duct. However, when anatomical variants or aberrant ducts are present, the right hepatic duct is at an increased risk for injury. Low insertion of the right sectoral hepatic duct, either into the CBD or at the cystic duct, is an important variant that places this duct at risk of injury during laparoscopic cholecystectomy. The conventional treatment for bile duct injury is hepaticojejunostomy or hepatectomy.

Few case reports have addressed the percutaneous management approach. Those reports used various ablative materials, such as fibrin, acetic acid, ethanol, and

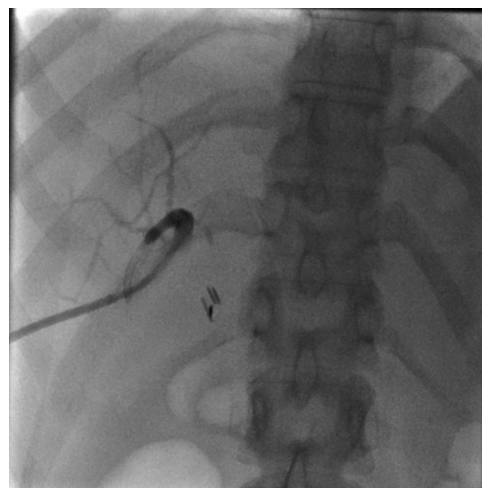


Fig. 4 Percutaneous transhepatic cholangiogram during the final session demonstrating small, irregular right posterior hepatic ducts with strictures and no leak, consistent with fibrosis.

glue.¹⁻³ The goal of ablation is to cause permanent injury of the biliary epithelium through necrosis that subsequently results in decreased biliary secretion and eventually atrophy of the affected segmental duct. Compensatory hypertrophy may ensue in the noninfused segments. Several sessions of chemical ablation may be required to eliminate the bile production from the affected segment. In some patients, a single injection might be enough to treat the biliary leak.⁴ If multiple sessions are needed, it is advised to perform the sessions at an interval of several days to avoid complications. Possible complications of biliary duct ablation with alcohol include failure, cholestasis, cholangitis, and abscess formation. Anti-inflammatory medications can be prescribed to patients who develop pain or low-grade fever.²

Conclusion

In conclusion, for certain cases of biliary injuries, chemical biliary ablation can help induce biliary fibrosis to prevent

bile leak, recurrent cholangitis, and avoid long standing PTBDs or further surgeries.

Conflict of Interest

None declared.

References

- 1 Park JI, Choi Y-K, Jung BH. Acetic acid sclerotherapy for treatment of biliary leak from an isolated right posterior sectoral duct after cholecystectomy. *Ann Surg Treat Res* 2017;92(04):221–224
- 2 Sasaki M, Hori T, Furuyama H, et al. Postoperative biliary leak treated with chemical bile duct ablation using absolute ethanol: a report of two cases. *Am J Case Rep* 2017;18:871–877
- 3 Rokni Yazdi H, Borhani A, Rasuli B, Kianoush S, Rafeian S, Jafarian A. Percutaneous transhepatic N-butyl cyanoacrylate injection therapy of an isolated bile duct associated with a bronchobiliary fistula. *J Vasc Interv Radiol* 2016;27(06):930–932
- 4 Miraglia R, Maruzzelli L, Caruso S, et al. Single-session percutaneous alcohol sclerotherapy for the treatment of isolated draining intrahepatic biliary duct in a five-month-old liver transplant recipient. *Diagn Interv Radiol* 2012;18(03):326–329