



# Transjugular Intrahepatic Portosystemic Shunt (TIPS) Extension for Transhepatic Mesocaval Shunt Creation: A Case Series for Treating Refractory Upper Gastrointestinal Bleeding in Patients with Chronic Portal Vein Thrombosis

Yashwant Patidar<sup>1</sup> Sushant Babbar<sup>1</sup> Amar Mukund<sup>1</sup> Shiv Kumar Sarin<sup>2</sup>

<sup>1</sup>Department of Intervention Radiology, Institute of Liver and Biliary Sciences, New Delhi, India

<sup>2</sup>Department of Hepatology, Institute of Liver and Biliary Sciences, New Delhi, India

Address for correspondence Yashwant Patidar, MBBS, MD, Department of Intervention Radiology, Institute of Liver and Biliary Sciences, New Delhi 110070, India (e-mail: dryashwantpatidar@gmail.com).

Indian J Radiol Imaging 2024;34:335–341.

## Abstract

Transjugular intrahepatic portosystemic shunt (TIPS) is known to benefit patients with decompensated liver disease by alleviating portal pressure. However, TIPS creation is technically difficult and challenging to perform in patients with chronic portal vein thrombosis (PVT) (4,5). Multiple endovascular techniques for portal vein recanalization with or without creating portosystemic shunt are available to decompress and alleviate portal hypertension in patients with PVT. In this case series, we represent TIPS extension to create an endovascular mesocaval shunt for the treatment of refractory upper gastrointestinal bleeding.

## Keywords

- ▶ mesocaval shunt
- ▶ PVR TIPS
- ▶ chronic PVT
- ▶ portal hypertension

## Introduction

Transjugular intrahepatic portosystemic shunt (TIPS) is performed to alleviate complications of portal hypertension<sup>1–3</sup> such as refractory ascites, refractory variceal bleeding, and hepatic hydrothorax by reducing portal pressure.<sup>4</sup> Portal vein thrombosis (PVT) was regarded as a contraindication for TIPS procedures. However, this notion has evolved, and PVT is no longer an absolute contraindication. Nonetheless, performing TIPS in the presence of PVT can present technical challenges.<sup>5,6</sup> The prevalence of PVT in cirrhotic patients is quite variable depending on the diagnostic modality used. According to Italian Venous Thrombotic Events Registry (PRO-LIVER) prospective multicenter study, which included consecutive cirrhotic patients who underwent portal vein

Doppler ultrasound over 2 years, PVT was detected in 17% patients.<sup>7</sup> Various options other than TIPS available to patients having refractory portal hypertension secondary to cirrhosis are percutaneous creation of an extrahepatic mesocaval shunt, surgical mesocaval shunt creation, and liver transplant, but the creation of a surgical shunt may be limited due technical or anatomical reasons.

Here we discussed three patients with the thrombosed portal vein (PV) without cavernous transformation presented with recurrent massive upper gastrointestinal (UGI) bleeding treated with endovascular mesocaval shunt creation and simultaneous coiling of the large gastric varices. All patients were given options of liver transplant and counseled regarding possible exclusion from liver transplant feasibility post procedurally, but they were unwilling to go for surgical

article published online  
December 15, 2023

DOI <https://doi.org/10.1055/s-0043-1777321>.  
ISSN 0971-3026.

© 2023. Indian Radiological Association. All rights reserved.  
This is an open access article published by Thieme under the terms of the Creative Commons Attribution-NonDerivative-NonCommercial-License, permitting copying and reproduction so long as the original work is given appropriate credit. Contents may not be used for commercial purposes, or adapted, remixed, transformed or built upon. (<https://creativecommons.org/licenses/by-nc-nd/4.0/>)  
Thieme Medical and Scientific Publishers Pvt. Ltd., A-12, 2nd Floor, Sector 2, Noida-201301 UP, India

treatment. Institutional review board approval was not required.

### Case 1

The patient is a 57-year-old female of Indian origin with hepatitis C virus-associated chronic liver disease. She presented with reduced appetite and increased fatigue accompanied by increased frequency of episodes of hematemesis (5 episodes in 7 months), biweekly paracentesis due to recurrent ascites, and increased jaundice detected on routine lab investigations. History includes chronic PVT Yerdel's grade III, and multiple sessions (5 sessions) of endoscopic ligation of esophageal varices because of refractory UGI bleeding. A preprocedure computed tomography (CT) scan shows features of portal hypertension with large esophageal and gastric varices and chronically occluded PV (measuring up to 6.5 mm) with small periportal collaterals. Pertinent laboratory values included hemoglobin—9.2, bilirubin—1.3, platelet  $61 \times 10^9/L$ , creatinine—0.56, urea—14, international normalized ratio (INR)—1.62. Child-Turcotte-Pugh score was 8 (Class B) and model of end-stage liver disease (MELD) score of 16. The patient was referred to the interventional radiology department for salvage TIPS. TIPS was attempted at authors institute; however, the procedure was unsuccessful because of the inability to negotiate guidewire across the chronically thrombosed PV.

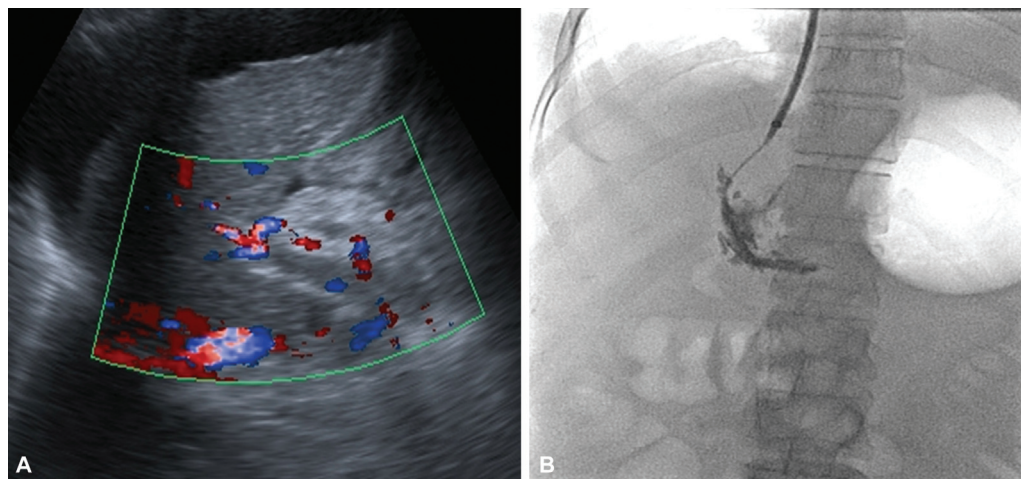
Multiple alternatives such as liver transplant and surgical shunt were considered. However, chances of mortality and morbidity were considerably high. So, second attempt was given for creating TIPS with subtle modification in technique and to extend TIPS into superior mesenteric vein (SMV) if need be creating mesocaval shunt.

Under sedation, right internal jugular vein (IJV) was punctured under ultrasound guidance and 10 Fr TIPS sheath was advanced into the right hepatic vein (►Fig. 1). Intrahepatic puncture using Colapinto needle was done from the right hepatic vein to main PV just at its bifurcation under

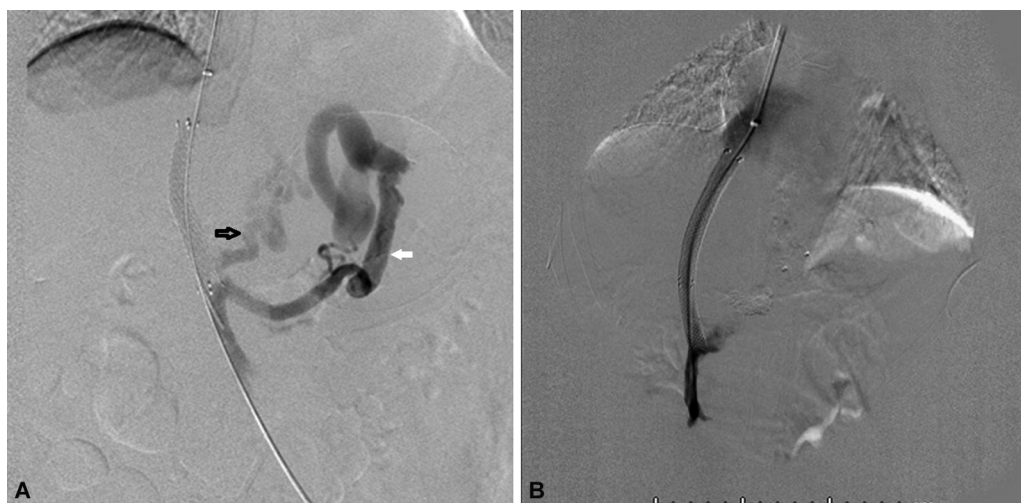ultrasound guidance and 0.0035" guidewire was advanced that went into the large left gastric afferent vein. The main difference in the technique was to have a more straight puncture targeting main PV near bifurcation rather than intrahepatic right portal vein branch that helped hydrophilic wire (straight tip) to be negotiated in a more straight path across the thrombotic segment. Venogram showed complete PVT with large afferent from the left gastric vein, posterior gastric, and short gastric vein to gastroesophageal varices. Mechanical thrombectomy and balloon dilatation were attempted to recanalize PV but the clot remained adherent. First covered stent graft was placed extending from the lower main PV near the splenoportal axis covering the ostium of the left gastric vein to inferior vena cava (IVC) that extended across the thrombus along with antegrade coil and glue embolization of posterior gastric and short gastric vein; however, flow across shunt was not established due to persistent thrombus in PV. Another uncovered stent was placed extending from SMV proximal part to IVC. Combination of stent deployed such that the uncovered portion extended into the SMV but allowed flow through the interstices from the splenic vein (►Fig. 2). Pre-procedure hepatic venous pressure gradient—24 (33–9 mm Hg), direct spleno portal (SP) axis pressure—33, IVC pressure—9 and postprocedure gradient of 9 (20–11), and SP axis/distal end stent—20 and IVC—11. Post-procedure venogram and follow-up CT scan showed a patent shunt and disappearance of the gastric varices. The patient remains asymptomatic at 6 years follow-up with the patent shunt without any need of anticoagulation (►Fig. 3).

### Case 2

A 53-year-old female patient presented with a history of incidentally diagnosed hepatitis B on medical management, with multiple episodes of hematemesis in the past 3 years, and had undergone endoscopic variceal ligation. Pertinent laboratory findings include hemoglobin—9.2, platelet— $87 \times 10^9/L$ , INR—1.43, creatinine—0.48, Child-Turcotte-Pugh



**Fig. 1** (A) Preprocedure Doppler showing complete portal vein thrombosis. (B) Portal venogram taken after obtaining transjugular venous access under ultrasonography guidance showing complete thrombosis. Note can be made of inflated Sengstaken–Blakemore tube.



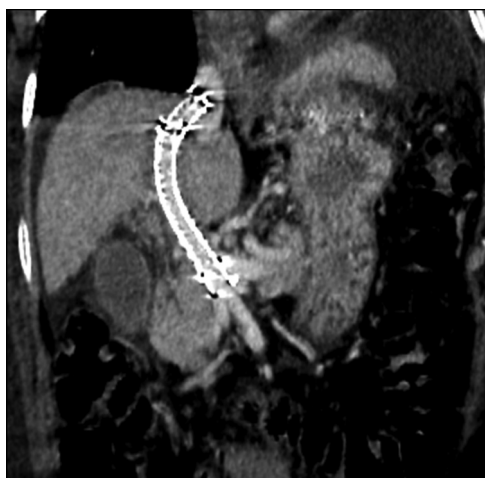**Fig. 2** (A) Venogram after placement of covered stent covering left gastric vein (LGV) (black arrow) showed persistent hepatofungal flow and opacification of gastroesophageal varices via LGV and posterior gastric vein (arrows). (B) Venogram post coil embolization and mesocaval shunt placement showing hepatopetal flow with opacification of shunt.

class B, and MELD score of 10. Contrast-enhanced CT scan showed changes of cirrhosis with PVT, multiple esophageal and gastric varices, and a lienorenal shunt. The patient was referred to the intervention radiology department for TIPS because of recurrent UGI bleeding. Right IJV was punctured under ultrasound guidance and 10 Fr TIPS sheath was inserted into the right hepatic vein. Using similar technique access to the main PV was gained through hepatic parenchyma under ultrasonography (USG) guidance. Portal venogram showed complete thrombus of main PV (Yerdel's grade III) with extension into SMV with shunting of blood to gastrorenal shunt. The covered stent (10mm) was deployed followed by antegrade plug and coil-assisted embolization of the large gastric varices with N-butyl cyanoacrylate. PV balloon venoplasty was done; however, clot remained adherent with poor flow seen across the TIPS, following which another uncovered stent was placed extending from proxi-

mal SMV to IVC. Combination of stent deployed such that the uncovered portion extended into the SMV but allowed flow through the interstices that were balloon dilated from the splenic vein. Postprocedure check venogram revealed good flow from mesocaval shunt with obliteration of the gastric varices (→ Fig. 4). Postprocedure mid stent pressure measures 10 mm Hg. Postprocedure follow-up on day 1, day 3, day 28, and day 60 and 1 year reveal patent shunt with no recurrent episodes of UGI bleeding. The patient is on follow-up.

### Case 3

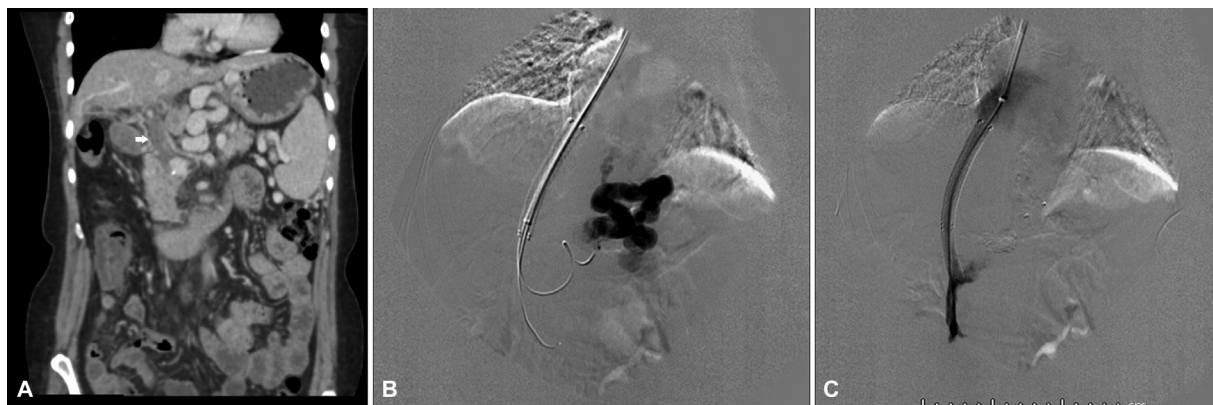A 49-year-old male patient with Nonalcoholic Steatohepatitis (NASH)-related cirrhosis, and multiple episodes of hematemesis in the past 1 year had undergone endoscopic variceal ligation. Multiphasic CT scan showed changes of cirrhosis with PVT (Yerdel's grade III), multiple esophageal and gastric varices, and lienorenal shunt. The patient was referred to the intervention radiology department for TIPS in view of refractory UGI bleeding and malena. Extended TIPS/mesocaval shunt was done with antegrade plug assisted embolization of the large gastric varices with N-butyl cyanoacrylate. In a similar manner as described above, postprocedure follow-up on day 1, day 3, day 28, and day 60 and 6 months reveal patent shunt with no recurrent episodes of UGI bleeding. Patient is on follow up.



**Fig. 3** Follow-up at 1 year showing patent stent with PSV of 140 cm/s on ultrasonography doppler. Contrast-enhanced computed tomography shows wall-to-wall opacification of mesocaval shunt.

### Discussion

The effectiveness of TIPS in managing adverse effects stemming from portal hypertension has been well-documented, showcasing remarkable outcomes.<sup>8</sup> Nevertheless, as the severity of PVT increases, the technical success rate of TIPS creation tends to decline. This decline in success is especially prominent in cases of complete chronic thrombosis. As an alternative approach, the creation of a mesocaval shunt, with or without portal vein recanalization (PVR), emerges as a



**Fig. 4** (A) Contrast-enhanced computed tomography shows complete portal vein thrombosis. (B) Covered stent placement extending from hepatic vein–inferior vena cava junction to main portal vein with antegrade coil and plug embolization of varices. (C) Overlapping uncovered stent placement extending to create mesocaval shunt.

feasible option for these patients. However, PVR TIPS has been defined as deployment of short length TIPS stent that does not cover the main PV as defined by Salem et al.<sup>9</sup> In instances where the flow through main PV is not well established, stent needs to be extended into SMV or splenic vein depending upon the extent of thrombus.

Stent extension into SMV becomes essential in cases where little or no flow is seen from SMV into shunt even after repeated recanalization attempts that predispose to early TIPS dysfunction/ thrombosis. Though stent extension into SMV makes future liver transplantation more complex, nonresolving extensive SMV thrombus precludes the possibility of liver transplantation. To circumvent the complexity of future transplant options in patients requiring extension of TIPS, it is proposed, additional uncovered stent extending from SMV to confluence can be deployed along with TIPS with a segment of stent free PV of approx. 2 cm that can be used by transplant surgeon; however, authors do not have personal experience and studies are warranted to assess for technical feasibility of the procedure.

Several methodologies have been documented for establishing a mesocaval shunt in situations where PV cannulation cannot be accomplished or extensive PV thrombosis less likely to respond from conventional PVR TIPS. (► **Table 1**)

Mesocaval shunt was first described in 1996 by Nyman et al,<sup>10</sup> who under CT guidance targeted retrieval basket placed in IVC traversing transverse colon and SMV and then a stent was placed under fluoroscopic guidance and wire was removed.

In another case report, Bercu et al<sup>14</sup> were able to approach transabdominally without perforating the bowel and relied on fluoroscopic guidance for visualization of anatomy during the procedure.

Hong et al<sup>12</sup> reported three cases of mesocaval shunt placement using intravascular ultrasound. The major drawback is nonavailability of intravascular US at many centers and the stent being extrahepatic there is an increased risk of migration.

Creating transvenous access between the hepatic vein and portal system proves to be the most challenging stage in

performing TIPS. Conventional methods of PV localization using wedge hepatic portography using carbon dioxide, contrast portography via direct percutaneous PV access, and delayed phase imaging after an arterial SMA angiogram<sup>16</sup> may not be very helpful in completely thrombosed PV.

To overcome the challenge of thrombosed PV cannulation, USG/CT guidance can be employed to assist in the precise insertion of a Colapinto needle into the thrombosed segment of the PV. Subsequently, a guidewire can be carefully threaded into either the SMV or splenic vein. If attempts to recanalize the PV are unsuccessful, the next course of action may involve the placement of a mesocaval shunt. Another technique for PV recanalization involves transsplenic access, where a guidewire is advanced as far as possible into the thrombosed PV, acting as a fiducial marker to target the PV. The wire can then be snared through the transjugular route.

Of all the approaches described in the literature for the creation of mesocaval shunt, few cases of sharp needle recanalization of thrombosed PV with Colapinto needle and subsequent placement of mesocaval shunt have been described. Though technically challenging, the potential benefit of this approach as compared to previously published case reports is reduced risk of infection, bleeding, and perforation peritonitis when using trascolonic,<sup>10</sup> transgastric<sup>11</sup> route, and being a partially intrahepatic shunt, it has fewer chances of shunt migration. Most importantly, the long-term follow in our cases at 2 years showed a patent stent with no recurrence of symptoms.

## Conclusion

The transjugular approach for mesocaval shunt placement is a viable technique in cases of chronic PVT and effectively reduces portal hypertension. However, additional studies are needed to assess the effectiveness and safety of mesocaval shunt procedures, both with and without variceal embolization.

**Table 1** Summary of previous case reports of mesocaval shunt creation

Age/sex	Clinical history	Imaging guidance	Technical approach	Clinical outcome	References
37/M	Idiopathic chronic PVT	CT and fluoroscopy	Transcolonic	Thrombosis (+) <sup>a</sup>	Nyman et al <sup>10</sup>
	Recurrent massive variceal bleeding			Recurrent variceal bleeding (-)	
	Failed prior surgical shunt attempts			Follow-up period: 14 months	
57/M	Metastatic CRC with multiple metastastectomies	CT and fluoroscopy	Transgastric	Thrombosis (+) <sup>b</sup>	Moriarty et al <sup>11</sup>
	Extrahepatic PVT			Recurrent variceal bleeding (+) <sup>b</sup>	
	Failed TIPS attempt			Follow-up period: 3 months	
16/F	Chronic PVT	Fluoroscopy and IVUS	Endovascular	Thrombosis (-)	Hong et al <sup>12</sup>
	Recurrent GI bleeding		Side-firing IVUS probe	Recurrent variceal bleeding (-)	
	Failed previous splenorenal shunt			Follow-up period: 11 months	
60/F	HCC with PV obliteration due to tumor thrombi	Fluoroscopy and IVUS	Endovascular	Thrombosis (-)	Hong et al <sup>12</sup>
	Failed variceal banding		Side-firing IVUS probe <sup>c</sup>	Recurrent variceal bleeding (-)	
				Follow-up period: 10 months	
55/M	Pancreatic teratoma S/P whipple OP	Fluoroscopy and IVUS	Endovascular	Thrombosis (-)	Hong et al <sup>12</sup>
	Segmental occlusion of SMV		Side-firing IVUS probe	Recurrent variceal bleeding (-)	
	Failed endoscopic clipping			Follow-up period: 3 months	
13/M	Extrahepatic portal vein occlusion	CT	Transabdominal	Thrombosis (-)	Burke et al <sup>13</sup>
	Failed surgical shunt attempt			Recurrent variceal bleeding (-)	
	Retroperitoneal rhabdomyosarcoma S/P surgical resection and RT			Follow-up period: 18 months	
58/F	C-viral cirrhosis with recurrent ascites	Fluoroscopy	Transabdominal	Thrombosis (-)	Bercu et al <sup>14</sup>
	Portal vein and SMV thrombosis			Recurrent variceal bleeding (-)	

(Continued)

**Table 1** (Continued)

Age/sex	Clinical history	Imaging guidance	Technical approach	Clinical outcome	References
	Failed previous splenorenal shunt and TIPS attempt			Follow-up period: 3 months	
N/A	Cirrhosis PVT (+)	CT and fluoroscopy	Transabdominal	N/A	Davis et al <sup>15</sup>
53/F	Chronic PVT Hepatitis C related cirrhosis	Fluoroscopy and USG	Transjugular	Thrombosis (–) Recurrent variceal bleeding (–) Follow-up period: 6 years	Present case
56/F	Hepatitis B related cirrhosis Chronic PVT	Fluoroscopy and USG	Transjugular	Thrombosis (–) Recurrent variceal bleeding (–) Follow-up period: 1 year	Present case
49 /M	Nash related cirrhosis Chronic PVT	Fluoroscopy and USG	Transjugular	Thrombosis (–) Recurrent variceal bleeding (–) Follow-up period: 6 months	Present case

Abbreviations: CRC, colorectal cancer; GI, gastrointestinal; HCC, hepatocellular carcinoma; IVUS, intravascular ultrasound; N/A, not available; OP, operation; POD, postoperative day; PV, portal vein; PVT, portal vein thrombosis; RT, radiation therapy; SMV, superior mesenteric vein; S/P, status post; TIPS, transjugular intrahepatic portosystemic shunt.

<sup>a</sup>Thrombosis occurred at POD #1, which was fully recanalized by balloon embolectomy. 12-month follow-up angiography revealed thrombotic occlusion of the second mesocaval shunt, but patient did not have recurrent symptoms and no further intervention was performed, <sup>b</sup>Angiography at 24 hours was performed due to recurrent GI bleeding revealing total thrombotic occlusion of the mesocaval shunt. Failure of recanalization led to a second mesocaval shunt creation, <sup>c</sup>Uncinate process of pancreas was traversed without significant complications, <sup>d</sup>Minor lower GI bleeding recurred at 9 months follow-up, but shunt patency was confirmed for 24 months.

Reprinted with modification from: Yonsei Med J. 2018 Jan;59(1):162-166.

#### Funding

None.

#### Conflict of Interest

None declared.

#### References

- Rössle M, Haag K, Ochs A, et al. The transjugular intrahepatic portosystemic stent-shunt procedure for variceal bleeding. *N Engl J Med* 1994;330(03):165–171
- Salerno F, Cammà C, Enea M, Rössle M, Wong F. Transjugular intrahepatic portosystemic shunt for refractory ascites: a meta-analysis of individual patient data. *Gastroenterology* 2007;133(03):825–834
- Zheng M, Chen Y, Bai J, et al. Transjugular intrahepatic portosystemic shunt versus endoscopic therapy in the secondary prophylaxis of variceal rebleeding in cirrhotic patients: meta-analysis update. *J Clin Gastroenterol* 2008;42(05):507–516
- Qi X, Yang M, Fan D, Han G. Transjugular intrahepatic portosystemic shunt in the treatment of Budd-Chiari syndrome: a critical review of literatures. *Scand J Gastroenterol* 2013;48(07):771–784
- Senzolo M, Tibbals J, Cholongitas E, Triantos CK, Burroughs AK, Patch D. Transjugular intrahepatic portosystemic shunt for PVT with and without cavernous transformation. *Aliment Pharmacol Ther* 2006;23(06):767–775
- Wils A, van der Linden E, van Hoek B, Pattynama PM. Transjugular intrahepatic portosystemic shunt in patients with chronic portal vein occlusion and cavernous transformation. *J Clin Gastroenterol* 2009;43(10):982–984
- Violi F, Corazza GR, Caldwell SH, et al; PRO-LIVER Collaborators. Portal vein thrombosis relevance on liver cirrhosis: Italian Venous Thrombotic Events Registry. *Intern Emerg Med* 2016;11(08):1059–1066
- Eesa M, Clark T. Transjugular intrahepatic portosystemic shunt: state of the art. *Semin Roentgenol* 2011;46(02):125–132
- Salem R, Vouche M, Baker T, et al. Pretransplant portal vein recanalization-transjugular intrahepatic portosystemic shunt in patients with complete obliterative portal vein thrombosis. *Transplantation* 2015;99(11):2347–2355

- 10 Nyman UR, Semba CP, Chang H, Hoffman C, Dake MD. Percutaneous creation of a mesocaval shunt. *J Vasc Interv Radiol* 1996;7(05):769-773
- 11 Moriarty JM, Kokabi N, Kee ST. Transvenous creation of a mesocaval shunt: report of use in the management of extrahepatic portal vein occlusion. *J Vasc Interv Radiol* 2012;23(04):565-567
- 12 Hong R, Dhanani RS, Louie JD, Sze DY. Intravascular ultrasound-guided mesocaval shunt creation in patients with portal or mesenteric venous occlusion. *J Vasc Interv Radiol* 2012;23(01):136-141
- 13 Burke C, Taylor AG, Ring EJ, Kerlan RK Jr. Creation of a percutaneous mesocaval shunt to control variceal bleeding in a child. *Pediatr Radiol* 2013;43(09):1218-1220
- 14 Bercu ZL, Sheth SB, Noor A, et al. Percutaneous mesocaval shunt creation in a patient with chronic portal and superior mesenteric vein thrombosis. *Cardiovasc Intervent Radiol* 2015;38(05):1316-1319
- 15 Davis J, Chun AK, Borum ML. Could there be light at the end of the tunnel? Mesocaval shunting for refractory esophageal varices in patients with contraindications to transjugular intrahepatic portosystemic shunt. *World J Hepatol* 2016;8(19):790-795
- 16 Wenz F, Nemcek AA Jr, Tischler HA, Minor PL, Vogelzang RL. US-guided paraumbilical vein puncture: an adjunct to transjugular intrahepatic portosystemic shunt (TIPS) placement. *J Vasc Interv Radiol* 1992;3(03):549-551