




Two Uncommon Cases of Pediatric Transethmoidal–Transnasal Encephaloceles with a Review of Literature

Abhijit Acharya¹  Satya Bhusan Senapati¹ Souvagya Panigrahi¹ Rama Chandra Deo¹
A. K. Mahapatra¹

¹ Department of Neurosurgery, IMS and SUM Hospital, Bhubaneswar, Odisha, India

Indian J Neurosurg

Address for correspondence Abhijit Acharya, MCh, Department of Neurosurgery, IMS and SUM Hospital, Bhubaneswar, Odisha 751029, India (e-mail: abhijitkirtika@gmail.com).

Abstract

Encephaloceles are defined as the herniation of brain matter beyond the confines of the skull bone through a defect on the cranium or face. The encephaloceles are classified into different categories as per onset as congenital or traumatic, as per contents as meningocele, meningoencephalocele, and hydromeningoencephalocele, and as per anatomical location into frontoethmoid, basal, occipital, and cranial vault. Transethmoidal encephalocele is a rare type of encephalocele with a very few patients reported in the literature to date. We are presenting two cases of transethmoidal–transnasal encephalocele in the pediatric age group with one being congenital and other traumatic in onset. The first child presented with a mass visible inside the nasal cavity since birth with nasal obstruction. The second child presented with a history of trauma 5 years back followed by occasional cerebrospinal fluid leak, fever, and nasal stuffiness. Both patients underwent craniotomy and excision of the encephalocele with repair of the defect in the cribriform plate. These two uncommon cases highlight the different onsets of the disease successfully managed surgically.

Keywords

- Encephaloceles
- cranial defects
- image-guided neurosurgery
- neurosurgery

Introduction

Encephaloceles are herniations of brain matter that can occur secondary to trauma or a cranial lesion, while the majority are congenital and caused by failure of neural tube closure.¹ Those who remain undiagnosed at birth present later with complications like nasal obstruction, cerebrospinal fluid (CSF) leak, meningitis, and visual abnormalities.^{1,2} The incidence of encephaloceles in live births is around 1/3000 to 1/10000, of which the transethmoidal encephaloceles comprise among the rarest.³ And, hereby, we report two cases with the above-mentioned rare clinical presentations of transnasal encephaloceles with two different etiologies, presented to our department within 6 months, followed by appropriate neurosurgical management and recovery.

Case 1

A 4-year-old child presented with a visible mass in his right-side nasal cavity, noticed since birth by his mother while feeding but ignored due to the absence of any other significant difficulties or symptoms associated. He was now brought to us due to gradually aggravating episodes of nasal blockage with occasional right frontal headache. The boy achieved his normal milestones as per age and vaccinated as per schedule. He had no motor or sensory deficit. There was no visible swelling over the forehead or nasal bridge. There was a globular mass visible inside the right nasal cavity (► **Fig. 1A**). There was no hypertelorism seen in the boy. He underwent a computed tomography (CT) brain followed by a plain magnetic resonance imaging (MRI) brain

DOI <https://doi.org/10.1055/s-0043-1777348>.
ISSN 2277-954X.

© 2024. The Author(s).

This is an open access article published by Thieme under the terms of the Creative Commons Attribution License, permitting unrestricted use, distribution, and reproduction so long as the original work is properly cited. (<https://creativecommons.org/licenses/by/4.0/>)
Thieme Medical and Scientific Publishers Pvt. Ltd., A-12, 2nd Floor, Sector 2, Noida-201301 UP, India

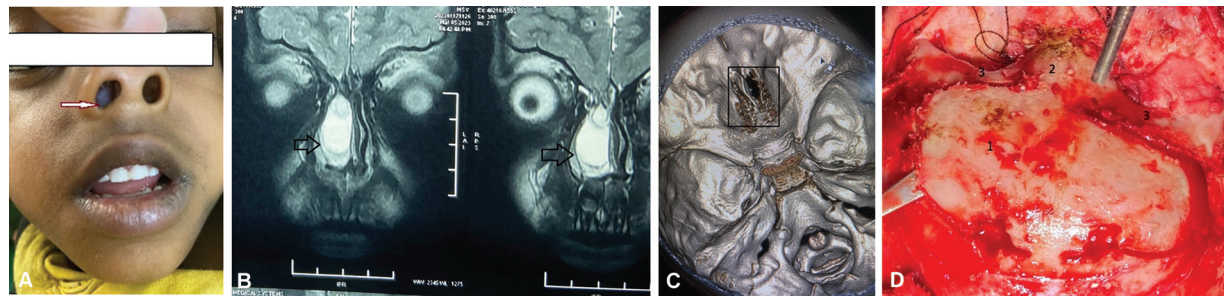


Fig. 1 (A) The nasal component of the encephalocele appears like a globular mass visible inside the Rt nasal cavity. (B) MRI brain showing a trans-ethmoid trans-nasal encephalocele. (C) CT brain which was suggestive of a defect in the ant skull base. (D) Craniotomy and repair of the defect (1) Frontal bone (2) Nasal bone (3) Supraorbital ridge.

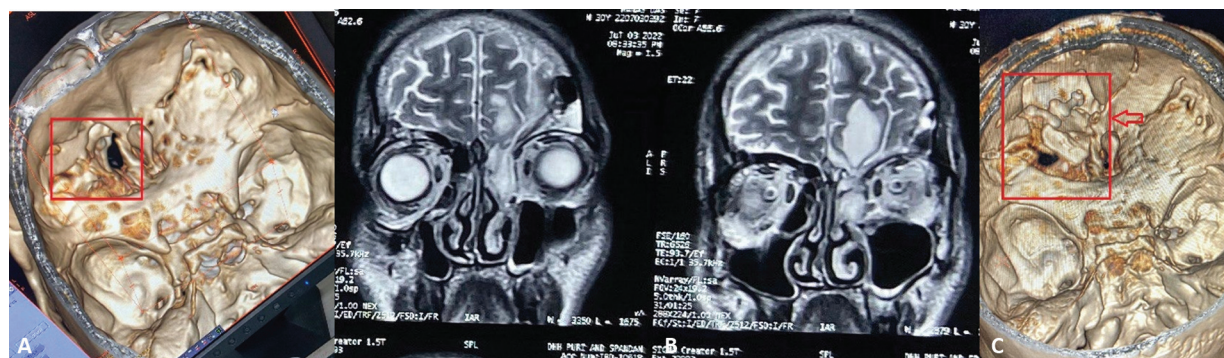


Fig. 2 (A) Bony defect in the antero lateral ethmoid bone (over the cribriform plate). (B) MRI brain showing transnasal herniation of the brain through the defect. (C) Single-stage repair of the defect with a bony strut used to close the defect.

that showed a transtethmoid–transnasal encephalocele (►**Fig. 1B**) with a bony defect in the anterolateral ethmoid bone (over the cribriform plate) (►**Fig. 1C**). After necessary investigations, the patient underwent a single-stage encephalocele repair with craniotomy and defect repair (►**Fig. 1D**). The postoperative period was uneventful with discharging the child in postoperative day 7 (POD 7).

Case 2

This patient was a 16-year-old child with a history of a road traffic accident 5 years back with occasional CSF leaks and features of fever and meningitis that always resolved with antibiotics. There was no other associated motor or sensory deficit in the patient. The patient underwent a CT brain that was suggestive of a defect in the anterior skull base (►**Fig. 2A**) and an MRI brain showing transnasal herniation of the brain through the defect (►**Fig. 2B**). This patient underwent a single-stage repair of the defect with a bony strut used to close the defect (►**Fig. 2C**). The postoperative period was uneventful and was discharged in POD 5.

Outcome and Follow-Up

Both patients had no intra or postoperative complications. Special intervention using intracranial glue was used in both surgeries. Follow-up up to 6 months showed no recurrence of rhinorrhea or any other symptoms.

Discussion

Overall, 80% of encephaloceles occur in the occipital area of the cranial vault mostly seen in Western countries like North America and Europe. However, in Southeast Asian countries anterior encephaloceles tend to be more commonly seen with an incidence of 1/3500 live births.¹ Out of the anterior encephaloceles, frontoethmoidal encephaloceles were found to be the most common.² The next common is frontonasal. Basal encephaloceles like transtethmoidal were found to be very uncommon. Several series were published by Suwanwala and Suwanwala in the 1970s.³ A large series of 133 cases of anterior encephalocele by AK Mahapatra showed that frontoethmoid encephalocele was the most common followed by transtethmoidal.¹ This literature by Indian authors supports the rarity of the above-mentioned transnasal, transtethmoidal presentations reported by us, sharing similar geographical demographics, with different etiologies, managed uniformly. A list of 12 previously published cases of transtethmoidal encephaloceles worldwide, to date, has been tabulated (►**Table 1**).

Occult transnasal, transtethmoidal encephaloceles present with CSF leak, meningitis, and nasal stuffiness.⁴ Posttraumatic encephaloceles were found in the literature; however, their incidence is less common as compared with congenital. Biopsies by ENT specialists can cause iatrogenic dural puncture with CSF leak in patients. Needless to say, all encephaloceles need surgery; however, meticulous planning is needed for the same

Table 1 Publications on transtethmoidal encephaloceles in literature are mentioned as follows

Sl no.	Year	Country	Age/Sex	Etiology	Clinical presentation	Site and size of defect	Author names
1	2021	USA	43 y/M	Congenital	Rhinorrhea, anosmia, headache	Lt ethmoidal and nasal wall 36 × 35 × 33mm	Lam et al ⁷
2	2020	Switzerland	56 y/F	Spontaneous	Recurrent unilateral nasal discharge	Rt anterior ethmoidal roof	Hallak et al ⁶
3	2020	Italy	33 d/F	Congenital	Feeding difficulties, failure to thrive	Rt cribriform plate	Parisi et al ⁸
4	2019	Tunisia	8 mo/M	Congenital	Nasal obstruction	Lt ethmoidal horizontal plate 10 × 5mm	Dhaha et al ⁹
5	2014	India	06 y/F	Trauma	CSF rhinorrhea	Lt cribriform plate	Keshri et al ¹⁰
6	2014	India	07 y/F	Congenital	Seizures	Rt cribriform plate	Keshri et al ¹⁰
7	2013	India	07 y/F	Congenital	Recurrent meningitis	Rt anterior and postethmoidal sinus roof	Keshri et al ¹⁰
8	2013	India	11 y/M	Congenital	Recurrent meningitis	Lt anterior ethmoidal sinus roof	Keshri et al ¹⁰
9	2013	India	09 y/F	Trauma	Recurrent meningitis	Rt anterior ethmoidal sinus roof	Keshri et al ¹⁰
10	2013	India	07 y/M	Trauma	Recurrent meningitis	Rt anterior ethmoidal sinus roof	Keshri et al ¹⁰
11	2012	Cuba	55 y/F	Spontaneous	CSF rhinorrhea	Rt ethmoidal sinus roof	Lopez Arbolay et al ⁵
12	2011	India	5 d/M	Congenital	Externally visible mass	Lt cribriform 3 × 3 × 2.5cm	Upasani et al ⁴

Abbreviations: CSF, cerebrospinal fluid; Lt, left; Rt, right.

depending upon the size, type, location, and associated hydrocephalous. Emergency surgery is avoided unless there is a leaking encephalocele that can result in meningitis.^{5,6}

Conclusion

Transnasal and transtethmoidal are rare encephaloceles, usually occult or mimicking a nasal polyp hanging down the nasal cavity, which creates a dilemma in exact diagnosis. Hence, it is imperative to get an MRI and CT done for conclusive evidence, in any case of doubt. Surgery being the only mode of treatment eventually, identifying the encephaloceles early, and thereby managing them aptly, is the challenge, aiming at improving the quality of life and morbidities, if any.

Conflict of Interest

None declared.

Acknowledgment

We acknowledge SOA University, Bhubaneswar, Odisha for their help in doing this work.

References

- Mahapatra AK. Anterior encephalocele - AIIMS experience a series of 133 patients. *J Pediatr Neurosci* 2011;6(Suppl 1):S27–S30
- Mahapatra AK, Agrawal D. Anterior encephaloceles: a series of 103 cases over 32 years. *J Clin Neurosci* 2006;13(05):536–539
- Suwanwela C, Suwanwela N. A morphological classification of sincipital encephalomeningoceles. *J Neurosurg* 1972;36(02):201–211
- Upasani AV, Patel DN, Chandna SB. A Rare Presentation of a Transtethmoidal Encephalocele at Birth, *Pediatrics & Neonatology*, Volume 55, Issue 5., 2014, Pages 404–406, ISSN 1875–9572, <https://doi.org/10.1016/j.pedneo.2012.12.015>
- Lopez Arbolay O, Rojas Manresa J, Gonzalez Gonzalez J, Bretón Rosario JL. Gigant transtethmoidal meningoencephalocele operated by full endonasal endoscopic approach: case report. *Case Rep Med* 2012;2012:763259
- Hallak B, Kurzbuch AR, Fournier JY, Bouayed S. Spontaneous transtethmoidal meningoencephalocele presenting in the form of recurrent unilateral nasal discharge: discussion of the diagnosis and endoscopic surgical management. *BMJ Case Rep* 2020;13(05):e234703
- Lam J, Lee DJ, Oladunjoye A. Large primary transtethmoidal encephalocele presenting in an adult. *Cureus* 2021;13(07):e16122
- Parisi C, Saetti R, Petitto LL, Novello M, Volpin L, Rustemi O. Transtethmoidal encephalocele endoscopically treated in a newborn: a case report. *Childs Nerv Syst* 2021;37(04):1333–1337
- Dhaha M, Slimane AEH, Karmani N, Bouhoula A, Kalel J. Transtethmoidal encephalocele: an unusual cause of pediatric nasal obstruction. *J Pediatr Neonat Individual Med* 2019;8(02):e080213
- Keshri AK, Shah SR, Patadia SD, Sahu RN, Behari S. Transnasal endoscopic repair of pediatric meningoencephalocele. *J Pediatr Neurosci* 2016;11(01):42–45