

Headache Management in Individuals with Brain Tumor

Ami Cuneo, MD¹ Natalia Murinova, MD¹

¹Department of Neurology, University of Washington, Seattle, Washington

Address for correspondence Ami Cuneo, MD, Department of Neurology, University of Washington, 1959 NE Pacific Street, Seattle, WA 98195-6182 (e-mail: amiza@uw.edu).

Semin Neurol 2024;44:74–89.

Abstract

Headache occurs commonly in individuals diagnosed with cerebral neoplasm. Though the features of a brain tumor-associated headache may vary, a progressive nature of headache and a change in headache phenotype from a prior primary headache disorder often are identified. Pathophysiologic mechanisms proposed for headache associated with brain tumor include headache related to traction on pain-sensitive structures, activation of central and peripheral pain processes, and complications from surgical, chemotherapeutic and/or radiotherapy treatment(s). Optimization of headache management is important for an individual's quality of life. Treatments are based upon patient-specific goals of care and may include tumor-targeted medical and surgical interventions, as well as a multimodal headache treatment approach incorporating acute and preventive medications, nutraceuticals, neuromodulation devices, behavioral interventions, anesthetic nerve blocks, and lifestyles changes.

Keywords

- ▶ headache
- ▶ brain tumor
- ▶ headache treatment

Headaches occur commonly in the general population. Affecting more than 90% of individuals during the lifetime,¹ headaches can range from an occasional nuisance to a severe, disabling condition. Within this broad clinical spectrum, most headaches are related to functional, neurochemical changes in an individual with a genetic and/or environmental predisposition. Examples of such *primary headache disorders* include migraine, tension-type headache, and cluster headache (▶ **Table 1**).² In comparison, *secondary headache disorders* are attributed to an underlying brain pathology, such as an intracranial neoplasm, vascular condition, cerebrospinal fluid (CSF) pressure-related disorder, or other etiology (▶ **Fig. 1**).^{2,3}

Headache attributed to intracranial neoplasm is defined by the International Classification of Headache Disorders, 3rd edition (ICHD-3) criteria.² In an individual with a known space-occupying neoplasm, the headache must develop in temporal relation to the neoplasm, worsen or improve in parallel with progression or successful treatment of the neoplasm, respectively, and have characteristics, such as progressive headache worsened in the morning/when laying down, headache aggravated by Valsalva-like manœuvres,

and/or headache accompanied by nausea and/or vomiting (▶ **Table 2a**).² The ICHD-3 also includes definitions for headache attributed to carcinomatous meningitis and pituitary lesions (▶ **Table 2b, c**).²

Concern for an underlying brain tumor is raised frequently by individuals presenting for headache evaluation.⁴ However, intracranial neoplasms comprise only 1% of newly diagnosed malignancies. Furthermore, brain tumors are identified on magnetic resonance imaging (MRI) in just 1.5% of those undergoing headache workup.^{5,6} When present, a cerebral neoplasm is 10 times more likely to be a metastatic lesion (e.g., from lung or breast cancer, or melanoma) than a primary brain tumor.^{5,7,8} Though headache is rarely the only symptom of a brain tumor, in clinical practice the diagnostic discernment of a primary versus secondary headache can be challenging, due in part to the high prevalence of primary headache disorders in the general population and because features of secondary headaches can mimic primary headaches.^{9,10}

A wide range of treatment options can be considered for headache related to cerebral neoplasm. Tumor-targeted treatments, such as surgical resection, chemotherapy, radiation

Table 1 Characteristics of common primary headaches as compared with headache related to intracranial neoplasm, as defined by the ICHD-3 criteria²

Headache characteristics	Migraine	Tension type	Cluster	Headache attributed to intracranial neoplasm
Minimum number of attacks	5	10	5	N/A
Duration (untreated or unsuccessfully treated)	4–72 h	30 min to 7 d	15–180 min	N/A
ICHD-3 diagnostic features	Must have ≥ 2 of 4 features: –Unilateral location –Pulsating quality –Moderate or severe intensity –Causing avoidance of routine physical activity	Must have ≥ 2 of 4 features: –Bilateral location –Pressing quality (non-throbbing) –Mild or moderate intensity –Not causing avoidance of routine physical activity	Severe or very severe unilateral, orbital, supraorbital, and/or temporal pain occurring with a frequency between 1 every other day and 8 per day	Requirements: –A space-occupying intracranial neoplasm has been demonstrated –Must have ≥ 2 of: –Headache developed in temporal relation to neoplasm, or led to its discovery –Headache either worsened with disease progression and/or improved in temporal relation with treatment of the neoplasm · Headache has ≥ 1 of 4: –Progressive –Worse in morning and/or when laying down –Aggravated by Valsalva –Associated with nausea and/or vomiting
Associated symptoms	Must have ≥ 1 of: –Light sensitivity and sound sensitivity –Nausea and/or vomiting	Must have both of: –No nausea or vomiting –No more than 1 of light or sound sensitivity	Must have ≥ 1 ipsilateral autonomic symptom (e.g., lacrimation, rhinorrhea, nasal congestion) or associated restlessness/agitation	Typically involves associated neurologic symptoms or signs on physical exam related to expansion of the mass. May be associated with intracranial hypertension.
Forms	Episodic migraine: < 15 headache days per month Chronic migraine: ≥ 15 headache days per month, including ≥ 8 migraine days per month for > 3 mo Migraine with aura: ≥ 2 episodes of fully reversible visual, sensory, or other symptoms lasting minutes usually associated with migraine	Episodic tension-type headache: < 15 headache days per month Chronic tension-type headache: ≥ 15 headache days per month for > 3 mo	Episodic cluster headache: ≥ 2 cluster periods lasting 7 d to 1 y (untreated) and separated by pain-free remission periods of ≥ 3 mo Chronic cluster headache: No remission or remission periods < 3 mo for ≥ 1 y	N/A

Note: For each headache diagnosis, the ICHD-3 criteria requires that it not be better accounted for by another ICHD-3 diagnosis.

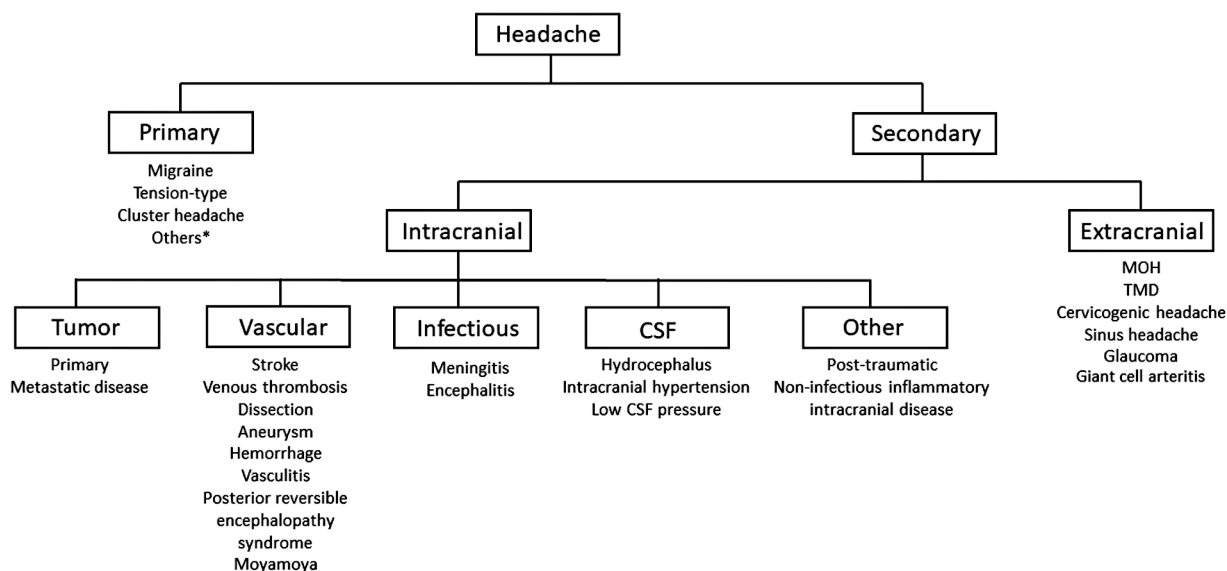


Fig. 1 Differential diagnosis of primary versus secondary etiologies of headache. *A list of other primary headaches is included in the ICHD-3 guidelines.² MOH, medication overuse headache; TMD, temporomandibular disorders.

therapy, and/or medications to reduce tumor-associated cerebral edema may be initiated on a case-by-case basis and can lead to improvement in headache. Importantly, individuals with cerebral neoplasm also may respond to standard thera-

pies for primary headaches, based upon the patient's tumor-associated headache phenotype and prior history of a primary headache disorder, though studies in this patient population are limited.¹¹ In the last decade, new treatments for primary

Table 2 ICHD-3 definitions of headache attributed to intracranial neoplasia²

<p>2a. Headache attributed to intracranial neoplasm Description: Headache caused by one or more space-occupying intracranial tumours.</p> <p>Diagnostic criteria:</p> <ol style="list-style-type: none"> A. Any headache fulfilling criterion C B. A space-occupying intracranial neoplasm has been demonstrated C. Evidence of causation demonstrated by at least two of the following: <ol style="list-style-type: none"> 1. headache has developed in temporal relation to development of the neoplasm, or led to its discovery 2. either or both of the following: <ol style="list-style-type: none"> a) headache has significantly worsened in parallel with worsening of the neoplasm b) headache has significantly improved in temporal relation to successful treatment of the neoplasm 3. headache has at least one of the following four characteristics: <ol style="list-style-type: none"> a) progressive b) worse in the morning and/or when lying down c) aggravated by Valsalva-like manoeuvres d) accompanied by nausea and/or vomiting D. Not better accounted for by another ICHD-3 diagnosis.
<p>2b. Headache attributed to carcinomatous meningitis Description: Headache caused by carcinomatous meningitis, usually accompanied by signs of encephalopathy and/or cranial nerve palsies.</p> <p>Diagnostic criteria:</p> <ol style="list-style-type: none"> A. Any headache fulfilling criterion C B. Carcinomatous meningitis (in the presence of systemic neoplasia known to be associated with carcinomatous meningitis) has been demonstrated C. Evidence of causation demonstrated by at least two of the following: <ol style="list-style-type: none"> 1. headache has developed in temporal relation to development of the carcinomatous meningitis 2. either or both of the following: <ol style="list-style-type: none"> a) headache has significantly worsened in parallel with worsening of the carcinomatous meningitis b) headache has significantly improved in parallel with improvement in the carcinomatous meningitis 3. headache is associated with cranial nerve palsies and/or encephalopathy D. Not better accounted for by another ICHD-3 diagnosis.

Table 2 (Continued)

<p>2c. Headache attributed to hypothalamic or pituitary hyper- or hyposecretion</p> <p>Description: Headache caused by a pituitary adenoma and hypothalamic or pituitary hyper- or hyposecretion, usually accompanied by disorder of temperature regulation, abnormal emotional state and/or altered thirst or appetite. It remits after successful treatment of the underlying disorder.</p> <p>Diagnostic criteria:</p> <ul style="list-style-type: none"> A. Any headache fulfilling criterion C B. Hypothalamic or pituitary hyper- or hyposecretion associated with pituitary adenoma has been demonstrated C. Evidence of causation demonstrated by at least two of the following: <ul style="list-style-type: none"> 1. headache has developed in temporal relation to onset of hypothalamic or pituitary hyper- or hyposecretion 2. either or both of the following: <ul style="list-style-type: none"> a) headache has significantly worsened in parallel with worsening of the hypothalamic or pituitary hyper- or hyposecretion b) headache has significantly improved in parallel with improvement in the hypothalamic or pituitary hyper- or hyposecretion 3. headache is associated with at least one of the following: <ul style="list-style-type: none"> a) disorder of temperature regulation b) abnormal emotional state c) altered thirst and/or appetite D. Not better accounted for by another ICHD-3 diagnosis.

headache disorders offer promise for individuals suffering from headache. Therefore, incorporation of a multimodal headache treatment approach, including evidence-based acute and preventive medications, nutraceuticals, neuromodulation devices, lifestyle modifications, and behavioral therapies, can be considered. Additional attention to diagnosis of medication overuse headache (MOH), a common, superimposed secondary headache disorder, should be paid in individuals with headache and brain tumor, as treatment of MOH may reduce central sensitization to pain and improve headache-related outcomes.¹²

This article reviews headache characteristics and pathophysiology in cerebral neoplasm, as well as the diagnostic evaluation and management of headache in this patient population.

Headache Features in Individuals with Brain Tumor

Traditionally, clinicians have considered certain headache features suggestive of an underlying cerebral neoplasm, including positional headache (e.g., worsened when supine/upon awakening), headache exacerbated with Valsalva-like manœuvres, and/or headache associated with nausea and/or vomiting (– **Table 2**).^{13,14} However, these features are not specific for headache related to intracranial neoplasm.

Additional brain tumor-associated headache characteristics have been described in the last decades. Forsyth and Posner found that most of these headaches had non-specific features, were mild, and mimicked migraine.¹⁴ Valentinis et al reported intracranial neoplasm-related headaches typically involved intermittent, moderate-intensity, pressure-like pain located in the bifrontal region, were rarely associated with nausea or vomiting, and often responded to analgesics; in this study, just 5.1% of patients undergoing surgery for brain tumors had the “classic” intracranial tumor-associated headache features.¹⁵ Schankin et al suggested that nearly 40% of brain tumor patients had tension-like headache, and that dull headache occurred more frequently with glioblastoma

multiforme, whereas pulsating headache was associated with meningioma.¹⁰ Pfund et al observed that tumor location coincided with the lateralization of headache in only one-third of patients.¹⁶ The progressive nature of headache, however, has been identified in 79.1% of individuals with cerebral neoplasm.^{16,17}

Diagnostic Evaluation and Workup of Headache Associated with Brain Tumor

Initial evaluation for headache related to brain tumor includes a comprehensive headache history. The most significant risk factor for headache development in cerebral neoplasm is a prior primary headache disorder^{10,18,19}; at the same time, secondary headaches may masquerade as tension-type headache, migraine, trigeminal autonomic cephalalgias, or other primary headache disorders.^{15,20–22} Taken together, these factors can lead to a diagnostic challenge for clinicians.

Additional neurologic history may provide diagnostic clues. For instance, an alteration in headache features over time may suggest a new underlying brain pathology.¹⁰ Presence of other neurologic symptoms can suggest secondary etiology of headache. Though headache is reported in up to 71% of individuals with brain tumor,^{14,16,23,24} only 1 to 2% of patients with cerebral neoplasm experience headache as the sole clinical symptom.^{10,25,26} Cerebral neoplasm-related headache commonly is accompanied by seizure and/or other focal neurologic symptoms.²⁷

A comprehensive neurologic exam, including evaluation for mental status changes, visual field defects, papilledema, cranial nerve dysfunction, motor and sensory abnormalities, and cerebellar dysfunction, is important. Though focal exam findings may be present, the neurologic exam may be normal due to the indolent nature of brain tumors, which allows time for compensation of neural brain networks.²⁸ In these cases, brain tumors may be asymptomatic and clinically silent, identified incidentally on imaging.⁷

In gathering the history and performing the neurologic exam, attention should be paid to the identification of “red flags.” The SNNOOP10 criteria addresses risk factors for secondary etiologies of headache, such as systemic symptoms (e.g., fever); history of neoplasm or neurologic findings on exam; sudden-onset headache; older age (> 50 years); pattern change from prior headaches; positional headaches;

headaches precipitated by cough, sneeze, or Valsalva-like manœuvres; papilledema; pregnancy/post-partum; progressive symptoms; painful eye with autonomic features; immunosuppression history; and use of acute analgesics associated with MOH (► **Table 3**).²⁹ If any of these “red flags” is present, further workup to evaluate for secondary headache should be considered (► **Fig. 2**). For individuals

Table 3 The SNNOOP10 criteria includes select red flags associated with secondary etiologies of headache

Red Flag	Examples of Clinical Signs, Symptoms, and/or Comorbidities	Select Related Secondary Headache Etiologies
Systemic	Fever, chills, sweats, weight loss, systemic disease, immunocompromised status, pregnancy/puerperium	Secondary headaches associated with malignancy, infection/opportunistic infection, inflammatory condition, and pregnancy (e.g., cerebral venous sinus thrombosis, reversible cerebral vasoconstriction syndrome (RCVS), posterior reversible encephalopathy syndrome)
Neurologic deficit	Focal neurologic signs on exam (e.g., papilledema, cranial nerve deficits, numbness, tingling, weakness, altered cognition) and/or seizure	Secondary headaches related to brain tumor (primary versus metastatic), infection (e.g., abscess, leptomenigeal disease, meningoenephalitis), vascular disorders, inflammatory/autoimmune conditions
Onset sudden	“Thunderclap headache,” defined as a rapid onset headache achieving maximal intensity within 1 minute ¹	Subarachnoid hemorrhage, other vascular disorders, RCVS, pituitary apoplexy, arterial dissection, intracranial hypotension, Chiari malformation, hypertensive crisis, complicated sinusitis, giant cell arteritis, brain tumor ²
Older age	Age > 50 years	Giant cell arteritis, brain tumor, vascular disorders, non-vascular intracranial disorders (e.g., inflammatory condition)
Pattern change and/or other ‘p’ features	New headache, change in headache frequency, severity, duration, location, and/or associated features; progressive headache; any new headache phenotype; headaches associated with position, precipitated by cough, sneeze, or exercise, painful eye +/- vision change, post-traumatic onset of headache, painkiller medication usage	Brain tumor, vascular and non-vascular (e.g., inflammatory) intracranial disorders, CSF-related disorders (e.g., intracranial hypotension, intracranial hypertension), posterior fossa malformation, Chiari malformation, acute angle closure glaucoma, subdural or epidural hematoma, medication overuse headache, medication side effect

Source: Used with permission from Do et al.²⁹

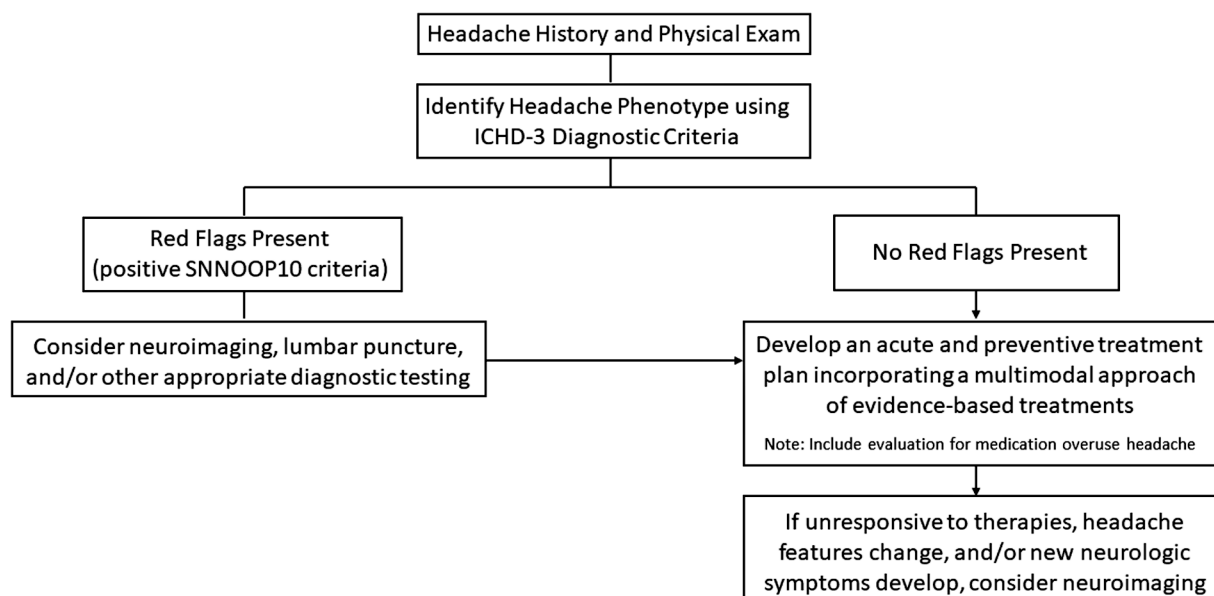


Fig. 2 A decision-making algorithm for further diagnostic workup, based on the presence of SNNOOP10 criteria risk factors for secondary headache.²⁹

previously diagnosed with brain tumor, repeat imaging should be considered if headache features change, if new neurologic symptoms or focal signs on exam develop, or if seizure, cognitive change, and/or signs of intracranial hypertension are identified.¹³

Though the chance of finding a brain tumor on imaging in a headache patient with no history of malignancy is low,^{27,29} MRI or computed tomography (CT) of the brain can help identify space-occupying cerebral lesions. MRI is superior to CT both in terms of imaging resolution and visualization of the brain's posterior fossa, whereas CT is more widely available and can be helpful in evaluating for a hemorrhagic component of tumor and/or associated cerebral edema. MRI spectroscopy can analyze the chemical composition of the lesion to help distinguish primary brain tumors from non-neoplastic etiologies (e.g., demyelinating disease, abscess, or stroke), but cannot diagnose tumor type. Histological evaluation from tumor biopsy or resection sample is required for confirmatory diagnosis.³⁰ If neurologic history, exam, and/or imaging raise concern for carcinomatous meningitis, CSF studies including cytology and flow cytometry are obtained. Labs (e.g., inflammatory markers), opening pressure during lumbar puncture, and additional imaging studies (e.g., head and neck vessel imaging) can help identify non-neoplastic secondary etiologies of headache.

Routine imaging for all headache patients is not required due to the high prevalence of primary headache disorders in the general population in combination with a similar rate of incidental findings of brain tumor in individuals with or without headache (►Fig. 2).^{31,32} Regular performance of extensive workup for secondary etiology of headache in all patients would subject individuals to invasive testing, risk of false-positive diagnoses with incidental findings, and contribute to a high economic burden with limited diagnostic yield.³²⁻³⁴ An exception includes headaches with features of the trigeminal autonomic cephalalgias. Lesions in the posterior fossa, pituitary, trigeminal nerve, and other locations, as well as cerebral venous sinus thrombosis, have been associated with headaches with phenotypes of hemi-crania continua,³⁵ paroxysmal hemicrania,³⁶ cluster headache,^{20,37} and/or short-lasting unilateral neuralgiform headache attacks with conjunctival injection and tearing or cranial autonomic symptoms (SUNCT or SUNA, respectively).³⁸⁻⁴⁰ Therefore, MRI of the brain with and without contrast, as well as MR angiography of the head and neck, should be considered in individuals with these headache characteristics.³¹

Pathophysiology of Brain Tumor-Related Headache Pain

Several mechanisms for cerebral neoplasm-related headache pain have been hypothesized. The traction theory proposes brain tumor headache is related to compression and distension of pain-sensitive structures from tumor growth, surrounding edema, or secondary hemorrhage.^{13,41} Though the brain parenchyma itself lacks pain receptors, several intra-

and extracranial structures are pain-sensitive, including blood vessels, cranial nerves with afferent pain fibers (e.g., the trigeminal nerve), cervical nerves (e.g., C1 and C2), dura mater, periosteum, and extra-cranial tissue.^{13,42-45}

Increased intracranial pressure can cause traction on pain-sensitive structures and trigger headache, as well.^{14,46} Intracranial pressure may increase in the setting of a rapidly expanding tumor with associated cerebral edema within the cranial vault.^{13,14,16} In addition, daily fluctuations in intracranial pressure can cause headache. For example, headache may be more pronounced upon awakening. Mechanistically, when in the supine position overnight, the diminished gravity-assisted venous drainage can contribute to cerebral edema. At the same time, a normal sleep-related increase in arterial pressure of carbon dioxide can lead to vasodilation, followed by a rise in intracranial pressure and headache.⁴⁴ In other cases, intraventricular, midline, and posterior fossa tumors may block CSF drainage, leading to increased intracranial pressure and traction upon periventricular pain-sensitive structures. For some individuals, a sudden-onset, paroxysmal headache triggered by change in body position or Valsalva-like manoeuvre may occur due to transient blockage of CSF flow at the foramen of Monro (i.e., from a colloid cyst or other tumor of the 3rd ventricle).^{13,44} Despite these factors, the risk of any particular cerebral neoplasm on headache is variable. Tumors in identical locations may have differing associations with headache,^{22,24} and tumors without apparent direct mass effect on pain sensitive structures have been associated with headache in some cases.^{13,16}

Peripheral sensitization to pain also can contribute to headache pain. Prolonged irritation of pain-sensitive structures from increased intracranial pressure can lead to release of pro-inflammatory neuropeptides at sites of inflammation, thereby exacerbating vascular edema, causing infiltration of immune cells, and leading to neurogenic inflammation with release of pro-pain substances, such as calcitonin gene-related peptide (CGRP) and substance P.⁴⁴ The increased risk of rare headache phenotypes in individuals with secretory pituitary adenomas suggests that hormones (e.g., prolactin and growth hormone) may lead to biochemical changes in the hypothalamic-pituitary axis that contribute to headache, as well.^{9,47}

Another proposed mechanism for headache in individuals with brain tumor includes central sensitization to pain from prolonged irritation from pain-sensitive pericranial structures, as well as from dysfunction of the efferent, pain-inhibition pathways that descend from brainstem nuclei on trigeminocervical and spinal nerves.^{13,17} Dysregulation of these descending pain inhibition pathways may contribute to prolonged headache pain.^{13,44}

Headache additionally can occur as a direct acute or chronic complication of brain tumor treatment, such as radiation therapy, chemotherapy, or neurosurgical intervention.²⁴ For example, during or immediately following radiation therapy, patients may develop acute injury (e.g., steroid-responsive damage to capillaries and leakage with edema), which can manifest clinically with headache, nausea, and

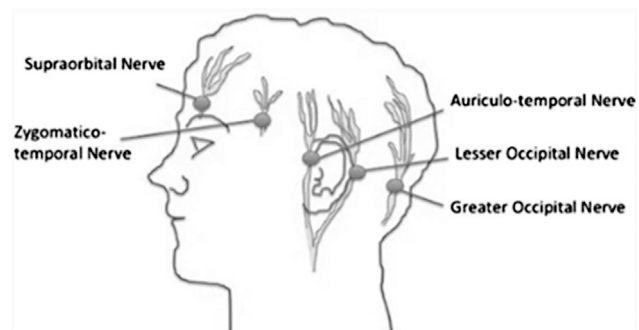


Fig. 3 Cutaneous innervation of the scalp with locations (circles) for local anesthetic injection for nerve blockade. (Used with permission from Dunn LK, Naik BI, Nemergut EC, Durieux ME. Post-craniotomy pain management: beyond opioids. *Curr Neurol Neurosci Rep* 2016;16(10):93)

vomiting.⁴⁸ Though the central nervous system (CNS) is protected in part by the blood–brain barrier, the CNS remains vulnerable to toxicity from some chemotherapies (e.g., retinoids, intrathecal methotrexate causing aseptic meningitis), resulting in headache among other neurologic symptoms, including encephalopathy, seizures, cerebrovascular complications, vision changes, cerebellar dysfunction, and neuropathy.^{49,50} While surgical intervention may be necessary in some cases of brain tumor, craniotomy can be associated with an independent risk of headache development predominantly at the surgical site due to mechanical disruption of the scalp's sensory innervation from nerves, including the occipital nerve, trigeminal nerve, and sensory branches of the 2nd and 3rd cervical nerves (→**Fig. 3**).^{18,46} Other secondary etiologies (e.g., CSF leak, hydrocephalus, cerebral hemorrhage, and/or meningoen- cephalitis) can lead to post-craniotomy headache in some individuals.¹⁹

Treatments for Headache Related to Cerebral Neoplasm and Intracranial Hypertension

A range of treatments may be used for headache management in patients with brain tumor. An individualized approach including patient-specific therapies should be pursued. Interventions targeting the brain tumor itself (e.g., neurosurgery, chemotherapy, radiation therapy, and/or management of intracranial hypertension) may be considered based upon the tumor's type, location, malignancy-potential, and extent of disease, as well as the patient's functional status and age.^{24,51}

Corticosteroids are recommended for treatment of headache from intracranial hypertension from tumor-related cerebral edema.¹³ This medication class is thought to decrease tumor-associated vasogenic edema via reduction of capillary permeability at the blood–brain barrier.⁵² The most potent corticosteroid, dexamethasone, has a relatively long half-life (36–72 hours) compared with prednisone (2–3 hours). Dexamethasone reaches complete efficacy at 24 to 72 hours and has limited mineralocorticoid effect.²⁴

Though no standardized protocol for dexamethasone therapy exists, typically dexamethasone 4 mg daily can adequately control headache.²⁴ Higher doses can be used, though they may be associated with dose-related toxicity (e.g., hyperglycemia, steroid-induced myopathy, avascular necrosis, infection, insomnia, and psychiatric disturbance) and have not been shown to be more effective.⁵³ The role for corticosteroids in headache treatment for individuals with cerebral neoplasm *without* associated brain edema or mass effect remains controversial.¹³ Other treatments for cerebral edema, such as osmotic agents (e.g., mannitol) or diuretics (e.g., furosemide), do not have established efficacy for headache management.¹³

For individuals with hydrocephalus related to CSF obstruction, ventricular drainage and/or ventricular shunting can be considered, if within the patient's goals of care.⁵⁴ However, the incidence of shunt malfunction is elevated in patients with brain tumor compared with those experiencing hydrocephalus from other etiologies⁵⁵ and the risk of early shunt failure after craniotomy in individuals with cerebral neoplasm is high (20%).⁵⁶ Though not studied directly in hydrocephalus related to cerebral neoplasm, carbonic anhydrase inhibitors (e.g., topiramate or acetazolamide) may decrease CSF production in hydrocephalus, as established in other conditions, such as idiopathic intracranial hypertension.^{57,58}

For most patients with cerebral neoplasm-related headache, treatment with tumor debulking and/or decompression results in improvement of headache symptoms.^{16,59} In one study of 164 patients with brain tumor and headache, Pfund et al showed that only 8% of patients continued to experience headache 3 months postoperatively.¹⁶ In a 2018 study, headache prevalence was found to decrease from 52% preoperatively to 30% at 6 months postoperatively in brain tumor patients.⁵⁹ Though neurosurgical intervention can help headache, in some individuals craniotomy itself may contribute to the development of a new, post-operative headache.⁶⁰ Historically, craniotomy was considered less painful than other surgeries, due to fewer pain receptors in the dura and insensitivity of the brain parenchyma to pain.^{61,62} This, however, has been debated. More recent studies have suggested that craniotomy is associated with significant pain in up to 60 to 84% of individuals, often located at the surgical site due to disruption of the pericranial muscle and soft tissue, as well as injury to cranial nerves,^{18,60,63–65} and eventually, central sensitization to pain may develop.⁶⁰ Suboccipital craniotomies, particularly using the retrosigmoid approach, are associated more frequently with chronic headache, with up to 66% of patients experiencing persistent headaches 3 years postoperatively.^{11,66}

New-onset or worsening headache also may occur as an adverse event related to certain chemotherapeutic agents (e.g., temozolomide, bromocriptine, bevacizumab, withdrawal of corticosteroids, and others),^{11,24,67} radiation therapy (particularly whole brain radiation),²⁴ or as a symptom of a medical complication from these treatments (e.g., headache related to aseptic meningitis from intrathecal chemotherapy,

or from radiation encephalopathy, which can present with headache at 1–6 months post-radiation).²⁴ Alternatively, palliative radiotherapy has been shown to decrease headache severity in 41% of individuals with metastatic cerebral neoplasm.⁶⁸

In combination with tumor-specific treatments, a range of medication and non-medication approaches for acute and preventive symptomatic management of headache may be employed for patients undergoing surgical intervention, as well as for those for whom surgery is not indicated.¹¹

Symptomatic Management of Post-Craniotomy Headache and Tumor-Related Headache in the Outpatient Setting

Acute Treatment

In the post-craniotomy patient, headache may affect both neurosurgical recovery and quality of life.^{60,69,70} Fifty to 90% of individuals may require medication for pain relief post-craniotomy,⁶⁰ however headache often is undertreated.^{63,69} This may be related in part to a dearth of evidence and consensus regarding treatment for post-operative pain following cranial neurosurgery.^{65,69}

Traditionally, medications used in the acute, post-surgical period have included acetaminophen, nonsteroidal anti-inflammatory drugs (NSAIDs), and opioids. Subcutaneous injection of sumatriptan, a medication used commonly as an abortive treatment for migraine, has been shown to be beneficial in a small study of individuals with post-craniotomy headache following microvascular decompression⁷¹; in another study, subcutaneous sumatriptan was associated with decreased opioid use in both adult and pediatric populations following cranial surgery.⁷⁰ Other treatments used in the acute, post-surgical setting include gabapentin and regional anesthetic nerve blocks.^{64,72,73}

Though acetaminophen, NSAIDs, triptans, and opioids typically are used in moderation in the short-term post-surgically, certain risks should be considered. NSAIDs, which cause impaired platelet aggregation, have been associated with post-surgical intracranial hemorrhage and also confer increased risk of post-operative renal failure.⁶⁵ Opioids, though commonly used in the post-surgical setting, can be sedating and compromise the neurologic exam during the acute period in which mental status, as well as motor and sensory function, is assessed. Furthermore, frequent, pro-

longed use of opioids, acetaminophen, NSAIDs, and triptans can result in development of central sensitization to pain and MOH. Defined by the ICHD-3 criteria as transformation of episodic primary headaches into chronic headaches occurring more than 15 days per month (– **Table 4**) in the setting of frequent use of abortive medications,² a role for MOH in exacerbating secondary headaches, such as headache related to cerebral neoplasm, has been postulated.¹³ MOH can be problematic for the patient. Affecting the function of pain-related neural pathways, MOH induces peripheral and central sensitization to pain, leading to an increase in headache frequency and a decrease in responsiveness to preventive medications.^{74,75} MOH is associated with poor quality of life and increased economic burden, including costs from medications and emergency department visits, as well as decreased work-related productivity.^{76,77}

Therefore, the diagnosis and prevention of MOH should be addressed early in a patient's clinical course. The variable influences of different medication classes upon the risk of development of MOH should be considered from the onset of headache symptoms. Opioids should be avoided when possible, due to risk of opioid-induced hyperalgesia and MOH^{78,79}; even low-frequency use of opioids and barbiturates (e.g., 8 or 5 days per month, respectively) can contribute to MOH.⁷⁷ The use of NSAIDs and Tylenol should be limited to no more than 14 days per month in combination to reduce the risk of development of MOH.² Triptans also can be associated with MOH and require limited use (no more than 9 days per month).² If acute analgesics are required, the practitioner and patient should tally the number of days per month of use of any culprit medication(s) at each visit; a general guideline is to limit the total use of these medications to 8–9 days per month. Treatment for MOH includes withdrawal from the culprit medications and use of alternative pain medications in the acute setting. For example, gabapentin, which can be used for acute postoperative pain, has been associated with decreased analgesic consumption after surgery, though risks of delayed tracheal extubation and increased sedation may occur.⁷³ Regional nerve blocks using bupivacaine, ropivacaine, and other anesthetics injected at the scalp can decrease pain severity after craniotomy and may exert a long-lasting benefit without causing MOH.^{64,72}

For all patients with headache related to cerebral neoplasm, whether or not craniotomy has been performed, standard acute treatments targeting both the brain tumor-

Table 4 ICHD-3 definition of medication overuse headache²

<p>Medication overuse headache <i>Description:</i> Headache occurring on 15 or more days/month in a patient with a pre-existing primary headache and developing as a consequence of regular overuse of acute or symptomatic headache medication (on 10 or more or 15 or more days/month, depending on the medication) for more than 3 mo. It usually, but not invariably, resolves after the overuse is stopped. <i>Diagnostic criteria:</i> A. Headache occurring on ≥ 15 d/mo in a patient with a pre-existing headache disorder B. Regular overuse for >3 mo of one or more drugs that can be taken for acute and/or symptomatic treatment of headache^a C. Not better accounted for by another ICHD-3 diagnosis.</p>
--

^aMedications that can contribute to MOH include NSAIDs, acetaminophen, combination medications that include caffeine, triptans, opioids, ergotamine, butalbital, lasmiditan, and others.

Table 5 Preventive medication treatments for migraine and tension-type headache phenotypes

Preventive medication	Dosing range	Initial dose ^a	Use for migraine vs tension type headache	Possible benefit for comorbidities	Side effects
Antiepileptics					
Topiramate (PO) ^a	25 mg/d to 200 mg/d	25–50 mg/d	Migraine Tension-type (limited evidence)	Weight loss	Paresthesia, memory impairment, dizziness, drowsiness, glaucoma, nephrolithiasis
Valproate (PO) ^a	500 mg/d to 1,000 mg/d	250 mg twice daily	Migraine	Mood stabilization Epilepsy	Alopecia, dizziness, drowsiness, hematologic effects, hepatotoxicity, hyperammonemia, delayed hypersensitivity reactions, pancreatitis, weight gain Teratogenic ^a
Antidepressants					
Amitriptyline (PO) ^b	10 mg/d to 150 mg/d	10 mg/d	Migraine Tension-type	Depression Neuropathic pain Fibromyalgia	Anti-cholinergic effects (e.g., constipation, blurred vision, urinary retention), increased risk of bleeding if used with anti-platelet agents/ anticoagulants, cardiac conduction abnormalities/ arrhythmias, dizziness, drowsiness, cognitive dysfunction, orthostatic hypotension
Venlafaxine (PO) ^b	70 mg/d to 225 mg/d	37.5 mg/d	Migraine	Anxiety Depression Neuropathic pain	Activation of mania/hypomania, hyponatremia, serotonin syndrome, sexual dysfunction, suicidal ideation, weight loss, nausea
Anti-hypertensives					
Beta-blockers					
Metoprolol (PO) ^a	25 mg twice daily to 200 mg/d	25 mg twice daily	Migraine	Hypertension, cardiac arrhythmias, heart failure	Bradycardia, bronchospasm, hypoglycemia, sleep disturbance, depression, dizziness, fatigue
Propranolol (PO) ^a	10 mg twice daily to 40 mg twice daily	10 mg twice daily	Migraine	Hypertension, cardiac arrhythmias, anxiety, essential tremor, postural orthostatic tachycardia syndrome	
Timolol (PO) ^a	5 mg/day to 15 mg twice daily	5 mg/d	Migraine	Hypertension, cardiac arrhythmias	
Atenolol (PO) ^b	25 mg/d to 100 mg/d	25 mg/d	Migraine	Hypertension, cardiac arrhythmias	
Nadolol (PO) ^b	20 mg/day to 240 mg/d	20 mg/d	Migraine	Angina, cardiac arrhythmias, hypertension	
					Drowsiness, insomnia, bradycardia, cardiac failure, hypotension

Table 5 (Continued)

Preventive medication	Dosing range	Initial dose ^a	Use for migraine vs tension type headache	Possible benefit for comorbidities	Side effects
Angiotensin-II receptor blocker					
Candesartan (PO) ^a	4 mg/d to 16 mg/d	4 mg/d or 8 mg/d	Migraine	Hypertension, heart failure	Hypotension, renal function abnormality, dizziness, hyperkalemia, back pain, upper respiratory infection
Angiotensin-converting enzyme inhibitor					
Lisinopril (PO) ^b	10 mg/d to 20 mg/d	10 mg/d	Migraine	Acute coronary syndrome, hypertension, proteinuric chronic kidney disease	Acute kidney injury, angioedema, cough, hyperkalemia, hypotension, syncope
Glutamate antagonist					
Memantine (PO) ^b	5 mg/d to 10 mg twice daily	5 mg/d	Migraine Tension-type Posttraumatic	Dementia, neurocognitive toxicity of whole brain irradiation	Hypertension, hypotension, dizziness, headache, agitation, delusion, hallucination
CGRP monoclonal antibodies					
Erenumab (SQ) ^a	70 mg monthly or 140 mg monthly	70 mg monthly	Migraine	–	Hypertension, constipation, antibody formation, injection site reaction, hypersensitivity reaction
Fremanezumab (SQ) ^a	225 mg monthly or 675 mg every 3 mo	225 mg monthly or 675 mg every 3 mo	Migraine	–	Antibody formation, injection site reaction
Galcanezumab (SQ) ^a	240 mg first month, followed by 120 mg monthly	240 mg first month	Migraine	–	
Eptinezumab (IV) ^a	100 mg every 3 mo or 300 mg every 3 mo	100 mg every 3 mo or 300 mg every 3 mo	Migraine	–	Antibody formation, injection-site reaction, nausea, fatigue
CGRP antagonists (gepants)					
Atogepant (PO) ^c	10 mg/d, 30 mg/d, or 60 mg/d	10 mg/d or 30 mg/d	Migraine	–	Weight loss, constipation, drowsiness, fatigue, elevated liver enzymes
Rimegepant (ODT) ^c	75 mg every other day	75 mg every other day	Migraine	–	Abdominal pain, nausea, rash, hypersensitivity reaction, dyspnea
OnabotulinumtoxinA (IM) ^a	155 units distributed evenly in 31 sites, or up to 195 units ^{112,131}	155 units distributed evenly in 31 sites, or up to 195 units ^{112,131}	Chronic migraine only	–	Hypertension, infection, and/or pain at injection site, exacerbation of headache, facial weakness, myasthenia, neck pain, muscle pain or spasm, blepharoptosis, bronchitis

(Continued)

Table 5 (Continued)

Preventive medication	Dosing range	Initial dose ^a	Use for migraine vs tension type headache	Possible benefit for comorbidities	Side effects
Other					
Gabapentin	100 mg/d to 1,200 mg three times daily	100 mg/d to 300 mg/d	Tension headache (limited evidence)	Fibromyalgia, neuropathic pain, secondary agent for focal onset seizures, restless legs syndrome, anxiety	Dizziness, drowsiness, respiratory depression, emotional lability, suicidal ideation, peripheral edema, weight gain
Pregabalin	25 mg/d to 150 mg three times daily	25 mg one to three times/day	Migraine ^{132,133} and tension-type headache ¹³⁴ (limited evidence for both conditions)		Dizziness, drowsiness, respiratory depression, hypersensitivity reaction, suicidal ideation, peripheral edema, visual disturbances, weight gain

Notes: Dosing for preventive medications is based on patient tolerance. Typically, it is recommended to start with a low dose and slowly up-titrate over weeks. When considering any preventive medication, the patient's renal function, pregnancy/lactation status, and medication interactions should be addressed.

^aEstablished efficacy, as supported by at least two Class I trials based on American Academy of Neurology evidence classification.⁸⁸

^bProbably effective, as supported by Class I or Class II trials based on American Academy of Neurology evidence classification.⁸⁸

^cEstablished efficacy based on at least one Class I trial based on American Academy of Neurology evidence classification.^{135,136}

related headache phenotype and any other underlying primary or secondary headache disorder(s) should be considered.^{13,60} If a headache related to intracranial neoplasm and/or post-craniotomy headache has migraine features, acute treatments for migraine can be used. Some of the newest abortive medications developed for treatment of migraine include gepants (e.g., rimegepant, ubrogepant, and zavegepant). Antagonists of CGRP, gepants are not thought to cause MOH.^{80,81} Compared with triptans, gepants have additional benefits including lack of vasoconstrictive properties, fewer side effects, and are not associated with adverse outcomes in individuals with cardiovascular risk factors.^{82,83} Though gepants have not been studied specifically in patients with cerebral neoplasm or post-craniotomy headache, these medications may be considered in individuals with headache with migraine features. Lasmiditan, another newer acute migraine medication, similarly does not cause vasoconstriction; however, it has more potential side effects (e.g., dizziness, drowsiness, euphoria) and may contribute to MOH.⁸⁰

Non-medication approaches used for the acute treatment of migrainous headaches may also be considered as adjunctive treatment. Several safe and effective neuromodulation devices that stimulate structures involved in the pathophysiology of headache pain (e.g., the trigeminal nerve, vagus nerve, and/or occipital nerve) have been developed for migraine. Though these devices have not been studied specifically in headache related to cerebral neoplasm, they may be considered as acute treatment, particularly if the headache has features of migraine or, in some cases, of cluster headache. Furthermore, when implemented as an acute treatment strategy, neuromodulation has been found to decrease the need for acute analgesics.^{84,85} Hot packs and

cold packs applied to the head also can help headache pain acutely.¹⁸

Preventive Treatment

Though gradual resolution of post-craniotomy headache may occur over time without the need for significant medical treatment for most patients,^{18,63} Schankin et al found that 32% of individuals continue to experience moderate-severe headache pain for more than 6 months following craniotomy.⁸⁶ Despite this, there is a striking paucity of randomized control trials and other literature surrounding the risks and benefits of preventive treatments for individuals with symptomatic post-craniotomy and/or cerebral neoplasm-related headache.⁶⁰ Practically, headache providers may employ evidence-based therapies targeting the headache phenotype (e.g., migraine, tension-type), with the understanding that further trials are needed to understand the benefits and risks of these treatments in individuals with brain tumor.^{13,60,87}

The aims of preventive medication for headache include decreasing headache attack frequency, severity, and duration, as well as headache-related disability. Adequate preventive treatment additionally can improve responsiveness to acute medication treatment.⁸⁸ Initiation of preventive medication for headache can be considered for individuals experiencing at least four headache days per month.^{88,89} Treatments for migraine-like and tension-like headaches in individuals with brain tumor may include conventional, evidence-based migraine therapies that also help with neuropathic pain, such as antidepressants, anticonvulsants, and others (– **Table 5**). Though the primary goal is to treat headaches effectively, a patient's medical and psychiatric comorbidities should be considered when choosing a preventive medication.

The antidepressant medication category includes selective serotonin and norepinephrine reuptake inhibitors (SSRIs and SNRIs), as well as tricyclic antidepressants (TCAs). SNRIs, such as venlafaxine and duloxetine, are considered probably effective as treatment for migraine^{90,91} and tension-type headache,⁹² though they have not been studied specifically in individuals with cerebral neoplasm.^{19,93} SNRIs can help improve comorbidities of neuropathic pain, anxiety, and depression. Dosing for most preventive medications for headache should start low with gradual titration to higher doses to reduce the risk of side effects, which can lead to premature discontinuation. SNRIs may be associated with gastrointestinal side effects. TCAs, such as nortriptyline and amitriptyline, are effective treatments for migraine⁹¹ and tension-type headache.⁹⁴ A common side effect of TCAs is reduction in sleep-onset latency,⁹⁵ which may be used to the patient's advantage if insomnia is a medical comorbidity.

Several anticonvulsant medications can be considered, as well. Gabapentin, an anticonvulsant with limited evidence for the treatment of migraine-type^{96–98} and tension-type⁹⁹ headache, can be used for the treatment of neuropathic pain, anxiety, and focal-onset seizures. In a retrospective study, gabapentin was found to improve postoperative pain and decrease opioid use in post-craniotomy patients,⁷³ and can be particularly effective in individuals with symptoms of hyperalgesia or allodynia.⁶⁵ Gabapentin's wide range of dosing from 100 mg daily to 1,200 mg three times daily allows for convenient gradations in titration when weighing benefit versus risk of side effects (e.g., drowsiness or dizziness). Pregabalin, a gabapentinoid derivative, has similar anticonvulsant and anti-pain properties. In a meta-analysis, pregabalin was not shown to decrease post-surgical pain; however, perioperative pregabalin was associated with reduced opioid consumption after surgery.¹⁰⁰ Topiramate is considered a highly effective treatment for the prevention of migraine^{88,101} and has limited evidence for the treatment of tension-type headache.¹⁰² Topiramate has been used for post-craniotomy pain, particularly when the pain has neuropathic features and/or there is trigeminal nerve involvement.⁶⁵

Memantine is a glutamate antagonist that has been used increasingly for the prevention of migraine,^{88,103,104} tension-type,¹⁰⁵ and posttraumatic headache.⁸⁷ In one study, memantine was found to have a short window of titration (3 days) to full benefit, while also demonstrating a minimal side effect profile.¹⁰⁶ Memantine additionally has been shown to help associated cognitive dysfunction in individuals receiving whole brain radiation.¹⁰⁷

The new CGRP monoclonal antibodies (e.g., erenumab, fremanezumab, galcanezumab, and eptinezumab) and gepants (e.g., atogepant, rimegepant) for the prevention of migraine headache have not been studied in individuals with post-craniotomy headache or headache related to brain tumor. These can be considered in individuals with migraine-phenotype headache. CGRP receptor antibodies also may have a neuroprotective role, and the possibility that CGRP antibodies could be used as an anti-tumor agent has been proposed.^{108–110} With this uncertainty, the decision to start an anti-CGRP medication in individuals with migraine

and brain tumor should be considered a risk–benefit analysis, made on a case-by-case basis.

Other medical interventions, such as muscle relaxants (e.g., tizanidine) and nerve blocks (e.g., occipital nerve block, cervical trigger point injections), may be used in individuals with migraine and tension-type headache, and can be considered for symptomatic benefit in patients with headache related to cerebral neoplasm.^{19,111} OnabotulinumtoxinA injection, an effective treatment for chronic migraine,¹¹² has been shown in several case series to improve post-craniotomy headache, and can be considered if the individual's headache meets chronic migraine diagnostic criteria.^{65,113,114}

Non-pharmacologic treatments for migraine, tension-type headache, and cluster headache can be considered in a patient with the appropriate headache phenotype. Nutra-ceuticals, such as riboflavin, magnesium, coenzyme Q10, and feverfew, have variable evidence for the preventive treatment of migraine. Involved in cellular energy production, riboflavin is a well-tolerated and cost-effective supplement that has been shown in several randomized controlled trials to reduce migraine frequency, though other studies have failed to show benefit.^{115,116} Low magnesium levels associated with mitochondrial dysfunction have been identified in migraine.^{117,118} Two randomized control trials have suggested benefit from daily magnesium supplementation for migraine prevention, while other studies have shown no benefit.^{116,119,120} Coenzyme Q10 supplementation is thought to have protective and supportive roles for mitochondrial function, and is considered a possibly effective migraine treatment.¹¹⁶ Though butterbur has strong evidence in migraine prevention, it is not recommended due to risk of hepatotoxicity.¹²¹

Several neuromodulation devices, as described above, have been approved for migraine and cluster headache prevention, and may be considered in patients with these headache phenotypes.¹²² Attention should be paid to whether the patient has history of seizure, as this may influence choice of neuromodulation device. In addition, physical therapy and massage therapy help with contributory neck tension.¹⁹ Behavioral interventions, such as biofeedback, cognitive behavioral therapy, and relaxation techniques, have grade A evidence as preventive treatment for migraine and can reduce headache-related outcomes by 35 to 55%, even in individuals without comorbid anxiety and depression.^{123–125} Lifestyle modifications, such as exercising frequently, maintaining healthy nutrition, managing obesity, and obtaining good quality sleep, have evidence in the treatment of migraine.^{126,127}

Comorbidities associated with headache exacerbation should be assessed. Individuals living with cerebral neoplasm commonly experience anxiety and depression, and further depressive symptoms may develop after brain surgery.¹²⁸ In migraine, anxiety and depression have been associated with increased headache-related disability, and interventions targeting these psychiatric comorbidities may lead to improvement in disability.¹²⁹ Other comorbidities, such as musculoskeletal conditions, temporomandibular disorder, chronic pain, and seizure, should be evaluated, as

some treatments may help both headache and these conditions.⁶⁵

Conclusions

Though most of the general population will experience a headache at some time, cerebral neoplasm as the cause of headache is rare. Individuals presenting with progressive headache, focal neurological signs or symptoms, and those with other features of the SNNOOP10 criteria warrant consideration of additional workup for secondary etiology of headache.

Risk factors for the development of headache in individuals with cerebral neoplasm include a prior history of headache and a larger tumor burden with midline shift.²⁴ Structure and function-related pain mechanisms (e.g., from compression of pain-sensitive structures and/or intracranial hypertension) may contribute to headache.

An individualized headache treatment approach should be developed using shared decision-making and consideration of the patient's goals of care. Patients should be monitored for tumor-related intracranial hypertension and treated appropriately with dexamethasone or neurosurgical intervention, if indicated. Though headache due to cerebral neoplasm often improves with neurosurgical intervention, many patients continue to experience chronic headaches after craniotomy and are at risk of undertreatment. At the same time, an underlying diagnosis of MOH should be identified early on, and treatment for this condition should be implemented so that optimal benefit of headache-related treatments can be achieved.

For individuals with headache related to brain tumor, a multimodal treatment approach incorporating pharmacologic and nonpharmacologic strategies should be used. Though a paucity of literature regarding acute and preventive treatments for headache related to cerebral neoplasm and post-craniotomy headache exists, symptomatic treatment may be based upon conventional therapies for the patient's headache phenotype, including acute and preventive medications, nutraceuticals, neuromodulation devices, behavioral interventions, anesthetic nerve blocks, and lifestyle changes. Additionally, an individual's headache-related comorbidities should be addressed, while understanding the patient's social determinants of health and prioritizing patient function and quality of life.

Conflict of Interest

None declared.

References

- Rasmussen BK, Jensen R, Schroll M, Olesen J. Epidemiology of headache in a general population – a prevalence study. *J Clin Epidemiol* 1991;44(11):1147–1157
- Headache Classification Committee of the International Headache Society (IHS) The International Classification of Headache Disorders, 3rd edition. *Cephalalgia*. 2018;38(01):1-211. doi: 10.1177/0333102417738202
- Lipton RB, Bigal ME, Steiner TJ, Silberstein SD, Olesen J. Classification of primary headaches. *Neurology* 2004;63(03):427–435
- Kurth T, Buring JE, Rist PM. Headache, migraine and risk of brain tumors in women: prospective cohort study. *J Headache Pain* 2015;16(01):501
- Ostrom QT, Price M, Neff C, et al. CBTRUS Statistical Report: primary brain and other central nervous system tumors diagnosed in the United States in 2015–2019. *Neuro-oncol* 2022;24 (suppl 5):v1–v95
- Martínez Barbero JP, Láinez Ramos-Bossini AJ, Rivera-Izquierdo M, Sendra-Portero F, Benítez-Sánchez JM, Cervilla JA. Prevalence and risk factors associated with tumors and other structural anomalies in brain MRI performed to rule out secondary headache: a multicenter observational study. *Int J Environ Res Public Health* 2022;19(06):3521
- McFaline-Figueroa JR, Lee EQ. Brain tumors. *Am J Med* 2018;131 (08):874–882
- Davis FG, Dolecek TA, McCarthy BJ, Villano JL. Toward determining the lifetime occurrence of metastatic brain tumors estimated from 2007 United States cancer incidence data. *Neuro-oncol* 2012;14(09):1171–1177
- Nelson S, Taylor LP. Headaches in brain tumor patients: primary or secondary? *Headache* 2014;54(04):776–785
- Schankin CJ, Ferrari U, Reinisch VM, Birnbaum T, Goldbrunner R, Straube A. Characteristics of brain tumour-associated headache. *Cephalalgia* 2007;27(08):904–911
- Kirby S, Purdy RA. Headaches and brain tumors. *Neuro Clin* 2014;32(02):423–432
- Abrams BM. Medication overuse headaches. *Med Clin North Am* 2013;97(02):337–352
- Palmieri A, Valentinis L, Zanchin G. Update on headache and brain tumors. *Cephalalgia* 2021;41(04):431–437
- Forsyth PA, Posner JB. Headaches in patients with brain tumors: a study of 111 patients. *Neurology* 1993;43(09):1678–1683
- Valentinis L, Tuniz F, Valent F, et al. Headache attributed to intracranial tumours: a prospective cohort study. *Cephalalgia* 2010;30(04):389–398
- Pfund Z, Szapáry L, Jászberényi O, Nagy F, Czopf J. Headache in intracranial tumors. *Cephalalgia* 1999;19(09):787–790, discussion 765
- Taylor LP. Mechanism of brain tumor headache. *Headache* 2014; 54(04):772–775
- Gee JR, Ishaq Y, Vijayan N. Postcraniotomy headache. *Headache* 2003;43(03):276–278
- Stec NE, Walbert T. Neuro-oncology and supportive care: the role of the neurologist. *Neurol Sci* 2022;43(02):939–950
- Edvardsson B. Symptomatic cluster headache: a review of 63 cases. *Springerplus* 2014;3(01):64
- Bosco D, Belfiore A, Fava A, et al. Relationship between high prolactin levels and migraine attacks in patients with microprolactinoma. *J Headache Pain* 2008;9(02):103–107
- Hadidchi S, Surento W, Lerner A, et al. Headache and brain tumor. *Neuroimaging Clin N Am* 2019;29(02):291–300
- Suwanwela N, Phanthumchinda K, Kaorophum S. Headache in brain tumor: a cross-sectional study. *Headache* 1994;34(07): 435–438
- Loghin M, Levin VA. Headache related to brain tumors. *Curr Treat Options Neurol* 2006;8(01):21–32
- Chou DE. Secondary headache syndromes. *Continuum (Minneapolis)* 2018;24(4, Headache):1179–1191
- Boiardi A, Salmaggi A, Eoli M, Lamperti E, Silvani A. Headache in brain tumours: a symptom to reappraise critically. *Neurol Sci* 2004;25(suppl 3):S143–S147
- Clarke CE, Edwards J, Nicholl DJ, Sivaguru A. Imaging results in a consecutive series of 530 new patients in the Birmingham Headache Service. *J Neurol* 2010;257(08):1274–1278

- 28 Mezzacappa FM, Thorell W. Neuronal Brain Tumors. In: StatPearls. StatPearls Publishing; 2022. Accessed January 22, 2023 at: <http://www.ncbi.nlm.nih.gov/books/NBK576406/>
- 29 Do TP, Remmers A, Schytz HW, et al. Red and orange flags for secondary headaches in clinical practice: SNN00P10 list. *Neurology* 2019;92(03):134–144
- 30 Behin A, Hoang-Xuan K, Carpentier AF, Delattre JY. Primary brain tumours in adults. *Lancet* 2003;361(9354):323–331
- 31 Eller M, Goadsby PJ. MRI in headache. *Expert Rev Neurother* 2013;13(03):263–273
- 32 Vernooij MW, Ikram MA, Tanghe HL, et al. Incidental findings on brain MRI in the general population. *N Engl J Med* 2007;357(18):1821–1828
- 33 Doherty CM, Forbes RB. Diagnostic lumbar puncture. *Ulster Med J* 2014;83(02):93–102
- 34 Jordan JE, Ramirez GF, Bradley WG, Chen DY, Lightfoote JB, Song A. Economic and outcomes assessment of magnetic resonance imaging in the evaluation of headache. *J Natl Med Assoc* 2000;92(12):573–578
- 35 de Coo IF, Wilbrink LA, Haan J. Symptomatic trigeminal autonomic cephalalgias. *Curr Pain Headache Rep* 2015;19(08):39
- 36 Cittadini E, Matharu MS. Symptomatic trigeminal autonomic cephalalgias. *Neurologist* 2009;15(06):305–312
- 37 De Pue A, Lutin B, Paemeleire K. Chronic cluster headache and the pituitary gland. *J Headache Pain* 2016;17(01):23
- 38 Mitsikostas DD, Ashina M, Craven A, et al; EHF Committee. European Headache Federation consensus on technical investigation for primary headache disorders. *J Headache Pain* 2015;17(01):5
- 39 Burish M. Cluster headache and other trigeminal autonomic cephalalgias. *Continuum (Minneapolis)* 2018;24(4, Headache):1137–1156
- 40 Williams M, Bazina R, Tan L, Rice H, Broadley SA. Microvascular decompression of the trigeminal nerve in the treatment of SUNCT and SUNA. *J Neurol Neurosurg Psychiatry* 2010;81(09):992–996
- 41 Ray BS. Experimental studies on headache: pain-sensitive structures of the head and their significance in headache. *Arch Surg* 1940;41(04):813
- 42 Obermann M, Holle D, Naegel S, Diener HC. Headache attributable to nonvascular intracranial disorders. *Curr Pain Headache Rep* 2011;15(04):314–323
- 43 Kunkle EC, Ray BS, Wolff HG. Studies on headache: the mechanisms and significance of the headache associated with brain tumor. *Bull N Y Acad Med* 1942;18(06):400–422
- 44 Goffaux P, Fortin D. Brain tumor headaches: from bedside to bench. *Neurosurgery* 2010;67(02):459–466
- 45 Kahn K, Finkel A. It IS a tumor – current review of headache and brain tumor. *Curr Pain Headache Rep* 2014;18(06):421
- 46 Bello C, Anderegg L, Luedi MM, Beilstein CM. Postcraniotomy headache: etiologies and treatments. *Curr Pain Headache Rep* 2022;26(05):357–364
- 47 Levy MJ, Matharu M, Goadsby PJ. Chronic headache and pituitary tumors. *Curr Pain Headache Rep* 2008;12(01):74–78
- 48 Giglio P, Gilbert MR. Neurologic complications of cancer and its treatment. *Curr Oncol Rep* 2010;12(01):50–59
- 49 Newton HB. Neurological complications of chemotherapy to the central nervous system. *Handb Clin Neurol* 2012;105:903–916
- 50 Cavaliere R, Schiff D. Neurologic toxicities of cancer therapies. *Curr Neurol Neurosci Rep* 2006;6(03):218–226
- 51 Perkins A, Liu G. Primary brain tumors in adults: diagnosis and treatment. *Am Fam Physician* 2016;93(03):211–217
- 52 Jha SK. Cerebral edema and its management. *Med J Armed Forces India* 2003;59(04):326–331
- 53 Vecht CJ, Hovestadt A, Verbiest HBC, van Vliet JJ, van Putten WLJ. Dose-effect relationship of dexamethasone on Karnofsky performance in metastatic brain tumors: a randomized study of doses of 4, 8, and 16 mg per day. *Neurology* 1994;44(04):675–680
- 54 Wong TT, Liang ML, Chen HH, Chang FC. Hydrocephalus with brain tumors in children. *Childs Nerv Syst* 2011;27(10):1723–1734
- 55 Khan F, Rehman A, Shamim MS, Bari ME. Factors affecting ventriculoperitoneal shunt survival in adult patients. *Surg Neurol Int* 2015;6(01):25
- 56 Hosainey SAM, Hald JK, Meling TR. Risk of early failure of VP shunts implanted for hydrocephalus after craniotomies for brain tumors in adults. *Neurosurg Rev* 2022;45(01):479–490
- 57 Walbert T, Khan M. End-of-life symptoms and care in patients with primary malignant brain tumors: a systematic literature review. *J Neurooncol* 2014;117(02):217–224
- 58 Scotton WJ, Botfield HF, Westgate CS, et al. Topiramate is more effective than acetazolamide at lowering intracranial pressure. *Cephalalgia* 2019;39(02):209–218
- 59 Ravn Munkvold BK, Sagberg LM, Jakola AS, Solheim O. Preoperative and postoperative headache in patients with intracranial tumors. *World Neurosurg* 2018;115:e322–e330
- 60 Rocha-Filho PAS. Post-craniotomy headache: a clinical view with a focus on the persistent form. *Headache* 2015;55(05):733–738
- 61 de Gray LC, Matta BF. Acute and chronic pain following craniotomy: a review. *Anaesthesia* 2005;60(07):693–704
- 62 Haldar R, Kaushal A, Gupta D, Srivastava S, Singh PK. Pain following craniotomy: reassessment of the available options. *BioMed Res Int* 2015;2015:509164
- 63 De Benedittis G, Lorenzetti A, Migliore M, Spagnoli D, Tiberio F, Villani RM. Postoperative pain in neurosurgery: a pilot study in brain surgery. *Neurosurgery* 1996;38(03):466–469, discussion 469–470
- 64 Nguyen A, Girard F, Boudreault D, et al. Scalp nerve blocks decrease the severity of pain after craniotomy. *Anesth Analg* 2001;93(05):1272–1276
- 65 Lutman B, Bloom J, Nussenblatt B, Romo V. A contemporary perspective on the management of post-craniotomy headache and pain. *Curr Pain Headache Rep* 2018;22(10):69
- 66 Ryzenman JM, Pensak ML, Tew JM Jr. Headache: a quality of life analysis in a cohort of 1,657 patients undergoing acoustic neuroma surgery, results from the acoustic neuroma association. *Laryngoscope* 2005;115(04):703–711
- 67 Narita Y. Drug review: safety and efficacy of bevacizumab for glioblastoma and other brain tumors. *Jpn J Clin Oncol* 2013;43(06):587–595
- 68 Wong J, Hird A, Zhang L, et al. Symptoms and quality of life in cancer patients with brain metastases following palliative radiotherapy. *Int J Radiat Oncol Biol Phys* 2009;75(04):1125–1131
- 69 Molnár L, Simon É, Nemes R, Fülesdi B, Molnár C. Postcraniotomy headache. *J Anesth* 2014;28(01):102–111
- 70 Patel KS, Laiwalla AN, DiCesare JAT, Garrett MC, Wang AC. Subcutaneous sumatriptan: association with decreases in postoperative pain and opioid use after elective cranial surgery. *J Neurosurg* 2020. Doi: 10.3171/2019.10.JNS192503
- 71 Venkatraghavan L, Li L, Bailey T, Manninen PH, Tymianski M. Sumatriptan improves postoperative quality of recovery and reduces postcraniotomy headache after cranial nerve decompression. *Br J Anaesth* 2016;117(01):73–79
- 72 Guilfoyle MR, Helmy A, Duane D, Hutchinson PJA. Regional scalp block for postcraniotomy analgesia: a systematic review and meta-analysis. *Anesth Analg* 2013;116(05):1093–1102
- 73 Türe H, Sayin M, Karlikaya G, Bingol CA, Aykac B, Türe U. The analgesic effect of gabapentin as a prophylactic anticonvulsant drug on postcraniotomy pain: a prospective randomized study. *Anesth Analg* 2009;109(05):1625–1631
- 74 Cheung V, Amoozegar F, Dilli E. Medication overuse headache. *Curr Neurol Neurosci Rep* 2015;15(01):509
- 75 Tepper SJ. Medication-overuse headache. *Continuum (Minneapolis)* 2012;18(04):807–822
- 76 Evers S, Marziniak M. Clinical features, pathophysiology, and treatment of medication-overuse headache. *Lancet Neurol* 2010;9(04):391–401

- 77 Bigal ME, Lipton RB. Excessive acute migraine medication use and migraine progression. *Neurology* 2008;71(22):1821–1828
- 78 Johnson JL, Hutchinson MR, Williams DB, Rolan P. Medication-overuse headache and opioid-induced hyperalgesia: a review of mechanisms, a neuroimmune hypothesis and a novel approach to treatment. *Cephalalgia* 2013;33(01):52–64
- 79 Bigal ME, Serrano D, Buse D, Scher A, Stewart WF, Lipton RB. Acute migraine medications and evolution from episodic to chronic migraine: a longitudinal population-based study. *Headache* 2008;48(08):1157–1168
- 80 Saengjaroenatham C, Strother LC, Dripps I, et al. Differential medication overuse risk of novel anti-migraine therapeutics. *Brain* 2020;143(09):2681–2688
- 81 Croop R, Madonia J, Stock DA, et al. Zavegepant nasal spray for the acute treatment of migraine: a Phase 2/3 double-blind, randomized, placebo-controlled, dose-ranging trial. *Headache* 2022;62(09):1153–1163
- 82 Mathew PG, Klein BC. Getting to the heart of the matter: migraine, triptans, DHE, ditans, CGRP antibodies, first/second-generation gepants, and cardiovascular risk. *Headache* 2019;59(08):1421–1426
- 83 Robbins MS. Diagnosis and management of headache: a review. *JAMA* 2021;325(18):1874–1885
- 84 Di Fiore P, Galli A, D'Arrigo G, et al. Transcutaneous supraorbital neurostimulation for acute treatment of chronic migraine: open-label preliminary data. *Neuro Sci* 2018;39(suppl 1):163–164
- 85 Urits I, Schwartz R, Smoots D, et al. Peripheral neuromodulation for the management of headache. *Anesth Pain Med* 2020;10(06):e110515
- 86 Schankin CJ, Gall C, Straube A. Headache syndromes after acoustic neuroma surgery and their implications for quality of life. *Cephalalgia* 2009;29(07):760–771
- 87 Kamins J, Charles A. Posttraumatic headache: basic mechanisms and therapeutic targets. *Headache* 2018;58(06):811–826
- 88 Ailani J, Burch RC, Robbins MS Board of Directors of the American Headache Society. The American Headache Society Consensus Statement: update on integrating new migraine treatments into clinical practice. *Headache* 2021;61(07):1021–1039
- 89 Lipton RB, Bigal ME, Diamond M, Freitag F, Reed ML, Stewart WF AMP Advisory Group. Migraine prevalence, disease burden, and the need for preventive therapy. *Neurology* 2007;68(05):343–349
- 90 Ozyalcin SN, Talu GK, Kiziltan E, Yucel B, Ertas M, Disci R. The efficacy and safety of venlafaxine in the prophylaxis of migraine. *Headache* 2005;45(02):144–152
- 91 Burch R. Antidepressants for preventive treatment of migraine. *Curr Treat Options Neurol* 2019;21(04):18
- 92 Zissis NP, Harmoussi S, Vlaikidis N, et al. A randomized, double-blind, placebo-controlled study of venlafaxine XR in outpatients with tension-type headache. *Cephalalgia* 2007;27(04):315–324
- 93 Walbert T, Stec NE. Palliative care in brain tumors. *Handb Clin Neurol* 2023;191:69–80
- 94 Jackson JL, Mancuso JM, Nickoloff S, Bernstein R, Kay C. Tricyclic and tetracyclic antidepressants for the prevention of frequent episodic or chronic tension-type headache in adults: a systematic review and meta-analysis. *J Gen Intern Med* 2017;32(12):1351–1358
- 95 Pringsheim T, Davenport WJ, Becker WJ. Prophylaxis of migraine headache. *CMAJ* 2010;182(07):E269–E276
- 96 Mathew NT, Rapoport A, Saper J, Magnus L, Klapper J, Ramadan N, Stacey B, Tepper S. Efficacy of gabapentin in migraine prophylaxis. *Headache: The Journal of Head and Face Pain* 2001 Feb 2;41(02):119–128
- 97 Di Trapani G, Mei D, Marra C, Mazza S, Capuano A. Gabapentin in the prophylaxis of migraine: a double-blind randomized placebo-controlled study. *Clin Ter* 2000;151(03):145–148
- 98 Linde M, Mulleners WM, Chronicle EP, McCrory DC. Gabapentin or pregabalin for the prophylaxis of episodic migraine in adults. *Cochrane Database Syst Rev* 2013;2013(06):CD010609
- 99 Spira PJ, Beran RG Australian Gabapentin Chronic Daily Headache Group. Gabapentin in the prophylaxis of chronic daily headache: a randomized, placebo-controlled study. *Neurology* 2003;61(12):1753–1759
- 100 Zhang J, Ho KY, Wang Y. Efficacy of pregabalin in acute postoperative pain: a meta-analysis. *Br J Anaesth* 2011;106(04):454–462
- 101 Silberstein SD, Neto W, Schmitt J, Jacobs DMIGR-001 Study Group. Topiramate in migraine prevention: results of a large controlled trial. *Arch Neurol* 2004;61(04):490–495
- 102 Lampl C, Marecek S, May A, Bendtsen L. A prospective, open-label, long-term study of the efficacy and tolerability of topiramate in the prophylaxis of chronic tension-type headache. *Cephalalgia* 2006;26(10):1203–1208
- 103 Charles A, Flippin C, Romero Reyes M, Brennan KC. Memantine for prevention of migraine: a retrospective study of 60 cases. *J Headache Pain* 2007;8(04):248–250
- 104 Mistry VM, Morizio PL, Pepin MJ, Bryan WE, Brown JN. Role of memantine in the prophylactic treatment of episodic migraine: a systematic review. *Headache* 2021;61(08):1207–1213
- 105 Lindelof K, Bendtsen L. Memantine for prophylaxis of chronic tension-type headache – a double-blind, randomized, crossover clinical trial. *Cephalalgia* 2009;29(03):314–321
- 106 Noruzzadeh R, Modabbernia A, Aghamollai V, et al. Memantine for prophylactic treatment of migraine without aura: a randomized double-blind placebo-controlled study. *Headache* 2016;56(01):95–103
- 107 Brown PD, Pugh S, Laack NN, et al; Radiation Therapy Oncology Group (RTOG) Memantine for the prevention of cognitive dysfunction in patients receiving whole-brain radiotherapy: a randomized, double-blind, placebo-controlled trial. *Neuro-oncol* 2013;15(10):1429–1437
- 108 Majima M, Ito Y, Hosono K, Amano H. CGRP/GRP receptor antibodies: Potential adverse effects due to blockade of neovascularization? *Trends Pharmacol Sci* 2019;40(01):11–21
- 109 Borkum JM. CGRP and brain functioning: cautions for migraine treatment. *Headache* 2019;59(08):1339–1357
- 110 Lv X, Chen Q, Zhang S, Gao F, Liu Q. CGRP: a new endogenous cell stemness maintenance molecule. *Oxid Med Cell Longev* 2022;2022:4107433
- 111 Potters JW, Klimek M. Local anesthetics for brain tumor resection: current perspectives. *Local Reg Anesth* 2018;11:1–8
- 112 Dodick DW, Turkel CC, DeGryse RE, et al; PREEMPT Chronic Migraine Study Group. OnabotulinumtoxinA for treatment of chronic migraine: pooled results from the double-blind, randomized, placebo-controlled phases of the PREEMPT clinical program. *Headache* 2010;50(06):921–936
- 113 Ranoux D, Martiné G, Espagne G, Salle H, Caire F. Delayed-onset post-craniotomy headache responsive to botulinum toxin A: a case series. *Acta Neurochir (Wien)* 2017;159(08):1375–1378
- 114 MacKenzie HM, Teasell R, Miller TA, Sequeira K. Peri-incisional botulinum toxin for chronic postcraniotomy headache after traumatic brain injury: a case series. *PM R* 2015;7(07):785–788
- 115 Thompson DF, Saluja HS. Prophylaxis of migraine headaches with riboflavin: a systematic review. *J Clin Pharm Ther* 2017;42(04):394–403
- 116 Rajapakse T, Pringsheim T. Nutraceuticals in migraine: a summary of existing guidelines for use. *Headache* 2016;56(04):808–816
- 117 Dolati S, Rikhtegar R, Mehdizadeh A, Yousefi M. The role of magnesium in pathophysiology and migraine treatment. *Biol Trace Elem Res* 2020;196(02):375–383
- 118 Lodi R, Iotti S, Cortelli P, et al. Deficient energy metabolism is associated with low free magnesium in the brains of patients

- with migraine and cluster headache. *Brain Res Bull* 2001;54(04):437–441
- 119 Peikert A, Wilimzig C, Köhne-Volland R. Prophylaxis of migraine with oral magnesium: results from a prospective, multi-center, placebo-controlled and double-blind randomized study. *Cephalalgia* 1996;16(04):257–263
- 120 Teigen L, Boes CJ. An evidence-based review of oral magnesium supplementation in the preventive treatment of migraine. *Cephalalgia* 2015;35(10):912–922
- 121 Wells RE, Beuthin J, Granetzke L. Complementary and integrative medicine for episodic migraine: an update of evidence from the last 3 years. *Curr Pain Headache Rep* 2019;23(02):10
- 122 Halker Singh RB, Ailani J, Robbins MS. Neuromodulation for the acute and preventive therapy of migraine and cluster headache. *Headache* 2019;59(suppl 2):33–49
- 123 Silberstein SD. Practice parameter: evidence-based guidelines for migraine headache (an evidence-based review): report of the Quality Standards Subcommittee of the American Academy of Neurology. *Neurology* 2000;55(06):754–762
- 124 Penzien DB, Rains JC, Andrasik F. Behavioral management of recurrent headache: three decades of experience and empiricism. *Appl Psychophysiol Biofeedback* 2002;27(02):163–181
- 125 Paul HA. *Biofeedback: A Practitioner's Guide*, edited by M. Schwartz & F. Andrasik: 2016. New York, NY: The Guilford Press, xx+ 764 pp., 115.00 (hardcover), 60.00 (paperback)
- 126 Agbetou M, Adoukonou T. Lifestyle modifications for migraine management. *Front Neurol* 2022;13:719467
- 127 Gaul C, van Doorn C, Webering N, et al. Clinical outcome of a headache-specific multidisciplinary treatment program and adherence to treatment recommendations in a tertiary headache center: an observational study. *J Headache Pain* 2011;12(04):475–483
- 128 D'Angelo C, Mirijello A, Leggio L, et al. State and trait anxiety and depression in patients with primary brain tumors before and after surgery: 1-year longitudinal study. *J Neurosurg* 2008;108(02):281–286
- 129 Lipton RB, Seng EK, Chu MK, et al. The effect of psychiatric comorbidities on headache-related disability in migraine: results from the Chronic Migraine Epidemiology and Outcomes (CaMEO) Study. *Headache* 2020;60(08):1683–1696
- 130 Schwedt TJ. Thunderclap headache. *Continuum (Minneapolis)* 2015;21(4 Headache):1058–1071
- 131 Blumenfeld A, Silberstein SD, Dodick DW, Aurora SK, Turkel CC, Binder WJ. Method of injection of onabotulinumtoxinA for chronic migraine: a safe, well-tolerated, and effective treatment paradigm based on the PREEMPT clinical program. *Headache* 2010;50(09):1406–1418
- 132 Pizzolato R, Villani V, Prosperini L, Ciuffoli A, Sette G. Efficacy and tolerability of pregabalin as preventive treatment for migraine: a 3-month follow-up study. *J Headache Pain* 2011;12(05):521–525
- 133 Calandre EP, Garcia-Leiva JM, Rico-Villademoros F, Vilchez JS, Rodriguez-Lopez CM. Pregabalin in the treatment of chronic migraine: an open-label study. *Clin Neuropharmacol* 2010;33(01):35–39
- 134 Rizzato B, Leone G, Misaggi G, Zivi I, Diomedei M. Efficacy and tolerability of pregabalin versus topiramate in the prophylaxis of chronic daily headache with analgesic overuse: an open-label prospective study. *Clin Neuropharmacol* 2011;34(02):74–78
- 135 Goadsby PJ, Dodick DW, Ailani J, et al. Safety, tolerability, and efficacy of orally administered atogepant for the prevention of episodic migraine in adults: a double-blind, randomised phase 2b/3 trial. *Lancet Neurol* 2020;19(09):727–737
- 136 Croop R, Lipton RB, Kudrow D, et al. Oral rimegepant for preventive treatment of migraine: a phase 2/3, randomised, double-blind, placebo-controlled trial. *Lancet* 2021;397(10268):51–60