

# Endometriosis: An Overview

Tanvir Agnihotri, MD<sup>1</sup> Abheek Ghosh, BS<sup>2</sup> Ashley Lamba, BS<sup>3</sup> Charles E. Ray, Jr., MD, PhD<sup>4</sup>

<sup>1</sup>Department of Radiology, New York University School of Medicine, New York, New York

<sup>2</sup>University of Maryland School of Medicine, Baltimore, Maryland

<sup>3</sup>Zucker School of Medicine at Hofstra/Northwell, Manhasset, New York

<sup>4</sup>Department of Radiology, University of Illinois College of Medicine, Chicago, Illinois

Address for correspondence Charles E. Ray, Jr., MD, PhD, Department of Radiology, University of Illinois at Chicago, 1740 W. Taylor Street, MC 391, Chicago, IL 60612 (e-mail: chray@uic.edu).

Semin Intervent Radiol 2023;40:544–548

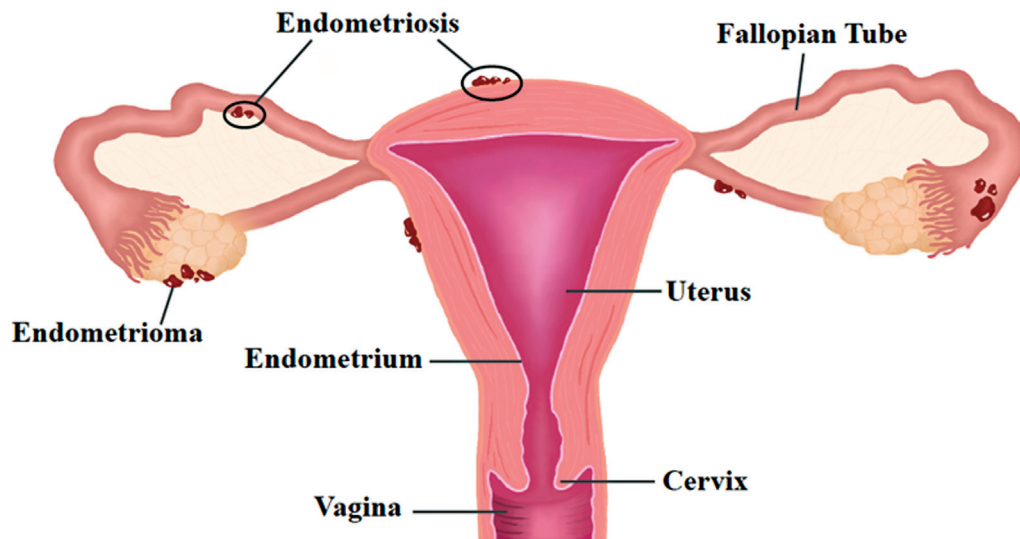
Endometriosis is a chronic, inflammatory gynecological condition defined by the presence of endometrial-like epithelium and/or stroma outside of the uterus (► **Fig. 1**). Endometriosis exists on a spectrum of presentations and can be further classified by location into superficial peritoneal (lesions involving the peritoneal surface), ovarian (formation of endometriomas or “chocolate cysts” on the ovaries typically containing ectopic tissue and bloody fluid), deep (nodular implantation of tissue into the peritoneal surface with associated fibrosis), extra-abdominal (outside the abdomen), and iatrogenic (dissemination of endometrium following surgery).<sup>1</sup> The clinical presentation of endometriosis is variable, and depends on the subtype of endometriosis and location(s) of involvement. While up to 20 to 25% of patients are asymptomatic, common clinical features include chronic pelvic pain which worsens prior to the onset of menses, dysmenorrhea, dyspareunia, and infertility.<sup>2,3</sup> Despite its strong link to infertility in women, the pathophysiology of endometriosis remains poorly understood. Postulated to be a combination of the development of a pro-invasive inflammatory milieu by endometrial cells and retrograde flux of endometrial tissue through the fallopian tubes into and beyond the endometrial cavity, there remains a lack of consensus regarding the etiology of endometriosis.<sup>1</sup> Furthermore, this explanation does not account for the disparity between women with retrograde flow, seen in up to 90% of women, and the eventual development of endometriosis.<sup>4</sup> With studies approximating the prevalence of endometriosis between 25 and 50% in infertile women, optimization of obstetric outcomes is a priority among patients seeking treatment.<sup>3</sup> While surgical outcomes typically improve symptoms and increase the pregnancy rate, they come with appreciable risk of damage to the ovaries and diminished ovarian reserve.<sup>5</sup> Given the significant morbidity and impairment in fertility associated with endometriosis, its examination as a clinical entity, as well as the limitations and advantages in its treatment, is warranted.

## Epidemiology

Endometriosis most commonly affects individuals aged 18 to 45 years, and is associated with several risk and protective factors.<sup>6</sup> Factors associated with increased risk include family history, taller height, shorter menstrual cycle length, earlier age at menarche, alcohol use, and caffeine intake.<sup>6</sup> Interestingly, protective factors include smoking, higher body mass index, regular exercise, oral contraceptive use, and higher intake of omega 3 fatty acids.<sup>6</sup> The incidence and prevalence of endometriosis are poorly understood, largely given the significant proportion of asymptomatic patients, heterogeneity in its classification within literature, and barriers to its diagnosis. As such, the range reported in literature greatly varies with prior meta-analyses noting a prevalence range from 0.2 to 71.4% depending on the population sampled, and current studies reflecting a stable prevalence rate across the past 30 years.<sup>7</sup> There remains a lack of consensus on the trajectory of incidence, with estimates ranging from a 1.6% increase in incidence to a 61% decrease overtime (116 per 100,000 women in the 1980s to 45 per 100,000 in the 2010s).<sup>8–13</sup> This disagreement within literature can be largely attributed to the significant challenges in diagnosis of endometriosis, and the average delay between clinical presentation and diagnosis in symptomatic patients.

## Diagnosis

For a confirmatory diagnosis of endometriosis, laparoscopic inspection with histologic confirmation is the gold standard.<sup>14</sup> However, the diagnosis of endometriosis is typically step-wise, with the decision to pursue laparoscopy aided by clinical presentation and imaging. Clinical suspicion typically arises in patients with a constellation of symptoms, namely dysuria, chronic pelvic pain, and dyspareunia, and in patients with infertility issues and inconclusive workup based on history and physical.<sup>14</sup> The most common physical



**Fig. 1** Endometriosis is a chronic, inflammatory gynecological condition marked by the growth of endometrial-like epithelium and/or stroma outside of the uterus. Endometriotic lesions located within the ovary are referred to as endometriomas.

exam findings are visible blue, red, or hemorrhagic nodules on the vagina or cervix, posterior vaginal fornix tenderness, and uterine motion tenderness.<sup>15</sup> Transvaginal ultrasound is considered an appropriate initial imaging modality for endometriosis, with lesions varying in presentation based on their locations and internal contents.<sup>16</sup> Typically, lesions appear as uni-/multilocular cysts with ground-glass echogenicity, and are avascular on color Doppler ultrasonography. Magnetic resonance imaging (MRI) is used as a second-line diagnostic modality for further characterization of lesions identified on ultrasound, in patients with high clinical suspicion who have not yet received imaging or those who opt against laparoscopic intervention. Sensitivity and specificity of ultrasound in the detection of endometriosis varies based on the subtype of endometriosis and approach utilized. A transvaginal approach has a sensitivity and specificity of 62 to 73% and 67 to 93%, respectively, for endometriosis diagnosis.<sup>17,18</sup> Across subtypes of endometriosis, MRI has superior sensitivity and specificity when compared with ultrasound in the detection or exclusion of endometriosis.<sup>19</sup>

Endometriosis is typically classified into four stages, as per the American Society for Reproductive Medicine (rASRM). The rASRM classification segments patients into four groups, stage 1 (minimal), stage 2 (mild), stage 3 (moderate), stage 4 (severe). Patients are classified by taking into account the presence of posterior cul-de-sac obliteration, location and site of implants, density of adhesions, and location of adhesions.<sup>20,21</sup>

## Existing Treatment Modalities

Endometriosis management depends on severity of symptoms and can be stratified based on decision to pursue medical versus interventional management, and on the goals of the patient themselves. In patients primarily managing pain with no efforts to conceive, NSAIDs, combined hormonal contraceptives, dienogest, medroxyprogesterone acetate,

and levonorgestrel intrauterine device implantation are considered first-line treatment.<sup>22–26</sup> Second-line therapies used are GnRH agonists such as leuprolide acetate, GnRH antagonists such as elagolix, and aromatase inhibitors.<sup>22–24</sup>

In those seeking to conceive, literature has shown a benefit in removing endometrial implants on fertility outcomes when compared with symptomatic management. In general, laparoscopic resection and ablation have been shown to result in higher rates of conception when compared against laparotomy.<sup>27,28</sup> Patients in stage 1 and stage 2 endometriosis with a history of infertility may experience increased conception rates, ~8.6% greater when compared with no intervention, in the year following surgery.<sup>29,30</sup> For moderate to severe disease, or in patients with “deep” endometriosis, expectant management has been shown to have pregnancy rates as low as 33% in stage 3 and 0% in stage 4. In these patients, laparoscopic resection has been shown to improve pregnancy rates between 57 and 69% and 52 and 68% for stage 3 and 4 patients, respectively.<sup>31</sup> In those uninterested in preserving fertility, hysterectomy with oophorectomy may be considered definitive surgical treatment.

## Rationale for Endovascular Therapy

While laparoscopy is considered the first-line option for optimizing fertility in patients with endometriosis, surgical intervention has been shown to have drawbacks as well, namely with respect to impact on functional ovarian reserve in patients with endometriomas. Anti-müllerian hormone (AMH), expressed by granulosa cells of actively growing follicles, is supported as a reliable and useful marker of ovarian reserve.<sup>32</sup> While laparoscopy has been shown as a promising treatment for managing pain and improving fertility outcomes, it comes with an appreciable risk of impacting ovarian reserve in patients with endometriomas. While the exact pathogenic mechanisms underpinning the

decline of ovarian reserve remain to be delineated, it is believed that stripping of the cyst wall may result in collateral damage to functional ovarian tissue, with potential loss of follicles.<sup>32</sup> In addition to impacting ovarian reserve, laparoscopy may lead to additional morbidity in patients. Endovascular interventions offer several benefits, leading to decrease in the following parameters: surgical complications (i.e., adhesions), postoperative pain, blood loss, infection risk, postoperative admission length, and hospital costs.<sup>33</sup> In higher surgical risk candidates, sclerotherapy may offer further benefits. As endometriosis is typically a recurrent condition, endovascular treatments are not limited by adhesions from prior surgical intervention, as long as there is sufficient visualization of a given lesion.<sup>34</sup>

### Brief Description of Technique

Interventional radiology (IR) offers promising treatments for patients with endometriosis. While there is a paucity of literature investigating the use of IR techniques in the treatment of deep or diffuse superficial endometriosis, there has been considerable examination of the use of needle-directed (NDS) and catheter-directed sclerotherapy (CDS) in the treatment of endometriomas. Prior to CDS treatment, MRI is typically performed for patients using axial and sagittal fast spin echo T2-weighted images and contrast-enhanced T1-weighted images.<sup>34</sup> During the procedure, a transabdominal ultrasonographic approach is used in patients who can be successfully accessed with no interfering structures between the abdominal wall and the lesion. In most cases, procedures are performed with transvaginal access. Ultrasound probes with in-plane needle guidance adaptors are placed following sterilization of the surgical site. Typically, 16- or 18-gauge needles with length of ~20 cm are directed transabdominally or transvaginally toward lesions. Following lesion puncture, a guidewire is typically inserted under fluoroscopic guidance through the needle, with exchange for a pigtail catheter. Endometrial contents are aspirated vigorously following catheter placement. To avoid sclerosant leakage into the peritoneum, cyst rupture is excluded through contrast injection into the lesion and subsequent visualization. Following exclusion of rupture, the pigtail catheter is clamped and varying concentrations of sclerosant (ethanol, methotrexate, tetracycline) are injected into the cyst and are either retained there (in situ method) or washed out following a time interval (typically 5–20 minutes).<sup>35</sup> Of note, prior studies have shown an appreciable decrease in rate of recurrence with longer rates of incubation of sclerosant prior to wash out.<sup>35–37</sup> NDS is similar to CDS apart from the use of a needle, as compared with a pigtail drainage catheter, for the aspiration and drainage of endometrioma content.

### Outcomes of Puncture Sclerotherapy for Endometriomas

As mentioned earlier, despite the limited availability of evidence for the use of sclerotherapy in deep endometriosis,

there is a stronger base of literature for its use in endometriomas. To accurately characterize benefit, a look at ovarian reserve, recurrence rate, pregnancy rate, and pain management can be used as a way to quantify interventional benefit.

With respect to ovarian reserve, studies have typically examined AMH decrement postoperatively after sclerotherapy. In one prospective study of 56 patients, investigators found similar levels of AMH between sclerotherapy ( $n = 31$ ) and prior cystectomy ( $n = 26$ ; 2.20 vs. 1.09) in patients undergoing in vitro fertilization (IVF).<sup>38,39</sup> The second study retrospectively analyzed 71 patients, showing that patients with AMH had no appreciable decrease in AMH levels (2.3–2.6 ng/mL) when compared 6 months postprocedure, while patients in the cystectomy group did (3.0–1.6 ng/mL,  $p < 0.05$ ). When compared against no intervention, sclerotherapy offers the potential for improved pregnancy outcomes with minimal risk toward the depletion of functional ovarian tissue.

Among three studies examining recurrence rate between sclerotherapy and cystectomy, the two aforementioned studies examining ovarian reserve found no appreciable difference in recurrence between sclerotherapy and cystectomy.<sup>34,38,39</sup> In the remaining study, a prospective cross-sectional study ( $n = 101$ ), patients in the sclerotherapy group ( $n = 44$ ) were noted to have a higher recurrence rate than the cystectomy group ( $n = 57$ ; 34.1 vs. 14.0%).<sup>40</sup> Of note, this study had a follow-up time of 7 years, which investigators attributed as a likely cause of their discrepant findings.<sup>40</sup>

With respect to spontaneous pregnancy rate, a prior mentioned prospective study in 56 patients undergoing IVF found a cumulative pregnancy rate of 55.2 versus 26.9% ( $p = 0.03$ ) when compared with patients undergoing IVF with prior cystectomy. While there remains a lack of additional comparative studies, studies have shown a benefit to sclerotherapy versus no intervention in the improvement of fertility outcomes in patients with endometriomas.<sup>41,42</sup>

Pain management is important to consider in patients with endometriosis, as palliation may be the key priority in individuals not actively trying to conceive. A Cochrane analysis examining randomized controlled studies, cohort studies, and case-control studies of endometrial cyst sclerotherapy noted a range of improvement between 68 and 96% in pain symptoms in ethanol sclerotherapy, and 80% after methotrexate sclerotherapy.<sup>35</sup> Furthermore, when comparing in situ versus washing techniques for treating endometriomas, there existed no differences in pain reduction.<sup>35</sup>

Endometrioma sclerotherapy is a relatively safe procedure with multiple studies reporting a 0% complication rate with patients.<sup>34,40,42</sup> The most frequent complication reported in literature is abdominal pain due to ethanol leakage into the peritoneum, although symptoms typically resolve shortly thereafter. On aggregate, sclerotherapy has been reported as a safe procedure with minimal incidence of complications noted in literature.

### Conclusion

Sclerotherapy offers a promising approach for patients who wish to pursue fertility, have low ovarian reserve, and are

contraindicated from or choose not to pursue more invasive interventions. While there remains variability within studies assessing the impact of sclerotherapy on patient outcomes, there appears to be a growing body of literature validating its use in the management of patients seeking treatment. Additionally, the targeted focus on endometriomas due, in part, to the inability of sclerotherapy to treat deep endometriosis hinders the generalizability of current literature toward patients with endometriosis at large. Nonetheless, given the promising data thus far, further evaluation of sclerotherapy in additional subtypes of endometriosis is warranted.

#### Conflict of Interest

None declared.

#### Acknowledgment

None.

#### References

- Horne AW, Missmer SA. Pathophysiology, diagnosis, and management of endometriosis. *BMJ* 2022;379:e070750
- Agarwal SK, Chapron C, Giudice LC, et al. Clinical diagnosis of endometriosis: a call to action. *Am J Obstet Gynecol* 2019;220(04):354.e1–354.e12
- Bulletti C, Coccia ME, Battistoni S, Borini A. Endometriosis and infertility. *J Assist Reprod Genet* 2010;27(08):441–447
- Nisenblatt V, Bossuyt PMM, Farquhar C, Johnson N, Hull ML. Imaging modalities for the non-invasive diagnosis of endometriosis. *Cochrane Database Syst Rev* 2016;2(02):CD009591
- Jee BC. Efficacy of ablation and sclerotherapy for the management of ovarian endometrioma: a narrative review. *Clin Exp Reprod Med* 2022;49(02):76–86
- Parasar P, Ozcan P, Terry KL. Endometriosis: epidemiology, diagnosis and clinical management. *Curr Obstet Gynecol Rep* 2017;6(01):34–41
- Ghiassi M, Kulkarni MT, Missmer SA. Is endometriosis more common and more severe than it was 30 years ago? *J Minim Invasive Gynecol* 2020;27(02):452–461
- Saavalainen L, Tikka T, But A, et al. Trends in the incidence rate, type and treatment of surgically verified endometriosis - a nationwide cohort study. *Acta Obstet Gynecol Scand* 2018;97(01):59–67
- Gylfason JT, Kristjansson KA, Sverrisdottir G, Jonsdottir K, Rafnsson V, Geirsson RT. Pelvic endometriosis diagnosed in an entire nation over 20 years. *Am J Epidemiol* 2010;172(03):237–243
- Gao M, Allebeck P, Mishra GD, Koupil I. Developmental origins of endometriosis: a Swedish cohort study. *J Epidemiol Community Health* 2019;73(04):353–359
- Missmer SA, Hankinson SE, Spiegelman D, Barbieri RL, Marshall LM, Hunter DJ. Incidence of laparoscopically confirmed endometriosis by demographic, anthropometric, and lifestyle factors. *Am J Epidemiol* 2004;160(08):784–796
- Leibson CL, Good AE, Hass SL, et al. Incidence and characterization of diagnosed endometriosis in a geographically defined population. *Fertil Steril* 2004;82(02):314–321
- Eisenberg VH, Weil C, Chodick G, Shalev V. Epidemiology of endometriosis: a large population-based database study from a healthcare provider with 2 million members. *BJOG* 2018;125(01):55–62
- ACOG Committee Opinion No. 760 Summary: dysmenorrhea and endometriosis in the adolescent. *Obstet Gynecol* 2018;132(06):1517–1518
- Riazi H, Tehranian N, Ziaei S, Mohammadi E, Hajizadeh E, Montazeri A. Clinical diagnosis of pelvic endometriosis: a scoping review. *BMC Womens Health* 2015;15:39
- Testini V, Eusebi L, Grechi G, Bartelli F, Guglielmi G. Imaging of endometriosis: the role of ultrasound and magnetic resonance. *Global Radiol* 2022;10:21–39
- Exacoustos C, Zupi E, Piccione E. Ultrasound imaging for ovarian and deep infiltrating endometriosis. *Semin Reprod Med* 2017;35(01):5–24
- Collins BG, Ankola A, Gola S, McGillen KL. Transvaginal US of endometriosis: looking beyond the endometrioma with a dedicated protocol. *Radiographics* 2019;39(05):1549–1568
- Theodoridis TD, Zepiridis L, Mikos T, et al. Comparison of diagnostic accuracy of transvaginal ultrasound with laparoscopy in the management of patients with adnexal masses. *Arch Gynecol Obstet* 2009;280(05):767–773
- Lee SY, Koo YJ, Lee DH. Classification of endometriosis. *Yeungnam Univ J Med* 2021;38(01):10–18
- Schippert C, Witte Y, Bartels J, et al. Reproductive capacity and recurrence of disease after surgery for moderate and severe endometriosis - a retrospective single center analysis. *BMC Womens Health* 2020;20(01):1–11
- Practice Committee of the American Society for Reproductive Medicine. Treatment of pelvic pain associated with endometriosis: a committee opinion. *Fertil Steril* 2014;101(04):927–935
- Practice Committee of the American Society for Reproductive Medicine. Endometriosis and infertility: a committee opinion. *Fertil Steril* 2012;98(03):591–598
- Practice bulletin no. 114: management of endometriosis. *Obstet Gynecol* 2010;116(01):223–236
- Kalaitzopoulos DR, Samartzis N, Kolovos GN, et al. Treatment of endometriosis: a review with comparison of 8 guidelines. *BMC Womens Health* 2021;21(01):397
- Allaire C, Bedaiwy MA, Yong PJ. Diagnosis and management of endometriosis. *CMAJ* 2023;195(10):E363–E371
- Darai E, Lesieur B, Dubernard G, Rouzier R, Bazot M, Ballester M. Fertility after colorectal resection for endometriosis: results of a prospective study comparing laparoscopy with open surgery. *Fertil Steril* 2011;95(06):1903–1908
- Quevedo A, Pasic R, Connor A, Chamseddine P. Fertility sparing endometriosis surgery: a review. *Gynecol Obstet Clin Med* 2021;1(03):112–118
- Vercellini P, Somigliana E, Viganò P, Abbiati A, Barbara G, Crosignani PG. Surgery for endometriosis-associated infertility: a pragmatic approach. *Hum Reprod* 2009;24(02):254–269
- Mavrelou D, Saridogan E. Treatment of endometriosis in women desiring fertility. *J Obstet Gynecol India* 2015;65(01):11–16
- Dunselman GAJ, Vermeulen N, Becker C, et al; European Society of Human Reproduction and Embryology. ESHRE guideline: management of women with endometriosis. *Hum Reprod* 2014;29(03):400–412
- Somigliana E, Berlanda N, Benaglia L, Viganò P, Vercellini P, Fedele L. Surgical excision of endometriomas and ovarian reserve: a systematic review on serum antimüllerian hormone level modifications. *Fertil Steril* 2012;98(06):1531–1538
- Ghasemi Tehrani H, Tavakoli R, Hashemi M, Haghighat S. Ethanol sclerotherapy versus laparoscopic surgery in management of ovarian endometrioma: a randomized clinical trial. *Arch Acad Emerg Med* 2022;10(01):e55
- Koo JH, Lee I, Han K, et al. Comparison of the therapeutic efficacy and ovarian reserve between catheter-directed sclerotherapy and surgical excision for ovarian endometrioma. *Eur Radiol* 2021;31(01):543–548
- Cohen A, Almog B, Tulandi T. Sclerotherapy in the management of ovarian endometrioma: systematic review and meta-analysis. *Fertil Steril* 2017;108(01):117–124.e5
- Noma J, Yoshida N. Efficacy of ethanol sclerotherapy for ovarian endometriomas. *Int J Gynaecol Obstet* 2001;72(01):35–39

- 37 Wang LL, Dong XQ, Shao XH, Wang SM. Ultrasound-guided interventional therapy for recurrent ovarian chocolate cysts. *Ultrasound Med Biol* 2011;37(10):1596–1602
- 38 Jee BC. Efficacy of ablation and sclerotherapy for the management of ovarian endometrioma: a narrative review. *Clin Exp Reprod Med* 2022;49(02):76–86
- 39 Yazbeck C, Madelenat P, Ayel JP, et al. Ethanol sclerotherapy: a treatment option for ovarian endometriomas before ovarian stimulation. *Reprod Biomed Online* 2009;19(01):121–125
- 40 Alborzi S, Askary E, Keramati P, et al. Assisted reproductive technique outcomes in patients with endometrioma undergoing sclerotherapy vs laparoscopic cystectomy: prospective cross-sectional study. *Reprod Med Biol* 2021;20(03):313–320
- 41 Lee KH, Kim CH, Lee YJ, Kim SH, Chae HD, Kang BM. Surgical resection or aspiration with ethanol sclerotherapy of endometrioma before in vitro fertilization in infertile women with endometrioma. *Obstet Gynecol Sci* 2014;57(04):297–303
- 42 Aflatoonian A, Rahmani E, Rahsepar M. Assessing the efficacy of aspiration and ethanol injection in recurrent endometrioma before IVF cycle: a randomized clinical trial. *Iran J Reprod Med* 2013;11(03):179–184