



# Review of Air Embolism for the Interventional Radiologist

Steven M. Zangan<sup>1</sup> Qian Yu<sup>1</sup>

<sup>1</sup>Department of Radiology, University of Chicago, Chicago, Illinois, United States

Address for correspondence Steven M Zangan, MD FSIR, 5841 S. Maryland Ave, MC 2026, Chicago, IL 60637, United States (e-mail: szangan@radiology.bsd.uchicago.edu).

Arab J Intervent Radiol 2024;8:6–12.

## Abstract

Air embolism is an uncommon but well-described complication of day-to-day interventional radiology procedures. When symptoms manifest, air embolism often results in severe morbidity or even death. Thus, an understanding of how to prevent, recognize, and manage air embolism is imperative for interventional radiologists. This article reviews the pathophysiology, etiology, diagnosis and treatment, and prognosis of air embolism.

## Keywords

- ▶ air embolism
- ▶ interventional radiology
- ▶ adverse events
- ▶ complication
- ▶ review

## Introduction

Air embolism can result from a wide variety of interventions and when symptomatic, often results in severe morbidity or even death. While uncommon, air embolism is a well-described complication of day-to-day interventional radiology procedures such as percutaneous lung biopsy and central venous access.<sup>1–3</sup> Therefore, interventional radiologists must be keenly aware of the prevention, clinical presentation, and management of this serious condition.

## Definition and Pathophysiology

Intravascular introduction of air occurs in the setting of a direct communication between a source of air and the vasculature, in which a sufficient pressure gradient leads to air crossing a breached vessel wall into the vascular lumen. The consequences of intravascular air are dependent on whether the embolus is arterial or venous. When air enters the venous circulation, it typically enters the right heart and pulmonary artery. The presence of small amounts of air in end pulmonary arteries results in an inflammatory response and endothelial damage. This potentiates pulmonary edema and hypoxemia. More directly, large bubbles can obstruct the

pulmonary outflow tract causing acute cor pulmonale, akin to an air lock within any liquid filled pipe and pump system. Ultimately, these events can result in circulatory collapse. In adults, it has been postulated that as little as 50 mL of venous air can be fatal, though other reports cite higher threshold volumes of 300 mL.<sup>4</sup> In children, even smaller volumes of air can be catastrophic. Lastly, venous air can pass through the pulmonary capillaries or pre-existing right to left shunts and cause arterial emboli. Distinct from venous air embolism, adverse events from arterial air embolism mainly result from end-organ ischemia, requiring only a few milliliters of air in parenchyma sensitive to ischemia such as the brain or heart.

## Etiology

Air embolism has been reported in the surgical and nonsurgical literature (▶ **Table 1**). Interventional radiology procedures such as percutaneous lung biopsy/thermal ablation, central venous access/catheter removal, and embolization of pulmonary arteriovenous malformation may predispose to air embolism.<sup>5</sup>

Right-sided (venous) emboli are most commonly associated with complications of central venous access. The Society of Interventional Radiology Quality Improvement Guidelines

article published online  
January 31, 2024

DOI <https://doi.org/10.1055/s-0043-1777810>.  
ISSN 2542-7075.

© 2024. The Author(s).

This is an open access article published by Thieme under the terms of the Creative Commons Attribution License, permitting unrestricted use, distribution, and reproduction so long as the original work is properly cited. (<https://creativecommons.org/licenses/by/4.0/>)

Thieme Medical and Scientific Publishers Pvt. Ltd., A-12, 2nd Floor, Sector 2, Noida-201301 UP, India

**Table 1** Conditions associated with vascular air embolism

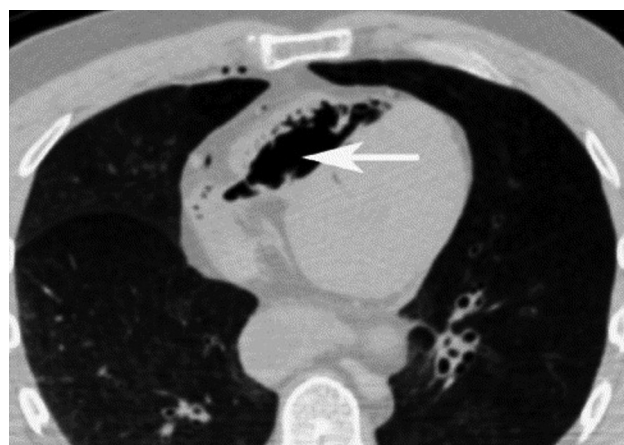Interventional radiology procedures	Percutaneous thoracic procedures (needle biopsy, thermal ablation, thoracentesis)
	Central venous catheterization (insertion, removal, hub discontinuity)
	Femoral and radial artery catheterization
	Intravenous contrast injection and venous sclerotherapy
	Arthrography
Head and neck surgeries	Neurosurgical (particularly sitting position craniotomies)
	Otolaryngological and ophthalmologic
Cardiothoracic	Bronchoscopy, lung resection, and transplantation, pacemaker insertion
Orthopaedic	Arthroscopy and arthroplasty
Obstetric and gynecologic	Hysteroscopy, cesarian section, Rubin test, abortion
Gastrointestinal	Endoscopy, cholecystectomy, liver transplantation
Trauma	Blast injury
	Penetrating chest trauma
Positive pressure ventilation	
Hemoperfusion and circulatory Support	Hemodialysis
	Cardiopulmonary bypass/ECMO
	Intra-aortic balloon rupture
Nonmedical etiologies	Decompression sickness
	Compressed gas diving
	Pulmonary barotrauma during ascent from dive
	Pulmonary bulla rupture during altitude exposure
	Hydrogen peroxide ingestion
	Sexual intercourse

Abbreviation: ECMO, extracorporeal membrane oxygenation.

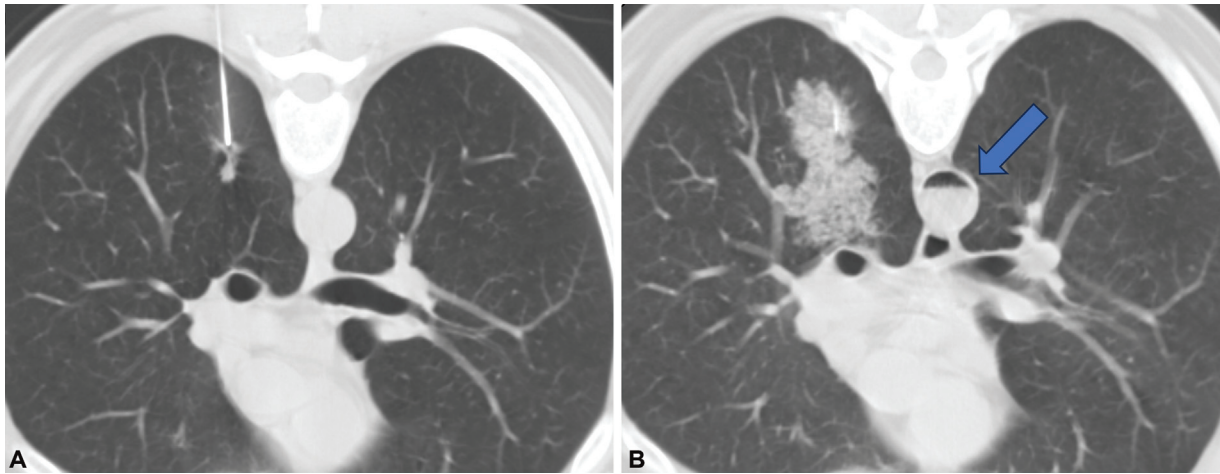
for central venous access report the air embolism complication rate at 1%.<sup>6</sup> Vesely reported a group of 15 patients who experienced air emboli, while a central venous catheter was advanced through the introducer sheath.<sup>2</sup> Alternatively, detachment of tubing from the hub, failure to close the hub, catheter fracture, and air entering a persistent subcutaneous tunnel after removal have all been described as culprits for air entry (→**Fig. 1**).<sup>7-11</sup> Reduction in central venous pressure during inspiration, hypovolemic states, and upright positioning of the patient may increase the risk of venous air embolism in these circumstances. As a result, central venous catheters are removed with patients lying supine, exhaling or performing Valsalva to increase pressures in the central vein and therefore decrease the risk for air embolus.

Left-sided (arterial) air emboli are commonly associated with thoracic interventions. Specific to percutaneous lung biopsy, when the tip of the needle resides in a pulmonary vein, air can enter the vein when the stylet is removed and the atmospheric pressure exceeds the pulmonary vein pressure. Inspiration further decreases the intravascular pressure. Ahn et al reported computed tomography (CT) evidence of pulmonary vein injury in 89% of air embolism cases following lung biopsy.<sup>12</sup> When the biopsy needle tip extends beyond the margin of the nodule, the risk may also in-

crease.<sup>13</sup> Alternatively, air may enter the vein when alveolar rupture creates a communication between the alveolus and pulmonary vein. In this case, if the patient coughs or suffers from chronic obstructive pulmonary disease, increased



**Fig. 1** A 14.5F tunneled central venous catheter was removed at the bedside with the patient semirecumbent, who developed chest pain immediately. Chest computed tomography demonstrated a large volume of air in the right ventricle (arrow) extending across the tricuspid valve. Note the punctate foci of air within the right internal mammary vein and coronary veins.

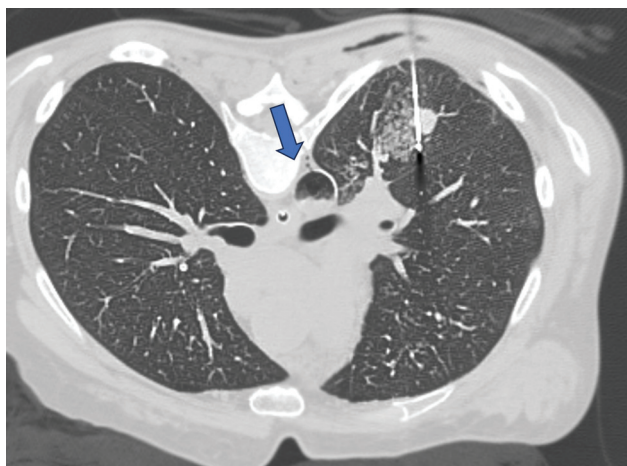

**Fig. 2** Patient developed air embolism in the aorta after percutaneous lung biopsy. (A) A small right lower lobe nodule is targeted. (B) After biopsy, perilesional hemorrhage obscures the nodule, and an air-blood level is seen in the aorta (arrow). This patient suffered from cardiac arrest while still prone in the computed tomography scanner, despite attempted resuscitation.

pressure in the lung then forces air across the communication into the vein (►Figs. 2 and 3). The Society of Interventional Radiology Quality Improvement Standards report the air embolism complication rate at 0.06 to 0.07%.<sup>14</sup> However, other studies report higher incidence at 3.8 to 4.8% with a clinically significant incidence of 0.17 to 0.49%.<sup>15,16</sup> In Pietersen's literature review, air was mostly found in the aorta or left heart (>50% of cases) with the coronary arteries (34%) and cerebral arteries (30%) less commonly affected.<sup>17</sup> Performing the biopsy with suspended respiration and occluding the hub with a finger or a few drops of saline to create a water seal are unverified techniques which may minimize the likelihood of air embolus.

### Presentation and Treatment

Though air embolism is rare, when performing percutaneous lung interventions or central venous access, operators must maintain a high index of clinical suspicion for its development



**Fig. 3** Patient undergoing radio frequency ablation of metastatic colorectal cancer in the lung developed air embolism in the aorta (arrow). The patient underwent treatment with hyperbaric oxygen therapy without significant long-term sequelae.

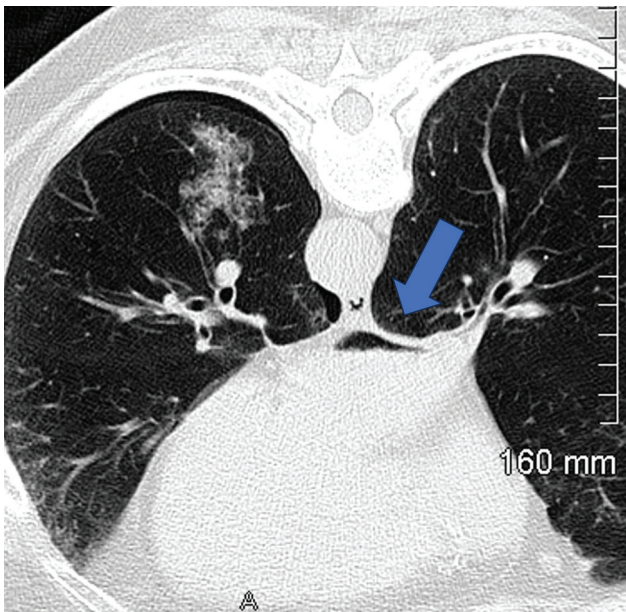
when patients experience acute onset respiratory distress or sudden cardiac or neurological events during these procedures (►Table 2). Clinical presentation varies dependent on the location of the embolus and if it is right or left sided.

Low-volume right-sided (venous) air embolism may be asymptomatic or present with cough or transient mild dyspnea that resolves spontaneously. Major air embolism may manifest as substernal chest pain or neurologic signs and symptoms such as a change in mental status or dizziness/lightheadedness. Catastrophic cases can progress to acute right-sided heart failure, hemodynamic collapse, and/or cardiac arrest. Patients may gasp or cough when air enters to pulmonary vasculature and a "sucking noise" occurs as air is pulled through the catheter or needle into the vessel.

**Table 2** Clinical and laboratory findings in air embolus

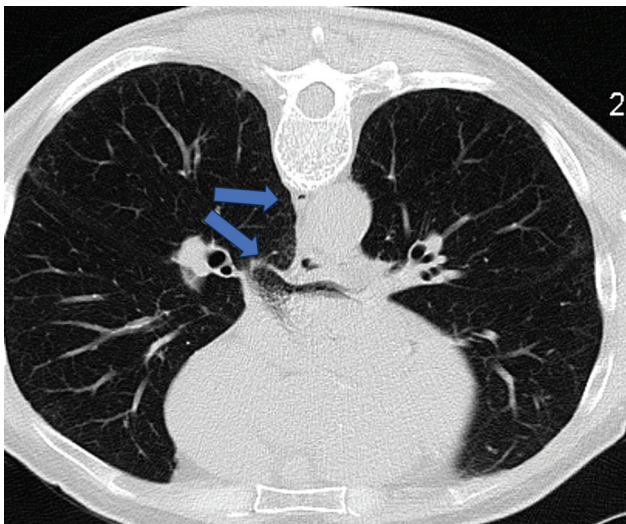
Pulmonary	Dyspnea, wheezing, and tachypnea
	Gasp reflex
	Rales
	Hypoxemia or hypercarbia
Cardiac	Chest pain, hypotension and tachycardia
	Mill wheel murmur
	Jugular venous distention, right heart strain, pulmonary hypertension
Neurologic (hypoperfusion and/or direct cerebral embolus)	Impending sense of doom
	Dizziness
	Altered mental status
	Focal neurologic deficit
Other	Superficial crepitus
	Livedo reticularis



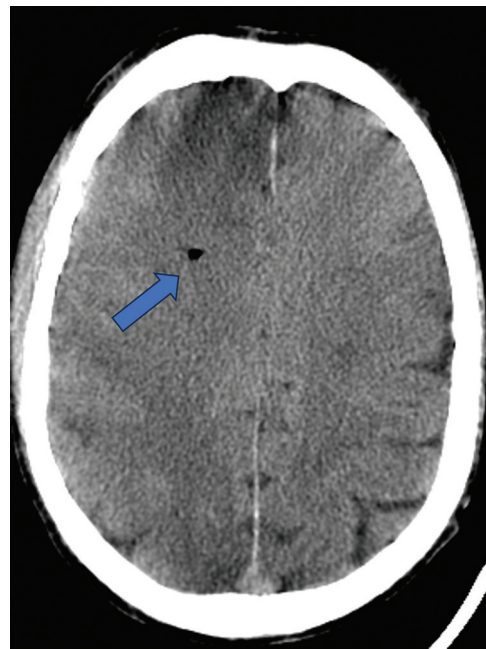


**Fig. 4** Patient underwent transthoracic needle biopsy of a left lower lobe ground glass nodule. Perilesional hemorrhage, a small pneumothorax, and air (arrow) within the nondependent portion of the left atrium are visible. This patient was rolled from prone on the computed tomography table to right side up to supine on the cart as necessitated by the scanner arrangement. Patient developed a stroke but recovered following hyperbaric oxygen therapy with only a minor residual deficit.

Left-sided (arterial) emboli are associated with a more varied presentation, dependent on the organ affected. The systemic air embolus may first be visible in the left atrium (► **Figs. 4 and 5**). Cerebral air emboli result in altered mental status or neurological defects such as stroke or transient ischemic attacks, whereas coronary emboli can cause chest pain and arrhythmias. Emboli to the spinal cord and arteries were described in 3% of all air emboli occurring in lung



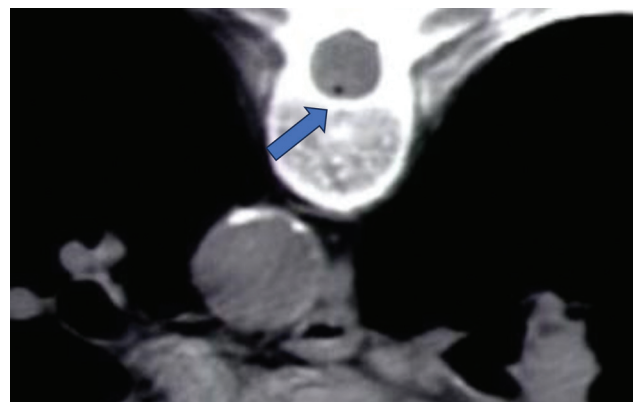
**Fig. 5** Patient developed air emboli in the left atrial appendage and azygos vein after lung biopsy (arrow). This patient was treated with hyperbaric oxygen therapy but had an irreversible motor deficit in the lower extremities, presumably from a spinal artery air embolus.



**Fig. 6** A patient undergoing a percutaneous lung biopsy developed altered mental status that could not be attributed to sedation. A head computed tomography demonstrated a punctate focus of air in a branch of the right anterior cerebral artery (arrow).

biopsy patients<sup>17</sup> (► **Figs. 6 and 7**). Unusual presentations include superficial crepitus and livedo reticularis with emboli to the skin and visual disturbances and bubbles within the retinal arteries with ocular emboli.

Though air can dissipate and rapidly absorb over the course of hours, the imaging guidance used during interventional radiology procedures allows the interventionalist to directly visualize intravascular air at an early stage. Nevertheless, imaging may be normal and the sensitivity and specific of radiologic imaging findings are poor. A study of 17 patients<sup>18</sup> with cerebral arterial air embolism reported a sensitivity of 25% in detecting cerebral air. In rare cases, fluoroscopy can reveal air in the main pulmonary artery and



**Fig. 7** Patient underwent percutaneous lung biopsy and could not move his legs following the procedure. Computed tomography revealed an air embolus (arrow) to the anterior spinal artery. The patient regained some function following hyperbaric oxygen treatment but was left with residual bladder dysfunction and leg weakness.

indirect signs of venous embolism such as pulmonary edema, focal oligemia, or pulmonary artery enlargement may be seen. The use of pulse fluoroscopy has been described as a method to improve sensitivity.<sup>19</sup> CT is particularly sensitive for the detection of emboli in the central veins, coronary arteries or brain. Interestingly, asymptomatic venous air emboli, presumably from intravenous power injection during CT, are detectable in 10 to 25% of CTs.<sup>20,21</sup>

Treatment of suspected air embolism centers on maintaining the airway, breathing, and circulation (►Fig. 8). Supplemental oxygen therapy should be administered immediately at a concentration as high as possible. Not only does this treat hypoxia and hypoxemia, but the supplemental oxygen increases the rate of diffusion of nitrogen out of the air bubble, reducing its size and increasing resorption.

Optimal positioning of a patient with suspected air embolism is controversial and varies on the nature and position of the air bubbles.<sup>22-24</sup> Classically, with venous air embolism, positioning the patient left lateral decubitus ("Durant's position") traps air in the right ventricle, as it will reside superior to the right ventricular outflow tract and pulmonary artery. However, if air has already passed into the pulmonary arteries, this maneuver would not have this theoretical benefit. Alvaran et al suggested left lateral decubitus position based on an animal experiment in which 40% survived a lethal air injection in this position.<sup>24</sup> However, based on an animal study showing left lateral decubitus positioning resulting in no difference in hemodynamic response, air persisting longer in the right atrium and right ventricular dilation, Geissler et al recommend leaving the patient in supine position.<sup>22</sup> In contrast to venous air embolism, flat supine positioning is advocated for arterial air embolism.<sup>25</sup> Rapid antegrade flow in the systemic arteries overcomes the buoyancy of air bubbles and the embolus can be propelled anywhere in the body, regardless of positioning. Head down positioning may even worsen the cerebral edema that can develop with emboli to the brain. A review of 97 patients suffering air embolism during percutaneous lung biopsy highlights variability in management.<sup>17</sup> Only the minority of patients had their position changed, mostly to Trendelenburg position. One patient was placed in right lateral decubitus with head down after CT showed air in the left ventricle and one was placed left lateral decubitus with head down after air was seen in the left ventricle.

While successful aspiration of air emboli using central venous catheters has been reported, it is unlikely that this would remove a significant quantity of air to be of definitive benefit.<sup>26,27</sup> Certainly, if a central venous catheter is present, an attempt at aspiration is of low risk, but insertion of a new venous or pulmonary arterial catheter is not recommended.

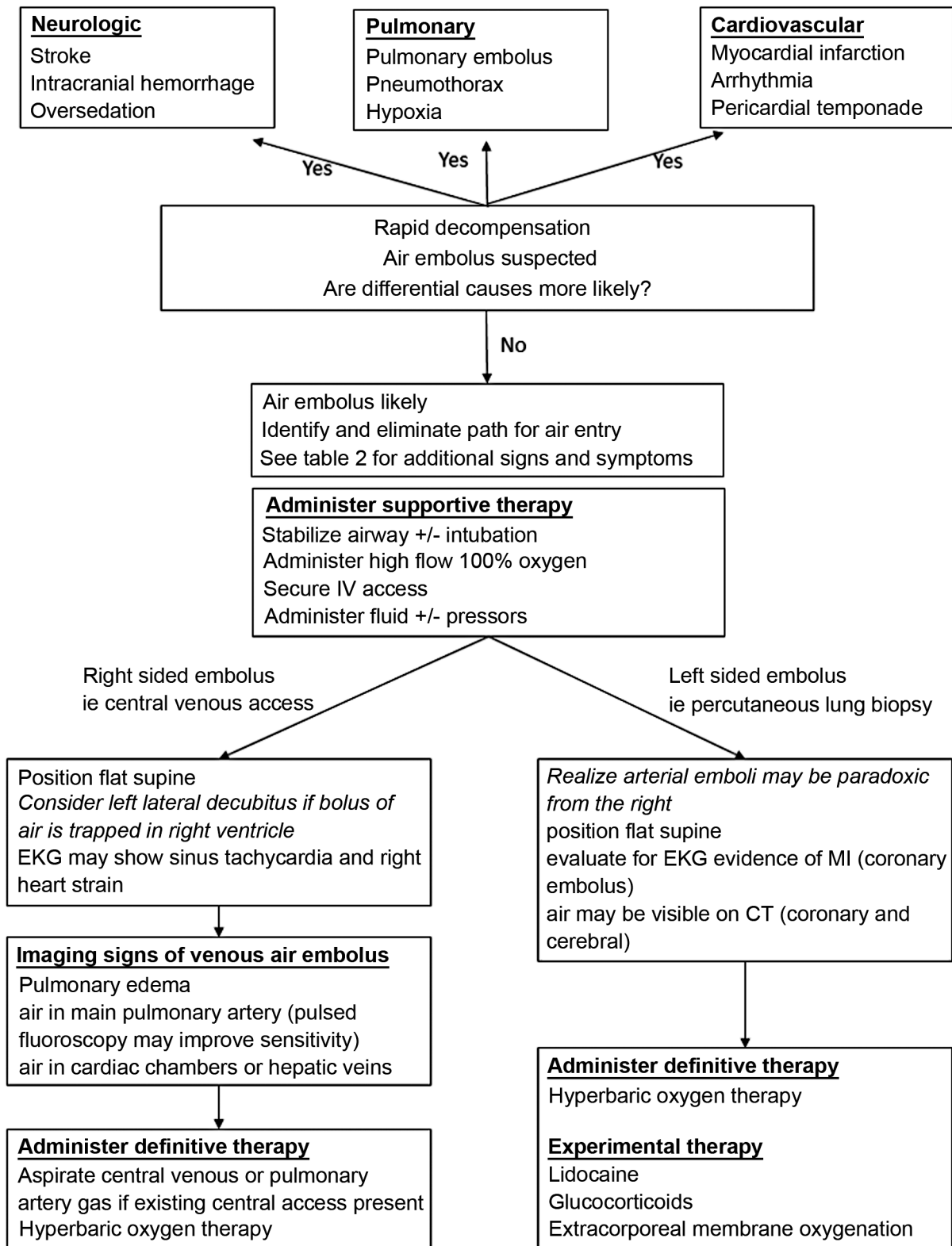
Hyperbaric oxygen therapy (HBO) can increase partial pressure of oxygen more than 2,000 mm Hg and has the potential to rapidly displace nitrogen from air bubbles and improve tissue ischemia. The utility of HBO is explained by Henry's Law (the amount of gas dissolved in solution is directly proportional to its partial pressure) and Boyle's Law (a gas's pressure and volume are inversely proportional). HBO is delivered at 3 atm, greatly increasing dissolved plasma oxygen

concentration. Additionally, at 3 atm bubble volume decreases by approximately two-thirds. Displacement of nitrogen with oxygen, which is subsequently metabolized, further aids in dissolution. HBO can be administered in an individual, or monoplace, unit consisting of a long plastic tube or in a multiperson room in which patient breath through masks or hoods. Most sessions last between 45 and 300 minutes and a variety of treatment tables are available, with the US Navy Diving Manual providing highly detailed protocols.<sup>28</sup> HBO is the mainstay of treatment for decompression sickness occurring in SCUBA divers,<sup>29</sup> but case series are small in iatrogenic air embolism. HBO has shown clinical benefit when administered within the first 4 to 6 hours after symptom onset. Blanc et al showed air embolism patients treated within 6 hours were more likely to recover, with the best outcomes in those who received treatment within 3 hours.<sup>30</sup> HBO has the potential to prevent cerebral edema and diminish the adherence of leukocytes to damaged endothelium.<sup>31-33</sup> Despite the potential benefits of HBO for treatment of air embolism, its limited availability among most healthcare facilities and the risk of transferring potentially unstable patients may hinder its wide application currently. Additionally, in patients with coexistent pneumothorax, chamber decompression could cause development of a tension pneumothorax. In these cases, placement of a chest tube prior to HBO is recommended.<sup>34</sup>

Intravenous lidocaine has shown to be neuroprotective in animal models due to sodium channel blockade and its anti-inflammatory effect but is not routinely used in humans. Similarly, methylprednisolone or dexamethasone has neuroprotective properties as they reduce intracranial hypotension, lower neuronal metabolism, and are potent anti-inflammatory drugs. Their use is also considered experimental.<sup>35</sup> Extracorporeal membrane oxygenation has been described as a rescue therapy in catastrophic cases of air embolus, but its role is unknown given limited evidence.<sup>36,37</sup>

### Prognosis

Available literature is largely limited to case reports and series with a high variability in the etiology, location, and treatment of the air embolus with a wide range of reported mortality from 5 to 23%.<sup>38</sup> Pietersen et al's review of air embolism complicating lung biopsy had 15.5% mortality, the majority of which were due to cardiac arrest.<sup>17</sup> However, 63% had no sequela and 9% had only minor sequela. Besseraeu et al reported outcomes in 119 patients with air embolism treated with HBO.<sup>38</sup> Short-term mortality was 12% and 1-year mortality was 21%. At 6 months, 75% of the survivors had mild or no disability. In Vesely's series of 15 air emboli complicating central venous catheter insertion, 10 patients had no or minimal symptoms, 4 patients had moderate or severe symptoms but completely recovered, and 1 patient died.<sup>2</sup> Similarly, in Blanc's cohort of 17 patients with venous or arterial air embolism, 8 patients completely recovered but 6 remained unconscious at discharge and three died.<sup>30</sup> Accidental injection of 100 mL air can be fatal.<sup>39,40</sup> Cardiac arrest at time of gas embolism and worse Simplified Acute Physiology Score were independent predictors of mortality.<sup>38</sup>



**Fig. 8** Diagnosis and algorithm of air embolism.

### Conclusion

In conclusion, air embolism is a rare but potentially catastrophic complication of common interventional radiology procedures. While data regarding the incidence, diagnosis,

and management of this grave condition is relatively limited and sometimes inconsistent, it is imperative that interventional radiologists understand the principles guiding its prevention and treatment.



**Conflict of Interest**

None declared.

**Acknowledgment**

We would like to thank Thomas Burdick, MD, Santa Fe Radiology for contributing cases and Brian Funaki MD FSIR, University of Chicago, for assisting with manuscript preparation and contributing cases.

**References**

- Bhatia S. Systemic air embolism following CT-guided lung biopsy. *J Vasc Interv Radiol* 2009;20(06):709–711
- Vesely TM. Air embolism during insertion of central venous catheters. *J Vasc Interv Radiol* 2001;12(11):1291–1295
- Lattin G Jr, O'Brien W Sr, McCrary B, Kearney P, Gover D. Massive systemic air embolism treated with hyperbaric oxygen therapy following CT-guided transthoracic needle biopsy of a pulmonary nodule. *J Vasc Interv Radiol* 2006;17(08):1355–1358
- Orebaugh SL. Venous air embolism: clinical and experimental considerations. *Crit Care Med* 1992;20(08):1169–1177
- Regan JD, Gibson KD, Rush JE, Shortell CK, Hirsch SA, Wright DD. Clinical significance of cerebrovascular gas emboli during polidocanol endovenous ultra-low nitrogen microfoam ablation and correlation with magnetic resonance imaging in patients with right-to-left shunt. *J Vasc Surg* 2011;53(01):131–137
- Dariusshnia SR, Wallace MJ, Siddiqi NH, et al; Society of Interventional Radiology Standards of Practice Committee. Quality improvement guidelines for central venous access. *J Vasc Interv Radiol* 2010;21(07):976–981
- Lambert MJ III. Air embolism in central venous catheterization: diagnosis, treatment, and prevention. *South Med J* 1982;75(10):1189–1191
- Thielen JB, Nyquist J. Subclavian catheter removal. Nursing implications to prevent air emboli. *J Intraven Nurs* 1991;14(02):114–118
- Lee JD, Roy TM. Venous air embolism and the central venous catheter. *J Tenn Med Assoc* 1995;88(02):51–53
- Tien IY, Drescher MJ. Pulmonary venous air embolism following accidental patient laceration of a hemodialysis catheter. *J Emerg Med* 1999;17(05):847–850
- Boer WH, Hené RJ. Lethal air embolism following removal of a double lumen jugular vein catheter. *Nephrol Dial Transplant* 1999;14(08):1850–1852
- Ahn Y, Lee SM, Kim HJ, et al. Air embolism in CT-guided transthoracic needle biopsy: emphasis on pulmonary vein injury. *Eur Radiol* 2022;32(10):6800–6811
- Jang H, Rho JY, Suh YJ, Jeong YJ. Asymptomatic systemic air embolism after CT-guided percutaneous transthoracic needle biopsy. *Clin Imaging* 2019;53:49–57
- Sheth RA, Baerlocher MO, Connolly BL, et al. Society of interventional radiology quality improvement standards on percutaneous needle biopsy in adult and pediatric patients. *J Vasc Interv Radiol* 2020;31(11):1840–1848
- Freund MC, Petersen J, Goder KC, Bunse T, Wiedermann F, Glodny B. Systemic air embolism during percutaneous core needle biopsy of the lung: frequency and risk factors. *BMC Pulm Med* 2012;12(01):2
- Monnin-Bares V, Chassagnon G, Vernhet-Kovacsik H, et al. Systemic air embolism depicted on systematic whole thoracic CT acquisition after percutaneous lung biopsy: incidence and risk factors. *Eur J Radiol* 2019;117:26–32
- Pietersen PI, Kristjansdottir B, Laursen C, M Jørgensen G, Graumann O. Systemic air embolism following computed-tomography-guided transthoracic needle biopsy of lung lesion - a systematic search of case reports and case series. *Acta Radiol Open* 2022;11(06):20584601221096680
- Benson J, Adkinson C, Collier R. Hyperbaric oxygen therapy of iatrogenic cerebral arterial gas embolism. *Undersea Hyperb Med* 2003;30(02):117–126
- Shah M, Pantin EJ. The utility of pulse fluoroscopy during Mediport insertion to diagnose air embolism. *Turk J Anaesthesiol Reanim* 2022;50(03):232–234
- Woodring JH, Fried AM. Nonfatal venous air embolism after contrast-enhanced CT. *Radiology* 1988;167(02):405–407
- Groell R, Schaffler GJ, Rienmueller R, Kern R. Vascular air embolism: location, frequency, and cause on electron-beam CT studies of the chest. *Radiology* 1997;202(02):459–462
- Geissler HJ, Allen SJ, Mehlhorn U, Davis KL, Morris WP, Butler BD. Effect of body repositioning after venous air embolism. An echocardiographic study. *Anesthesiology* 1997;86(03):710–717
- Oppenheimer MJ, Durant TM, Lynch P. Body position in relation to venous air embolism and the associated cardiovascular-respiratory changes. *Am J Med Sci* 1953;225(04):362–373
- Alvaran SB, Toung JK, Graff TE, Benson DW. Venous air embolism: comparative merits of external cardiac massage, intracardiac aspiration, and left lateral decubitus position. *Anesth Analg* 1978;57(02):166–170
- Muth CM, Shank ES. Gas embolism. *N Engl J Med* 2000;342(07):476–482
- Gould DS, Gould DB. Venous air embolism retrieval catheters cannot capture bubbles; an air lock is required. *Acta Anaesthesiol Scand* 1996;40(02):272–274
- Bedford RF, Marshall WK, Butler A, Welsh JE. Cardiac catheters for diagnosis and treatment of venous air embolism: a prospective study in man. *J Neurosurg* 1981;55(04):610–614
- Navy Dot. Volume 5: Diving medicine and recompression chamber operations. In: U.S. Navy Diving Manual, revision 7. Washington, D.C.: Naval Sea Systems Command; 2016:17–44
- Moon RE, Mitchell S. Hyperbaric treatment for decompression sickness: current recommendations. *Undersea Hyperbaric Medicine* 2019;46(05):685–693
- Blanc P, Boussuges A, Henriette K, Sainty JM, Deflelie M. Iatrogenic cerebral air embolism: importance of an early hyperbaric oxygenation. *Intensive Care Med* 2002;28(05):559–563
- Miller JD, Ledingham IM, Jennett WB. Effects of hyperbaric oxygen on intracranial pressure and cerebral blood flow in experimental cerebral oedema. *J Neurol Neurosurg Psychiatry* 1970;33(06):745–755
- Mink RB, Dutka AJ. Hyperbaric oxygen after global cerebral ischemia in rabbits reduces brain vascular permeability and blood flow. *Stroke* 1995;26(12):2307–2312
- Thom SR, Mendiguren I, Hardy K, et al. Inhibition of human neutrophil beta2-integrin-dependent adherence by hyperbaric O<sub>2</sub>. *Am J Physiol* 1997;272(3 Pt 1):C770–C777
- Freiberger JJ, Feldmeier JJ. Evidence supporting the use of hyperbaric oxygen in the treatment of osteoradionecrosis of the jaw. *J Oral Maxillofac Surg* 2010;68(08):1903–1906
- Mitchell SJ, Bennett MH, Moon RE. Decompression sickness and arterial gas embolism. *N Engl J Med* 2022;386(13):1254–1264
- Seong GM, Lee J, Kim M, Choi JC, Kim SW. Massive air embolism while removing a central venous catheter. *Int J Crit Illn Inj Sci* 2018;8(03):176–178
- Kuo C-T, Yang Y, Tseng S-H, et al. Treat venous air embolism induced acute hypoxemic respiratory failure during retinal surgery by ECMO (VV mode). *Zhonghua Minguo Xinzangxue Hui Zazhi* 2021;37(02):208–210
- Bessereau J, Genotelle N, Chabbaut C, et al. Long-term outcome of iatrogenic gas embolism. *Intensive Care Med* 2010;36(07):1180–1187
- Yeakel AE. Lethal air embolism from plastic blood-storage container. *JAMA* 1968;204(03):267–269
- O'Quin RJ, Lakshminarayan S. Venous air embolism. *Arch Intern Med* 1982;142(12):2173–2176