Article published online: 2024-01-05

An Outcome Analysis of Fibrin Sealant versus Staples for Fixation of Split-Thickness Skin Grafts

Akshara Shuchi[1] Deepti Gupta[1] Sujata Sarabahi[1]

[1] Department of Burns, Plastic and Maxillofacial Surgery, VMMC and Safdarjung Hospital, New Delhi, India

Indian J Plast Surg 2024;57:60–66.

Address for correspondence Akshara Shuchi, MBBS, DNB, Department of Burns, Plastic and Maxillofacial Surgery, VMMC and Safdarjung Hospital, New Delhi, 110029, India (e-mail: aks.tamanna@gmail.com).

Abstract

Background Skin grafting plays a vital role in post-burn and post-traumatic wound management. Split-thickness skin grafts (STSG) are traditionally fixed using staples or sutures, which have tedious application and their removal necessitates painkillers, medical equipment, and human intervention. As an alternative, fibrin sealant is a biological tissue adhesive, composed of thrombin, calcium, and fibrinogen. Fibrin sealant promotes hemostasis and acts as a biological adherent.

Objective The aim of this study was to evaluate the outcomes (graft take, wound healing and complications) of fibrin sealant and staples for STSG fixation.

Methods It is a randomized controlled trial on 40 patients with wounds of minimum 400 cm^2. Wound area was divided into equal halves and randomly allocated to the study group or control group. In the study group, 4 mL per 200 cm^2 of fibrin sealant was sprayed followed by STSG application. In the control group, STSG was fixed with only skin staples. Evaluation was done on postoperative days 3, 5, 15, and 30 for graft take, hematoma/seroma, infection, and complete wound healing.

Results The mean graft take was significantly higher (p-value < 0.05) in the study group than in the control group (91 vs. 89%). No seroma or hematoma formation was seen in either group. Complete wound healing was seen in more patients in the study group, but the difference was statistically insignificant.

Conclusion Fibrin sealant is an excellent alternative to staples for skin grafting, with the advantage of better graft take and being free of pain that is incurred during staple removal.

Keywords
- fibrin sealant
- split-thickness skin grafting
- granulating raw area
- staples

Introduction

Autologous skin grafting plays a vital role in post-burn and post-traumatic wound management. Clinical obstacles such as repeated graft failure, microbial wound colonization, and a scarcity of donor sites have driven the development of biologic and synthetic skin substitutes and newer graft fixation techniques.

Achieving a complete contact of the skin graft with wound surface is essential for graft take. The traditional graft fixation techniques include staples and sutures that require removal that necessitates painkillers, medical equipment, and human intervention.[1,2] And also it is time consuming to fix grafts with sutures. Due to these concerns, an alternative way for graft fixation has been an active research area.

article published online
January 5, 2024

DOI https://doi.org/10.1055/s-0043-1777867.
ISSN 0970-0358.

Thieme Medical and Scientific Publishers Pvt. Ltd., A-12, 2nd Floor, Sector 2, Noida-201301 UP, India

Absorbable staples were tried, but the venture proved to be a futile exercise.[3–5]

Preventing fibrin formation through systemic or local heparinization and application of fibrinolysin to wound bed have been shown to reduce skin graft adherence.[6–9] These findings support the role of fibrin for graft take and therefore, fibrin sealant was tried to affix grafts to the wound bed.

Fibrin sealants have been used for fixation of skin grafts but the results have been inconclusive so far. We conducted this study to objectively evaluate the use of fibrin sealant for fixation of skin graft and compare it with the conventional technique of staple fixation.

Materials and Methods

An interventional randomized controlled trial was conducted for a period of 18 months at our center. The study was both patient blinded and outcome assessor blinded. The approval for the study was taken from the institutional review board. The study was registered with Clinical Trials Registry India (Registration No CTRI/2022/08/044992).

Patients within the age of 1 year and 80 years, with a minimum of 400 cm^2 granulating raw area following burns or trauma, were included in the study after taking written informed consent. Patients with coagulation disorders and any other comorbidity that precluded skin grafting were excluded from the study. All cases were operated when the preoperative swab report showed no growth. Demographic details of all the patients were recorded and a detailed history and clinical examination was performed (►**Fig. 1**).

The sample size was calculated using the data from a previous study of Muthukumar et al[10] who observed a 95% graft take with fibrin sealant. Taking these values as reference and assuming a difference of 25% in graft take between fibrin sealant and the conventional method, the minimum required sample size with 80% power of study and 5% level of significance was 33 patients in each study group. To reduce the margin of error, the total sample size taken was 40.

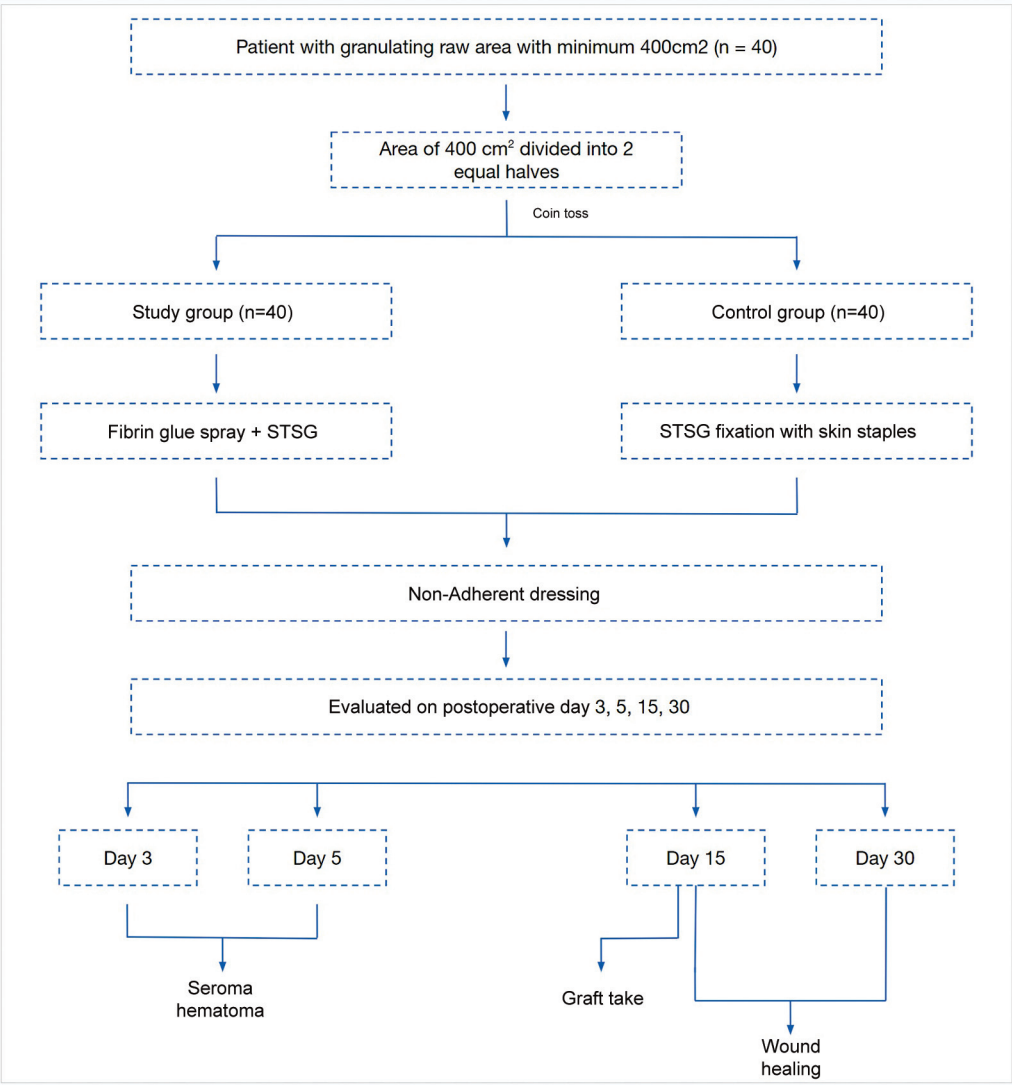

Fig. 1 Flowchart summarizing the study methodology. STSG, split-thickness skin grafts.

Formula used was as follows:

$$N = ((pf \times (1\text{-}pf) + pc \times (1\text{-}pc)) \times \text{pow}\ (Z\alpha + Z\beta, 2) \\ / \text{pow}\ (pc\text{-}pe, 2)$$

where,
pf = percentage of graft take in fibrin sealant
pc = percentage of graft take in the conventional method
where Zα is the value of Z at two-sided α error of 5% and Zβ is the value of Z at power of 80%.

Surgery was performed under general anesthesia. After cleaning and draping, the area of the wound to be grafted was measured by taking an impression of the wound on a graph sheet and counting the number of boxes within the impression. Wound bed was prepared for grafting by excising a thin layer of granulation tissue with the help of a skin grafting knife. Thorough hemostasis was achieved with adrenaline solution (1:1,00,000) soaked gauzes and bipolar electrocautery. An area of 400 cm^2 was selected and divided into a proximal and a distal half. A coin toss was done to allocate each area to either the study group (A) or the control group (B). In the study group, the graft bed was sprayed with fibrin sealant (Tisseel, Baxter Biosurgical, Vienna, Austria) with the help of the Easy Spray device and STSG was quickly applied onto it. Easy Spray is a battery-operated pressure regulator device. It spreads sealant in a spray form by using medical air at a high pressure, from a distance of 15 cm, to create a thin layer of 4 mL per 200 cm^2. In the control group, STSG was fixed with skin staples. Both the areas were dressed with Vaseline gauze followed by nonadherent dressing.

Technique for Preparation of Fibrin Sealant

Fibrin glue is composed of primarily thrombin, calcium, and fibrinogen. It comes in four components

1. Human thrombin lyophilized: Thrombin is present in human plasma and takes part in clotting cascade by converting fibrinogen to fibrin. After reconstitution, 1 mL contains 500 IU thrombin that solidifies rapidly.
2. Calcium chloride solution (40 µmol/mL): In the presence of positive calcium ions, thrombin converts fibrinogen to fibrin monomers, which then polymerizes to an insoluble fibrin clot.
3. Synthetic aprotinin solution (3000 K IU/mL): Aprotinin is a fibrinolysis inhibitor and is added to the fibrinogen component as a clot stabilizer to ensure clot longevity.
4. Sealer protein concentrate lyophilized: After reconstitution, 1 mL of the sealer protein contains clottable protein 75 to 115 mg, fibrinogen 70 to 110 mg, plasma fibronectin 2 to 9 mg, factor XIII 10 to 50 U, plasminogen 40 to 120 mg.

Preheat all vials in a Fibrinotherm heating and steering device or in a water bath at a temperature of 37°C for approximately 10 minutes. Transfer aprotinin solution to vial containing sealer protein. Gently swirl the vial to ensure that the product is completely soaked. Reconstitution is complete when no undissolved particles are visible. Transfer calcium chloride solution to the thrombin vial and repeat the same. The two solutions are loaded into the syringes and connected to the spraying system.

Study Outcomes

The first dressing was done on day 3 and the graft was evaluated by a blinded assessor on postoperative day 3, 5, 15, and 30. On day 3 and 5, the presence of complications such as hematoma or seroma formation was noted, and a swab culture was taken to assess for the presence of any infection. On day 15, any residual raw area was measured using a graft sheet as described earlier. The area of graft take was calculated by deducting the measured residual raw area from the total raw area (200 cm^2). The percentage of graft take was then calculated. To evaluate wound healing, the number of patients who had completely healed wounds at day 15 and day 30 was noted. Wound was considered as healed when the entire wound surface area was covered with a layer of epithelium.

All quantitative data were presented as the mean ± standard deviation and as median with 25 and 75 percentiles (interquartile range). The presentation of the categorical variables was done in the form of number and percentage (%). The data normality was checked by using Kolmogorov–Smirnov test. The cases in which the data was not normal, nonparametric tests were used. The following statistical tests were applied for the results:

1. The comparison of the quantitative variables and not normally distributed in nature were analyzed using Wilcoxon signed-rank test.
2. The qualitative variables were analyzed using the chi-squared test.

The data entry was done in the Microsoft Excel spreadsheet and the final analysis was done with the use of Statistical Package for Social Sciences (SPSS) software, IBM manufacturer, Chicago, USA, version 25.0.

A *p*-value of less than 0.05 was considered statistically significant.

Results

In our study, the age of the patients ranged from 15 to 54 years. The mean and median ages were 36.17 ± 11.16 and 37 years, respectively. Most of the patients were from the age group of 35 to 44 and 45 to 54 years (30% each). This patient demographic is representative of the predominant age group and gender distribution of patients that we receive at our center.

The main indication for STSG were patients with raw areas following burn injuries constituting 75%, while the rest (25%) were those with raw areas following trauma. The most common wound location was upper limb (57.5%) followed by lower limb (20%), posterior trunk (12.5%), and anterior trunk (10%). Being a dedicated tertiary level burn care unit, our center receives a high load of burn victims. Hence, the majority of our study participants had post-burn raw areas.

The mean percentage of graft take on postoperative day 15 in the fibrin group was 90.88 ± 9.86 with a range of 45 to 100,

Table 1 Comparison of graft take and wound healing between groups FG and C

	Group FG ($n = 40$)	Group C ($n = 40$)	*p*-Value
Graft take on day 15			
Mean ± SD	90.88 ± 9.86	88.88 ± 9.37	0.016
Median (25th–75th percentile)	95 (85–95)	90 (85–95)	
Range	45–100	50–100	
Wound healing			
Day 15	10 (25%)	5 (12.50%)	0.152
Day 30	32 (80%)	27 (67.50%)	0.204

Abbreviation: SD, standard deviation.

while in the conventional group, it was 88.88 ± 9.37 with a range of 50 to 100. The difference between the two groups was statistically significant with better graft take noted in the fibrin group (►**Table 1**; ►**Fig. 2A–C**).

Complete wound healing was present in 25% ($n = 10$) and 80% ($n = 32$) of the included areas in the study group on day 15 and 30, respectively. However, in the control group, the number of areas that were completely healed by day 15 and 30 were lesser ($n = 5$ on day 15 and $n = 27$ on day 30). This difference was found to be statistically insignificant (►**Table 1**).

No seroma or hematoma formation was observed in either of the groups on the postoperative day 3 and 5. Infection was noted in 22.5% of the grafts in both the groups in our study, with a positive wound culture on the postoperative day 3 and 5. The most common organism isolated was *Pseudomonas aeruginosa*.

Discussion

Wound care for post-burn and traumatic wounds has evolved progressively over the years, with various treatment options dominating the scene during different periods. But skin grafting has stood the test of time and autologous, meshed split-thickness skin grafts are the preferred treatment for extensive full-thickness wounds.[11–14] Skin grafts are usually secured to the recipient site by sutures, staples, or tie-over dressings[15] as skin graft immobility is crucial for the revascularization of the graft.[16] Despite a healthy wound bed and good postoperative care, failure of skin grafting in a significant number of cases has troubled surgeons and patients alike. Various factors like poor adherence, seroma, or hematoma formation disrupt the vascularization of the graft from its bed resulting in graft failure.[10]

Fibrin sealant has been used over the last three decades as an adhesive in various surgical domains, including plastic and reconstructive surgery. The hemostatic effect of fibrin was first demonstrated in wounds by Bergel in 1909.[17] Fibrin sealant was shown to promote hemostasis and act as a biological adherent by promoting quick, firm adhesion between the wound bed and the graft.[18,19]

In our study, the mean percentage of graft take on postoperative day 15 was higher in the study group as compared with the control group. Fibrin sealant has been

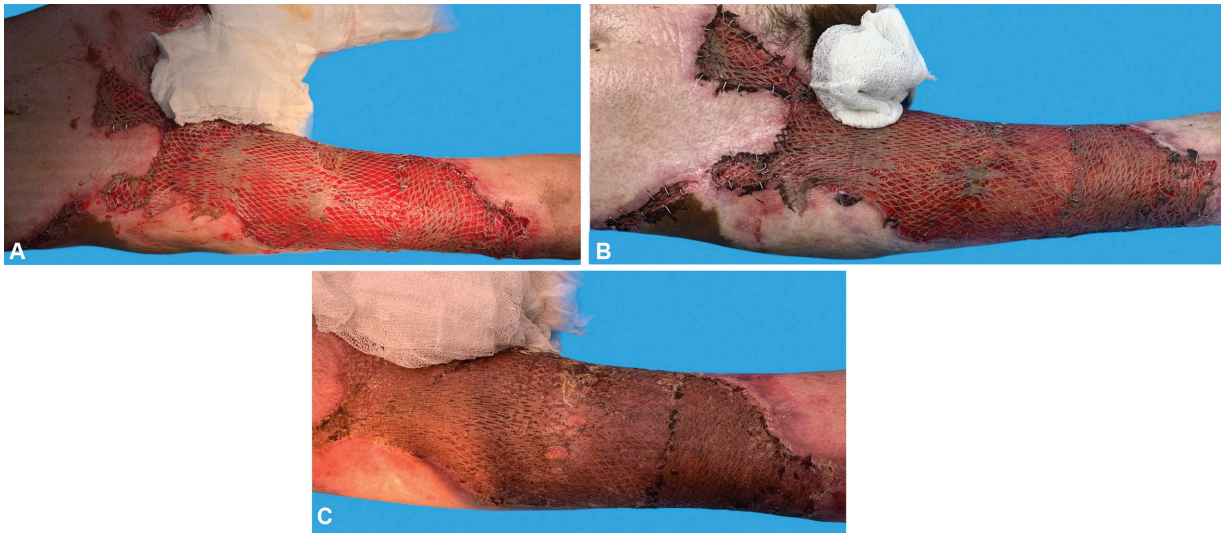

Fig. 2 (**A**) Split-thickness skin grafts affixed with fibrin sealant in the proximal 200 cm^2 and with skin staples in the distal 200cm^2. Rest of the grafted area on abdomen and groin was not included in the study. (**B**) Postoperative day 3. (**C**) Postoperative day 15. A small patch of graft loss is visible in the area allocated to the study group.

Table 2 Analysis of graft take, complete wound healing, and graft related complications in studies evaluating use of fibrin sealant in skin grafting

		Present study	Saxena et al[20]	Gibran et al[23]	Foster et al[24]	Han et al[21]	Kim et al[22]	Muthukumar et al[10]
Thrombin concentration in fibrin sealant		250 IU/mL	Not mentioned as prepared indigenously	4 IU/mL	4 IU/mL	400 IU/mL	Diluted 400 IU/mL (dilution not mentioned)	259 IU/mL
Percentage of graft take	Study	Day 15—91%	Day 14—96%	Day 5—100%	Day 5—62.3%	Day 30—98.14%	99.20%	Day 15—95%
	Control	Day 15—89%	Day 14—88%	Day 5—100%	Day 5—55%	Day 30—95.35%	98.20%	Day 15—90.2%
	p-Value	0.016	–	0.35	0.089	< 0.05	0.032	< 0.001
Wound healing	Study	25% (Day 15) 80% (Day 30)	–	79.5% (Day 28)	48% (Day14) 70.3% (Day 28)	–	–	–
	Control	12.5% (Day 15) 67.5% (Day 30)	–	59% (Day 28)	42.6% (Day 14) 65.8% (Day 28)	–	–	–
	p-Value	0.152 (Day 15) 0.204 (Day 30)	–	0.0215	0.2299	–	–	–
Seroma formation (%)	Study	Day 3—Nil Day 5—Nil	–	Day 1—Nil	Day 1—29.7%	7.84%	–	Nil
	Control	Day 3—Nil Day 5—Nil	–	Day 1—2%	Day 1—62.3%	9.55%	–	5%
Hematoma formation (%)	Study	Day 3—Nil Day 5—Nil	–	Day 1—Nil	–	–	–	Nil
	Control	Day 3—Nil Day 5—Nil	–	Day 1—2%	–	–	–	15%
Wound infection (%)	Study	Day 3—22.5 Day 5—22.5	–	–	–	–	–	10%
	Control	Day 3—22.5 Day 5—22.5	–	–	–	–	–	10%

seen to result in a higher graft take by Saxena et al,[20] Han et al,[21] Kim et al,[22] Muthukumar et al,[10] Gibran et al[23] and Foster et al[24] reported a comparable graft take between the fibrin group and conventional group (►**Table 2**).

Adherence of the graft to the raw area is crucial for graft survival. Fibrin sealant reduces graft displacement by promoting clot formation and providing adherence over the entire wound area, as compared with staples that fix the graft at only certain points. It also acts as a bonding protein between the wound bed and skin.[6–9,25–28] Fibrin and fibronectin have been shown not only to act as conduits for the movement of fibroblasts but also provide a highly cross-linked fibrin network that stabilizes the graft and enhances the nutrition of the graft by increased plasmatic circulation/serum imbibition that is followed by neovascularization by growth of vascular buds. These properties of fibrin account for better graft take as seen in ours and other previous studies.

In our study, complete wound healing was present in a higher number of cases, but this difference was statistically insignificant. Foster et al[24] found the fibrin sealant and staple fixation to be equally efficacious for complete wound closure. On the contrary, Gibran et al[23] found statistically significant difference in wound healing between the fibrin and conventional group on day 28, which they attributed to the contiguous adhesion provided by the sealant to the graft (►**Table 2**). For a wound to heal, wound fibroblasts, macrophages, or migratory keratinocytes contribute to persistent fibronectin deposition. The fibrin–fibronectin matrix facilitates the transmigration of fibroblasts that then generate type 1 collagen. This illustrates how increased cross-linking in a matrix provided by fibrin sealant may speed up the migration of fibroblasts through the matrix.

The mechanical factors (hematoma/seroma, shear forces) play an essential role in the causation of graft failure by altering the fibrin interface between the graft and wound bed, thus interfering with revascularization. In our study, no seroma or hematoma formation was observed in either of the groups on the postoperative day 3 and 5. Majority of the other studies have also reported no incidence of seromas or hematomas with the use of fibrin sealant. Fibrin sealant has been observed to aid clot formation thereby promoting hemostasis and reducing the chances of hematoma formation. However, Foster et al[24] and Han et al[21] reported 29.7 and 7.84% incidence of seroma and hematoma, respectively, in the fibrin sealant group. The sheet grafts applied to the wound bed in their study could have accounted for the formation of seroma and hematoma as drainage is limited in a sheet as compared with a meshed graft. We attribute the absence of seroma or hematoma formation in our study to the use of meshed skin grafts and our emphasis on thorough hemostasis (►**Table 2**).

In addition to the above-mentioned observations, it was also noted that application of skin staplers was slightly more time consuming and the removal was a painful experience for the patients, both of which are obviated by the use of fibrin sealant. Use of fibrin sealant has been shown to reduce postoperative pain in other studies as well.[29,30]

Limitations of the Study

Due to contiguity of the wound areas in the study and the control group, various parameters such as pain score and infection rates could not be evaluated. Removal of staples was associated with pain, but no statistical evaluation was done to compare pain at the recipient site between both the groups. The duration of surgery was not compared in our study as we grafted small areas of 200 cm^2, but further studies can evaluate this aspect.

Conclusion

Fibrin sealant is an excellent alternative to use of staples for fixation of skin grafts. Its use is associated with a significantly increased percentage of graft take and is also equally efficacious as staples in achieving complete wound closure. Further research is essential to analyze the financial feasibility of use of fibrin sealants in skin grafting procedures.

Clinical Trial Registration Information
Clinical Trials Registry - India (CTRI): www.ctri.nic.in/
Registration No CTRI/2022/08/044992

Institutional Review Board Certificate
The Institutional Review Board/Thesis Protocol Review Committee of VMMC and Safdarjung Hospital, New Delhi, has reviewed and approved the study to be conducted in the present form at VMMC and Safdarjung hospital, New Delhi.

Conflict of Interest
None declared.

Acknowledgment
The authors would like to thank the patients who participated in this study, their families, and all clinical staff at each participating study site.

References

1 Kulber DA, Bacilious N, Peters ED, Gayle LB, Hoffman L. The use of fibrin sealant in the prevention of seromas. Plast Reconstr Surg 1997;99(03):842–849, discussion 850–851[discussion 50–1]
2 Zederfeldt H. Does fibrin play an important role in wound healing? In: Schlag G, Redl H, eds. Fibrin Sealing in Surgical and Nonsurgical Fields. Berlin: Springer-Verlag; 1994:18–22
3 Mohammadi AA, Bakhshaeekia AR, Marzban S, et al. Early excision and skin grafting versus delayed skin grafting in deep hand burns (a randomised clinical controlled trial). Burns 2011; 37(01):36–41
4 Best T, Lobay G, Moysa G, Tredget E. A prospective randomized trial of absorbable staple fixation of skin grafts for burn wound coverage. J Trauma 1995;38(06):915–919
5 O'Broin ES, O'Donnell M, O'Donovan D, Tiernan E, Lawlor DL, Eadie PA. Absorbable skin graft staples: a clinical trial using Graftac-X. Br J Plast Surg 1996;49(07):485–487
6 Burleson R, Eiseman B. Nature of the bond between partial-thickness skin and wound granulations. Surgery 1972;72(02): 315–322
7 Perry AW, Krizek TJ. Topical antifibrinolytic agents and skin graft survival. Surg Forum 1981;32:565

8 Teh BT. Why do skin grafts fail? Plast Reconstr Surg 1979;63(03): 323–332
9 Thorton JW, Tavis MJ, Harney JH, Pirkle H, Bartlett RH, Woodroof EA. Graft adherence to wound surfaces: collagen fibrin interactions. Burns 1978;3:23
10 Muthukumar V, Dash S, Danish AF, Sheth S, Nanda D, Ahluwalia C. Fibrin sealant for split-thickness skin graft fixation in burn wounds - an ancillary postulated role in scar modulation. Wound Medicine. 2020;31:100197
11 Herndon DN, Parks DH. Comparison of serial debridement and autografting and early massive excision with cadaver skin overlay in the treatment of large burns in children. J Trauma 1986;26(02): 149–152
12 Janzekovic Z. A new concept in the early excision and immediate grafting of burns. J Trauma 1970;10(12):1103–1108
13 Muller MJ, Herndon DN. Operative wound management. In: Herndon DN, ed. Total Burn Care. London: W.B. Saunders; 2001:221–31
14 Thompson P, Herndon DN, Abston S, Rutan T. Effect of early excision on patients with major thermal injury. J Trauma 1987;27(02):205–207
15 Miller R, Wormald JCR, Wade RG, Collins DP. Systematic review of fibrin glue in burn wound reconstruction. Br J Surg 2019;106(03): 165–173
16 Grunzweig KA, Ascha M, Kumar AR. Fibrin tissue sealant and minor skin grafts in burn surgery: A systematic review and meta-analysis. J Plast Reconstr Aesthet Surg 2019;72(06):871–883
17 Bergel S. Uber Wirkungen des Fibrins. Dtsch Med Wochenschr 1909;35:663
18 Butts CC, Sahawneh J, Duffy A, et al. Cost-benefit analysis of outcomes from the use of fibrin sealant for fixation of skin grafts in small-size burns compared to staples as historical controls: a retrospective review. Ann Plast Surg 2015;74(02):173–175
19 Krishna D, Kumar S, Sharma U, Gupta D. Impact of nonscraping of granulation tissue on outcomes after skin grafting. Indian J Burns 2017;25(01):33–37
20 Saxena S, Jain P, Shukla J. Preparation of two-component fibrin glue and its clinical evaluation in skin grafts and flaps. Indian J Plast Surg 2003;36:14–17
21 Han HH, Jun D, Moon SH, Kang IS, Kim MC. Fixation of split-thickness skin graft using fast-clotting fibrin glue containing undiluted high-concentration thrombin or sutures: a comparison study. Springerplus 2016;5(01):1902
22 Kim Y, Kym D, Cho YS, et al. Use of fibrin sealant for split-thickness skin grafts in patients with hand burns: a prospective cohort study. Adv Skin Wound Care 2018;31(12):551–555
23 Gibran N, Luterman A, Herndon D, et al; FS 4IU Clinical Study Group. Comparison of fibrin sealant and staples for attaching split-thickness autologous sheet grafts in patients with deep partial- or full-thickness burn wounds: a phase 1/2 clinical study. J Burn Care Res 2007;28(03):401–408
24 Foster K, Greenhalgh D, Gamelli RL, et al; FS 4IU VH S/D Clinical Study Group. Efficacy and safety of a fibrin sealant for adherence of autologous skin grafts to burn wounds: results of a phase 3 clinical study. J Burn Care Res 2008;29(02):293–303
25 Foresman PA, Tedeschi KR, Rodeheaver GT. Influence of membrane dressings on wound contraction. J Burn Care Rehabil 1986;7 (05):398–403
26 Frank DH, Brahme J, Van de Berg JS. Decrease in rate of wound contraction with the temporary skin substitute Biobrane. Ann Plast Surg 1984;12(06):519–524
27 Leipziger LS, Glushko V, DiBernardo B, et al. Dermal wound repair: role of collagen matrix implants and synthetic polymer dressings. J Am Acad Dermatol 1985;12(2 Pt 2):409–419
28 Grabb WC. Basic techniques of plastic surgery. In: Grabb WC, Smith JW, eds. Plastic Surgery: A Concise Guide to Clinical Practice. 3rd ed. Boston, MA: Little, Brown, & Co;; 1979:16–35
29 Dhua S, Suhas TR, Tilak BG. The effectiveness of autologous platelet rich plasma application in the wound bed prior to resurfacing with split thickness skin graft vs. conventional mechanical fixation using sutures and staples. World J Plast Surg 2019;8(02):185–194
30 Mullens CL, Messa CA IV, Kozak GM, Rhemtulla IA, Fischer JP. To glue or not to glue? Analysis of fibrin glue for split-thickness skin graft fixation. Plast Reconstr Surg Glob Open 2019;7(05): e2187

