



# Takotsubo's Cardiomyopathy in a Young Female with Severe Traumatic Brain Injury: A Case Report

Gayatri Kumari<sup>1</sup> Anoop K. Singh<sup>2</sup> Sharma V. Jaishree<sup>3</sup> Ashutosh Tiwari<sup>4</sup>

<sup>1</sup>Neuroanesthesia and Neurocritical Care, Life Line Hospital & Research Centre Azamgarh, Uttar Pradesh, India

<sup>2</sup>Department of Neurosurgery, Life Line Hospital & Research Centre Azamgarh, Uttar Pradesh, India

<sup>3</sup>Department of Anesthesiology, Government Medical College, Azamgarh, Uttar Pradesh, India

**Address for correspondence** Gayatri Kumari, MD (Anesthesiology), FCCM, MCCM, 14/69, Raidopur Nai Basti, Azamgarh, UP 276001, India (e-mail: reply2gayatri@gmail.com).

<sup>4</sup>Department of Neuroanesthesia and Neuro Critical Care, Life Line Hospital & Research Centre Azamgarh, Uttar Pradesh, India

J Neuroanaesthesiol Crit Care

## Abstract

Takotsubo's cardiomyopathy (TC) typically presents with acute cardiac dysfunction due to regional wall motion abnormality, but unlike other cardiac pathologies, it recovers within a short period. Here, we report the case of a 23-year-old woman who presented to us following severe traumatic brain injury (TBI). Her Glasgow coma scale (GCS) deteriorated rapidly in the preoperative period and she developed TC following surgery. Despite an uneventful surgery, she needed cardiovascular support by vaso-pressors and inotropes in the postoperative period. She was diagnosed with TC on serial transthoracic echocardiography, with complete cardiac function recovery within 9 days. The diagnosis of TC was supported by electrocardiography (not correlating coronary artery disease), elevated troponin I and N-terminal prohormone of brain natriuretic peptide (NT-proBNP), and the presence of a physical sensor like TBI. As an unrecognized TC due to a low GCS score after severe TBI may negatively impact outcomes, we aim to emphasize that vigilant perioperative management may give good outcomes even in less commonly encountered serious TC.

## Keywords

- ▶ Takotsubo's cardiomyopathy
- ▶ transthoracic echocardiography
- ▶ traumatic brain injury

## Introduction

Takotsubo's cardiomyopathy (TC) is predominantly a disease of elderly women but can occur at any age or sex. It has been well studied in subarachnoid hemorrhage (SAH), but uncommonly reported in patients with ischemic stroke, intracerebral hemorrhage, and traumatic brain injury (TBI).<sup>1,2</sup> Here, we report TC in a young woman with severe TBI, which is an unusual scenario in this disease. As it remains difficult to elicit cardiomyopathy symptoms in severe TBI victims, these undiagnosed cardiomyopathy poses a significant challenge to perioperative management.

## Case Report

A 23-year-old woman with no previous comorbidities presented to the emergency room with head injury from a road

traffic accident 20 hours earlier. On arrival, her Glasgow coma scale (GCS) was E2V3M5, pupils were of bilateral normal size with normal reaction, heart rate was 100 beats/min, blood pressure was 90/60 mm Hg, respiratory rate was 16 breaths/min, and SPO<sub>2</sub> was 98%. Computed tomography of the head showed left frontoparietal acute subdural hematoma with frontotemporal contusion and mass effect (▶ **Fig. 1**). Her initial electrocardiogram (ECG), E-FAST (Extended Focused Assessment with Sonography in Trauma), and transthoracic echocardiogram (TTE) revealed no abnormal findings.

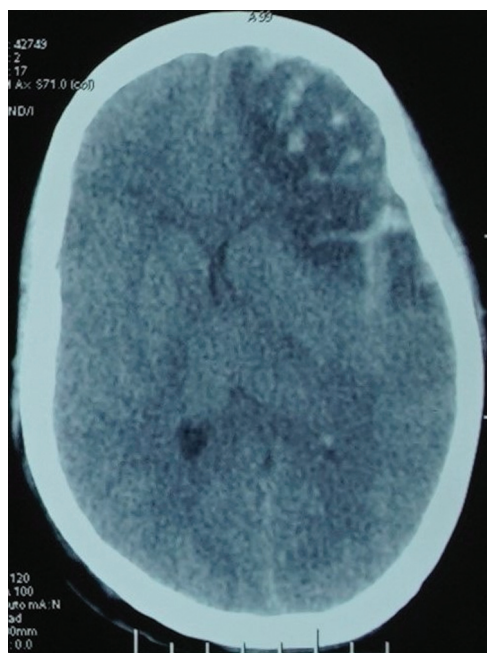
In view of rapid deterioration with GCS E1V1M5 in the next 3 hours, an emergency surgery aiming left hemispheric decompressive craniectomy and left frontotemporal contusion evacuation was commenced within 5 hours of hospitalization. After opioid-based induction and a smooth intraoperative period, the patient was electively ventilated in the postoperative period.

DOI <https://doi.org/10.1055/s-0043-1778077>.  
ISSN 2348-0548.

© 2024. The Author(s).

This is an open access article published by Thieme under the terms of the Creative Commons Attribution License, permitting unrestricted use, distribution, and reproduction so long as the original work is properly cited. (<https://creativecommons.org/licenses/by/4.0/>)

Thieme Medical and Scientific Publishers Pvt. Ltd., A-12, 2nd Floor, Sector 2, Noida-201301 UP, India



**Fig. 1** Axial view of the computed tomography (CT) of the head showing left frontoparietal acute subdural hematoma with left frontotemporal contusion and sylvian subarachnoid hemorrhage with mass effect evident as midline shift.

In next 4 hours, noradrenaline (0.1  $\mu\text{g}/\text{kg}/\text{min}$ ) was added because of a drop in mean arterial pressure (MAP). Within 12 hours, noradrenaline had to increase to 0.266  $\mu\text{g}/\text{kg}/\text{min}$ . Furthermore, adrenaline (0.1  $\mu\text{g}/\text{kg}/\text{min}$ ), vasopressin (0.04 U/kg/h), and hydrocortisone were added to keep the patient hemodynamically stable. Bilateral basal crepitations were heard on chest auscultation.

At this stage, ECG revealed sinus tachycardia with low voltage complexes and U waves in inferior leads. Besides, TTE was suggestive of severe global left ventricular (LV) hypokinesia, severe LV systolic dysfunction with LV ejection fraction (LVEF) about 20 to 25%, mildly dilated LV, mildly dilated left atrium (LA), mild 2+ mitral regurgitation (MR), mild tricuspid regurgitation (TR), mild pulmonary arterial hypertension (PAH), and grade II diastolic dysfunction, with

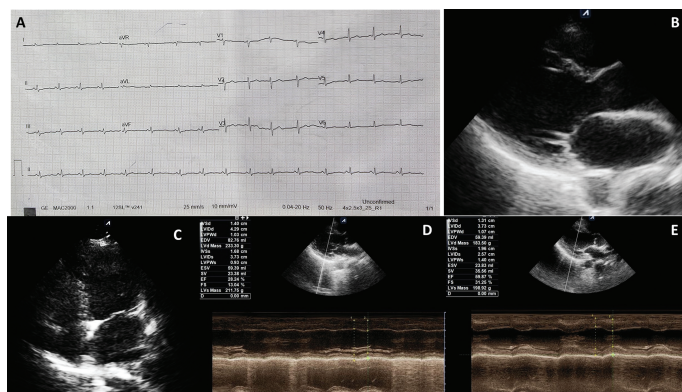
normal right ventricular (RV) systolic function, no intracardiac clot/vegetation, or pericardial pathology. Laboratory cardiac biomarkers exceeded pathological thresholds: CKMB was 36.01 IU/L (normal: 1–25 IU/L), troponin I raised to 1,985 ng/L (normal: <16 ng/L), and N-terminal prohormone of brain natriuretic peptide (NT-proBNP) was 3,968 pg/mL (normal: <75 years, <125 pg/mL). Dobutamine (6.7  $\mu\text{g}/\text{kg}/\text{min}$ ) was added to maintain cardiac contractility, and furosemide (0.1 mg/kg/h) to reduce the cardiac load. The patient continued to be mechanically ventilated, and tracheostomy was done. With this treatment, the patient started showing improvement. The heart rate decreased to less than 100 beats/min, and LVEF improved to about 25 to 30% on day 2. Adrenaline and vasopressin were withdrawn over the 3 days. Gradually, noradrenaline and dobutamine were withdrawn over the next 5 days. Serial TTE showed improvement in LV function, with an LVEF of 60% on day 9 (**Fig. 2**).

Coronary angiography was not performed as coronary artery disease (CAD) seemed unlikely, as ECG findings were not suggestive. Furthermore, recovery in cardiac function on serial TTE suggested TC as the underlying pathology. Finally, an improved patient (GCS E4VtM6) with an LVEF of 66% was discharged from the hospital on day 25.

## Discussion

TC, also known as “stress-induced cardiomyopathy,” “apical ballooning syndrome,” or “broken heart syndrome,” was first reported by the Japanese cardiologist Hikaru Sato (1990).<sup>2</sup> It is an acute, transient, and reversible heart failure syndrome due to regional wall motion abnormalities (RWMA) of the ventricular myocardium with associated new ECG changes and elevation of cardiac biomarkers in the absence of CAD.<sup>3</sup>

The clinical presentation varies from nonspecific to life-threatening symptoms. Almost 80 to 90% of TC patients are women older than 60 years. The common symptoms include chest pain (>75% of patients), dyspnea (50%), and dizziness (>25%).<sup>4</sup> Physical examinations remain consistent with acute systolic heart failure and reveal crackles, tachycardia, hypertension, and narrow pulse pressure.<sup>4</sup> Therefore,



**Fig. 2** Postoperative day 1 (A) electrocardiogram. Transthoracic echocardiogram (TTE) of systolic phase showing global LV hypokinesia. (B) Parasternal long-axis view. (C) Apical four-chamber view. (D) Day 2 TTE showing low ejection fraction. (E) Day 9 TTE showing improved cardiac functions.

diagnosing TC remains challenging in healthy young patients with low GCS scores.

Life-threatening complications like congestive heart failure (44–57% of cases), cardiogenic shock (15–45%), dysrhythmias (10%), pulmonary edema, thromboembolism, LV wall rupture, and death have been reported as fatal TC complications.<sup>5</sup>

Various diagnostic criteria for TC have been developed. The recent expert consensus statement came into clinical practice in 2018 as an International Takotsubo Diagnostic Criteria (InterTAK Diagnostic Criteria).<sup>6</sup> The InterTAK Diagnostic Criteria adhere to transient RWMA pertinent to TC and return to normal within a short period, presence of triggering factors, likely ECG changes (however, rare cases exist without ECG changes), elevation of cardiac biomarkers, and brain natriuretic peptide, predominantly in postmenopausal women with exclusion of infectious myocarditis and CAD.<sup>6</sup> The diagnosis remains straightforward when the patient's symptoms fit the criteria; however, atypical presentations (normal ECG/young age) may challenge it.

Likewise, in our case, the patient was unconscious and was on mechanical ventilation. She had a severe hypotension with basal crepitations, her ECG was not suggestive of acute coronary event, and TTE showed a global LV pathology without evidence of pulmonary embolism and myocarditis, suggesting TC as the most likely differential.

The management of TC remains mainly supportive, with prompt bedside cardiac assessment, and vasopressor and inotrope support in patients with cardiogenic shock. Cardiovascular function may be improved using dobutamine or other pharmacological or nonpharmacologic treatments, including extracorporeal life support.

Our patient's condition improved with use of dobutamine, reduction of cardiac load, and maintenance of hemodynamics with vasopressors, including ventilatory support. Recently, use of levosimendan has been reported in patients with aneurysmal SAH, where dobutamine was deemed ineffective. In a recent series, levosimendan was used successfully

used. The paucity of literature reporting its use is because of the rarity of the entity itself.<sup>7</sup>

In our case, although it was difficult to make a diagnosis with the symptoms alone, the criteria supporting the diagnosis of TC were based on the presence of a precipitating physical stressor (TBI), ECG finding excluding CAD, elevated troponin and NT-proBNP levels, a reversible LV dysfunction on serial TTE, followed by a complete recovery (LVEF of 66%) on day 19.

## Conclusion

Perioperative physicians need to have high index of suspicion to diagnose and appropriately treat TC in patients with severe TBI.

### Conflict of Interest

None declared.

## References

- Finsterer J, Wahbi K. CNS disease triggering Takotsubo stress cardiomyopathy. *Int J Cardiol* 2014;177(02):322–329
- Akashi YJ, Ishihara M. Takotsubo syndrome: insights from Japan. *Heart Fail Clin* 2016;12(04):587–595
- Cheah CF, Kofler M, Schiefecker AJ, et al. Takotsubo cardiomyopathy in traumatic brain injury. *Neurocrit Care* 2017;26(02):284–291
- Boyd B, Solh T. Takotsubo cardiomyopathy: review of broken heart syndrome. *JAAPA* 2020;33(03):24–29
- Lee SE, Yoon SH, Kang HJ, Ahn JH. Takotsubo syndrome as an overlooked and elusive cause of a single episode of dyspnea in young women: a case report. *BMC Cardiovasc Disord* 2021;21(01):430
- Ghadri JR, Wittstein IS, Prasad A, et al. International expert consensus document on Takotsubo syndrome (part I): clinical characteristics, diagnostic criteria, and pathophysiology. *Eur Heart J* 2018;39(22):2032–2046
- Santoro F, Ieva R, Ferraretti A, et al. Safety and feasibility of levosimendan administration in Takotsubo cardiomyopathy: a case series. *Cardiovasc Ther* 2013;31(06):e133–e137