



The Utility of Routinely Performing a Short-Interval Cholecystogram following Cholecystostomy Tube Placement

Jospeh Geisler¹ Mohammad Amarneh^{1,2}

¹ Department of Radiology, Division of Vascular and Interventional Radiology, University of Iowa Hospitals and Clinics, Iowa City, Iowa, United States

² Department of Radiology, Division of Interventional Radiology, Boston Children's Hospital, Harvard Medical School, Boston, Massachusetts, United States

Address for correspondence Mohammad Amarneh, MD, Division of Interventional Radiology, Boston Children's Hospital, Harvard Medical School, Boston, MA, 02115, United States
(e-mail: Mohammad.amarneh@childrens.harvard.edu).

Arab J Intervent Radiol 2024;8:27–30.

Abstract

Purpose The purpose of this study is to evaluate the utility of routinely performing short-interval cholecystogram (SIC) following percutaneous cholecystostomy tube (PCT) placement and to identify predictive factors for early PCT dislodgment.

Materials and Methods We conducted retrospective review of 224 adult patients who underwent PCT placement for acute cholecystitis at a single tertiary care medical center. SIC was defined as occurring at least 1 day after PCT placement and prior to the patient being discharged from the hospital. Early PCT dislodgment was defined as occurring within 2 months of placement.

Results Among 224 patients, 181 (80%) patients underwent SIC on average 3 days after PCT. Of these, 175 (97%) had PCT appropriately positioned, while 6 (3%) showed tube malposition outside the gallbladder. Patients who underwent a SIC demonstrated a similar rate of early tube dislodgment compared to those discharged without this procedure (12.6 vs. 14.3%, $p=0.81$). Notably, patients with a body mass index exceeding 40 kg/m² had a higher likelihood of early cholecystostomy tube dislodgment (29 vs. 14%, $p=0.038$).

Conclusion Routinely performing a SIC following PCT may offer limited benefit. We recommend selectively performing this study on patients with clinically suspected tube dislodgement.

Keywords

- ▶ acute cholecystitis
- ▶ percutaneous cholecystostomy
- ▶ short-interval cholecystogram
- ▶ PCT dislodgement

Introduction

Acute cholecystitis is a common disease that is traditionally treated with antibiotics and cholecystectomy. The 2018 Tokyo guidelines support early gallbladder drainage for patients with moderate or severe acute cholecystitis who are not surgical candidates.¹ Nationwide use of percutaneous cholecystostomy tube (PCT) is increasing among patients

admitted with acute cholecystitis. Some patients later undergo an interval cholecystectomy, while others have the tube in place for the remainder of their life or eventually have the tube removed without surgery.^{2,3}

Several studies have examined the long-term outcomes of PCTs; however, there is little discussion in the literature regarding the frequency of early PCT dislodgement and how to prevent this event. Feared complications of early PCT

article published online
January 31, 2024

DOI <https://doi.org/10.1055/s-0043-1778119>.
ISSN 2542-7075.

© 2024. The Author(s).

This is an open access article published by Thieme under the terms of the Creative Commons Attribution License, permitting unrestricted use, distribution, and reproduction so long as the original work is properly cited. (<https://creativecommons.org/licenses/by/4.0/>)

Thieme Medical and Scientific Publishers Pvt. Ltd., A-12, 2nd Floor, Sector 2, Noida-201301 UP, India

dislodgement include recurrent cholecystitis and bile leak if the tube is dislodged prior to tract maturation.⁴

The authors' institutional practice has long involved the routine performance of a short-interval cholecystogram (SIC) following PCT. During the PCT procedure, we intentionally restrict contrast injection to prevent the excessive distension of an obstructed gallbladder, thus reducing the risk of intraprocedural sepsis. Subsequently, within the same hospital admission, a SIC is performed. This procedure allows for ample time for the gallbladder to decompress, serving the dual purpose of confirming the correct tube positioning and assessing the patency of the cystic duct. While the practice of SIC has been sporadically discussed in the literature,⁵ comprehensive studies examining the benefits of routinely implementing this imaging procedure are scarce.

To the best of our knowledge, no study has undertaken a systematic evaluation of the advantages conferred by this practice. Hence, the principal aim of this study is to assess the efficacy of routinely conducting a SIC and to identify potential predictive factors for early PCT dislodgment.

Materials and Methods

This study was conducted with institutional review board approval. A retrospective search of the medical record of a single tertiary care academic medical center was performed to identify all adult patients who underwent PCT placement between January 2016 and December 2020. Patients younger than 18 years old and those who had PCT placed for an indication other than acute cholecystitis (e.g., biliary diversion) were excluded from this study.

Data regarding preprocedure imaging, PCT placement, laboratory results, SIC results, tube dislodgement and subsequent management, and PCT outcome were recorded and analyzed. Statistical analysis was performed using spreadsheet software (Excel 2019; Microsoft, Redmond, Washington, United States).

Preprocedure imaging was defined as any imaging modality that included the gallbladder performed within 7 days of cholecystostomy tube placement. The type of acute cholecystitis (calculous, acalculous, and gangrenous/perforated) for which cholecystostomy tube was placed was determined by reviewing clinical notes and preprocedure imaging. SIC was defined as occurring at least 1 day after percutaneous cholecystostomy tube placement and prior to the patient being discharged from the hospital. Patients underwent PCT exchange as an outpatient 6 to 8 weeks after placement. Therefore, we defined early PCT dislodgment as an instance where the tube was found outside of the gallbladder lumen within 8 weeks of tube placement.

Results

Two hundred twenty-four patients were identified who fit the inclusion criteria. There were 141 (63.0%) males and 83 (37%) females. The mean patient age was 66.4 years (range: 18–96 years). The average patient body mass index (BMI) was 30.3 kg/m² (range: 14.2–74.7).

Most commonly an 8-French pigtail catheter was used for initial PCT ($n=200$, 89.3%), while 10-French catheters ($n=20$, 8.9%) and 6-French catheters ($n=4$, 1.8%) were used less frequently. Nearly all cholecystostomy tubes were either Skater (Argon Medical Devices, Frisco, Texas, United States) or Mac-Loc (Cook Medical, Bloomington, Indiana, United States) locking pigtail catheters. PCTs were secured to the skin with a 2-0 Prolene suture (Ethicon Inc., Raritan, New Jersey, United States). Both transhepatic and transperitoneal techniques were used for cholecystostomy tube placement. The technical success rate for PCT placement was 100%. All PCTs were performed by one of six board-certified interventional radiologists.

Indication and Preprocedure Imaging

The most common indication for PCT was acute calculous cholecystitis ($n=153$, 68.3%) followed by acalculous cholecystitis ($n=42$, 18.8%) and gangrenous/perforated cholecystitis ($n=29$, 12.9%).

Prior to cholecystostomy tube placement, 187 (83.5%) patients underwent an ultrasound, 172 (76.8%) underwent a CT that included the abdomen, 69 (30.1%) underwent a HIDA (hepatobiliary iminodiacetic acid) scan, and 20 (8.9%) underwent an MRI of the abdomen. All patients underwent either an ultrasound or CT abdomen prior to PCT placement. Most patients (72.2%) underwent multiple imaging studies prior to tube placement. The most common combination of preprocedure imaging studies was both ultrasound and CT ($n=93$, 41.5%), followed by ultrasound, CT and HIDA scan ($n=34$, 15.2%), followed by ultrasound and HIDA scan ($n=20$, 8.9%).

Short-Interval Cholecystogram Results

One hundred eighty-one patients (80.8%) underwent SIC at least 1 day after PCT placement and before discharge from the hospital. The SIC was performed an average of 3 days following PCT placement (range: 1–25 days). SIC showed the pigtail catheter tip located within the gallbladder lumen in 175/181 (96.7%) patients and showed a malpositioned PCT with tip outside of the gallbladder lumen in six patients (3.3%). Of the 175 SICs that showed an appropriately positioned PCT, 92 (52.5%) showed a patent cystic duct, while 83 (47.5%) showed an occluded cystic duct. There was no statistically significant correlation between the type of acute cholecystitis and the likelihood of cystic duct patency (► **Table 1**).

Two of the six patients with malpositioned PCT had a fresh-stick PCT placed immediately following the cholecystogram. The other four had the malpositioned tubes removed without immediate replacement. Two of these four patients died within 30 days; one underwent cholecystectomy 1 month later, and the other underwent cholecystectomy 3 months later. Additionally, 6 patients without tube dislodgement had PCT exchange and/or repositioning at the time of SIC due to kinking visualized in the abdominal wall or patient discomfort (► **Fig. 1**).

Early PCT Dislodgement

Early PCT dislodgement occurred in 35 (15.6%) patients. Patients who underwent a SIC and were discharged with tube in the gallbladder lumen had a similar rate of early PCT

Table 1 Short-interval cholecystogram results

	Cystic duct occluded (n = 83, 47%)	Cystic duct patent (n = 92, 53%)
Calculous cholecystitis (n = 122)	60 (49%)	62 (51%)
Acalculous cholecystitis (n = 30)	13 (43%)	17 (57%)
Gangrenous and/or perforated Cholecystitis (n = 23)	10 (44%)	13 (56%)

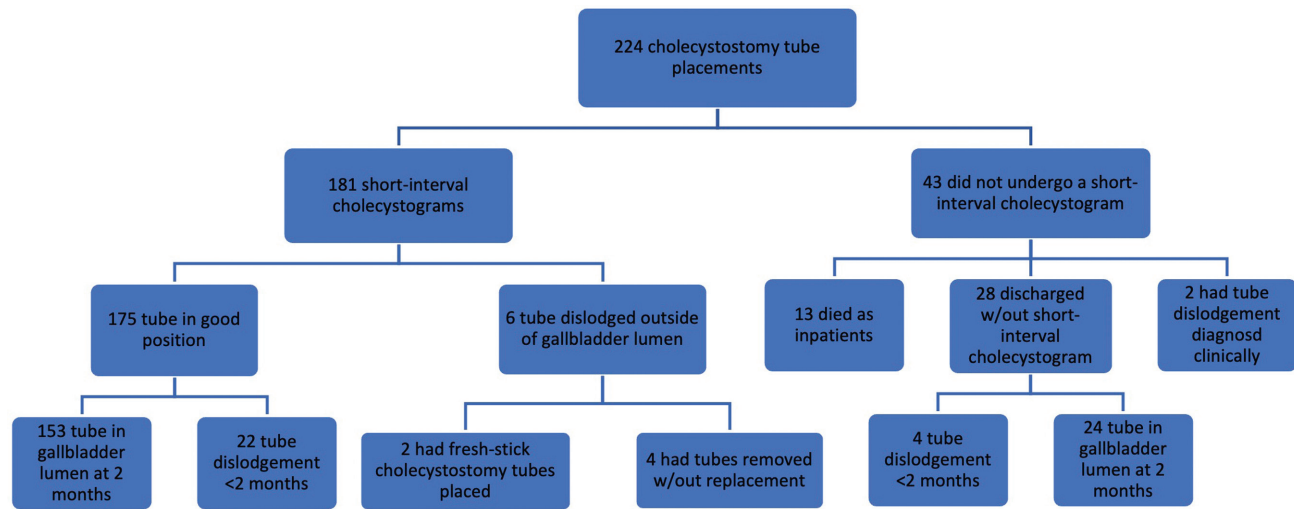


Fig. 1 Summary of study results.

dislodgement compared with those who were discharged from the hospital without undergoing this study (12.6 vs. 14.3%, $p = 0.81$). Patients with a BMI greater than 40 kg/m^2 were more likely to have early PCT dislodgment compared with patients with a BMI less than 40 kg/m^2 (29 vs. 14%, $p = 0.038$) (→ **Fig. 2**). Patient age, sex, and type of acute cholecystitis were not found to correlate with likelihood of early PCT dislodgement.

Discussion

Early PCT is a common challenge encountered in clinical practice, affecting approximately 15.6% of the patients in our study. This prevalence aligns with the reported 6 to 15% dislodgment rate in the existing literature.⁶⁻⁹ Our research indicates that the likelihood of early PCT dislodgment is comparable between patients who underwent a normal

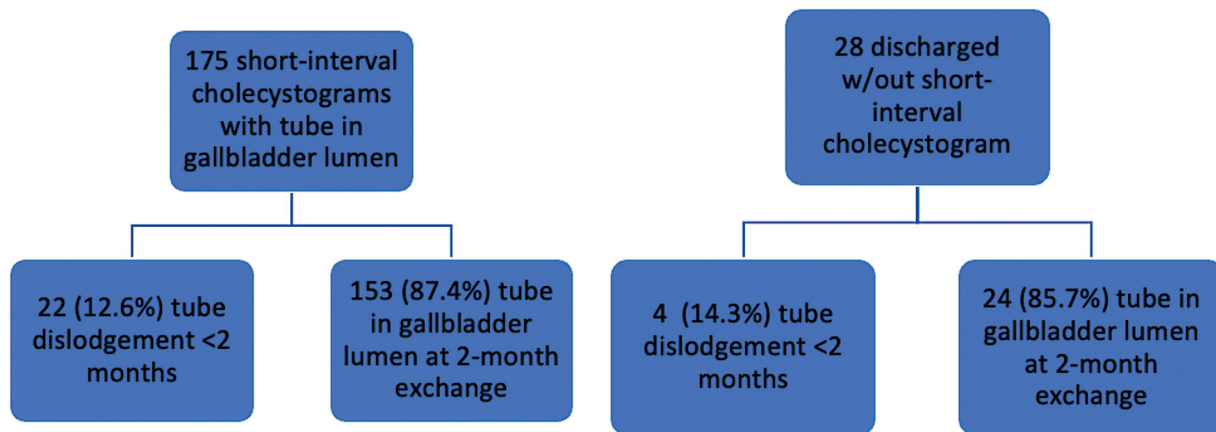


Fig. 2 Patients who underwent a short-interval cholecystogram and were discharged with tube in the gallbladder lumen had a similar rate of early tube dislodgement (occurring <2 months after placement) compared with those who were discharged from the hospital without undergoing this study (12.6 vs. 14.3%, $p = 0.81$).

SIC and those who were discharged from the hospital without this study (12.6 vs. 14.3%, $p = 0.81$).

Notably, our study found that patients with a BMI greater than 40 kg/m² exhibited a significantly higher incidence of early PCT dislodgment. This observation indirectly supports the findings of Jonasch et al, who reported that tube length is an independent and significant factor affecting the rate of PCT dislodgment.¹⁰ In their retrospective review of 216 patients, they noted a 2.2% increase in the risk of tube dislodgment for each millimeter increase in path length, suggesting that such patients may benefit from additional strategies to mitigate early tube dislodgment.

Current best practices suggest leaving PCTs in place for tract maturation for at least 3 to 6 weeks. Some publications have proposed the possibility of earlier drain removal (<3 weeks) but recommended conducting an over-the-wire sheath fistulography to study tract maturation in this scenario.⁴ While this approach may lead to earlier PCT removal and an improved quality of life for patients, it necessitates an additional procedure and poses the risk of recurrent acute cholecystitis. An alternative strategy could involve capping the PCT if the SIC confirms patent cystic duct and removing the drain after 3 to 6 weeks without a tract study, or earlier with a tract study. However, it is imperative to underscore that this alternative approach warrants further research and consideration.

Interestingly, only two out of the six patients with a dislodged PCT detected on the SIC required tube reinsertion. This implies that clinical suspicion, based on decreased PCT output and the absence of clinical improvement, could have guided the need for tube replacement even without the cholecystogram.

The study findings indicate that the routine practice of conducting a SIC after PCT placement may offer limited advantages in mitigating early PCT dislodgment. Consequently, the authors advocate for a more pragmatic approach, emphasizing close monitoring of PCT output and reserving cholecystogram assessments for situations where there is clinical suspicion of tube malfunction. This suspicion may arise from symptoms such as pain during flushing, persistently low tube outputs, visible catheter retraction, and similar indicators.

It is noteworthy that the authors of this study have adjusted their clinical protocols based on these conclusions. This underscores the vital role of questioning and reassessing established clinical practices through rigorous research and quality improvement initiatives.

It is crucial to acknowledge the limitations of our study, including its retrospective design, data collection spanning a

5-year period, and reliance on a single institution's patient population.

Conclusion

Routinely performing a SIC following PCT may be of limited benefit. We suggest selectively performing this study on patients with clinically suspected tube dislodgment.

Ethical Approval Statement

This study has obtained IRB approval from the University of Iowa Institutional Review Board and the need for informed consent was waived.

Conflict of Interest

None declared.

References

- 1 Mayumi T, Okamoto K, Takada T, et al. Tokyo Guidelines 2018: management bundles for acute cholangitis and cholecystitis. *J Hepatobiliary Pancreat Sci* 2018;25(01):96–100
- 2 Bundy J, Srinivasa RN, Gemmete JJ, Shields JJ, Chick JFB. Percutaneous cholecystostomy: long-term outcomes in 324 patients. *Cardiovasc Intervent Radiol* 2018;41(06):928–934
- 3 Wadhwa V, Trivedi PS, Makary MS, et al. Utilization and outcomes of cholecystostomy and cholecystectomy in patients admitted with acute cholecystitis: a nationwide analysis. *AJR Am J Roentgenol* 2021;216(06):1558–1565
- 4 Wise JN, Gervais DA, Akman A, Harisinghani M, Hahn PF, Mueller PR. Percutaneous cholecystostomy catheter removal and incidence of clinically significant bile leaks: a clinical approach to catheter management. *AJR Am J Roentgenol* 2005;184(05):1647–1651
- 5 De Geus T, Moriarty HK, Waters PS, et al. Outcomes of patients treated with upfront cholecystostomy for severe acute cholecystitis. *Surg Laparosc Endosc Percutan Tech* 2020;30(01):79–84
- 6 Boules M, Haskins IN, Farias-Kovac M, et al. What is the fate of the cholecystostomy tube following percutaneous cholecystostomy? *Surg Endosc* 2017;31(04):1707–1712
- 7 Pang KW, Tan CH, Loh S, et al. Outcomes of percutaneous cholecystostomy for acute cholecystitis. *World J Surg* 2016;40(11):2735–2744
- 8 Duncan C, Hunt SJ, Gade T, Shlansky-Goldberg RD, Nadolski GJ. Outcomes of percutaneous cholecystostomy in the presence of ascites. *J Vasc Interv Radiol* 2016;27(04):562–6.e1
- 9 Kallini JR, Patel DC, Linaval N, Phillips EH, Van Allan RJ. Comparing clinical outcomes of image-guided percutaneous transperitoneal and transhepatic cholecystostomy for acute cholecystitis. *Acta Radiol* 2021;62(09):1142–1147
- 10 Jonasch D, Raza S, Voutsinas N. Abstract no. 176 influence of clinical and procedural factors on rate of cholecystostomy tube dislodgement and other complications. *J Vasc Interv Radiol* 2023;34(03):S80–S81