Article published online: 2024-01-15

Healing of Humeral Intracondylar Fissure Following Distal Ulnar Ostectomy to Treat Concurrent Elbow Joint Incongruity in a Dog

Rodrigo Alvarez[1] Claudio Motta[2]

[1] Department of Surgery, Southern Counties Veterinary Specialists, Forest Corner Farm, Hangersley, Ringwood, Hampshire, United Kingdom of Great Britain and Northern Ireland
[2] Department of Surgery, Southern Counties Veterinary Specialists, Ringwood, Hampshire, United Kingdom of Great Britain and Northern Ireland

Address for correspondence Rodrigo Alvarez, DVM, GPCert (SAS) MRCVS, Forest Corner Farm, Hangersley, Ringwood BH24 3JW, United Kingdom of Great Britain and Northern Ireland (e-mail: rav94av@gmail.com).

VCOT Open 2024;7:e17–e22.

Abstract

A 22-week-old female Labrador retriever presented with intermittent bilateral forelimb lameness. Computed tomography (CT) study interpretation revealed bilateral humeral intracondylar fissures (HIF) surrounded by sclerotic epiphyseal bone. Other changes included bilateral distal ulna retained cartilage core, secondary negative radioulnar incongruity (RUI), and medial coronoid process disease. The patient underwent bilateral dynamic distal ulnar ostectomies (DUO) in an attempt to address the elbow incongruity. Follow-up CT studies were performed at 2, 4, and 10 months postoperatively, which showed a bilateral improvement of elbow congruence and complete healing of HIF on the left side. The degree of congruence correction in the right elbow was possibly suboptimal, and following an initial improvement, a transcondylar screw was placed due to HIF progression.

Keywords
- elbow dysplasia
- humeral intracondylar fissure
- dog

Introduction

The etiology of humeral intracondylar fissures (HIF) has been widely investigated in previous studies,[1–6] but its etiology remains largely unclear.[1,2,4,5] Previous hypotheses proposed that HIF represent an incomplete fusion/ossification of the secondary ossification centers of the humeral condyle[5] or can be a manifestation of a stress fissure occurring following complete ossification.[1,2,4,7] A genetic,[5] metabolic,[8] conformational,[2,3,9] and an environmental component in dogs with high levels of activity[10,11] have also been considered. Regardless of its etiopathogenesis, a proposed theory attributes condylar failure to the presence of biomechanical abnormalities caused by elbow incongruity, which produces aberrant shear forces onto the humeral condyle.[1,2,11–13] Shear forces may prevent or delay ossification or may generate a fissure/fracture secondary to abnormal mechanical stress.[1–5] Previous literature reported significant association between elbow dysplasia and HIF,[2,5,12,14] although there are no conclusive studies that directly link these two processes.

Humeral intracondylar fissures are of highest prevalence in English Springer Spaniels, American Cocker, and French Bulldog,[1,11,15–19] but this condition has also been reported in other breeds (Labrador Retriever, English Pointer, German Shepherd Dog, Rottweiler, Tibetan Mastiff, and German Wachtel).[1,11,15–19] This report aims to describe the case of a Labrador Retriever diagnosed with severe negative radioulnar incongruity (RUI) suspected to be secondary to distal ulna retained cartilaginous core. A computed tomography (CT) study revealed bilateral complete HIF and bilateral medial compartment disease (MCD). Following treatment involving bilateral distal ulnar ostectomy (DUO), follow-up

received
October 30, 2023
accepted after revision
November 28, 2023

DOI https://doi.org/10.1055/s-0043-1778129.
ISSN 2625-2325.

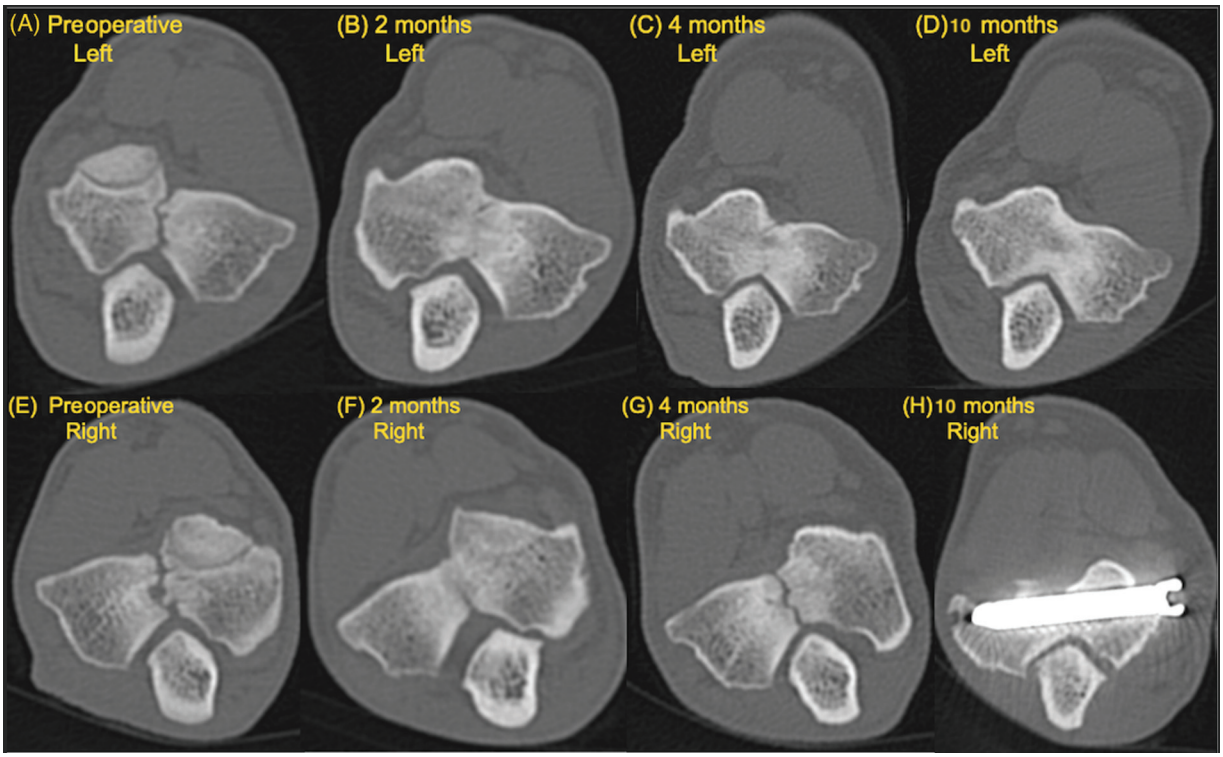

Fig. 1 Two-dimensional reconstructed views of the (**A**–**D**) left and (**E**–**H**) right humeral condyle acquired by computed tomography showing healing of the previously detected complete fissure of the left condyle visible in the transverse plane (**A**–**D**) and a progression on the right intracondylar fissure after initial improvement.

CT revealed bilateral improvement of elbow congruence and complete fusion of the left HIF (►**Fig. 1**). To the best of the authors' knowledge, this is the first report of ossification of an HIF after performing DUO surgery to address RUI.

Case Description

A 22-week-old entire female Labrador Retriever, weighing 16 kg and a body condition score of 5/9, was presented for investigation of bilateral forelimb lameness persisting for 2 months. The referring veterinarian and owners reported that the lameness began following a short period of generalized illness, characterized by lethargy, anorexia, reluctance, and inability to stand. Diagnostic investigations at the referring practice included standard bilateral orthogonal radiographic views of shoulders, elbows, and carpi, revealing no abnormalities in the shoulders or carpi but indicating retained cartilage cores in the distal ulnas and subchondral sclerosis at the level of the semilunar notch. On the day of the referral, the patient's lameness was subjectively evaluated, revealing bilateral forelimb lameness, with the right forelimb being more affected. Bilateral moderate elbow effusion was palpable, and there was severe discomfort upon extension of the elbows.

A CT study of the antebrachia was performed under sedation using butorphanol (Torbugesic; Zoetis US) 0.3 mg/kg and medetomidine (Domitor, Orion Pharma) 20 µg/kg, both intravenously. The patient was positioned on the CT table in sternal recumbency with the elbows parallel and extended cranially. Slice thickness was 1.1 mm, with 0.6-mm bed increment to ensure high-quality reconstruction. CT image interpretation confirmed the diagnosis of bilateral retained endochondral cartilage cores on the ulnar physis. The images also revealed an irregular and elongated trochlear notch and a widened humeroulnar space (►**Fig. 2**). A well-defined hypoattenuating line extending from the distal articular surface to the supratrochlear foramen compatible with bilateral complete HIF was bilaterally detected in the bone window reconstruction. The coronoid process appeared bilaterally irregular and hypoattenuating, which was suggestive of medial coronoid disease and mild secondary osteoarthritis, which prompted bilateral dynamic DUO. The surgery was scheduled for the following day. The patient was premedicated using methadone (Comfortan; Dechra) 0.3 mg/kg intravenous (iv) and medetomidine (Domitor; Orion Pharma) 5 µg/kg iv and anesthesia induced using propofol (Abbott Laboratories) 1 mg/kg iv and maintained with isoflurane (IsoFlo; Abbott Laboratories Ltd) in oxygen. Surgical intervention involved bilateral caudolateral approaches to the distal ulnar diaphysis. The DUO were performed using a long, narrow microsagittal saw blade, oriented based on intraoperative and subjective assessment, approximately 2 to 3 cm proximal to the distal ulnar physis line, allowing for the removal of approximately 10-mm sections of bone. The surgical site was then closed: the fascia was sutured using 2–0 polydioxanone (PDS; Ethicon), the subcutaneous tissue and skin were closed with 3–0 poliglecaprone (Monocryl; Ethicon) utilizing an intradermal pattern, and the wound was covered with cyanoacrylate tissue adhesive (Dermabond; Ethicon). The postoperative radiographs confirmed the accurate positioning of the ostectomies. The patient recovered uneventfully from anesthesia. Computed tomography studies were performed at

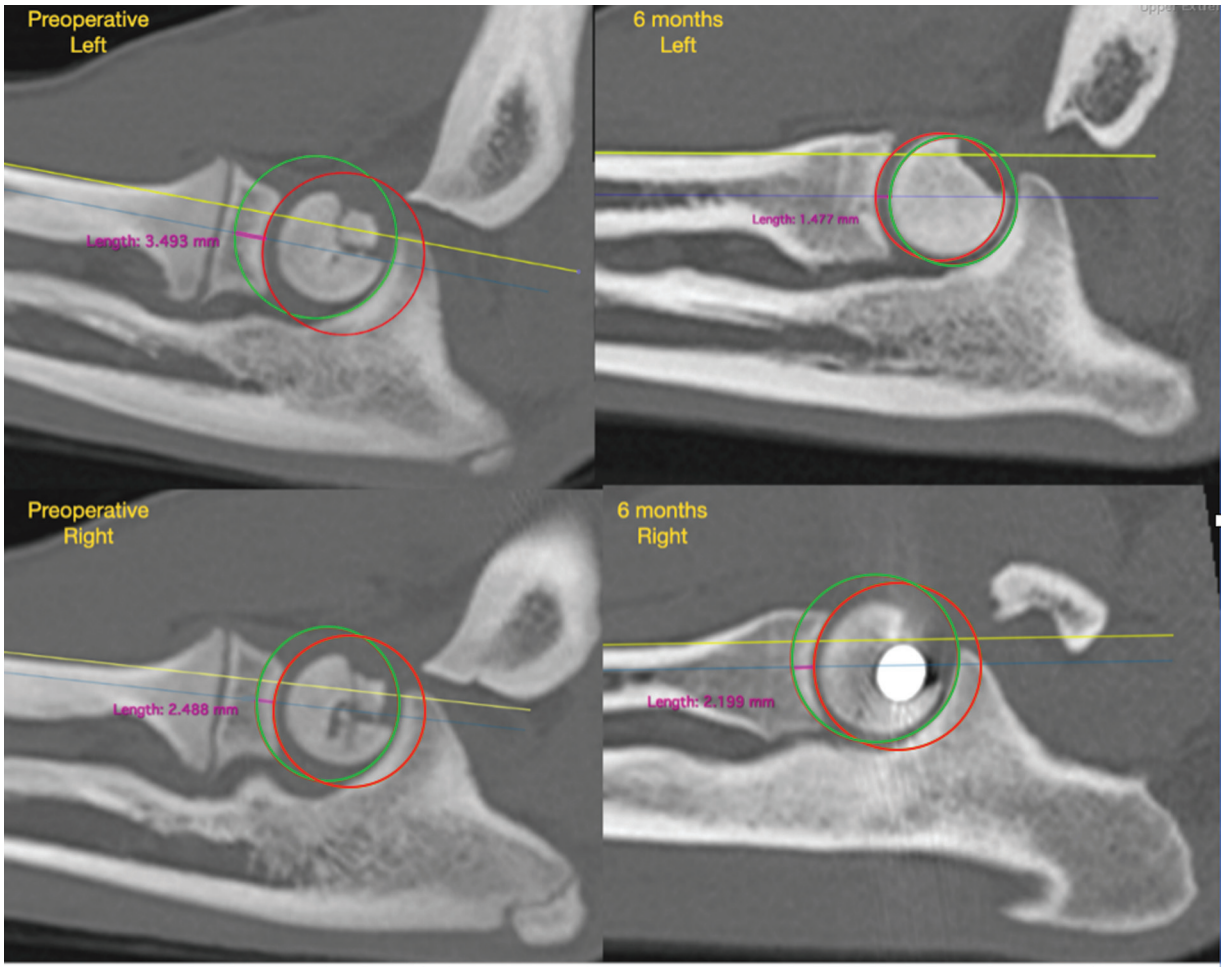

Fig. 2 Quantification of incongruence on the left and right elbows using a circle superimposition technique for preoperative computed tomography (CT) images and 10 months after a distal ulnar ostectomy (DUO) surgery.

2, 4, and 10 months postoperatively. On every occasion, sedation was induced as described earlier for the original CT imaging. Assessment of the images of the left elbow revealed an improvement in congruence (►**Fig. 2**) despite the humeroulnar space remaining markedly widened and uneven. The right elbow initially demonstrated residual marked incongruity, featuring an increased humeroulnar space. Subsequent to the surgical intervention, a mild improvement in congruence was observed at the 2-month postoperative CT study. However, no further improvement in congruence was noted in subsequent CT series (►**Fig. 2**). The studies revealed progressive radiographic evidence of bone healing in the left HIF, resulting in complete radiographic attenuation of the previously detected defect as depicted in ►**Fig. 1**. On the right side, a similar decrease in size of the HIF was observed in line with the contralateral joint. However, at the 4-month postoperative evaluation, a significant widening of the HIF on the right was observed, prompting the decision for prophylactic transcondylar screw placement. Additionally, a bilateral elbow arthroscopy was performed to assess the articular cartilage, evaluate the HIF, and remove the medial coronoid process fragment in the right elbow (►**Fig. 3**). Four months after surgery, bilateral callus formation was observed bridging the ulnar ostectomy, with mild irregular periosteal reaction along the caudal cortex

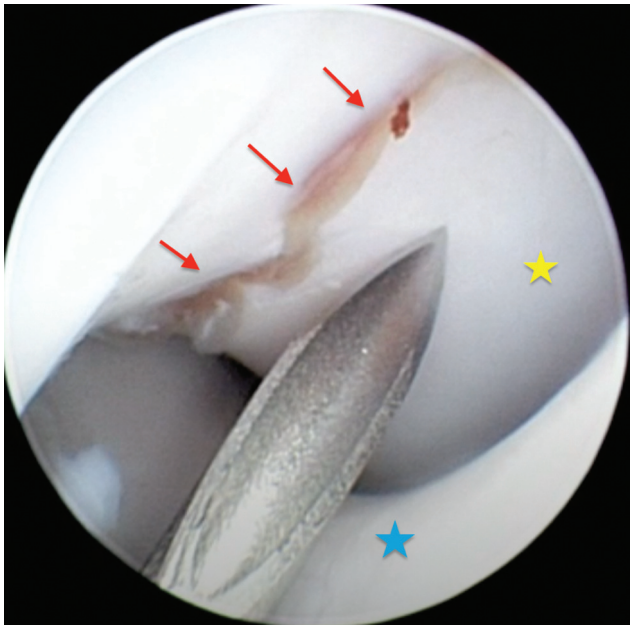

Fig. 3 Arthroscopic image of the right elbow. A humeral intracondylar fissure HIF (*red arrows*) is visible in the center of the humeral condyle. The *yellow star* indicates the humeral condylar trochlea articular surface. The *blue star* indicates the trochlear notch.

of the radius diaphysis. At this stage, persistent right forelimb lameness was noted, and this further supported the decision to address the widening of the HIF and medial coronoid process fragmentation. The patient was sedated using medetomidine (Domitor; Orion Pharma) 5 µg/kg iv, methadone (Comfortan; Dechra) 0.3 mg/kg iv, and acepromazine (Acetate; Novartis Animal Health) 10 mg/kg iv. Propofol (Abbott Laboratories) 1 mg/kg iv was used to induce the anesthesia, which was maintained with isoflurane (IsoFlo; Abbott Laboratories Ltd) in oxygen. An approach to the right medial humeral epicondylar region facilitated transcondylar sequential drilling under fluoroscopic guidance to permit placement of a transcondylar 5-mm, 40-mm-long titanium locking screw. Following thorough lavage, closure was routine with intradermal suture and tissue adhesive (cyanoacrylate). Elbow arthroscopy was subsequently conducted with a 2.7-mm-diameter 30-degree oblique arthroscope, with the use of medial elbow portals. Joint exploration revealed a modified Outerbridge score of 3 out of 5 on the base of the right medial coronoid process, with a well-demarcated medial coronoid fragment that was readily detached and removed. The affected cartilage was removed with a probe and the underlying sclerotic bone was debrided with a hand burr until healthy bleeding subchondral bone was encountered. Arthroscopic examination of the humeral intracondylar region revealed a line of fibrous tissue in the humeral condyle in the location of the HIF. Absorbable cruciate sutures (3–0 poliglecaprone; Monocryl, Ethicon) were used to close the skin incision. Arthroscopy of the contralateral (left) elbow had a modified Outbridge score of 0, with no overt articular portion of the partial intracondylar fissure or any medial coronoid changes suggestive of fissuring or coronoid fragmentation. The dog recovered uneventfully from anesthesia. The patient returned to the hospital 6 weeks postoperatively. The owner reported a progressive improvement of forelimb function following surgery. On presentation, the patient showed a mild bilateral lameness, as well as a mild loss of muscle mass in the forelimbs. Elbow manipulation revealed bilateral mild pain response to extension. Six months after transcondylar screw placement (10 months after bilateral DUO), the patient returned for a follow-up examination and repeated CT scan. According to the owner, the patient had experienced fluctuating mild lameness in the right forelimb, while the overall function of the left forelimb was deemed satisfactory. On examination, moderate muscle atrophy in the right forelimb and severe right elbow effusion were detected. Manipulation of the right elbow was moderately painful, particularly during extension. There was a mild reduction in the range of motion during extension of the left elbow. Manipulation of the left carpus elicited discomfort during flexion, and manipulation of the left elbow elicited mild pain during full extension. Mild periarticular new bone formation was observed bilaterally, suggesting a progression of osteoarthritis. On the left elbow, there was no evidence of HIF, although the condyle demonstrated persistent sclerosis. Conversely, the HIF remained apparent on the right elbow, despite the presence of a transcondylar screw (►**Fig. 1**). The left elbow showed minimal incongruity, transitioning from a negative to a positive radioulnar step, as indicated by the circles of best fit. The right elbow demonstrated persistent moderate RUI (►**Fig. 2**). At this stage, the ostectomies had fully ossified.

Discussion

The etiology of HIF has been a subject of interest and debate. One widely discussed theory proposes that abnormal loading forces acting on the condyle might hinder ossification in immature patients or lead to stress (fatigue) fissures/fractures in older patients.[1–5] Regarding the timing of union of the medial and lateral condyle ossification centers, there is a lack of up-to-date advanced imaging-based studies. Current publications[20,21] estimate that ossification begins during the first 3 weeks of life, but the specific union time varies significantly, ranging from 8 weeks to 4 months. Caution should be exercised when diagnosing HIF in skeletally immature animals, since these estimations are derived from old radiograph studies with inconsistent results. The term incomplete ossification of the humeral condyle encompasses nonunion of the secondary centers of ossification of the humeral condyle, and its etiology may involve genetic causes, abnormal loading on the elbow joint, vascular abnormalities, hormonal variations, or a combination of these factors.[1,2,4,5,7,8] The lesion's location and a potential breed predisposition in Spaniels and French Bulldogs have led to hypotheses of problems in ossification.[1,11,15–19] However, some authors have reported HIF in healthy and normally ossified elbows, challenging the assumption of ossification issues in all cases.[4,6,22] On the other hand, stress fissures/fractures resulting from chronic abnormal stress forces on healthy bone have been proposed as a contributing factor.[1–3,7,12] Evidence supporting the presence of abnormal forces on elbows with HIF comes from a study that observed complex multidirectional patterns of screw fractures used to treat HIF, hinting at intracondylar instability that hinders regeneration.[3] Histological samples from the fracture site also align with the presence of abnormal forces, showing fibrous tissue with increased osteoclastic activity, plasma cells, osteonecrosis, and sclerosis, with an absence of chondrocytes or cartilage matrix.[5,11] These findings resemble those seen in fatigue fissures/nonhealing fractures observed in other contexts.[4,5,11] A suggested relationship between HIF and other elbow abnormalities has been mentioned previously.[2,12] The concomitant presence of HIF with MCD and elbow incongruity has been observed, leading to the hypothesis that incongruity may be a potential cause of condylar failure of fusion.[2,12] Recent arthroscopy-based findings describing humero-anconeal incongruity in cases of HIF and its absence in healthy elbows support the notion of a possible causal association between these two processes.[12] In the case presented here, the clinical signs and examination findings localized the source of the lameness to the elbows. The patient exhibited severe bilateral RUI due to premature closure of the ulnar physis (►**Fig. 2**) as well as bilateral HIF. In consideration of the patient's age and skeletal maturity, a DUO was chosen over a proximal osteotomy.[23–26] The initial treatment plan included a staged approach, wherein the first step involved DUO, followed by the subsequent

placement of prophylactic transcondylar screws. Subsequent evaluation after the ostectomies revealed partial bilateral ossification of the HIF. Considering this observation, a conservative approach was initially taken, opting to monitor the condition and repeat imaging tests. The left side showed a complete union of the HIF and satisfactory improved incongruity correction (►**Figs. 1** and **2**). In contrast, the right side exhibited less successful incongruity correction, along with HIF progression and concurrent fragmentation of the medial coronoid process. These findings prompted the decision to intervene, and a subtotal coronoid ostectomy and placement of a transcondylar screw were performed on the right side to address the underlying pathology.

The reasons for the variation in incongruity progression between the two sides remain speculative. The right elbow incongruity was more severe, which could have contributed to the suboptimal outcome. Although no complications were observed with the healing of the ostectomies, there is a possibility that the right side ulnar ostectomy healed prematurely, potentially explaining the less favorable outcome. It is worth noting that cases of spontaneous ossification of HIF are exceedingly rare and have not been widely reported in the literature. Despite multiple methods of healing enhancement, rate of HIF healing remains lower than expected, with some authors reporting low rates of healing[1] and others reporting more positive results.[14,27] However, there exists a single case report of a spontaneous resolution of an HIF in a very young French Bulldog puppy.[28] Although this report suggests a possibility of spontaneous healing, it is crucial to acknowledge that the tendency of these defects is typically not to heal. Furthermore, given the age of the animal in the mentioned case, the presence of a definitive HIF diagnosis might be questionable. While this report provides interesting insights, it remains an isolated and exceptional observation in contrast to the established understanding of HIF cases.

The authors speculate that improved elbow congruence after ulnar osteotomy procedures may permit condylar healing. This suggests a possible correlation between HIF development, healing, and abnormal forces generated by elbow incongruity. Recently, a similar healing outcome in bilateral HIF was reported in a case report where proximal osteotomies of the ulna were performed,[29] and a series of cases utilizing this treatment approach was presented at a recent congress, providing further support to our observations.[30] It is important to acknowledge that this study is based on a single case report, and further research is warranted to draw definitive judgment.

In conclusion, RUI and HIF, although seen only in this singular case, raise the intriguing possibility of a potential relationship between the two. Such assumed association prompts the need for further investigations into joint incongruity and HIF, and, in particular, to assess whether DUO in juvenile patients may enhance HIF healing. Recent investigations[12,29,30] support this suggested link between incongruity and HIF, reinforcing a cause-and-effect hypothesis. Caution is advised in attributing the healing of the left-sided HIF solely to DUO, as there may be cases of spontaneous resolution or delayed ossification in dogs with HIF. This single case report, although yielding interesting insights, cannot provide far-reaching recommendations on possible effects of osteotomy on cases with HIF. Additional clinical research will be necessary to better understand the postulated intricate effects of joint incongruity on HIF and the value of treatment by corrective osteotomies.

Funding
None.

Conflict of Interest
None declared.

References

1 Butterworth SJ, Innes JF. Incomplete humeral condylar fractures in the dog. J Small Anim Pract 2001;42(08):394–398
2 Carrera I, Hammond GJ, Sullivan M. Computed tomographic features of incomplete ossification of the canine humeral condyle. Vet Surg 2008;37(03):226–231
3 Charles EA, Ness MG, Yeadon R. Failure mode of transcondylar screws used for treatment of incomplete ossification of the humeral condyle in 5 dogs. Vet Surg 2009;38(02):185–191
4 Farrell M, Trevail T, Marshall W, Yeadon R, Carmichael S. Computed tomographic documentation of the natural progression of humeral intracondylar fissure in a cocker spaniel. Vet Surg 2011;40(08):966–971
5 Marcellin-Little DJ, DeYoung DJ, Ferris KK, Berry CM. Incomplete ossification of the humeral condyle in spaniels. Vet Surg 1994;23 (06):475–487
6 Witte PG, Bush MA, Scott HW. Propagation of a partial incomplete ossification of the humeral condyle in an American cocker spaniel. J Small Anim Pract 2010;51(11):591–593
7 Walton MB, Crystal E, Morrison S, et al. A humeral intracondylar repair system for the management of humeral intracondylar fissure and humeral condylar fracture. J Small Anim Pract 2020;61(12):757–765
8 Strickland AL, Sprinz H. Studies of the influence of estradiol and growth hormone on the hypophysectomized immature rat epiphyseal cartilage growth plate. Am J Obstet Gynecol 1973;115(04): 471–477
9 Larsen LJ, Roush JK, McLaughlin RM, Cash WC. Microangiography of the humeral condyle in Cocker Spaniel and non-Cocker Spaniel dogs. Vet Comp Orthop Traumatol 1999;12(03): 134–137
10 Denny HR. Condylar fractures of the humerus in the dog; a review of 133 cases. J Small Anim Pract 1983;24(04):185–197
11 Gnudi G, Martini FM, Zanichelli S, et al. Incomplete humeral condylar fracture in two English Pointer dogs. Vet Comp Orthop Traumatol 2005;18(04):243–245
12 Danielski A, Yeadon R. Humero-anconeal elbow incongruity in spaniel breed dogs with humeral intracondylar fissure: arthroscopic findings. Vet Surg 2022;51(01):117–124
13 Schmidt TH, Fischer M, Böttcher P. Three dimensional in vivo kinematography of the canine elbow joint in sound dogs and in dogs with elbow dysplasia. Vet Surg 2014;43(05):e123
14 Meyer-Lindenberg A, Heinen V, Fehr M, Nolte I. Incomplete ossification of the humeral condyle as the cause of lameness in dogs. Vet Comp Orthop Traumatol 2002;15(03):187–194
15 Gabriel P, Pfeil A, Ludewig E, Böttcher P, Oechtering G. Magnetic resonance imaging diagnosis: incomplete ossification of the humeral condyle in a German shepherd dog. J Small Anim Pract 2009;50(02):92–94
16 Robin D, Marcellin-Little DJ. Incomplete ossification of the humeral condyle in two Labrador retrievers. J Small Anim Pract 2001;42(05):231–234

17 Moores AP, Agthe P, Schaafsma IA. Prevalence of incomplete ossification of the humeral condyle and other abnormalities of the elbow in English Springer Spaniels. Vet Comp Orthop Traumatol 2012;25(03):211–216
18 Strohmeier UW, Harris KP. Humeral intracondylar fissures in French bulldogs. Vet Rec 2021;189(11):e504
19 Rørvik AM. Risk factors for humeral condylar fractures in the dog: a retrospective study. J Small Anim Pract 1993;34(06):277–282
20 Hare WC. The age at which the centers of ossification appear roentgenographically in the limb bones of the dog. Am J Vet Res 1961;22:825–835
21 Ticer JW. Radiographic Technique in Small Animal Practice. W.B. Saunders Company; 1975
22 Piola V, Posch B, Radke H, Telintelo G, Herrtage ME. Magnetic resonance imaging features of canine incomplete humeral condyle ossification. Vet Radiol Ultrasound 2012;53(05):560–565
23 Johnson KA. Surgical correction of premature closure of ulnar growth plate. J S Afr Vet Assoc 1978;49(03):255
24 Evans LB. Surgical correction of premature closure of the ulnar growth plate in the dog. J S Afr Vet Assoc 1977;48(04):287–288
25 Loewen KG, Holmberg DL. Surgical management of premature closure of the distal ulnar growth plate in a growing dog. Can Vet J 1982;23(04):113–116
26 Vezzoni A. Ulnar osteotomies in elbow dysplasia: from 4 months of age to adulthood. Paper presented at: 4th World Veterinary Orthopaedic Congress, March 1–8, 2014, Breckenridge, CO
27 Fitzpatrick N, Smith TJ, O'Riordan J, Yeadon R. Treatment of incomplete ossification of the humeral condyle with autogenous bone grafting techniques. Vet Surg 2009;38(02):173–184
28 Garland BW, Dumitru EA, Ororbia A, Oxley B. Spontaneous resolution of a humeral intracondylar fissure in a skeletally immature French Bulldog. VCOTOpen 2023;6:e37–e40
29 Karydas S, Danielski A. Proximal ulnar osteotomy as a treatment for humeral intracondylar fissure in a Shetland Sheepdog. Animals (Basel) 2023;13(03):519
30 Danielski A, Yeadon R. Proximal ulnar osteotomy as a treatment for humeral intracondylar fissure in spaniel breed dogs: preliminary results. Paper presented at: Proceedings of the ESVOT 2022 Congress, September 21–24, 2022, Nice, France