

Restoration of Sensibility to the Injured Thumb

MASOOD H KHAN, M.S., M.S. & D. A. CAMPBELL REID, F.R.C.S.

The United Sheffield Hospitals, Sheffield.

THE importance of adequate sensation over the tactile surface of the thumb cannot be overstated. It is essential for the important pinch grip which enables one to perform fine manipulations. Moberg has repeatedly stressed the need for tactile gnosis, that element of sensory function which permits one to distinguish texture, shape and other details of objects without their being visualised. His picking-up test is based on this faculty and is invaluable in assessing sensation. Where loss of sensation in the thumb cannot be made good by digital nerve suture, an innervated skin flap may be used. Two different techniques for achieving this are presented in this paper and illustrated in their application to two similar injuries.

Case I

K.M. a male aged 23 years was admitted on 21.8.73 with an injury to his left thumb. On examination there was a deep laceration of the thumb extending through the interphalangeal joint. The end appeared viable and some sensation was present. An x-ray (Fig. 1) showed the fracture of the base of the terminal phalanx with disruption of the joint. The wound was debrided and loosely sutured. The hand was elevated. In spite of this the end of the thumb failed to survive and became necrotic. The area of necrosis covered the greater part of the volar aspect of the thumb indicating that the laceration

had extended obliquely on this aspect. The dorsal surface was intact distally to

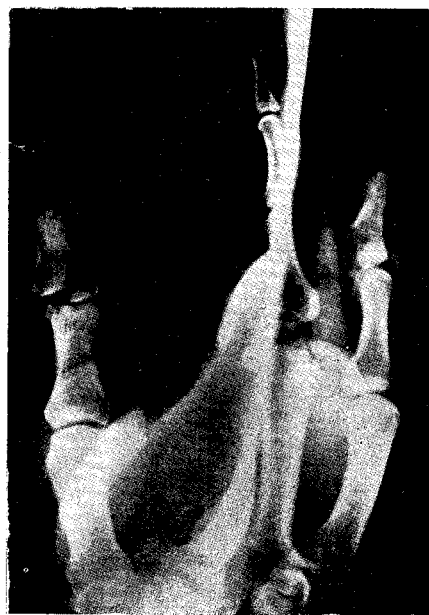


Fig. 1—X-ray -Fracture of the base with disruption of joint interphalangeal joint level. On 9.9.73 the gangrenous portion of the thumb was removed leaving a large volar defect. This was covered by a cross-finger flap from the back of the index metacarpal and proximal phalanx. The radial nerve fibres to this flap were dissected out and transferred into the thumb (Fig. 2). The flap was divided and inset to the thumb on 30.9.73. The patient had good sensation in the flap referred to the dorsal aspect of the index finger, from the time it was transferred. He made excellent progress. He was able to use the thumb well within a few weeks. The flap was

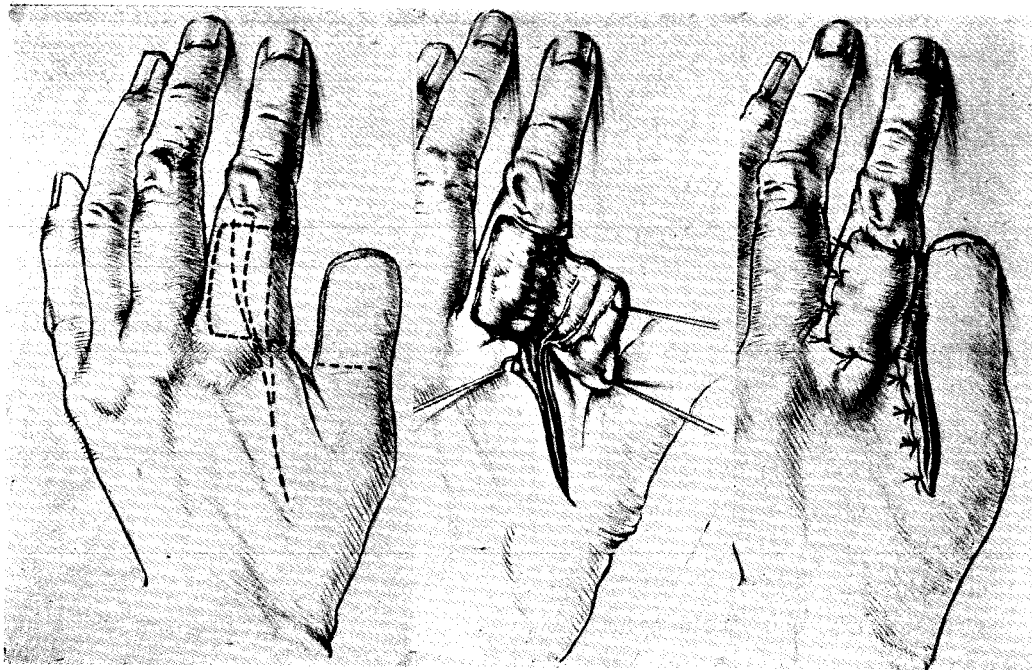


Fig. 2—Cross finger flap with radial nerve fibres

innervated and moist (Fig. 3). The picking-up test was positive and he returned to work-weeks after the injury.

Case II

C.S. a male aged 59 years was ad-

mitted on 4.9.73 having trapped his right thumb at work. On examination there was a deep, almost circumferential laceration around the end of the thumb just distal to the interphalangeal joint. The

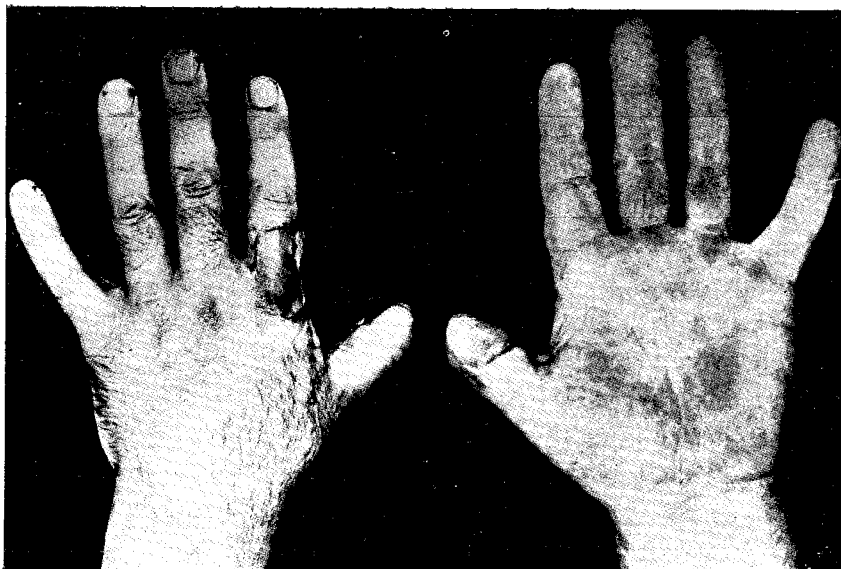


Fig. 3—Post operative innervated flap to thumb

injury had extended right through the terminal phalanx near its base (Fig. 4).

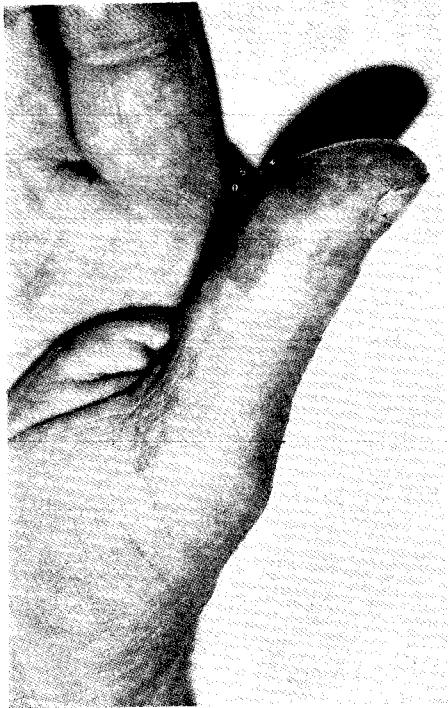

Fig. 4—Healed scar at the terminal phalanx near its base (without sensation)

The end of the thumb appeared viable though only remaining attached by a small pedicle. An x-ray (Fig. 5) showed fracture near T.P. joint. It was sutured back in place loosely and survived completely. On subsequent examination, there was no sensation in the end of the thumb indicating division of both digital nerves. The flexor pollicis longus tendon had also been divided. He was unable to use the thumb owing to the lack of sensation in it. On 23.1.74 a neurovascular island flap was transferred from the ulnar side of the ring finger to the ulnar aspect of the thumb. The ring finger defect was repaired with a full-thickness graft using

the skin removed from the thumb (Fig. 6). The patient made an uneventful recovery and is using his thumb well.

Discussion

Loss of sensation on the volar aspect of the thumb due to division of the digital nerves should be treated by primary nerve suture provided the wound is suitable and other conditions are favourable. An operating microscope is of value in such instances. The injury may be associated with tendon division. The first priority, however, must be suture of the nerves even if it means undertaking a tendon graft later when some sensory recovery has occurred (Reid 1966). Should primary suture not have been performed and the thumb pulp is completely anaesthetic then secondary nerve repair may be considered. This may necessitate the use of nerve grafts if, after resecting the neuroma, such a gap is left that the ends cannot be joined by direct suture. This is really only a feasible proposition in the proximal part of the thumb. At the level of the interphalangeal joint or distal to it, one should consider an alternative method of restoring sensation. This is also required when nerve repair is impossible for any other reason e.g. loss of skin and pulp. It may also be required as a secondary measure following primary surgery where viability of the thumb has been in question. In such cases minimal primary surgery only should be undertaken.

To restore sensation in such cases reconstruction may be by a hetero-digital neurovascular island flap as originally suggested by Moberg (1955) and subsequently developed by Littler (1956, 1961).

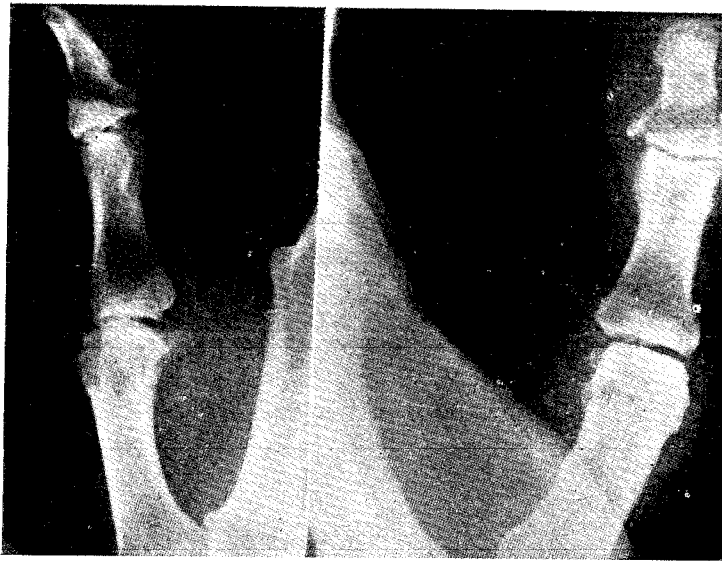


Fig. 5—X-ray showing fracture near T.P. joint

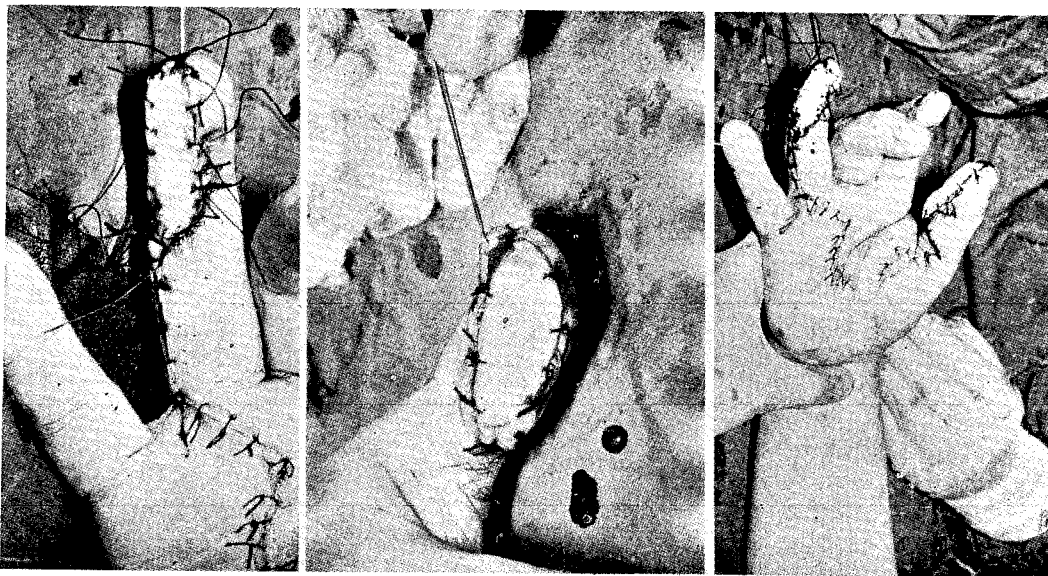


Fig 6—Neuro-vascular island flap to thumb

The flap may be taken from the ulnar side of the ring finger and transferred to the ulnar aspect of the thumb pulp (the surface against which the index finger opposes). The results of this procedure have been reported by Tubiana and Duparc (1961), Reid (1966) and have proved eminently successful.

An alternative method for restoring sensation in thumb reconstruction was suggested by Holeyich (1963) who advocated transferring the branches of the radial nerve from the back of the index finger together with their blood supply. This he did in a thumb reconstructed by a tubed flap.

This was a short thumb and the fibres just reached the end and re-innervated the flap, but only with essential protective sensation. The Nerve pedicle so designed was too short to reach the end of a thumb of normal length and was therefore of little use in restoring sensation to the terminal pulp. The method was extended to include a racket-shaped skin flap which was then transferred to the reconstructed thumb. It was still only possible, even by this means, to re-innervate a short thumb.

This idea has now been taken further by Adamson et. al. (1967) whose method enabled a cross-finger flap from the dorsum of the index finger to be combined with transfer of the intact radial nerve fibres to that flap. The main advantage of this method is that the tactile surface of a finger is not involved.

In those cases where the thumb has been amputated re-attachment by microvascular anastomosis is now becoming a reality (O'Brien et. al. 1973) utilising the techniques pioneered by Buncke (1967) Kleinert and Kasdan (1965) Serafin et. al. (1973) showed that a replanted distal phalanx of a thumb can survive on a repaired arterial pedicle without venous anastomosis.

Summary

Two almost identical thumb injuries with total loss of tactile sensation are presented. In one, sensibility was restored by a hetero-digital neurovascular island flap; in the other by a radial nerve flap.

A brief review of the relevant literature is given.

Our thanks to Mrs. J.D. Marriott for typing the manuscript.

References

1. Adamson, J. E., Horton, C. E. : Sensory Rehabilitation of injured hand. *Plast. and Reconst. Surg.*, 40 : 53, 1967.
2. Buncke, H. and Schutz, N. P. : *Microvascular Surgery*, C. V. Mosby Co., St. Louis, 1967.
3. Daniel R. K. and Taylor G. I. : Distant Transfer of an Island flap by microvascular anastomosis. *Plast. and Reconst. Surg.*, 52 : 111, 1973.
4. Holevich, J. : A new method of restoring sensitivity to the thumb. *J. Bone and Jt. Surg.*, 45 B : 496, 1963.
5. Littler J. W. : *Reconstructive Plastic Surgery*, Edited by Converse, C., W. B. Saunders Company, Philadelphia, 1964. Vol. IV, P, 1638.
6. Mcfarlane R.M. and Stromberg, : Resurfacing of thumb following major skin losses *J. Bone and Jt. Surg.*, 44 A, 1365, 1962.
7. Obrien, B. M., Macleod, A. M. : Clinical reimplantation of digit. *Plastic and Reconst. Surg.*, 52, 490, 1973.
Miller, G. D. H., Newing, R. K.
Hayhurst, J. & Morrison, W. A.
8. Reid, D. A. C. : Recent advances in Plastic and Reconstructive Surgery 19 : 234, 1966.
9. Reid, D. A. C. : Neurovascular Island flap in thumb reconstruction, *Brit. J. Plast. Surg.*, 19 : 234, 1966.