

## A METHOD OF MANAGING ELECTRICAL INJURY AROUND ORAL CAVITY

\*V. Bhattacharya, M.S., M.Ch. \*\*J. K. Sinha, M.S., F.R.C.S.

\*\*\*F. M. Tripathi, M.S., M.Ch.

Electrical burns of the mouth and perioral regions are infrequent. Only a limited number of reports are found in the literature. The purpose of this paper is to illustrate one of the methods for achieving esthetic and functional rehabilitation in a post electric burn disfigurement about the mouth.

### Case Report

A 4 years old boy presented with a defect and ulcer of the lower lip and chin 3 weeks after an electrical burn (Fig. 1). The accident occurred by chewing a domestic 'live' electric wire which was hanging from the wall socket. He was treated conservatively. X-ray of the mandible showed a sequestrum which was removed. Following this the ulcer healed leaving behind deformed lower lip and adjoining area.

Examination before final repair revealed a full thickness loss of right one-third of the lower lip preserving the commissure. The margin of the defect was adherant to the adjacent alveolar process obliterating the gingiolabial sulcus (Fig. 2). The normal mobility of the lip was restricted. With the result, there was not only distortion in the normal outline of the lip but also interference with the normal function and constant drooling of saliva. In addition a transverse hypertrophic scar was traversing underneath the whole of the lower lip to the left side of the chin. The contraction of this band lead to

rolling-out of the normal left two-third of the lip, making it more prominent. It was also interfering with the full opening of the mouth. The lower two central incisors were malarticulated.

### Operative procedure

The scar was completely excised. The rolled-out left two-third of the lip was made free and mobilised. The labial sulcus was deepened by releasing the lip from the alveolar border. The normal lip was advanced to the right and sutured to the defect in layers completing the reconstruction of the lip. The defect recreated following scar excision across the upper part of the chin was covered by a cervical transposition cum rotation flap based on the right side (Fig. 3). The donor area was closed directly.

### Result

Review 6 months following operation showed a good oral sphincter, adequate buccal sulcus with no drooling of saliva. The patient had no difficulty in opening the mouth. The flap had settled down well giving a good esthetic outlook. The donor scar became almost inconspicuous (Fig. 4).

### Discussion

Devis (1959) observed that mouth is most commonly involved in electrical injury occurring in children. We see one or two cases every year in our section. Majority of the victims fall in the infant and toddler group

\*Lecturer

\*\*Head

\*\*\*Reader

Section of Plastic Surgery, Institute of Medical Sciences, Banaras Hindu University, VARANASI

(Schultz, 1952 ; Kazanjian et al., 1954 ; Thomson et al., 1965). The primary reason being the 'live' electrical wire, kept carelessly while children are creeping or playing. This becomes an object of curiosity and because of the inherent tendency the child starts chewing or biting it sustaining the injury.

### **Electrophysical Mechanism**

Opinion as to the exact mechanism of the injury in such cases differs. Some people blame it to arcing (Kazanjian, 1954), while others attribute it to combination of arc and contact (Fleury, 1957 ; Muir, 1958). As the child puts the wire in the mouth, the moist lip or the pooled saliva in the labial sulcus establishes a short circuit between the cord terminations—resulting in formation of the destructive arc. The damage remains restricted mainly to the local tissue (Schultz, 1952). The heat generating from an arc is very high and therefore the delicate tissue about the mouth are destroyed rapidly with serious consequences.

Initial appearance of the wound is disturbing to the parents and the physician. Two most significant facts which should be kept in mind when treating such a case is the critical role of mouth in the esthetic unity of face and the oral function (Monasterio et al., 1980). It is possible to achieve this goal best by replacing the lost tissue by an equivalent flap from the neighbouring structures. The cervical flap used in this case had an obvious advantage of ideal colour match, proper hair growth and unnoticeable donor site.

Lot of controversy persist concerning the timing of surgery in such cases. Advocates of early reconstruction feel that functional sequelae are more if the wound is allowed to heal secondarily. Excessive scar formation results in bad function and esthetic distortion of the soft tissues. Thus much

more flap replacement is required than if the cases are treated at acute stage. According to them better result is obtained with early repair, since less tissue distortion was allowed to occur (Hystop, 1957 ; Muir, 1958 ; Fleury, 1959 ; Monasterio, 1980).

However, majority of the authors advocate conservative approach allowing spontaneous healing before definitive surgery is undertaken (Dale, 1954 ; Lewis, 1950 ; Pearl, 1933 ; Kazanjian, 1954 ; Kragh et al., 1961 ; Schultz, 1952 ; Pitt et al., 1969, etc.). We are also of the view that better results are achieved by delayed plastic repair of the residual deformities. It is felt that if the initial approach is conservative, valuable tissue can be preserved which otherwise may be sacrificed during very early debridement and repair. The degree of initial injury and its progressive nature is difficult to assess in the beginning (Kazanjian, 1954). With the formation of the slough sufficient debridement is advocated to promote early stimulation of healthy granulation tissue. Once the wound heals completely, the residual deformity should be reconstructed by an appropriate method using a local flap.

During their follow up these patients should be carefully watched for any tightness of the lower lip, hypoplasia of the chin and malocclusion resulting in overbite.

### **Summary**

This case report illustrates one of the methods for the management of deformities caused by electrical contact around mouth. The lip was advanced for the reconstruction of oral sphincter. The chin defect was covered by a cervical transposition cum rotation flap.

### **Acknowledgement**

We want to thank Mr. S. N. Lahiri for drawing the diagram.

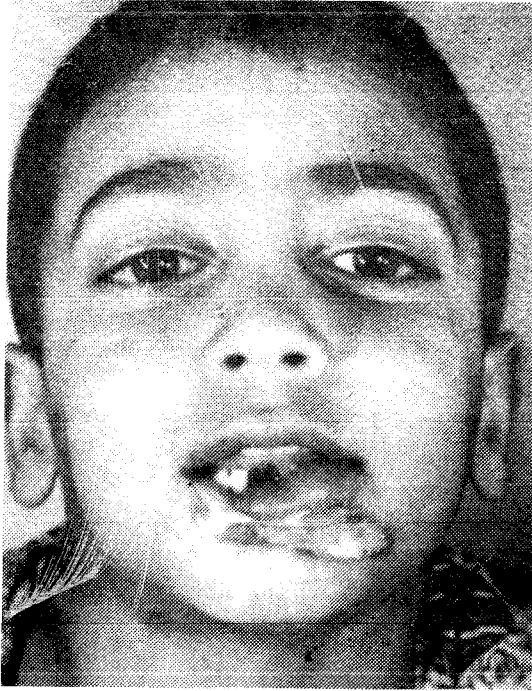

Fig. 1. The defect after 6 weeks with ulcerated area over the chin, sequestrectomy already done.

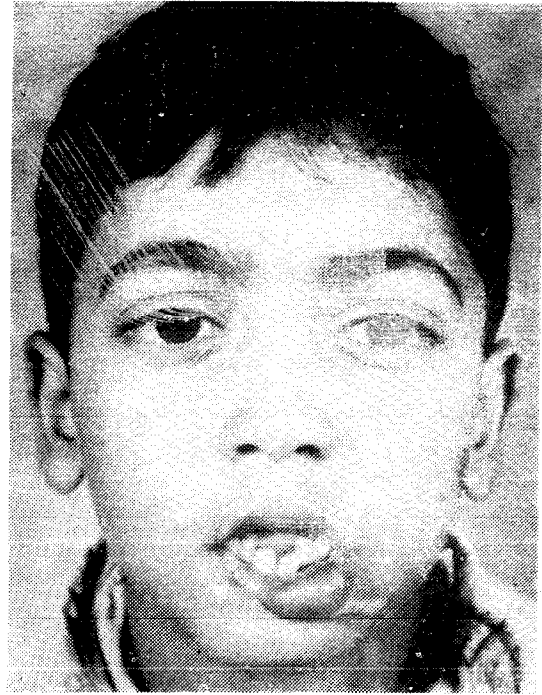

Fig. 2. Residual deformity 6 months following burn.

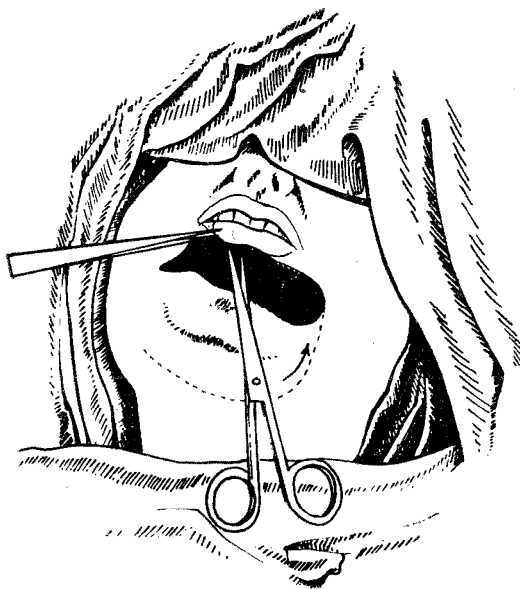


Fig. 3. Diagrammatic representation of the procedure used for the correction of the deformity.

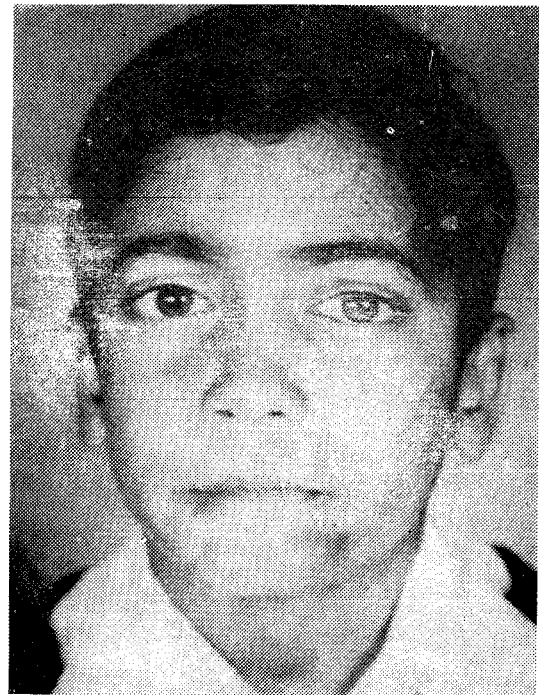


Fig. 4. Post-operative view 6 months later showing acceptable esthetic result.

## REFERENCES

1. Dale, R. H. ; Electrical Accidents. Brit. J. Plast. Surg., 7 : 44, 1954.
  2. Davis, M. R. ; Burns caused by Electricity. Brit. J. Plast. Surg., 11 : 288, 1959.
  3. Fleurey, A. F. ; Electrical Burns of the Lips : A Modified plan of Treatment. Am. Surgeon, 25 : 328, 1959.
  4. Hyslop, V. B. ; Treatment of Electric Burns of the Lips. Plast. Reconst. Surg., 20 : 315, 1957.
  5. Kazanjian, V. H. and Roopenian, A. ; The treatment of Lip Deformaties Resulting from Electric Burns. Am. J. Surg., 88 : 884, 1954.
  6. Kragh, L. V. and Erich, J. B. ; Treatment of Severe Electric Injuries. Am. J. Surg., 101 : 419, 1961.
  7. Lewis, G. K. ; Bruns from Electricity. Ann. Surg., 131 : 80, 1950.
  8. Marchae, D. ; Electrical Burns of the Lip and Mouth. Plast. Reconst. Surg., 46 : 85, 1970.
  9. Monasterio, F. O. and Factor, R. : Early definitive treatment of Electric Burns of the Mouth. Plast. Reconst. Surg., 65 : 169, 1980.
  10. Muir, I. F. K. ; The treatment of Electrical Burn. Brit. J. Plast. Surg., 131 : 80, 1950.
  11. Pearl, F. L. ; Electric Shock. Arch. Surg., 27 : 227, 1933.
  12. Schultz, L. W. ; Burns of the Mouth. Am. J. Surg., 83 : 619, 1952.
  13. Schultz, L. W. and Vazironi, S. J. ; Electrical Burns of the Mouth. Am. J. Surg., 92, 98 : 1959.
  14. Thomson, J. H., Juckes, A. W. and Farmer, A. W. ; Electric Burns of the Mouth in children. Plast. Reconst. Surg., 35 : 466, 1965.
-