

## Original Article

# Reliance on double pedicle TRAM flap technique in breast reconstruction based on mammographic evidence

Fuat Yüksel, Emir Silit, Bahattin Çeliköz

Plastic and Reconstructive Surgery and Radiology, Gülhane Military Medical Academy, Haydarpaşa Hospital, İstanbul-Türkiye.

**Address for correspondence:** Plastic and Reconstructive Surgery and Radiology, Gülhane Military Medical Academy, Haydarpaşa Hospital, İstanbul-Türkiye.

### ABSTRACT

Breast reconstruction is now a part of the overall treatment of breast cancer. Its main drawback is rather the suspicion to conceal any probable recurrence. Fat necrosis is a particularly important finding because it can be mistaken for a local recurrence. Alternatively, local recurrences may be dismissed as areas of fat necrosis. Fat necrosis is a relatively minor complication of TRAM flap breast reconstruction but one that can induce anxiety, expense, and inconvenience for patients and concerns about tumor recurrence. The techniques selected for reconstruction must carry the least risks for these awful complications.

15 breast cancer cases were treated in our center by using Bostwick's principles. These include double-pedicle technique in cases with one or two risk factors and added vascular delay two weeks prior to this procedure in cases with more risk factors.

During the follow up period, neither the patients nor her physicians experienced any nodules in their treatment sites clinically. One case is the only exception that she felt hardness but it softened. Mammographically, no images of fat necrosis were observed in any of the cases.

In contrary to other studies reporting no advantages of double pedicle technique to lessen the risk for fat necrosis, we observed fat necrosis only in one of 15 cases. This may be because both sides of the flap are supplied axially and delay procedures are added in high risk patients.

### KEY WORDS

Tram Flap, double Pedicle, Mammography

### INTRODUCTION

**B**reast cancer is the second most common cancer among women and the second leading cause of death secondary to cancer.<sup>1</sup> Techniques, that are used in treatment of this disease, have evolved through the years to eradicate the tumor cells completely while restoring the patients' pre-disease

state. Although it was proved that breast conserving surgery was a reliable option, it has many drawbacks and most patients prefer mastectomy accompanied with breast reconstruction. The main concern about breast reconstruction is suspicion for concealing any probable recurrences. Mastectomy removes most (>95%) breast cells at risk but does not remove all breast cells at risk.<sup>2</sup>

In cancer patients, prosthetic implant reconstruction or autologous reconstruction does not adversely affect survival. Furthermore, early breast reconstruction may improve the patient's psychological well-being. Although mastectomy is generally believed to be a definitive procedure, local recurrence in the chest wall or in the reconstructed breast does infrequently occur. Chest-wall recurrence after mastectomy is reported in 0.2%-1% of women per year.<sup>3</sup> Recurrent local disease following mastectomy and reconstruction is similar to local recurrence following mastectomy alone. Singletary<sup>4</sup> reported a 4.2% recurrence rate in 95 patients with TRAM reconstructions who were followed up for more than 4 years. Kroll et al<sup>16</sup> noted a 6.7% TRAM recurrence rate at 5.6 years in 104 patients treated with skin-sparing mastectomy and reconstruction. Overall, an annual recurrence rate of 1%-2% has been reported for T1 and T2 tumors during the first 5 years.

One problem that is unique to the use of autologous tissue in breast reconstruction, however, is fat necrosis. Fat necrosis is defined as the formation of a small firm area (or areas) of scar tissue in the periphery of a flap caused by ischemic necrosis of subcutaneous fat in the absence of necrosis of overlying flap skin. Fat necrosis usually resolves spontaneously over several months, but occasionally it becomes infected and requires drainage and/or resection. In addition, fat necrosis can lead to concerns about possible tumor recurrence and may require needle biopsy or even excisional biopsy, causing patient anxiety, expense and inconvenience.<sup>5</sup>

Since autologous tissue breast reconstruction offers a great emotional support to patients, partial or total loss of the flaps is a great disaster for those, who have already been sensitized and psychologically labile because of breast cancer. Patients with flap loss during attempted reconstruction of their tissue deficits from other causes on different sites may tolerate these complications. But, breast cancer victim may not accept this because she expects a breast similar to its original state. Hence, many surgeons have attempted to augment the blood supply to the flap for salvaging the ischemic parts. Augmenting blood supply to the ischemic parts of a TRAM flap in the acute phase may

salvage the flap and the flap organizes in the recipient bed. If this supply is at the threshold level, fat necrosis may ensue at the end, which causes great concern to both the surgeon and the patients. Hence, every breast surgeon has been trying to perform reliable methods to treat these patients without further complications and concerns.

In search for the most reliable approach for breast reconstruction, we performed many of the techniques reported before with variable results. Finally, our patients and we were satisfied with Bostwick's principles.<sup>6</sup> These principles include:<sup>7</sup>

1. Unipedicle TRAM flap in ideal cases with no risk factors and limited tissue need,
2. Double-pedicle technique in low and intermediate risk patients,
3. Vascular delay preceding double-pedicle technique in high-risk group.

We followed up our patients treated in this way both with clinical and mammographical evaluation for probable recurrence or fat necrosis for more than 18 months and present our results to show the reliability of the above principles.

## PATIENTS, METHODS AND RESULTS

Breast reconstructions based on Bostwick's principles were performed in 15 consecutive cases in our department between the years 2000 and 2003. 6 cases were immediate reconstruction during skin sparing mastectomy and the rest were delayed procedures performed at least two years after mastectomy. All surgical procedures were performed by the same surgeon. 11 patients had 1 or 2 risk factors and 4 had more. Double-pedicle technique was used in the former and vascular delay preceding double-pedicle technique was used in the latter. (Table I). Four of the immediately reconstructed group (Patient No: 7,8,13,14) had both chemotherapy and radiotherapy following surgery. This radiation therapy consisted of a single daily treatment 5 days a week for 5 to 6 weeks. A total radiation dose of about 5000 cGy was delivered to the reconstructed breast regions.

**Table 1: Treatment status for patients studied**

Case No.	Age	Stage of breast cancer	Reconstruction Immediate&delayed	Technique	Risk Factors	Complications
1	48	III	delayed	double pedicle +vascular delay	smoking, obesity, radiation	-
2	52	III	delayed	double pedicle	radiation, obesity	-
3	62	II	delayed	double pedicle	post-menopausal	-
4	32	II	immediate	double pedicle	much tissue need Partial necrosis at the breast skin	-
5	54	I	delayed	double pedicle +vascular delay	smoking, obesity, post-menopausal	-
6	64	II	delayed	double pedicle	post-menopausal	-
7	42	II	immediate	double pedicle	obesity	-
8	38	I	immediate	double pedicle	smoking	-
9	51	III	delayed	double pedicle +vascular delay	smoking, radiation Skin loss at obesity lower abd. flap site	-
10	62	III	delayed	double pedicle +vascular delay	obesity, radiation post-menopausal	-
11	58	III	delayed	double pedicle	radiation, post-menopausal	-
12	38	II	delayed	double pedicle	smoking	-
13	42	II	immediate	double pedicle	obesity	-
14	52	II	immediate	double pedicle	post-menopausal	-
15	56	I	immediate	double pedicle	post-menopausal fat necr.	-

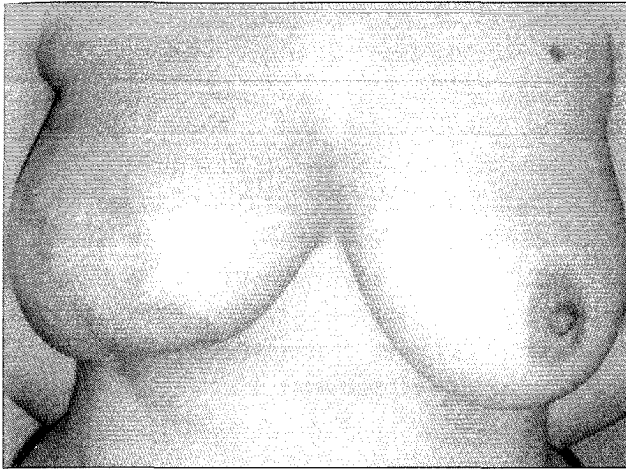
The patients were followed up for 18-27 months after surgery. They were examined physically by the breast team (including a general surgeon, a plastic surgeon, an oncologist and a radiologist) at three month-intervals and mammographical views were taken at six month-intervals. All mammograms had been prospectively assessed by using the American College of Radiology Breast Imaging Reporting and Data System (BI-RADS):<sup>8</sup> category 1 negative; 2 benign; 3 probably benign; 4 suspicious and 5 highly suggestive of a malignancy.

Following these principles, no vascular compromises, arterial or venous, were observed during or after the operations even at the most distal part on the TRAM flaps. Neither one of the physicians palpated nor any patients felt any nodules in their flaps during the follow-up period even following radiation therapy. The only exception was the patient No. 15 who felt hardness on the upper pole of her flap on the 6th month following surgery. She had not got any adjuvant therapy and this hardness could not be visualized mammographically and it softened thereafter.

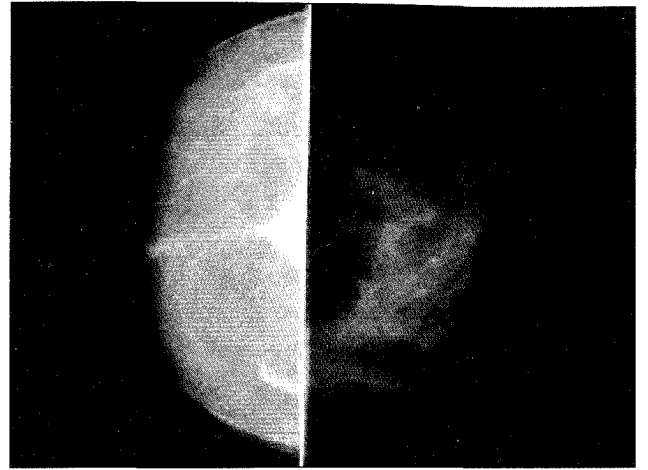
Mammographic findings of all cases include the vascular pedicle, surgical clips, and surgical scars which produce radiopaque lines in predictable locations. The reconstructed breast had a homogeneous, fatty nature, with few vascular and connective tissue opacities and an absence of ductal structures or ligaments. No traces of any suspicious lesion supposing probable fat necrosis or recurrence were observed on serial mammograms of the patients. All of them were Category I according to BI-RADS (Figure 1, 2, 3).

**DISCUSSION**

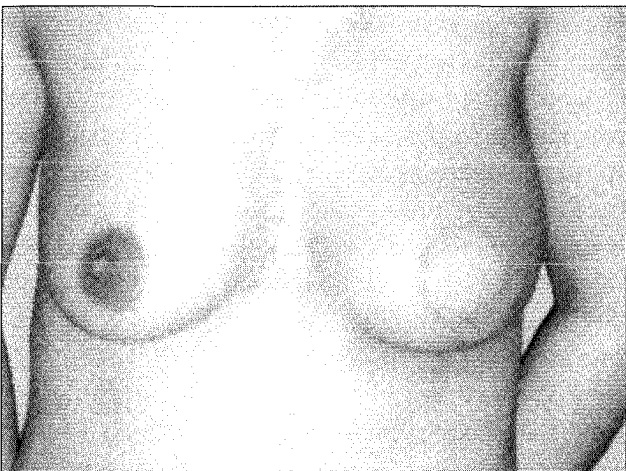
Reconstruction with TRAM flaps has not been shown to affect survival or local recurrence adversely<sup>9</sup>. Recurrent breast cancer following reconstruction, although uncommon, has been reported with 4%-11% of patients developing recurrence in the TRAM-reconstructed breast, most within the first 5 years. Annual incidence of 1% has been reported. Annual local recurrence rates following mastectomy without reconstruction range from 0.2% to 1%<sup>12</sup>. Since any nodules or hardness in reconstructed breast must warn



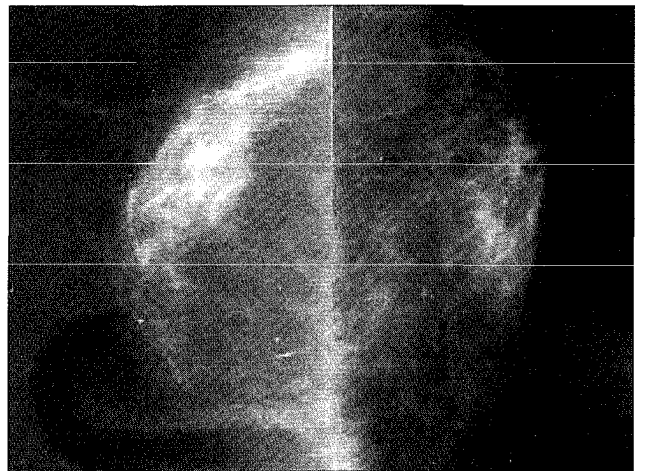
**Figure 1a:** Post operative 18th month view of patient No: 4 whose right breast reconstructed immediately. She had both radiation therapy and chemotherapy. The partial skin loss of spared breast skin had been skin grafted.



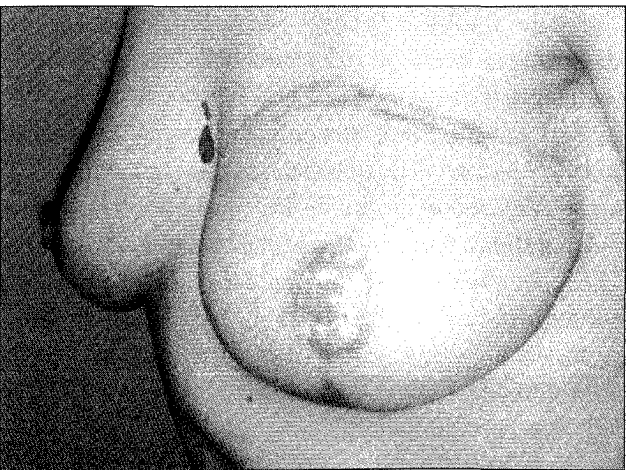
**Figure 1b:** Craniocaudal mammogram of the breasts



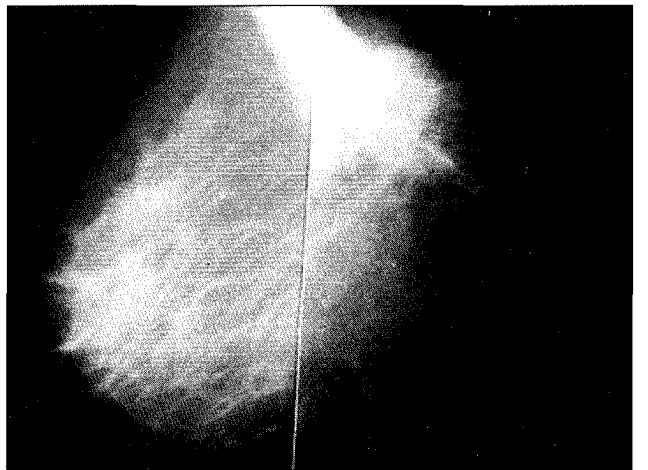
**Figure 2a:** Post operative 18th month view of patient No: 15 whose left breast reconstructed immediately. She had both radiation therapy and chemotherapy and a radiation burn occurred in the sternal area.



**Figure 2b:** Mediolateral mammogram of the breasts.



**Figure 3a:** Post operative 20th month view of patient No: 12 whose left breast reconstructed two years after mastectomy.



**Figure 3b:** Mediolateral mammogram of the breasts.

the surgeons for probable recurrence, every member of the team must be careful for any changes developed in the tissues. The differential diagnosis of such changes after TRAM flap reconstruction includes fat necrosis, scar tissue, edema, fibrocystic disease, seroma, hematoma, suture or dermal calcifications, abscess and in particular, new or recurrent breast cancer.<sup>10</sup>

Fat necrosis is a relatively minor complication of TRAM flap breast reconstruction but one that can induce anxiety, expense, and inconvenience for patients and concerns about tumor recurrence by the patient's oncologist. Although fat necrosis usually softens and clinically disappears with time, it sometimes becomes infected and may require drainage or even excision. For these reasons, it is desirable to minimize the incidence of fat necrosis.<sup>5</sup>

Fat necrosis is a particularly important finding because it can be mistaken for a local recurrence. Alternatively, local recurrences may be dismissed as areas of fat necrosis. Fat necrosis is defined as the formation of a small, firm area of scar tissue usually in the flap periphery that may be secondary to ischemic necrosis of subcutaneous tissue without necrosis of the overlying skin.<sup>10</sup> It occurs postoperatively in approximately 30% of all TRAM flaps.<sup>5</sup> On a mammogram this may appear as an area of increased density with or without calcifications, a nodular density, or an area of lucency.

The diagnosis of fat necrosis is usually a clinical one, made by palpation of a nodule of deep subcutaneous scar tissue in the periphery of the flap where the blood supply would be expected to be the least robust. This diagnosis is necessarily subjective and depends somewhat on the examiner's diligence. Fat necrosis can also be detected mammographically when calcifications were found in the reconstructed breast.<sup>11,12</sup>

Surveillance of the TRAM-reconstructed breast for cancer detection often has been performed with regular clinical breast examination, although some sites routinely perform mammography as well. Those who use clinical examination alone believe that physical

examination allows early detection and note the paucity of studies in which the efficacy of mammographic screening of TRAM recurrence is assessed.<sup>13,14</sup>

Mammography of the reconstructed breast is not performed routinely because of the presumed low yield of detecting occult primary or recurrent breast cancer. However, the presence of a mass on breast physical examination and the evaluation of breast implant integrity in the reconstructed breast are indications for mammography.<sup>13</sup>

Normal mammographic findings include the vascular pedicle, surgical clips, and surgical scars, which produce radiopaque lines in predictable locations. Mammography has been used as a tool to aid in the distinction between fat necrosis and cancer. However, it has been noted that there is a spectrum of mammographic features of fat necrosis which include spiculated densities indistinguishable from carcinoma; localized thickening and deformity of the skin; branching, rodlike or angular microcalcifications similar to those found in carcinoma; and single or multiple benign-appearing lipid filled cysts with or without calcified walls.<sup>10,13</sup>

Until the effect of imaging the reconstructed breast on patient survival is known, physical examination of the reconstructed breast will continue to be the method of choice for early detection of cancer recurrence in the reconstructed breast.<sup>13,15</sup>

Because mammography enables detection of nonpalpable recurrence at a smaller size than does clinical examination, screening patients with TRAM reconstruction after mastectomy for cancer may be reasonable. Screening may be especially relevant in those patients who have undergone mastectomy and TRAM flap reconstruction for early stage carcinoma without metastatic disease.<sup>14</sup>

Although partial flap necrosis in the immediate post-operative period is very bothering for both surgeons and patients, it can be managed by secondary intentions without any fear for prognosis of cancer.

On the other hand, localized hardness developed in the reconstructed breast is much more bothering because this may be the evidence for recurrence, that is grave prognosis of the cancer. Hence, a breast surgeon dealing with breast reconstruction should be familiar with these developments and should try to find out and perform the most reliable techniques, so that, he must feel confident with the late results. As reported before, many surgeons introduced new techniques to augment the vascular supply to the TRAM flaps. Among them, the most popular ones are double pedicle technique, vascular delay, super-charged or super-drained flaps or free flap applications.<sup>16</sup>

Some claimed that the advantage of the free TRAM flap is, compared with the conventional TRAM flap, having a better flap blood supply and therefore a lower incidence of partial flap loss. In theory, this increased blood supply should also lead to a lower incidence of fat necrosis, an advantage that has never been adequately documented.<sup>17,18</sup>

Interestingly, in a significant study, the incidence of clinical fat necrosis was higher in the double-pedicled conventional TRAM flaps than it was in the unipedicled conventional flaps. The authors explained that by the fact, double-pedicled flaps were used primarily in higher-risk patients, especially those who smoked cigarettes, during the time before free TRAM flaps were widely used at their institution.<sup>5</sup>

In our current study, we do not compare the results between various techniques. The numbers of our procedures performed for each technique is limited. Hence, we can not declare any statistical significance. Here, we only present the results of our recent cases treated by using Boswick's principles, that is, "double pedicle" technique. In that view, we do not agree with the report,<sup>5</sup> stating high incidence of fat neurosis for double pedicle technique. We observed fat necrosis only in one of the 15 cases. All the reconstructed breasts were quite soft with the exception of that case, who felt hardness in the beginning but softened later.

When a single-pedicle transverse rectus abdominis myocutaneous technique is used, the distal half of the

contralateral skin hemiellipse is at higher risk of developing flap necrosis. In fact, recent studies have shown that the entire contralateral skin hemiellipse is poorly random in nature. This concern has prompted some surgeons to intentionally discard random portions of the flap, especially in patients with risk factors including active cigarette smoking, obesity 25% above ideal body weight, history of breast or chest wall radiation, older age and surgical scars of the abdominal donor site.<sup>6,19</sup>

Axial vessels branching from the direct periumbilical rectus abdominis muscular perforators nourish the lateral extensions of the TRAM flap that are not directly over the rectus abdominis muscle. Also, there is a vascular network present primarily at the level of the subdermal plexus across the midline of the abdomen providing flow to the skin on the contralateral side. In unilateral TRAM flap elevation, the contralateral half of the flap is dependent of this subdermal plexus across the midline. Radiation, obesity, vasoconstriction or any disorders affecting the microcirculation may affect the circulation of this contralateral tissue. Hence, if a surgeon has suspicion about this cross-circulation and desires a reliable method, then he must prefer techniques offering direct blood supply to both sides of TRAM flaps.<sup>17</sup> In double pedicle technique, there is no zone IV, only I and III present and offers direct (axial) blood supply to both sites of the flap. In fact, zone IIIs can also be discarded if tissue need is limited.

Although many surgeons prefer free TRAM flap application in the recent time, it also carries the additional risk of total flap loss. The complications rates reported for the free TRAM flap range from 2% to 4% fat necrosis and 5% to 8% total flap loss.<sup>4,6,12</sup> In fact, the contralateral random portion of the flap (zone 4) may be compromised and lead to fat necrosis or require excision of a segment of poorly vascularized tissue.

The advantage of the delayed TRAM flap is the increase in blood supply and decrease in venous congestion observed clinically during and after surgery. Surgical delay appears to increase the nutritive blood flow based on the capture of adjacent vascular territories due to dilatation of choke vessels. Dilatation of the draining

venous system following delay creates incompetent valves resulting in venous regurgitation and increased venous return. Performing the delay procedure 2 weeks prior to the definitive breast reconstruction was recommended.<sup>20</sup> Doppler examinations of the superior epigastric vessels performed prior to and 1 week following the delay procedure revealed significant increase in vessel diameter and flow.

Free TRAM procedure is not our choice of surgery in breast surgery. We believe that breast cancer victims may tolerate partial loss that can happen with pedicled flaps but not the disaster of total loss during free flap procedure as well as late fat necrosis at all. We think that we do not have the right for risking our patients for both reasons and use free transfers only when absolute indications are present. Otherwise, we prefer double-pedicle technique in cases with one or two risk factors and added vascular delay two weeks prior to this procedure in cases with more risk factors. In this way, we can reconstruct the breasts with tissues having vascular supply axial in nature and we feel confident for the following management of the patients.

## REFERENCES

1. Coleman J III, Bostwick J III: Breast Cancer. In *Plast and Reconstr breast surg*, Bostwick J III (ed). Quality Medical Publishing, St. Louis, 2000;663.
2. Eidelman Y, Liebling RW, Buchbinder S, et al. Mammography in the evaluation of masses in breasts reconstructed with TRAM flaps. *Ann Plast Surg* 1998;41:229.
3. Harris J, Morrow M. Treatment of early stage breast cancer. In Harris J, Lippman M, Morrow M, Hellman S, eds. *Diseases of the breast*. Philadelphia, Pa: Lippincott-Raven, 1996;487-547.
4. Singletary SE. Skin-sparing mastectomy with immediate breast reconstruction: the MD. Anderson Cancer Center experience. *Ann Surg Oncol* 1996;3:411.
5. Kroll SS, Gherardini G, Martin JE, et al. Fat necrosis in free and pedicled flaps. *Plast Reconstr Surg* 1998;102:1502.
6. Yüksel F, Çeliköz B. Double-pedicle Tram flap breast reconstruction: Following Bostwick's principles. *Aesth Plast Surg* 2002;26:444.
7. Bostwick J III: *Abdominal flap reconstruction*. Plast and Reconstr breast surg. Quality Medical Publishing, St. Louis, 2000;981.
8. American College of Radiology. *Breast imaging reporting and data system*. 3rd ed. Reston, Va: American College of Radiology, 1998.
9. Noone RB, Frazier TG, Noone GC, et al. Recurrence of breast carcinoma following immediate reconstruction: a 13-year review. *Plast Reconstr Surg* 1994;93:96.
10. Shaikh N, LaTrenta G, Swistel A, et al. Detection of recurrent breast cancer after TRAM flap reconstruction. *Ann Plast Surg* 2001;47:602.
11. Holmes FA, Singletary ES, Kroll SS, Holbert JM, et al. Fat necrosis in an autogenously reconstructed breast mimicking recurrent carcinoma at mammography. *Breast Dis* 1988;1:211.
12. Hogge JP, Robinson RE, Magnant CM, Zuurbier RA. The mammographic spectrum of fat necrosis of the breast. *Radiographics* 1995;15:1347.
13. Leibman AJ, Styblo TM, Bostwick J. III. Mammography of the postreconstruction breast. *Plast Reconstr Surg* 1997;99:68.
14. Helvie MA, Bailey JE, Roubidoux MA, et al. Mammographic screening of TRAM flap breast reconstructions for detection of nonpalpable recurrent cancer. *Radiology* 2002;224:211.
15. Mendelson, EB. Evaluation of the Postoperative Breast. In L. W. Bassett (Ed.), *Radiologic Clinics of North America*, Vol. 30. Philadelphia: Saunders, 1992:107-38.
16. Kroll SS, Schusterman MA, Tadjalli HE, Singletary SE, Ames C. Risk of recurrence after treatment of early breast cancer with skin-sparing mastectomy. *Ann Surg Oncol* 1997;4:193.
17. Schusterman MA, Kroll SS, Miller MJ, et al. The free TRAM flap for breast reconstruction: A single center's experience with 211 consecutive cases. *Ann Plast Surg* 1994;32:234.
18. Boyd JB, Taylor GI, Corlett R. The vascular territories of the superior epigastric and the deep inferior epigastric systems. *Plast Reconstr Surg* 1984;73:1.
19. Bunkis J, Walton RL, Mathes S, et al. Experience with the transverse lower rectus abdominis operation for breast reconstruction. *Plast Reconstr Surg* 1983;72:819.
20. Codner MA, Bostwick J III: The delayed TRAM flap. *Clin Plast Surg* 1998;25:183.