

## Brief Communication

# Safe method for release of severe post burn neck contracture under tumescent local anaesthesia and ketamine

**Pawan Agarwal**

Plastic Surgery Unit, Department of Surgery, N.S.C.B. Government Medical College, Jabalpur - 482003, India.

**Address for correspondence:** Dr Pawan Agarwal, 292/293 Napier town, Jabalpur - 482001, India. E-mail: drpawanagarwal@yahoo.com

### ABSTRACT

Severe post burn neck contracture results in difficult intubation, which can be life threatening and can result in multiple serious complications and sequels. Thirty patients with age ranging from 12 to 50 years were operated under local tumescent anesthesia supplemented with intravenous ketamine for release of post burn neck contracture and split skin grafted. This technique obviates the need for endotracheal intubation. There were no complications attributed to this anesthesia technique. There was no graft loss and blood loss was minimal.

### KEY WORDS

Neck contracture, Tumescent local anesthesia

### INTRODUCTION

Severe post burn neck contracture represents a challenge to the plastic surgeon as well as to the anesthesiologist. The challenge lies in the restoration of the form and function of this region with safety. The traction forces caused by burn scar contracture may pull and cause insufficient neck extension, incomplete oral occlusion, cicatricial ectropion, and tracheal alterations affecting respiration. This results in difficult intubation that can be life threatening and can result in multiple serious complications and sequels.<sup>1,2</sup> To circumvent these complications contracture is released initially under local anesthesia to allow sufficient neck extension and then the anesthesiologist intubates the patient. Then

the surgery is continued under general anaesthesia. This process apart from being inconvenient causes contamination of the surgical field as well. In this study endotracheal intubation was avoided and the whole procedure was performed under local tumescent anaesthesia (TLA) supplemented with intravenous ketamine.

### MATERIAL AND METHODS

Thirty patients of severe post burn neck contracture with age ranging from 12 to 50 years were operated under local tumescent anesthesia supplemented with intravenous ketamine. Weight of the patients ranged from 22 kg to 80 kg. All the operative procedures were done under the supervision of qualified

anesthesiologists. The patients were premedicated the night before surgery with Tab. Diazepam (5 mg) and just before surgery with intravenous diazepam 0.1mg/kg body weight, intramuscular pentazocine 0.6 mg/kg and intravenous glycopyrrolate 0.004mg/kg. After this patient's neck and thighs were prepared and draped. Skin incision was marked and tumescent local anesthesia infiltrated along with the incision line and in to the surrounding areas. Volume of tumescent local anesthesia ranged from 70 ml to 200 ml depending upon the extent of contracture. Tumescent local anesthesia consisted of 0.4% lidocaine, 1:500,000 epinephrine with sodium bicarbonate and Inj. Hylase. It is prepared by mixing 30 cc of 2% lidocaine, 20 cc of sodium bicarbonate, one ampoule of epinephrine and one ampoule of Hylase in 450 cc of Ringer lactate solution. After waiting for 20 minutes the neck contracture was released and hemostasis achieved, and amount of split skin graft required was estimated. An anesthetic dose of intravenous ketamine 1-2 mg/kg was given and split skin graft was harvested. This skin graft was sutured over the raw area. A well-fitted soft neck collar was given over the tie-over dressing. If required an analgesic dose of ketamine 0.5 mg/kg was given. For children the technique was modified and anaesthetic dose of ketamine (0.5-1mg/Kg body weight) was given in the beginning and surgery carried out under ketamine and tumescent local anesthesia. All patients were allowed to take oral feed after 6 hours;

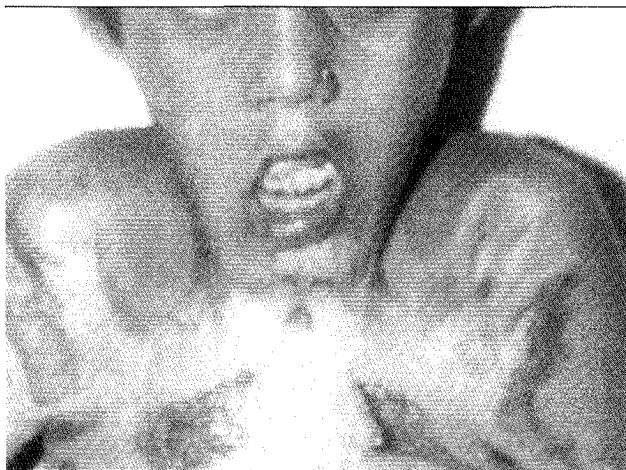

Figure 1: Preoperative photograph showing post burn neck contracture

nasogastric tube feeding was not required. Postoperatively, patients were kept in supine position with neck hyper extended by providing pillows under the shoulder.

## RESULTS

None of the all thirty patients operated with this technique showed any complications attributed to the anesthesia technique. There was no graft loss and with tumescent local anesthesia blood loss was minimal (Average blood loss 50 ml). Total operative time ranged from 60 to 90 minutes. Post-operative complications included a hematoma and two seromas, which were punctured to drain it.

## DISCUSSION

Severe post burn neck contracture poses difficult problems to the anesthesiologist. Usual technique includes blind naso-tracheal intubation or release of contracture under local anaesthesia followed by intubation of the patient. Both techniques have their own problems. Other methods include use of fibre-optic bronchoscope and laryngeal mask but these equipments are expensive and may not be available in most places.<sup>3</sup> Retrograde intubation is not possible because of presence of scar in the anterior aspect of neck. (Figure 1, 3).

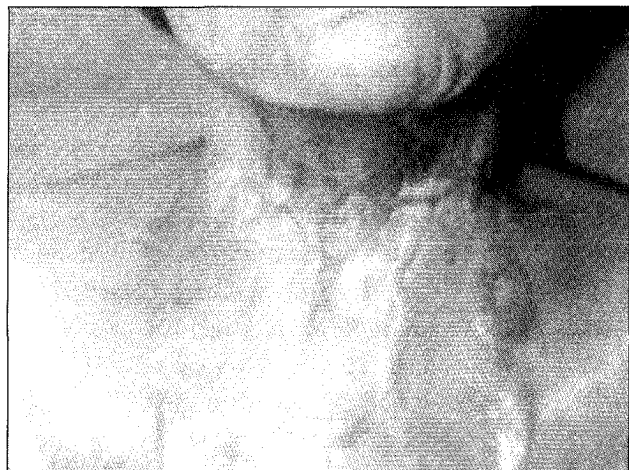


Figure 2: Postoperative results after 1 month showing adequate neck extension and 100% skin graft take

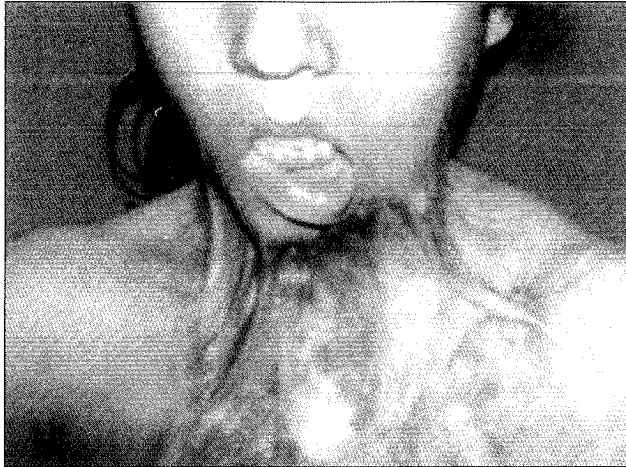


Figure 3: Post burn neck contracture with ectropion lower lip in 17 years old girl

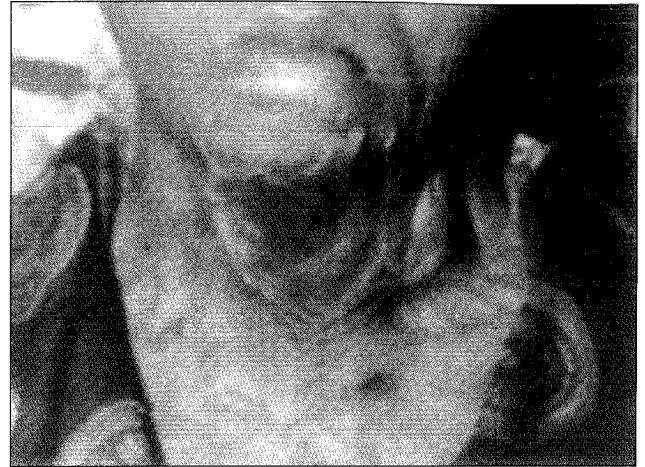

Figure 4: Postoperative results after 2 months

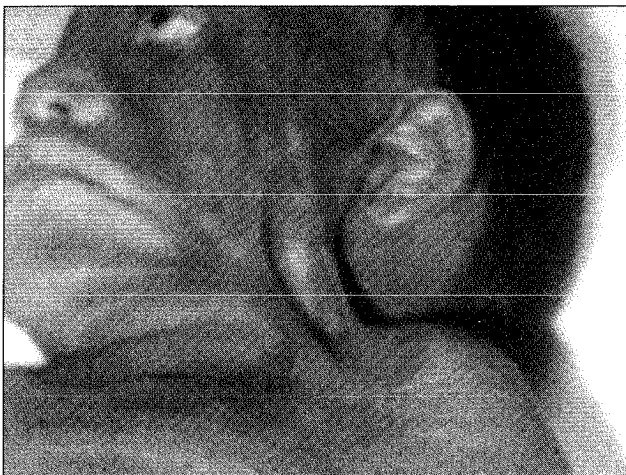


Figure 5: Post burn neck contracture in 12 years old boy involving the angle of mouth, lower eyelid and extending up to left shoulder

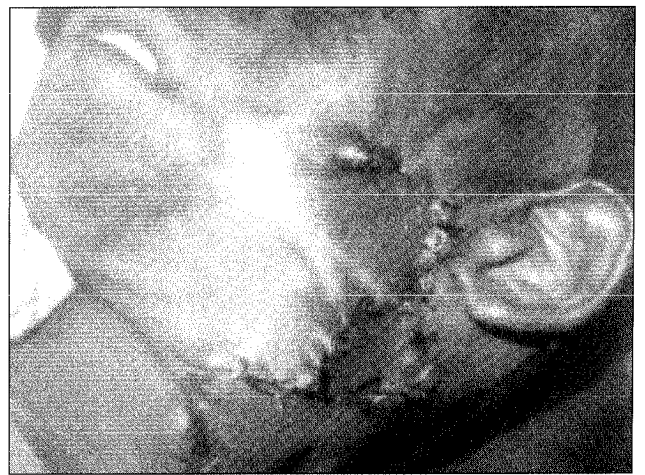


Figure 6: Postoperative results immediately after surgery

We released the neck contracture under tumescent local anesthesia and complete extension was achieved. Skin graft was harvested under anesthetic dose of ketamine. If there was any problem associated with ketamine that could be dealt easily by intubating the patient, as the neck was by this time completely extended. (Figure 2, 4).

In children, ketamine was given right at the beginning of the procedure followed by injection of tumescent local anesthesia and than release of neck contracture and skin grafting was performed. (Figure 5, 6). This method is very safe, as the respiration and swallowing reflex remains intact under ketamine.

Following the infiltration of TLA, peak plasma lidocaine

infiltration. Clinical local anesthesia was apparent for up to 18 hours, obviating the need for postoperative analgesia. Dilution of lidocaine and Epinephrine-induced vasoconstriction diminishes and delays the peak plasma lidocaine concentrations, thereby reducing potential toxicity. A safe upper limit for lidocaine dosage using the tumescent technique is estimated to be 35 mg/kg.<sup>4</sup> Infiltrating a large volume of dilute epinephrine assures diffusion throughout the entire targeted area while avoiding tachycardia and hypertension. The associated vasoconstriction was so complete that there was virtually no blood loss in surgery. Adding epinephrine, however, made the injection more painful because of the acidic sodium metabisulphite that had to be added to prevent epinephrine oxidation.<sup>5</sup> Injection pain could be reduced

by buffering the solution using sodium bicarbonate in a dose of 1 mEq per 10 ml of lidocaine ratio to make solution more physiologic in pH. (7.41).<sup>6</sup>

This technique obviates the need for endo-tracheal intubation. Difficult and traumatic intubation causes exaggerated sympathetic response resulting in tachycardia and hypertension, which in turn results in more bleeding peroperatively and subsequent loss of skin graft. Complications of ketamine includes tongue fall, regurgitation and emergence phenomenon. These can be prevented by putting an airway and giving antisialogogue like atropine or glycopyrrolate. It is important that a qualified anesthesiologist must be present throughout the procedure to monitor the patient.

Advantages of tumescent local anesthesia includes hydro-dissection of the tissues, easy disperseability into the scar tissue, painless injection, good anesthesia, less bleeding during and after surgery and good post operative analgesia in all patients. Only disadvantage of tumescent local anesthesia is a wet surgical field.

We conclude that use of tumescent local anesthesia followed by ketamine for severe post burn neck contracture is a safe, simple and effective method. This technique has good patient compliance and completely obviates the need for difficult endotracheal intubation. Reduced blood loss and reduced skin graft loss are additional benefits of this technique.

## REFERENCES

1. Shiby Ninan, Gupta AK Ramkumar G. A technique in positioning the neck during mentosternal contracture release. *Burns* 2003;29:613-4.
2. Nath S, Erzingatsian K, Simond S. Management of post burn contracture of the neck. *Burns* 1994;20:438-41.
3. Afilalo M, Guttman A, Stern E, Lloyd J, Colacone A, Tselios C et al. Fiber optic intubation in the emergency department: A case series. *J Emerg Med* 1993;11:387-91.
4. Klein JA. Tumescent technique for regional anesthesia permits lidocaine doses of 35mg/kg for liposuction. *Dermatol Surg Oncol* 1990;16:248-63.
5. Lawrence C. Drug management in skin surgery. *Drugs* 1996;52:805-17.
6. Smith SL, Hodge JA, Lawrence N, Badame AJ, Coleman WP. The importance of bicarbonate in large volume anesthetic preparations. Revisiting the tumescent formula. *J Dermatol Surg Oncol* 1992;18:973-5.