

Brief Communication

Circumferential skin defect - Ilizarov technique in plastic surgery

Vrisha Madhuri, Shankar R. Kurpad, Manasseh Nithyananth, Thilak S Jepegnanam, V. T. K. Titus, Prema Dhanraj

Department of Orthopaedics, Christian Medical College and Hospital, India.

Address for correspondence: Dr. Vrisha Madhuri, Professor, Department of Orthopaedics Unit II, CMC Hospital, Vellore - 632 004, India. E-mail: madhuriwalter@cmcvellore.ac.in

ABSTRACT

A young man had an open fracture of the tibia with bone and soft tissue loss in the distal part of the left leg following a crush injury. The circumferential skin defect was successfully treated with controlled lengthening of the distal skin by the Ilizarov technique using nylon wires and skin staples to apply traction. This was combined with limb reconstruction done simultaneously using orthofix external fixator. This case report highlights the use of an orthopaedic technique to provide skin cover in distal leg.

KEY WORDS

Circumferential skin loss, Ilizarov technique, distal leg soft tissue loss, skin elongation, open fracture tibia

INTRODUCTION

Circumferential skin loss may be associated with open fractures of the tibia in high velocity injuries. The classical management of soft tissue defects needs no reiteration. The advent of Ilizarov technique has revolutionized the field of reconstructive surgery.

In the recent literature, reports have appeared which show that slow stretching of skin can be successfully done using interlacing thick nylon sutures or a skin stretching device in order to bring the wound edges together either soon after the injury or later, after skin

release.^{1,2} Ilizarov had described skin lengthening transversely to provide coverage for the tibia by means of controlled sustained tension using Kirschner wires.³ Use of this technique has been made by others to cover defects overlying infected nonunions⁴. Based on the concept of skin elongation described in literature we have modified the technique to apply it for a circumferential skin defect in the distal part of the leg. We report a case with this new technique.

CASE REPORT

History

A 19-year old male student presented to us one week

after sustaining open Grade 3B fracture of both bones of his left leg. He had wound debridement twice elsewhere.

Physical findings

At admission the circumferential loss of skin and soft tissues was measured and found to be 15 cm over the

distal two thirds of the leg, exposing necrotic muscles and 10 cm of devitalized tibia. The distal part of the limb, devoid of soft tissue coverage above the ankle level, was hanging by the posterior neurovascular bundle and flexor digitorum longus. Bone deficiency was present at this site. The posterior tibial artery was palpable, the dorsalis pedis showed retrograde flow and distal to the circumferential skin loss, the limb was

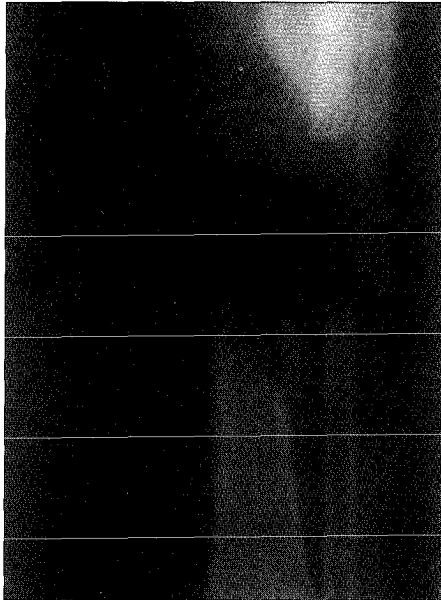


Figure 1: Radiograph at admission showing extent of skeletal disruption

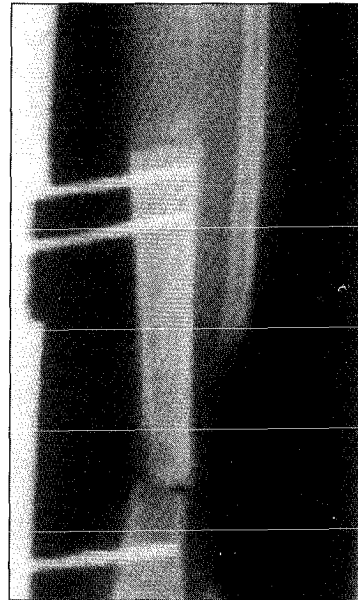


Figure 2: Radiograph after debridement and application of the limb reconstruction system (Orthofix) and collapse of 10 cm of tibia, and distraction osteogenesis at proximal corticotomy site

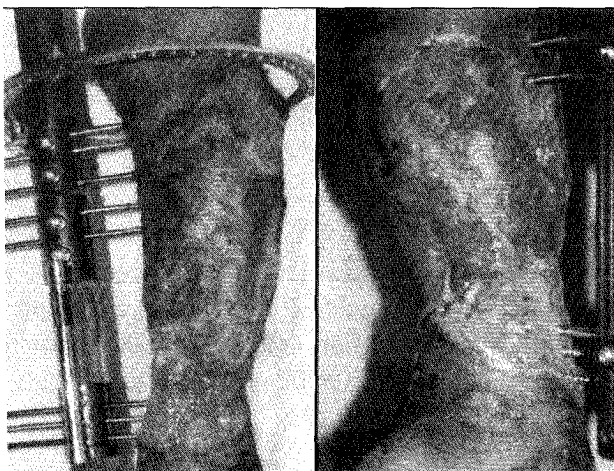


Figure 3: Clinical Photograph, Pre procedure view, showing the extent of in defect




Figure 4: The skin traction apparatus in use

anaesthetic. The radiographs at admission showed segmental bone loss of the tibia. (Figure 1).

Operative technique

The wound was debrided, creating a bony defect of 10 cm. This was primarily collapsed (docked) and a limb reconstruction device (Orthofix) applied, to allow for limb lengthening later. The shortening created by acute docking allowed soft tissue cover of the neurovascular bundle and there was no exposed bone devoid of periosteum. Figure 2 shows the final radiograph at the end of docking and lengthening. After 4 days of debridement, a partial thickness skin graft was applied over the soft tissue that was exposed. This graft showed more than 90% take in the proximal part above

the fracture and 10% take in the distal area where the vascularity was compromised. At this stage (Figure 3), 3 weeks post injury, realizing that recurrent breakdown of skin might occur later, we planned on lengthening the skin from the distal edge. A circumferential skin gap existed varying from 8 to 15 cm with underlying viable granulation.

Technique for skin lengthening

An Iizarov ring was anchored to the proximal most threaded screw of the limb reconstruction system. Skin staples were placed circumferentially, 5 mm from the skin edge, aligned vertically in groups of 2 or 3, one centimeter apart. Thick nylon suture was looped around the groups of staples, passed through the holes of the ring and attached to the posts mounted on threaded rods with square nuts to allow for 0.25 mm. of stretch at a time (Figure 4). No anaesthesia was required. The patient was taught to turn the square nut a quarter turn at a time pulling the skin up 0.25 mm. at a time. Since this was compromised skin, we restricted the skin lengthening to 5 mm. a day, done at intervals several times throughout the day. Such traction was continued for 3 weeks. Figure 5 shows a schematic representation of the skin staple junction and the construct of the traction device.

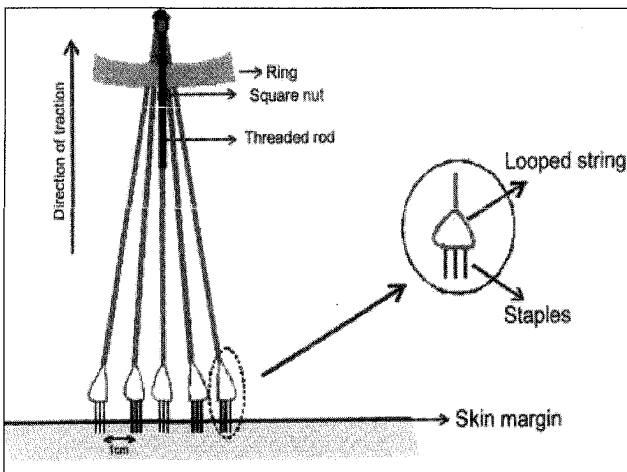


Figure 5: Schematic diagram showing the placement of staples, nylon wires and traction construct

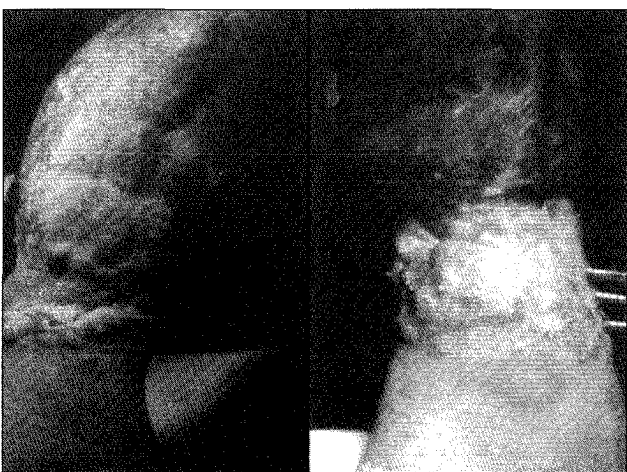


Figure 6: Post procedure view, showing the extent of skin cover achieved

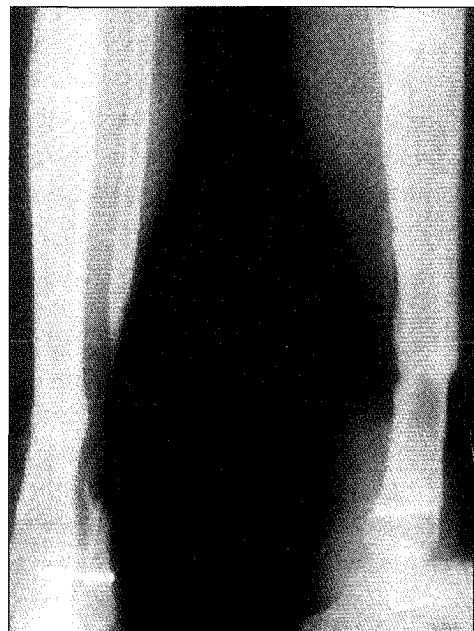

Figure 7: Radiograph at 1.5 year follow up, showing union of the fracture, lengthening of tibia and 7 arthrodesis of the distal tibio-fibular joint

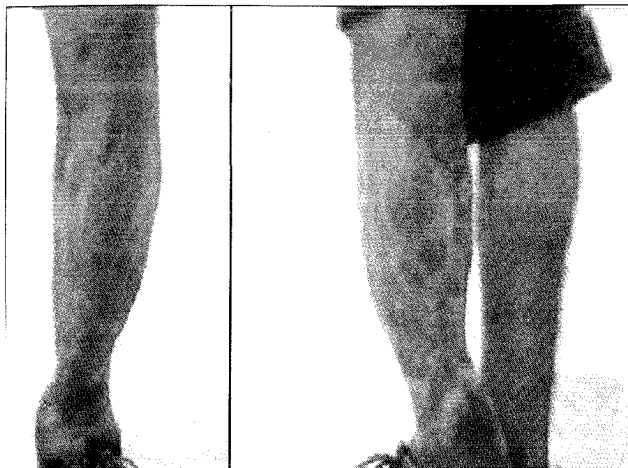


Figure 8: The patient wearing shoes

The extent of skin lengthening can be seen from below the level of the Orthofix distal pin set (Before the procedure - Figure 3) to above the level of the Orthofix distal pin set (After the procedure - Figure 6). Using this as a rough scale the skin lengthening in this region measures 8 cm. The skin gap remained in a small anterior area where the Schanz screws of the Orthofix device prevented the skin staples attachment and skin lengthening. This was skin grafted. The traction device was then removed.

The patient continued to be on treatment for lengthening of the tibia. He recovered sensation over the plantar aspect of the foot. Appearance of the limb one year later after achieving lengthening of 10 cm is seen in Figure 10. His radiographs show union of his fracture (Figure 7). At present he has no discharging sinuses, wears normal shoes (Figure 8) and has no disability. He has had no break down and has protective sensation in the lengthened skin.

DISCUSSION

The ideal method for treating a skin defect is replacement with the patient's normal sensate skin. It is better if removal of skin from another area can be avoided. This can be achieved by lengthening the patient's own skin. Lengthening of skin along with bone and soft tissue is regularly done in orthopaedic surgery utilizing the Ilizarov method, which is based on the principle of tissue growth under tension.^{3,4,5,6} Skin

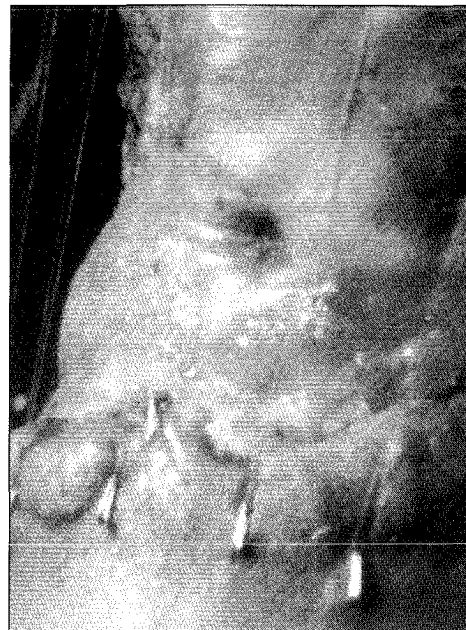

Figure 9: Skin staples pullout - a complication.

stretching devices and techniques have been described in the literature.^{1,2} We have utilized a combination of these two approaches whereby skin was lengthened gradually in a controlled fashion to treat circumferential skin loss. Different from previous reports, we used more gradual and controlled skin lengthening in order to avoid staple pullout or fibrosis or skin necrosis occurring in the skin due to too rapid a stretch. An advantage of this gradual controlled stretch is that we were able to use it on compromised skin.

We did have problems with the pulling out of three

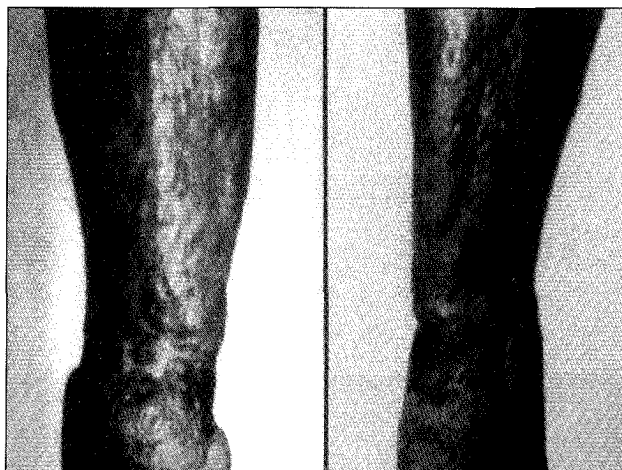

Figure 10: The leg at 1 year follow up

staples during the third week of skin traction in the anteromedial region (Figure 9). This complication has been described by other authors as well¹. Locally undermining the skin edges and reapplication has not improved their hold considerably in our experience. We advocate completion of skin lengthening within a three-week period, as thereafter staple pullout is more likely. Staple pull out can also be avoided by directing the line of pull parallel to and close to the skin.

The limitations of this technique are pulling out of the staples when lengthening is prolonged, done too fast or if the waiting period after debridement is long. Application of this technique on skin compromised by scarring and low vascularity is contraindicated. Our experience is limited to this one case for circumferential technique and there is need for more cases to establish the procedure. The advantages are that no anaesthesia is required, it is very cheap and replacement is by normal sensate skin. The skin lengthening is concurrent with the treatment of open fracture and hence there is no increase in the duration of treatment.

We believe this technique would be useful in selected cases of circumferential skin loss or in areas such as the lower leg and ankle where a skin graft would be unstable due to repetitive frictional trauma from the footwear.

REFERENCES

1. Concannon MJ, Puckett C. Wound coverage using modified tissue expansion. *Plast Reconstr Surg* 1998;102:377-84.
2. Hirshowitz B, Lindenbaum E, Har-Shai Y. A skin stretching device for the harnessing of the viscoelastic properties of skin. *Plast Reconstr Surg* 1993;92:260-70.
3. Ilizarov GA. The tension stress effect on the genesis and growth of tissues, in *Transosseous Osteosynthesis. Theoretical and clinical aspects of the regeneration and growth of tissue.* Springer-Verlag, Berlin Heidelberg 1992.
4. Kocialkowski A, Marsh DR, Shackley DC. Closure of skin defect overlying infected non-union by skin traction. *Br J Plast Surg* 1998;51:307-10.
5. Madhuri V, Dhanraj P. Correction of post burns contracture of wrist with Ilizarov method. *Burns* 1998;24:576.
6. Maiocchi AB, Aronson J (ed.). *Operative Principles of Ilizarov.* Williams and Wilkins. Milan, Italy, 1991.