

## Case Report

# Macromastia of pregnancy: A unique presentation of this rare clinicohistopathological entity

Sarda Anil K, Kulshreshta Vishal N, Bhalla Shweta A, Singh Lakhwinder, Chaturvedi Uma K

Departments of Surgery and Pathology, Maulana Azad Medical College and Lok Nayak Hospital, India.

Address for correspondence: Dr. A.K.Sarda, 27 RPS, Triveni-1, New Delhi - 110017, India. E-mail: aksarda@rediffmail.com

### ABSTRACT

The present case is a unique presentation of a patient who developed a small lump in her breast during her first pregnancy but it was only during her third pregnancy that it increased in size and became a huge fungating mass. Although, gigantic sizes of this pathologic entity have been reported, the present case had the involved breast hanging till below the inguinal ligament and required sling to support the breast. Since the pre-operative diagnosis was suggestive of cystosarcoma phylloides, no attempt at reconstructive surgery was contemplated.

### KEY WORDS

Breast, benign tumour, macromastia

### INTRODUCTION

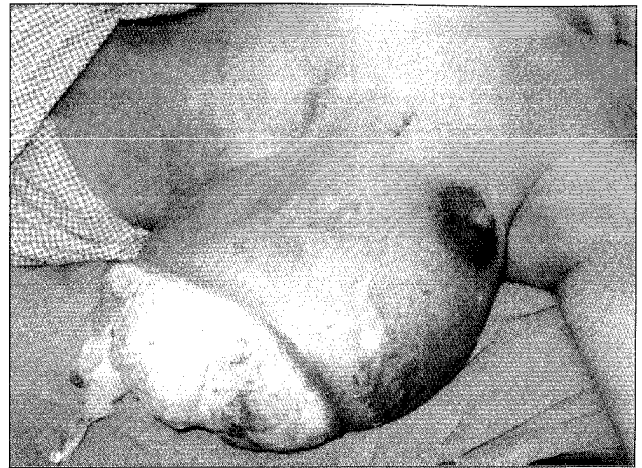Gestational macromastia (syn. Gigantomastia) is a rare disorder with disproportionate massive enlargement of one or both breasts that may or may not undergo spontaneous regression after parturition. Various criteria have been identified to differentiate macromastia from simple breast enlargement: breast weight exceeding 600 grams and causing discomfort and stretching of the overlying skin causing ulceration.<sup>1,2</sup> We present a rare case of a 28 year old patient presenting with a huge fungating mass in her left breast in the ninth month of her pregnancy. This patient had a small lump which developed during her first pregnancy. However, it was only during her third pregnancy that the lump increased in size to a huge fungating mass requiring surgery. The histopathology of the mastectomy specimen declared it to be macromastia of pregnancy. The interesting

feature of this rare disease was the massive size of the breast-probably the biggest reported so far.

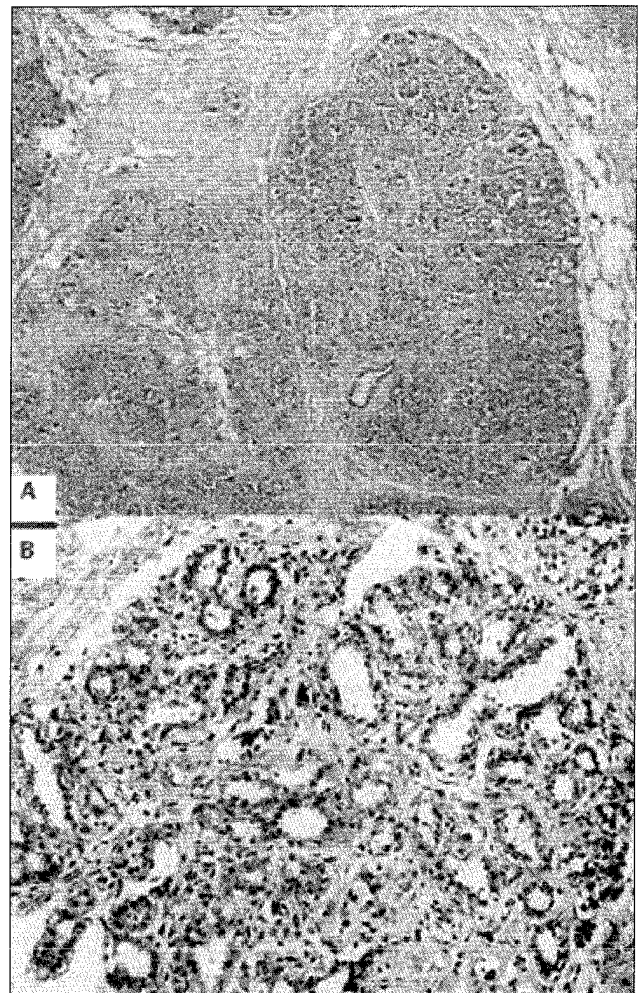
### CASE REPORT

A 28 year old pregnant lady presented in her ninth month of pregnancy with a huge fungating mass in her left breast. On taking a detailed history the patient revealed that she had noticed a small swelling in her left breast three years previously, which appeared about two months into her first pregnancy. There was no change in the size of the lump during the second pregnancy or in between her three pregnancies. This swelling started increasing in size after the onset of her current pregnancy and had reached its gigantic proportions over nine months. Two months prior to admission the overlying skin developed ulcers in the most dependent part of the breast which rapidly increased in size. Thereafter the exposed tumour tissue

underwent necrosis and started sloughing. Due to the extreme discomfort to the patient because of the large size and fungation of the large breast, the patient reported to the hospital during the ninth month of her pregnancy. The patient had two live issues the eldest being three years old. She had no past or family history of breast disease. On examination the patient was very pale. She had a huge mass in the left breast with the breast descending almost down to the inguinal region (Figure 1). The breast measured 35 x 30 x 10 cm. She required supporting the breast with a sling. There was fungation on the lower aspect of the breast with purulent discharge (Figure 2). The breast felt nodular in consistency. The overlying overstretched skin had a few small ulcers with a foul smelling discharge. The nipple and areola were oedematous, markedly stretched out but essentially normal. The ipsilateral axillary lymph nodes were not enlarged. The contralateral breast was normal. The patient's blood reports were Hb 7gm/dL with a PCV of 27%, TLC 10,800/mm<sup>3</sup>, DLC P78L20 M1E2-1, Blood sugar 90 mg/dL, Blood urea 20mg/dL, Serum Sodium 140 mmol/L, Serum Potassium 3.7 mmol/L. Her ECG was within normal limits and her chest X-ray showed a few patchy opacities in the right lower zone suggestive of pneumonitis. Fine Needle Aspiration Cytology of the breast lump suggested a diagnosis of cystosarcoma phylloides. With this diagnosis and in view of the massive size and fungation of the mass, it was decided to take up the patient for a total mastectomy. However, the patient deferred surgery till after her delivery. After delivery of a healthy male baby, the patient was transfused three units of blood but her general condition did not improve. She was also unable to get anesthetic clearance due to a severe lower respiratory chest infection. In view of the patient's poor general condition a decision was made to take up the patient for a simple mastectomy under local anesthesia. The simple mastectomy was undertaken with an intercostal block and local infiltration of 1% lignocaine. During the surgery there were large vascular channels which required careful dissection. The blood loss was limited to 400 ml. The patient developed mild post operative wound infection which responded to local dressings. Histopathology of the breast specimen showed lactational changes, adenosis and periductal as well as



**Figure 1:** Photograph of the patient in the supine position demonstrating the huge size, the large size of the ulcer and the tumour tissue which is seen sloughing off.



**Figure 2:** (A) shows markedly expanded lobule due to pregnancy-lactational changes (H&E X100) while (B) demonstrates cytosol vacuolation indicative of lactational changes (H&E X400).

diffuse fibrosis (Figure 2a). Acini showed vacuolated inner epithelium. Some lobules showed eosinophilic secretions in the dilated lumina (Figure 2b). No features of abscess, phylloides tumour or carcinoma were present. The final diagnosis was macromastia of pregnancy.

## DISCUSSION

The incidence of gigantomastia of pregnancy is approximately 1:100000 pregnant women.<sup>3</sup> The etiology of this condition remains a matter of speculation with the most common theories supporting hormonal imbalance or end organ hypersensitivity<sup>4</sup>. There are some case reports with documented hyperprolactinemia.<sup>3,5</sup> Other reports reveal no endocrine abnormality<sup>6</sup>. The possibility of increased number or increased sensitivity of prolactin receptors in the target organ has also been suggested.<sup>5</sup> Histological evidence of glandular hyperplasia and increased connective tissue has been commonly reported.<sup>3,7</sup> There is acinar and periacinar fibrosis in contrast to the normal gravid and lactational breast when the acini have large cylindrical cells and fibrous tissue is rather scant.<sup>8</sup> A misdiagnosis of phylloides tumour on fine needle aspiration cytology was probably made in the present case because of the abundant spindled out cells from the fibrous tissue.

Unilateral gigantomastia is exceptional<sup>3</sup>; it would suggest that local factors such as individual target organ sensitivity to the causative agent may have had an important role to play.

There is either some regression or no relief following delivery.<sup>9,10</sup> Thus reduction mammoplasty remains the mainstay of treatment during the postpartum period.<sup>11</sup> Although there does not seem to be a consensus, with some authors advising conservative management with progestational agents.<sup>12</sup> Also treatment during pregnancy remains somewhat controversial. Some authors advise that the primary measures should be local measures such as breast support and analgesics failing which a total mastectomy is to be considered.<sup>13</sup> There is also a report of therapeutic abortion being performed in the first trimester followed by a simple

mastectomy.<sup>14</sup> Medical management of this condition has also been discussed extensively. Prolonged bromocriptine therapy has been recommended after delivery before planning a surgical reduction.<sup>11</sup>

The present case of unilateral gigantomastia is a diagnostic dilemma. It had other unusual features like growth over a period of three pregnancies and the abundant spindled out cells from the fibrous tissue which lead to a misdiagnosis of phylloides tumour on fine needle aspiration cytology, leaving no choice but to offer mastectomy as the only treatment modality to the patient. Under different circumstances even such large fungating breast masses may be amenable to reduction mammoplasty leaving the patient with a cosmetically acceptable, albeit a nonfunctional breast.

## REFERENCES

1. Ship AG, Shulman J. Virginal and gravid mammary gigantism: recurrence after reduction mammoplasty. *Br J Plast Surg* 1971; 24:396-401.
2. Jurkiewicz MJ, Stevenson TR. Plast and reconstr surg. In: principles of Surg Eds Schwartz SE, Shires GT, Spencer DD, Storer EH Principles of Surg, Vol 2 Singapore, Mc Graw Hill, 1984:2101-50.
3. Zargar AH, Laway BA, Masoodi SR et al. Unilateral gestational macromastia-an unusual presentation a rare disorder. *Postgrad Med J* 1999;75:101-3.
4. Wolf Y, Pauzer D, Groutz A. Gigantomastia complicating pregnancy. Case report and review of literature. *Acta Obstet Gynecol Scand* 1995;74:159-63.
5. Wolner-Hansen P, Palmer B, Sjoberg NO. Gigantomasti. *Acta Obstet Gynecol Scand* 1981;60:525-7.
6. Gargan TJ, Goldwyn RM. Gigantomastia complicating pregnancy. *Plast Reconstr Surg* 1987;80:121-4.
7. Ziener A. Macromastia in pregnancy-normal or a complication? *Zentralbl Gynakol* 1990;112:1303-7.
8. Leis SN, Palmer B, Ostberg G. Gravid Macromastia. *Scand J Plast Reconstr Surg* 1974;8:247-9.
9. Greely PW, Robertson LE, Curtin JW. Mastoplasty for bilateral benign breast hypertrophy associated with pregnancy. *Ann Surg* 1965;162:1081-3.
10. Miller CV, Becker DW. Management of first trimester breast enlargement with necrosis. *Plast Reconstr Surg* 1979;63:383-6.
11. Agarwal N, Kriplani A, Gupta A. Management of Gigantomastia complicating pregnancy. A case report. *J Reprod Med* 2002; 47:871-4.
12. Lewison EF, Jones GS, Trimble FH et al. Gigantomastia complicating pregnancy. *Surg Gynecol Obstet* 1958;110:215-23.
13. Lafreniere R, Temple W, Ketcham A. Gestational macromastia. *Am J Surg* 1984;148:413-8.
14. Miller CJ, Becker DW Jr. Management of first trimester breast enlargement with necrosis. *Plast Reconstr Surg* 1979;63:383-6.