

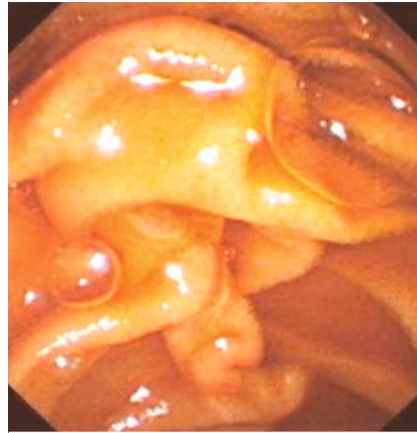
## Acute pancreatitis: ascaris in the pancreatic duct

A 36-year-old woman was admitted to our department with epigastric radiating pain, nausea, vomiting, fever, tachycardia, and sweating. The pain radiated to the back and had worsened. The sclera showed mild icterus. Laboratory test results showed elevated levels of total bilirubin (38 mmol/L), serum amylase, lipase, and white blood cells. Computed tomography scan showed an enlarged pancreatic head and a dilated pancreatic duct. A diagnosis of acute biliary pancreatitis was considered, although the cause of the dilated pancreatic duct was not clear. The Ranson's prognosis scale was 4, and therefore we performed endoscopic retrograde cholangiopancreatography (ERCP).

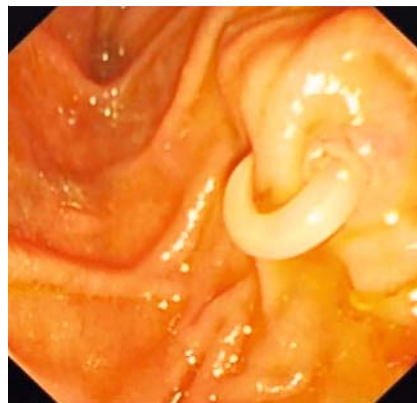
During ERCP, we could not find any abnormality in the papilla initially (► Fig. 1). After pancreatic duct cannulation, a strip filling defect was seen in the main pancreatic duct when we injected the contrast (► Fig. 2). The *Ascaris* worm came out of the papilla after pancreatography (► Fig. 3). We used a snare to grasp and remove the worm from the pancreatic duct (► Fig. 4, ► Video 1), and albendazole was given to prevent re-infection by the worms. The patient recovered smoothly and was discharged 6 days later.

Ascariasis-induced pancreatitis commonly occurs by worm invasion of the ampullary orifice, entering the bile duct, and blocking the pancreatic duct orifice, and rarely by direct invasion of the pancreatic duct. It is a rare but important cause of acute pancreatitis in developing countries. *Ascaris* is one of the common intestinal parasites and usually inhabits warm and humid areas where sanitation and hygiene are poor.

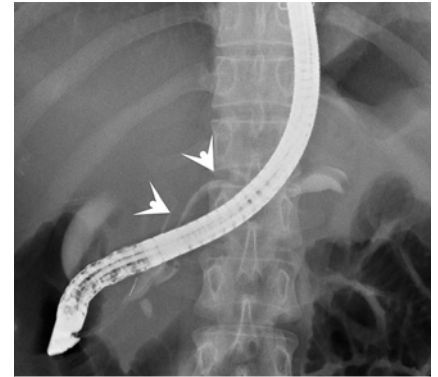
The disease may remain asymptomatic, with ascarides resident in the lumen of the small intestine. Symptoms can occur when helminths, including *Ascaris*, invade the biliary or pancreatic ducts. Presentation varies, the most common



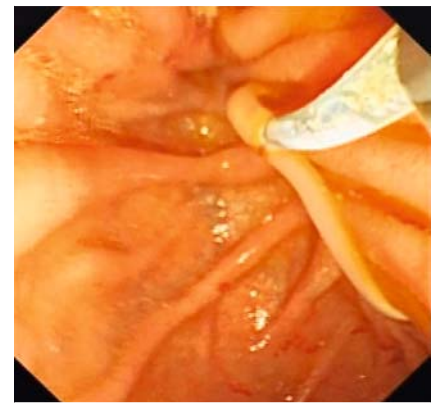
► Fig. 1 During endoscopic retrograde cholangiopancreatography, no abnormality was seen in the papilla initially.



► Fig. 3 After pancreatography, the *Ascaris* came out of the papilla.



► Fig. 2 The pancreatic duct angiography revealed a strip filling defect (arrows) in the main pancreatic duct.



► Fig. 4 After grasping the *Ascaris* with a snare, it was successfully removed.

being biliary colic (56%), acute cholangitis (25%), and acute cholecystitis (13%); acute pancreatitis makes up only 6% [1]. The pancreatitis induced by ascariasis is usually mild, and diagnosis is possible by conventional imaging [2,3]. ERCP is an effective diagnostic as well as treatment procedure for ascariasis in the biliary and pancreatic ducts [4]. Anthelmintic drugs are needed to avoid ascariasis relapse.

Endoscopy\_UCTN\_Code\_CCL\_1AZ\_2AF

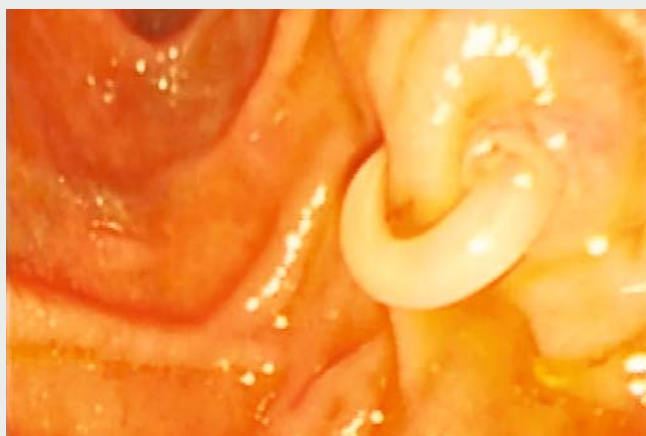
### Competing interests

None

### The authors

**Naveed Khan<sup>\*</sup>, Chuncheng Wu<sup>\*</sup>, Bing Hu**  
Department of Gastroenterology, West China Hospital, Sichuan University, China

<sup>\*</sup> These authors contributed equally to this work.



**Video 1** The pancreatography revealed a strip filling defect in the main pancreatic duct. The *Ascaris* came out of the papilla after pancreatography. We used a snare to grasp the *Ascaris* and successfully remove it.

- [3] Ng KK, Wong HF, Kong MS et al. Biliary ascariasis: CT, MR cholangiopancreatography, and navigator endoscopic appearance – report of a case of acute biliary obstruction. *Abdom Imaging* 1999; 24: 470–472
- [4] Alam S, Mustafa G, Ahmad N et al. Presentation and endoscopic management of biliary ascariasis. *Southeast Asian J Trop Med Public Health* 2007; 38: 631–635

#### Bibliography

DOI <https://doi.org/10.1055/s-0044-101600>

Published online: 16.2.2018

Endoscopy 2018; 50: E119–E120

© Georg Thieme Verlag KG

Stuttgart · New York

ISSN 0013-726X

#### ENDOSCOPY E-VIDEOS

<https://eref.thieme.de/e-videos>



Endoscopy E-Videos is a free access online section, reporting on interesting cases and new

techniques in gastroenterological endoscopy. All papers include a high quality video and all contributions are freely accessible online.

This section has its own submission website at <https://mc.manuscriptcentral.com/e-videos>

#### Corresponding author

##### Bing Hu, MD

Department of Gastroenterology, West China Hospital, Sichuan University, No. 37 Guo Xue Alley, Chengdu 610041, Sichuan Province, China  
Fax: +86-028-85423387  
[hubingnj@163.com](mailto:hubingnj@163.com)

#### References

- [1] Klimovskij M, Dulskas A, Kraulyte Z et al. Ascariasis of the pancreatic duct. *BMJ Case Rep* 2015. doi:10.1136/bcr-2014-207936
- [2] Wu S. Sonographic findings of *Ascaris lumbricoides* in the gastrointestinal and biliary tracts. *Ultrasound Q* 2009; 25: 207–209