

# DEGUM Recommendations on Infection Prevention in Ultrasound and Endoscopic Ultrasound

## DEGUM-Empfehlungen zur Hygiene in Sonografie und Endosonografie

### Authors

Thomas Müller<sup>1</sup>, Heike Martiny<sup>2</sup>, Eberhard Merz<sup>3</sup>, Jens Döffert<sup>4</sup>, Matthias Wüstner<sup>5</sup>, Wolfgang Lessel<sup>6</sup>, Hans Heynemann<sup>7</sup>, Thomas Enzmann<sup>8</sup>, Heiko Dudwiesus<sup>9</sup>, Dieter Nuernberg<sup>10</sup>, Christian Tesch<sup>11</sup>, Marc André Weber<sup>12</sup>, Siegfried Krishnabhakdi<sup>13</sup>, Jörg Heil<sup>14</sup>, Alexander Wree<sup>15</sup>, Christian Jenssen<sup>16</sup>

### Affiliations

- 1 Department of Internal Medicine I, Kreiskliniken Reutlingen, Germany
- 2 Technical Hygiene, Charite, Berlin, Germany
- 3 Center for Ultrasound and prenatal Medicine, Center for Ultrasound and Prenatal Medicine, Frankfurt, Germany
- 4 Anesthesia and Critical Care Medicine, Kreisklinikum Calw-Nagold, Calw, Germany
- 5 Central Ultrasound Department, Bruederkrankenhaus, Trier, Germany
- 6 Urologie, Praxis, Magdeburg, Germany
- 7 Urology, Universitätsklinikum Halle, Germany
- 8 Klinik für Urologie und Kinderurologie, Klinikum Brandenburg, Germany
- 9 Langenfeld, Germany
- 10 Department of Gastroenterology, Brandenburg University of Medicine Theodor Fontane, Neuruppin, Germany
- 11 Orthopedics and Trauma Surgery, Praxis, Hamburg, Germany
- 12 Institute for Diagnostic and Interventional Radiology, Universitätsmedizin Rostock, Germany
- 13 Department of Vascular Surgery, Klinikum Herford, Germany
- 14 Department of Gynekology and Obstetrics, University Hospital, Heidelberg, Germany
- 15 Internal Medicine III, Universitätsklinikum Aachen, Germany
- 16 Klinik für Innere Medizin, Krankenhaus Märkisch Oderland Strausberg/ Wriezen, Germany

### Key words

ultrasound, infection, intervention, disinfection, endoscopic ultrasound

received 12.09.2017

accepted 29.12.2017

### Bibliography

DOI <https://doi.org/10.1055/s-0044-102006>

Published online: March 6, 2018

Ultraschall in Med 2018; 39: 284–303

© Georg Thieme Verlag KG, Stuttgart · New York

ISSN 0172-4614

### Correspondence

Dr. Thomas Müller

Med. Klinik I, Kreiskliniken Reutlingen, Steinenbergstrasse 31, 72764 Reutlingen, Germany

Tel.: ++49/71 21/20 00

[mueller\\_tho@klin-rt.de](mailto:mueller_tho@klin-rt.de)

### ABSTRACT

Microbial contamination of ultrasound probes for percutaneous or endoscopic use is common. However, infectious diseases caused by transmission of microorganisms by US procedures have rarely been reported. In Germany, legal regulations address hygiene in ultrasound procedures. Based on these regulations and the available literature, an expert panel of the German Society of Ultrasound in Medicine (DEGUM) has formulated sophisticated recommendations on hygienic measures in percutaneous and endoscopic US, including US-guided interventions.

### ZUSAMMENFASSUNG

Mikrobielle Kontaminationen von Schallköpfen, kutan oder endokavitär angewandt, sind häufig, tatsächliche Infektionen nach Sonografien werden jedoch nur kasuistisch berichtet. In Deutschland existieren rechtliche Vorschriften zur Schallkopfhigiene. Ein Expertengremium der DEGUM hat vor dem Hintergrund der Vorschriften und der verfügbaren Literatur differenzierte Empfehlungen zur Hygiene in der Sonografie und der Endosonografie, einschließlich der ultraschallgestützten Interventionen, formuliert.

## Introduction

Due to its universal availability, the lack of ionizing radiation, and its useful applications for medical practitioners with a broad range of areas of specialization, ultrasound has become an important diagnostic imaging method. An ultrasound probe and a coupling medium are always applied to the patient's body.

Ultrasound is also widely used in many medical fields for controlling percutaneous interventions, such as puncture, biopsy, regional anesthesia, catheter and drainage placement [1–4]. From a hygiene standpoint, the proximity of non-sterile material (ultrasound probe) to the injection cannula or drainage tube is problematic in particular [5–7].

In the case of diagnostic endoscopic ultrasound imaging, the ultrasound probe is inserted into an opening in the body. In the case of endoscopic ultrasound-guided puncture (transesophageal, transgastral, transbronchial, transvaginal, transrectal), the integrity of the mucous membranes is additionally compromised.

The current ultrasound probe preparation practices in Europe were recorded in a survey by the European Society of Radiology (ESR). 65 % of respondents indicated that they clean and disinfect the ultrasound probe after every examination of intact skin. In the case of invasive examinations, 77 % of respondents use sterile ultrasound probe covers and 77.5 % use sterile gel. However, only 946 of 22 000 surveys were completed and returned, corresponding to a response rate of only 4.6 %, thereby greatly limiting the significance of the survey. 666 respondents provided information regarding invasive methods [8].

In Germany, there are legal regulations regarding the use of medical devices and their preparation [9–12], which are clearly defined in recommendations from the Commission for Hospital Hygiene and Infection Prevention (KRINKO) [13–15]. Several professional societies have also published guidelines and recommendations, some of which only address individual aspects of this topic [16–21]. However, there is little prospective data regarding infections caused by transmission of microorganisms during US procedures. As a result, the German Society of Ultrasound in Medicine (DEGUM) has formulated valid, comprehensive, and sophisticated recommendations for daily practice.

## Method

On the initiative of DEGUM's Working Group for Interventional Ultrasound and with the authorization of the extended board of the society, 16 experts were named as the authors of the recommendations on hygiene in ultrasound and endoscopic ultrasound in January 2016 after invitation to the boards of the divisions and working groups. After approval of the topics and questions, a systematic search of the literature (PubMed, Limits 01/1980–02/2017, human, German, English; Google Scholar) was performed and the relevant publications of the Robert-Koch Institute were viewed. This literature search was supplemented by a targeted hand search by the members of the expert panel. The last update was made as part of the review process in December 2017.

Based on the results of the literature analysis, the valid laws in Germany, existing guidelines and expert experience, the authors

completed their recommendations on hygiene in ultrasound and endoscopic ultrasound by the end of April 2017. These recommendations were discussed in the divisions and working groups of DEGUM and in the expert group, and the final version was approved using a Delphi method from June 8 to July 8, 2017. Recommendations that did not achieve agreement of at least 75 % (12/16 authors) in the Delphi method were discarded or revised and then reconsidered. The recommendations accepted for this publication were adopted in "consensus" (agreement of 12–13/16 authors), with "strong consensus" (14–15/16 authors) or unanimously (16/16 authors).

Although this expert consensus is based on a significantly larger pool of data than previously published recommendations, even those of KRINKO, there were only a few prospective studies and almost no comparative studies regarding the main topic of infection rates. Many of the cited studies are only of medium or low quality. Therefore, grading of the evidence and evaluation of the strength of the recommendation were intentionally eliminated.

## Background

### Microbial contamination

An observational study from France visually inspecting probes from daily use in an emergency room detected macroscopic contamination with gel, blood, or dust in 58 % of cases [22]. When the ultrasound probes at six American hospitals were tested for contaminants, all six came back positive, albeit only with microorganisms of normal skin flora, including yeast [23]. In 320 swabs of ultrasound probes of point-of-care US devices, a single-center American study found bacterial growth (exclusively apathogenic microorganisms) in only 5.5 % of cases [24]. Another American study examined ultrasound probes from an emergency room and found contamination with skin flora in 67 % of cases including pathogenic microorganisms in 1.2 %. The rate increased to 70 % when examining patients with skin or soft-tissue infections [25]. Problematic bacteria like MRSA were found by other authors in up to 41 % of ultrasound probes after examination of MRSA-positive patients [26].

An English epidemiological study found microorganisms from the skin and environment on ultrasound probes, gel and device keyboards in 65 % of cases and potentially pathogenic agents in 9.4 % (one-fifth being on the ultrasound probe) [27]. An ultrasound probe used for abdominal ultrasound in the clinical routine was examined using contact plates at the Greifswald University Hospital. Examination of 95 contact samples from this probe showed that only 17 (18 %) were without a microbiological finding after wiping and before disinfection. Coagulase-negative staphylococci were seen in the vast majority of the other cases [28]. Contamination of 60 % of all ultrasound probes after abdominal examination is reported in Australia [29] and of 42–100 % of ultrasound probes in routine use examined in Poland [30]. A current, European-American study found that ultrasound probes have a tendency to have greater microbial contamination than public toilets and handles on buses [31].

Endoscopic ultrasound probes are semi-critical medical devices and are subject to strict preparation criteria [14, 32]. Sykes et al. report skin and environmental organisms on 83.3% of examined vaginal probes and on 45% of rectal probes (potentially pathogenic microorganisms 6.7% and 3%, respectively) [27].

These contamination rates show the necessity for clear recommendations regarding hygiene both in diagnostic ultrasound imaging and ultrasound-guided therapy.

## Legal basis

### Application

According to the German Protection against Infection Act (IfSG, § 23 (3)), the heads of medical facilities must ensure that the necessary measures as determined by current medical knowledge are taken to prevent nosocomial infections and the transmission of pathogens. Moreover, according to § 36 of the IfSG, in-house infection prevention procedures must be defined in hygiene plans [9].

In the event of damage, e. g. the occurrence of an infection after an ultrasound intervention, the examiner must show that the necessary measures according to current medical science have been met and the valid recommendations have been observed [33]. Therefore, according to IfSG § 23 (4): “It is assumed that the requirements according to current medical science in this area have been met if the published recommendations of the Commission for Hospital Hygiene and Infection Prevention have been observed” [9].

In 2011, this commission (KRINKO) published the “Hygiene Requirements for Puncture and Injection” [13], which are discussed in the following.

The KRINKO recommendations [13] require skin antiseptic with a sufficiently long application time for percutaneous puncture. Microorganisms must not be able to be transferred from the clothing of the person performing the examination to the patient. Four risk groups are defined on the basis of the puncture procedure, the puncture target, and the assumed infection risk (► **Table 1**). Individual risk factors must also be taken into consideration.

Based on the categorization of the risk groups, KRINKO makes detailed recommendations regarding materials, barrier precautions, and protective clothing with examples (► **Table 2**).

The KRINKO recommendations also relate to ultrasound-guided puncture [13, 15]. The guidelines do concede that there are no randomized studies with a clinical end point and only minimal scientific data in this regard is available [13, 15]:

In the case of ultrasound-guided puncture, in which the probe touches the puncture site or can come into contact with the puncture needle, the probe is to be provided with a sterile cover (► **Fig. 1–3**).

In the case of ultrasound-guided puncture for inserting a catheter, the sterile cover must also include the supply cable (► **Fig. 4**).

If a non-sterile ultrasound coupling medium is used, it must not be allowed to contaminate the needle or the puncture region.

► **Table 1** Puncture risk groups according to KRINKO [13].

risk group	definition
1	simple puncture procedure and low risk of puncture-associated infection
2	simple puncture procedure and low infection risk but serious consequences documented in the literature in the case of (rare) occurrence of infection and no need to temporarily set down sterile puncture tools.
3	puncture of organs or cavities or complex puncture procedure with need to temporarily set down sterile puncture tools, with or without an assistant.
4	complex puncture with the need to temporarily set down sterile puncture tools and aseptic handling of puncture tools by an assistant and/or the insertion of catheters or foreign objects into body cavities or deep clefts in tissue.

This is ensured, for example, when the ultrasound probe is applied outside the puncture region (► **Fig. 2**).

If an ultrasound coupling medium is used directly at the puncture site, an alcohol skin disinfectant or sterile ultrasound gel is to be used (► **Fig. 1, 3**).

Hand hygiene as the most effective single step in breaking the chain of infection in health care facilities is particularly important in (interventional) ultrasound. Hygienic hand disinfection must be performed immediately before contact with a patient, immediately prior to aseptic activities, immediately after contact with potentially infectious materials, after contact with a patient, and after contact with the patient’s immediate surroundings and is thus an essential and continually repeated part of diagnostic ultrasound imaging. Surgical hand disinfection (washing hands and lower arms with soap, followed by disinfection up to the elbows) is required for intraoperative ultrasound [13, 34].

### Preparation

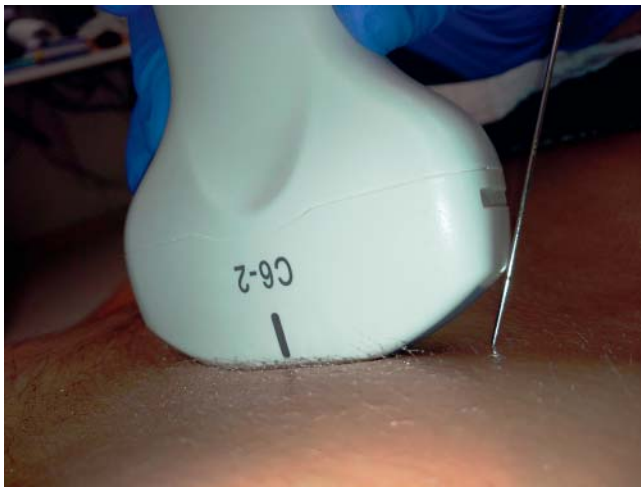
Preparation includes preliminary cleaning, cleaning, disinfection, rinsing, drying and inspection of the cleanliness and intactness of the ultrasound probe. In 2012, KRINKO and the Federal Institute for Drugs and Medical Devices (BfArM) published “Hygiene Requirements for the Preparation of Medical Devices” [14].

All medical devices must be cleaned and disinfected using validated methods and sterilized if necessary [19]. The requirements [14] necessitate detailed description of a validated method for the preparation of devices to be used in a low-germ – i. e. disinfected – and sterile state with reference to the Medical Device Directive and DIN EN ISO 17664. The legal situation in Germany requires ultrasound probe manufacturers to describe these methods. However, this information is often missing in practice [28, 35].

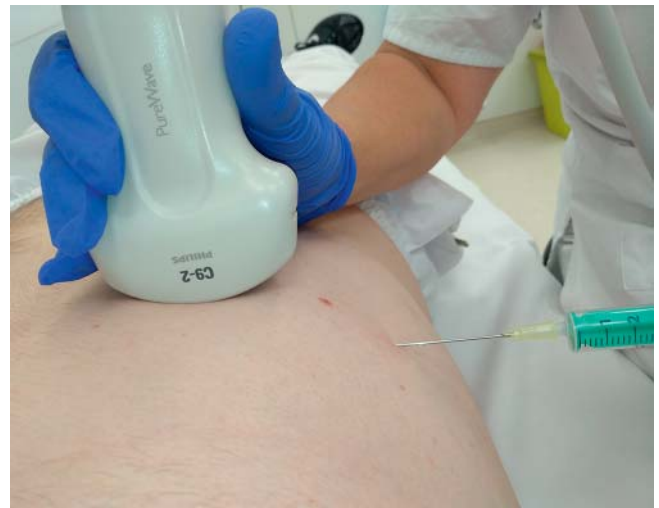With respect to the type of application and the resulting risk, there are three categories of medical devices: non-critical, semi-critical, and critical. Ultrasound probes that only come in contact with healthy skin are “non-critical”. Cleaning and disinfection

► **Table 2** KRINKO recommendations to be taken into consideration in a hygiene plan, modified according to [13].

risk group	type of puncture	type of swab	cover	additional protective clothing	
				examiner	assistance
1	i. v. injection (peripheral)	low-germ	none	low-germ gloves	not required
2	pleural puncture, ascites puncture, bladder puncture (diagnostic)	sterile	none	sterile gloves, surgical mask	no special measures
3	organ puncture (e. g. kidney, liver, lymph node, spleen, thyroid) amniocentesis chorionic villus sampling transvaginal/transrectal (ultrasound-guided) cyst or tissue puncture	sterile	sterile drape	sterile gloves	no special measures
	joint puncture	sterile	sterile drape	sterile gloves, surgical mask in the case of puncture with syringe change	surgical mask in the case of puncture with syringe change
4	pleural drainage catheter placement in other body cavities or organs	sterile	sterile drape	sterile gloves, surgical mask, surgical cap, sterile long-sleeve gown	surgical mask



► **Fig. 1** Incorrect puncture using the freehand technique with minimal needle distance from the ultrasound probe. The needle unintentionally comes in contact with the ultrasound probe that has only been disinfected. A sterile cover for the ultrasound probe would be needed in this case.



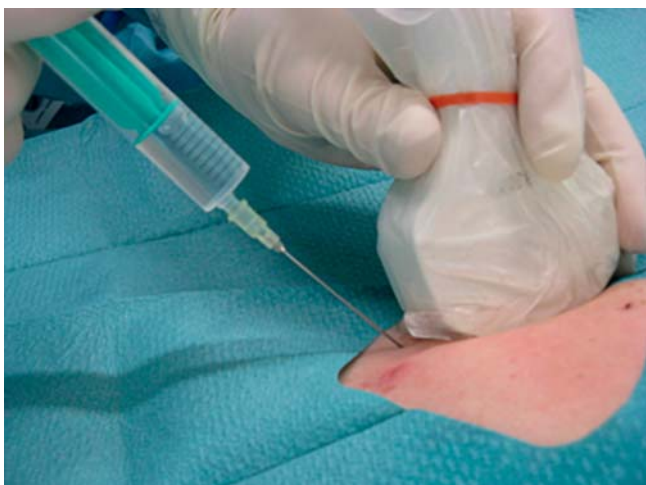► **Fig. 2** A safety distance between the ultrasound probe and the sterile needle is maintained in this freehand biopsy. If the examiner can ensure that the needle will not come into contact with the ultrasound probe, a sterile ultrasound probe cover is not necessary.

after every use is sufficient here. Disinfectants with only bactericidal and yeasticidal (yeast killing) activity are to be used.

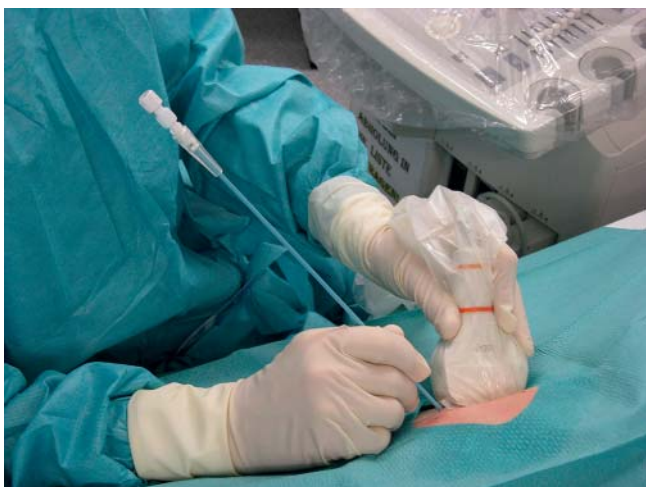Ultrasound probes that come into contact with the mucous membrane or diseased skin, e. g. during introitus or perineal ultrasound, are “semi-critical medical devices without special preparation requirements”. In this case, disinfection with bactericidal (including mycobacteria), fungicidal and virucidal activity must be performed. The check for virucidal activity must be performed

according to the current guidelines of the Society for Virology in Germany and the Robert Koch Institute [14].

Rigid endoscopic ultrasound probes (► **Fig. 5**) are generally semi-critical medical devices of group A (without special preparation requirements). In Appendix 7 of the indicated publication, BfArM and RKI define the requirement as follows: “Manufacturers of ultrasound probes for transvaginal use are required to provide specifications regarding at least one effective and suitable disinfection method with the above-mentioned spectrum of efficacy



► **Fig. 3** Correct application of the sterile ultrasound probe cover in a freehand biopsy with possible contact between the needle and the ultrasound probe. The examiner is wearing sterile gloves. A sterile drape/incise drape as a barrier precaution is obligatory when tools (e.g. syringe) must be changed/set down during puncture.




► **Fig. 4** Placement of an abscess drainage tube. Ultrasound probe, cable, and keyboard are covered with sterile covers. Following hand disinfection, the examiner is dressed as in a surgical situation. A sterile drape/incise drape serves as the barrier precaution. A sterile ultrasound gel is used as the contact medium. A sterile work table is additionally available.

in the instructions for use. Proof of efficacy with recognized methods must be documented by an expert opinion (...)” [14]. This requirement was included in the ultrasound agreement in 2017 [36].

Flexible endoscopic ultrasound probes and rigid probes with an internal instrument channel are part of group B (with greater preparation requirements) and must therefore undergo preliminary cleaning directly after use and should preferably be prepared for use by machine [14].

As thermolabile devices, guide adapters that can be clamped to the ultrasound probe (► **Fig. 6**) are to be disinfected at least once and covered with a sterile cover. Injection needles and



► **Fig. 5** Rigid endoscopic ultrasound probe with puncture adapter. The ultrasound probe is first covered with a low-germ cover that is partially filled with ultrasound gel. The disposable needle guide is mounted over this.

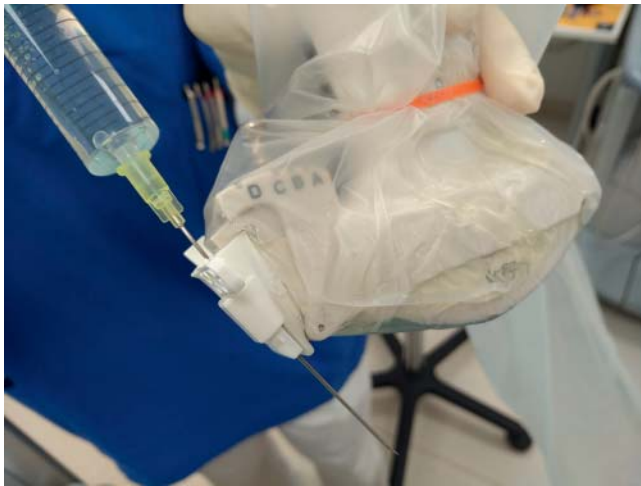needle guides are generally to be used as sterile disposable products (► **Fig. 5, 6**). Puncture needles and drainage tube are “critical” medical devices that must be sterile. Ultrasound probes with a puncture channel (► **Fig. 7**) must also be sterilized [14].

In intraoperative ultrasound (► **Fig. 8**), ultrasound probes are inserted into open body cavities and are thus also considered critical medical devices. In addition, they are thermolabile (“critical C”). The KRINKO/BfArM recommendations require machine cleaning and disinfection as well as sterilization (e.g. plasma or ethylene oxide sterilization). Moreover, preparation is subject to external quality control. This is to be verified by certification of the quality management system to guarantee that these requirements have been met [14].

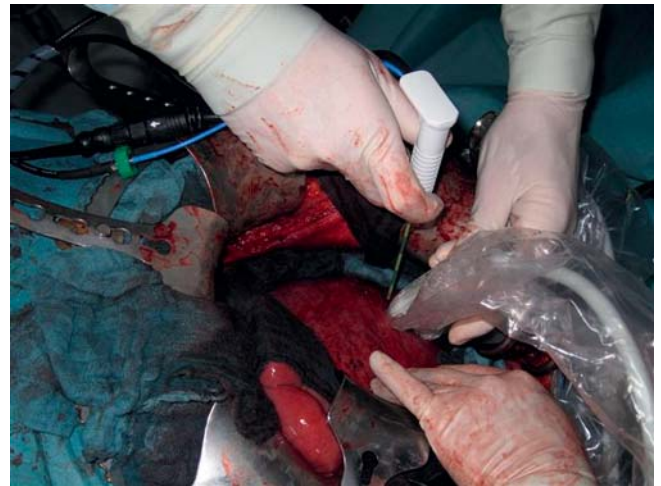In English and French-speaking countries, there is often a differentiation between “low”, “intermediate” and “high-level disinfection”. “Low-level disinfection” refers to the killing of most vegetative bacteria, some fungi, and viruses in a short period of time (< 10 min). “High-level disinfection” means that all microorganisms including spores are killed [32, 37]. This categorization is not legally relevant in Germany.

## Guidelines

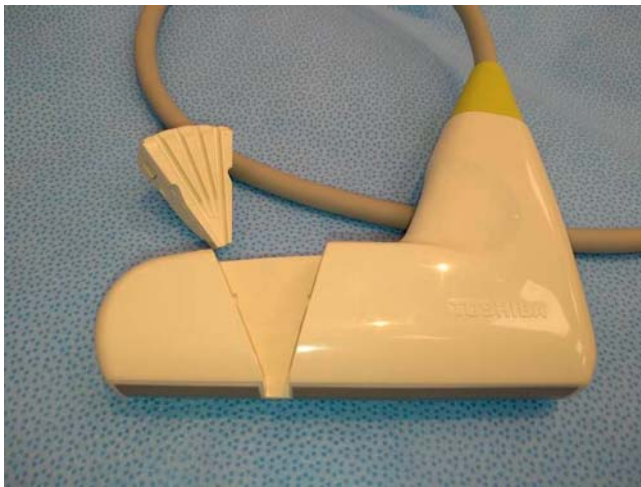The current European guidelines of the EFSUMB for interventional ultrasound go into less detail compared to the KRINKO recommendations that are based on the principle of risk minimization. They are primarily based on two categories not defined in greater detail: “major and minor invasive procedures” with varying infection risks. This required adapted hygiene measures. Sterile gloves, disposable gowns, and sterile ultrasound probe covers are recommended also for minor measures while asepsis as in the operating room is recommended for major interventions. EFSUMB requires cleaning and disinfection for the preparation of ultrasound probes, while ultrasound probes with a puncture channel or intraoperative probes must be sterilized [21].



► **Fig. 6** Ultrasound probe with puncture adapter. The guide adapter is attached to the ultrasound probe under the sterile cover. The sterile disposable needle guide is clamped on top. The ultrasound probe cover also covers the cable.



► **Fig. 8** Intraoperative ultrasound with intervention. The sterilized ultrasound probe or probe treated with bactericidal (including mycobacteria), fungicidal, and virucidal immersion disinfection is packed in sterile packaging. The examiner is dressed like a surgeon.



► **Fig. 7** Ultrasound probe with puncture channel with removed needle guide. As a rule, these ultrasound probes and needle guides must be sterilized since the needle in the channel touches both parts.

In November 2014, the Regional Anesthesia Working Group of the German Society of Anesthesiology published its S1 guidelines, which require that the ultrasound probe and cable be covered with a suitable sterile cover in ultrasound-guided regional anesthesia. No differentiation is made between “single shot” and “catheter-based” regional anesthesia. Moreover, only sterile ultrasound gel or another sterile fluid can be used to improve image quality. In addition, all persons participating in catheter implantation must wear a surgical cap and a new surgical mask. In single-shot puncture, only a surgical mask is necessary. The sterile gown and surgical cap can be dispensed with [20].

In 2015, the “Hygiene in Hospital and Practice” working group of the AWMF published S1 guidelines regarding hygiene measures in intraarticular puncture and injection requiring a certain

distance between the ultrasound probe and puncture site (not defined in greater detail) during ultrasound-guided freehand puncture. Disinfection of the ultrasound probe and patient skin is then sufficient, and a sterile ultrasound probe cover is not required. The coupling medium should be a disinfectant [17]. The current S1 guidelines of the same working group do not include ultrasound control of vascular catheter insertion [18].

Guidelines of the American Centers for Disease Control and Prevention also address ultrasound and were last published in 2008 [32]. The French Radiology Society published hygiene recommendations for interventional radiology in 2012 [38].

## Current data

### Percutaneous ultrasound

The contamination rates of examined ultrasound probes from the clinical routine were mentioned in the introduction. Transmission of *Staphylococcus aureus* from patient to patient via only dry-wiped, non-disinfected ultrasound probes was already proven 30 years ago [39]. However, reports of infections due to transmission of microorganisms via contaminated ultrasound probes are not known. This would also be difficult to prove since at the time of manifestation of an infection the ultrasound probe would typically already have been used again numerous times.

### Bacterial contamination of ultrasound gel

As noninvasive products for temporary use, ultrasound gels are class I medical devices according to European law and as such are equal to pharmaceuticals with respect to function, safety, and quality. In the EU it can therefore be assumed that commercially available ultrasound gel is primarily not contaminated with bacteria.

However, contaminated gels were found in up to 2.5% of cases (*Pseudomonas aeruginosa*, USA; *Burkholderia cepacia*, Italy, Cana-

da; mycobacteria, Taiwan) and were determined to be a source of nosocomial infections [40–44]. Endemic transmission of *Achromobacter xylosoxidans* after transrectal prostate biopsy was able to be traced back to contaminated gel in Israel [45]. Heated gel in pediatrics was identified as the source of infection with *Staphylococcus aureus* [46]. However, heating the gel to over 40 °C tends to reduce the rate of bacterial contamination [47].

If gel is transferred from the disposable bottle, contamination and infection can occur. Eight cases of gel-associated infection with ESBL-producing *Klebsiella pneumoniae* were reported in France [48]. Contamination rates can be high: in two publications 28 % and 59.5 % of all gels were contaminated including with pathogenic bacteria (*Stenotrophomonas maltophilia*, *Acinetobacter baumannii*, *Staphylococcus aureus*, MRSA, *Bacillus* spp., among others) [47, 49].

In a comment regarding bacterial contamination of ultrasound gel, North American authors cited case reports indicating contamination of the gel with *Pseudomonas aeruginosa* already during manufacture [50]. Despite the addition of preservatives, e. g. parabens, ultrasound gels are not always free of microorganisms [42]. In addition, ultrasound gel can enter the needle when it passes through the gel [51]. Various authors require the use of sterile ultrasound gel for every procedure requiring skin disinfection. This relates to all percutaneous biopsies [44, 50].

#### CONCLUSION:

1. Commercially available ultrasound gels are usually but not always free of microorganisms.
2. Refillable gel containers are often contaminated.
3. There are case histories and reports of local outbreaks of various infections caused by the transmission of microorganisms via contaminated ultrasound gels.
4. Infections caused by transmission of microorganisms via contaminated ultrasound probes are not known despite high contamination rates.

#### Ultrasound probe preparation

According to the international literature, a broad range of cleaning and disinfection methods are used for ultrasound probes.

Cleaning only with dry paper is common but is not sufficient from a hygienic standpoint: Of 50 ultrasound probe swabs examined in an Iranian study, 98 % were positive for aerobic bacteria and 52 % for anaerobic bacteria immediately after an examination. After wiping with paper towels, the rates were 42 % and 21 %, respectively [52]. A Nigerian study found positive swabs in 37 or 40 patients immediately after examination, including 34.6 % cases of MRSA. An average of 90 colony-forming units (CFUs) were detected immediately after examination, 12.9 CFUs after the probe was wiped once, and 3.3 CFUs after the probe was wiped twice [53]. This coincides with findings from the USA [25] and Wales [26].

A study from Wales prospectively examined ultrasound probes immediately after abdominal ultrasound in 40 patients (including 34 with MRSA colonization). 40 swabs were taken immediately

and then another 40 after the probes were wiped with paper towels. Two groups were formed: 20 swabs were performed after disinfection with 70 % alcohol and 20 after another wiping only with dry paper. On average, there were 128 CFUs immediately after use, 21 CFUs after wiping with paper once, 2 CFUs after wiping with paper twice, and only 0.05 CFUs after cleaning with paper and alcohol. 41 % of the first 34 swabs taken from ultrasound probes after use on MRSA-positive patients were positive for MRSA [26].

In a Canadian study, 31 non-endocavitary ultrasound probes were contaminated with various quantities of MRSA and were then cleaned with 0.5 % hydrogen peroxide solution. After five minutes, contamination could no longer be detected on any of the probes [54]. An English prospective study examined 120 swabs of ultrasound probes and ultrasound units for regional anesthesia after cleaning and disinfection with 70 % isopropanol. No bacteria growth was seen in 85 % of cases and growth of apathogenic microorganisms of the skin was seen in 15 % of cases [55].

French authors compare three different methods for cleaning/disinfection: Dry wiping with paper towels, antiseptic cleaning with a cloth sprayed with disinfectant (mixed solution, Aniospray 29) and a ten-minute UV-C treatment. The median microbial reduction (in CFUs) was 100 % after UV-C treatment, 98.4 % after cleaning with an antiseptic wipe, and 87.5 % after wiping with dry paper. Bacteria-free swabs were seen in 88 %, 16 % and 4 % of cases [56].

A study from Turkey found comparable efficacy for the cleaning of ultrasound probes with 80 °C hot water for five minutes and cleaning with antiseptic wipes (Cleanisept® Wipes) based on 20 swabs in each case: Coagulase-negative staphylococci were detected in 5 % of cases (1/20) [57].

#### CONCLUSION:

1. In daily use there are primarily microorganisms of normal skin flora on ultrasound probes.
2. These microorganisms and pathogenic bacteria like MRSA cannot be reliably eliminated by wiping.
3. There are numerous proposed and used cleaning and disinfection methods with varying success rates.

#### Percutaneous interventional ultrasound

Given the broad use of ultrasound for guiding invasive measures, there are astonishingly few publications that address hygiene in this regard. The available publications regarding infectious complications in ultrasound-guided interventions are case histories and largely retrospective analyses or surveys [58–62]. However, retrospective surveys have the risk of overlooking clinically inapparent infections or infections treated elsewhere. In addition, the hygiene conditions and antiseptic measures are usually not standardized and therefore cannot be tracked or compared in all cases.

A large retrospective study from Italy found only three infections in 16 648 biopsies and 3035 therapeutic interventions involving the liver over a period of 22 years, all after ethanol instillation.

However, only 8% of the 12 962 biopsied patients were reexamined with documentation after two to three weeks [63].

In the case of a retrospective analysis of a biopsy register of the Mayo Clinic in Rochester, infections were detected in 8 (0.1%) of the 6613 primarily ultrasound-guided liver biopsies performed over 12 years. Unfortunately, the authors do not provide any information regarding hygiene measures. All eight infections (cholangitis, cholegenic sepsis, infected biliary fistulas) occurred in patients with biliary obstruction or after liver transplantation. The authors discussed periinterventional antibiotic prophylaxis for this subgroup [64].

Since infections can also occur with delay, infectious complications were not recorded in the multicenter prospective PIUS study by DEGUM published in 2015 [65]. The available prospective data is analyzed in the following.

### Infections after ultrasound-guided percutaneous injection/ biopsy

An older prospective study from Italy examined 719 diagnostic and therapeutic abdominal interventions in 558 patients. An antiseptic regime analogous to that of venipuncture was used in this context: Skin disinfection with an iodine solution, ultrasound probe disinfection (70% alcohol), no sterile covers, no contact between needle and ultrasound probe. The coupling medium was sterile gel or Vaseline. Puncture was performed using the freehand and in-plane technique. The observation period was five days. Serologic testing for hepatitis was performed after three and six months in patients and examiners. No signs of infection were seen [66].

A prospective study from Romania examined infectious complications after ultrasound-guided interventions involving the musculoskeletal system and reported no infections in 988 interventions in 945 patients (0). Non-sterile gel was used, the probe was cleaned only with a dry, soft paper, and no sterile cover was used. The examiner had washed but not disinfected his hands and wore gloves, an apron and a mask covering the mouth. The patient's skin was disinfected with 70% alcohol and a povidone-iodine solution or povidone-iodine solution alone. A follow-up examination was performed after three weeks as planned. Otherwise, the patient was instructed to call in the event of infection [67].

In contrast to prospective studies, two large retrospective analyses from the Mayo Clinic in Rochester found a low incidence of intervention-associated infections:

An analysis of registry data of 13 534 interventions (thoracic and abdominal, biopsy and drainage, but no local ablative procedures) found a total of 14 infections (0.1%) during the observation period of 12 months [68]. A sterile cover for the ultrasound probe was not used for transcutaneous biopsies but the patient's skin was disinfected [69]. The infections included abscesses, bacteremia, and peritonitis. There were no infections after fine-needle aspiration and thoracocentesis, while infections occurred

in 0.2% of cases after cutting needle biopsy. Infections were observed more frequently after biopsy of the pancreas (0.9%) and liver biopsy (0.3%) than after kidney biopsy (0.09%), for example [68].

In a further, mixed retrospective and prospective database analysis by the Mayo Clinic, 12 708 ultrasound-guided breast biopsies from the years 2005–2013 were evaluated. After skin disinfection, the puncture area was surrounded by sterile surgical drapes, and the ultrasound probes were disinfected with povidone iodine and a quaternary ammonium chloride solution or with isopropanol and a quaternary ammonium chloride solution. The gel was sterile. A cover was not used for the ultrasound probes. The intervention-associated infection rate was 0.11%. All infections were localized and were able to be treated with short-term oral antibiotic therapy [70].

### Infections after ultrasound-guided percutaneous placement of a drain or catheter

We could not find any prospective studies regarding infection rates after ultrasound-guided drain placement. It was problematic that drains are often placed in abscesses and empyemas. Therefore, it is difficult to determine the cause of infection (primary disease vs. intervention).

Two prospective studies examined the rate of catheter-associated bacteremia/septicemia after ultrasound-guided placement of central-venous catheters versus the "landmark technique". Puncture was performed using barrier precautions and a sterile ultrasound probe cover. A non-randomized observational study from Switzerland found an infection rate of 1.7% after ultrasound-guided placement of 844 catheters. The rate is similar to that of the "landmark technique" (2%; 33/1639). The average catheter dwell time was six and five days, respectively [71]. In another randomized study (450 patients per arm), the infection rate was significantly higher. However, it was significantly lower in the ultrasound-guided group (10.4%) than in the group without ultrasound guidance (16%). The authors attribute the reduction to the lower number of failed puncture attempts due to ultrasound guidance. The dwell time of the catheters is not specified [72].

### Infections after ultrasound-guided local ablation therapy

A large retrospective monocentric study from Italy found only 5 infections in 3035 therapeutic liver interventions in 22 years. All occurred after ethanol instillation: two early abscesses in a total of 315 cyst aspirations (0.6%) and one case of cholangitis after a total of 372 ethanol instillations of tumors (0.27%). Two "late" abscesses eight and twelve months after intervention are not to be considered procedure-related [63].

One case of ascites and sepsis (0.3%) was registered prospectively by the same working group after radiofrequency ablation (RFA) in 375 sessions. The observation period was 24 hours [73].



**CONCLUSION:**

1. Infections after ultrasound-guided freehand puncture without use of a sterile ultrasound probe cover (“no-touch” technique) could not be identified in the few available prospective studies.
2. Extensive evaluation of registry data found infections after percutaneous ultrasound-guided interventions in a total of 0.1 – 0.2 % of cases.
3. In the case of complex therapeutic interventions, the infection rate is slightly higher.
4. When placing central-venous catheters, ultrasound control seems to result in lower infection rates than the “landmark technique”.

**Rigid endoscopic ultrasound****Endorectal ultrasound**

Transrectal ultrasound (TRUS) is used to evaluate the prostate and its internal structures in that the ultrasound probe is inserted into the rectum and positioned in the immediate vicinity of the prostate. Rigid endorectal ultrasound is also used to stage rectal cancer, to evaluate fistulas, and to evaluate the pelvic floor and the sphincters.

Moreover, ultrasound-guided biopsy of the prostate, e. g. for the diagnosis of prostate cancer, is largely performed with endocavitary probes (► Fig. 5), with a puncture needle penetrating the rectal mucosa which is populated by microorganisms.

**Contamination of endorectal probes**

45 % of 60 swabs of endorectal probes in the clinical routine over three months contained microorganisms from the environment, while 3 % contained potential pathogens [27]. A relatively current metaanalysis regarding contamination of endovaginal and endorectal probes included 32 studies from 1993 – 2011. The rate of pathogenic microorganisms was almost 13 % incl. 1 % viruses (HSV, HPV, CMV) [74].

The perforation rate of the latex covers on endorectal probes is high and can be as much as 9 % after puncture [74, 75].

**Infections after endoscopic ultrasound-guided transrectal biopsy**

After transrectal prostate biopsy, infectious complications are seen in 1 – 17.5 % of cases. These are primarily urinary tract infections and prostatitis. Sepsis occurs more rarely (0.3 % – 3.1 %) [74, 76 – 83]. In a population study including 75 190 men, infections are the most common complication with a rate of 72 % [84].

According to data from the SEER registry, the risk for subsequent hospitalization due almost exclusively to infectious complications after transrectal prostate biopsy is 2.65 times higher compared to a randomly selected control population without prostate biopsy [85]. Infections with gram-negative bacteria (*E. coli*, *klebsiella*) and *clostridium* as well as with pathogens from venereal infections (e. g., *Treponema pallidum*, *Neisseria gonorrhoeae*, HIV) are primarily seen. Infections with multiresistant microor-

ganisms not included in conventional periinterventional antibiotic regimens are detected in a relevant percentage of cases with sepsis [76, 86].

In particular, the difficult-to-disinfect internal puncture channel in the probe [87] and the repeated use of the initially sterile biopsy needle are problematic here. Rectal colonization with fluoroquinolone-resistant *E. coli*, previous antibiotic treatment, a medical profession, and international travel were identified as risk factors in addition to multiple biopsy [76, 80, 88 – 91].

**Value of antibiotic prophylaxis**

Antibiotic prophylaxis lowers the rate of symptomatic infections after transrectal prostate biopsy even if it is still unclear which medications should be used and for how long [77, 92, 93]. Antibiotic prophylaxis for transrectal endoscopic ultrasound-guided prostate biopsy is included in the German and European guidelines [94, 95].

Prospective randomized studies and metaanalyses show that targeted antibiotic prophylaxis on the basis of microbiological examination of rectal swabs is more effective than standard prophylaxis [96 – 99]. Empirical combination prophylaxis is also more effective than the standard approach [92, 99, 100].

**Other preventative measures**

A metaanalysis of 7 studies and 2049 patients found a significant relative reduction in the risk for fever and bacteremia when antibiotic administration was combined with rectal enemas with a povidone-iodine solution [101]. In a prospective randomized study not included in this analysis including 865 men, only a tendency but no significant reduction in infectious complications from 3.5 % to 2.6 % could be observed [102].

The literature also includes a recommendation for formalin disinfection of the biopsy needle in multiple punctures of the prostate for reducing the risk of sepsis [103].

**CONCLUSION:**

1. The infection rate after transrectal prostate biopsy is high.
2. Rigid rectal endoscopic ultrasound probes are often contaminated after examination.

**Endovaginal ultrasound**

Transvaginal ultrasound probes are standard ultrasound equipment in gynecology and obstetrics. They are routinely used in gynecological diagnosis, in reproductive medicine, in early prenatal diagnosis, and for evaluating the fetal brain based on cephalic presentation and for evaluating the cervix and the internal cervix in advanced pregnancy. As a rule, the vaginal probe for ultrasound examination is covered with a latex cover partially filled with gel that is then removed and disposed of after the examination. Compared to simple commercial covers, condoms have a similar leakage rate [104].

The use of only a latex cover for a vaginal probe does not meet the necessary requirements for application and preparation [14].

Vaginal ultrasound probes are categorized as semi-critical medical devices of group A, i. e., they are to be prepared according to the manufacturer's specifications after every examination of a patient [14, 105, 106].

### Contamination of endovaginal probes

Cross-contamination with various pathogens (e. g. MRSA, HBV, HCV, HIV, HSV, HPV, CMV) can occur when handling the probe, ultrasound gel, and cover [6, 14, 74, 107]. Two metaanalyses describe the contamination rates of endovaginal probes:

One found a pooled endovaginal probe contamination rate of 12.9% for bacteria and 1% for viruses after "low-level disinfection". The latex covers were contaminated with viruses (HSV, CMV, HPV) in 19.4% of cases. Immediately after removal of the latex cover, the contamination rate is 33.7% [74].

The other metaanalysis found a contamination rate of the ultrasound probes of 50% for bacteria and 4% for viruses immediately after examination, with testing only for HPV being performed in most cases [104].

The ultrasound probe handle also presents a potential risk for the transmission of microorganisms. Therefore, it must always be ensured that the handle is sufficiently cleaned and disinfected [107–109].

### Infections following endovaginal ultrasound

Cases of infection from in-vitro fertilization have been reported [110–112]. These cases were infections with the patient's own vaginal flora and transmission of HCV. Large prospective studies also describe almost no infections. Therefore, there was only one case of fever and no documented infections in 1058 individual aspiration procedures [113].

#### CONCLUSION:

1. Endovaginal probes are frequently contaminated with bacteria after examination even when used correctly.
2. Only individual cases of actual infection due to microorganisms transmitted via vaginal endoscopic ultrasound have been reported.

### Ultrasound probe preparation

In the daily routine probes must be able to be cleaned and disinfected quickly and reliably to keep the time interval between examinations as low as possible. Ideally the ultrasound probe does not need to be disconnected from the ultrasound unit or brought to another room for preparation. The KRINKO-/BfArM recommendation requires a separate area for preparation which can however be in the examination room [14]. Additional important aspects are compatibility of the cleaner and disinfectant with the probe material and safety for patients and examiners.

After removal of the cover, the probe must be cleaned as well as undergo bactericidal, fungicidal, and virucidal disinfection [14, 105, 108, 114–116].

Various methods are used for disinfecting rigid endoscopic ultrasound probes: Treatment with virucidal wipes [117, 118], wipes plus foam [105], immersion disinfection methods [117, 119], a fully automatic disinfection system with hydrogen peroxide aerosol [107, 109, 120, 121] or methods in which UV-C radiation is used [122, 123]. While most bacteria but not always all viruses and no bacterial spores are killed when using wipes alone, all microorganisms, including some bacterial spores, are inactivated with the other methods. The current WFUMB guidelines regarding the preparation of endovaginal probes provides an overview [105].

It was shown that the reduction in test organisms with simple wipe disinfection is not always sufficient. This was due to joints, grooves, and corners that cannot be sufficiently reached and cleaned with a wipe [107].

In addition, it was able to be shown that various disinfection liquids used in the immersion method, e. g. glutaraldehyde, orthophthalaldehyde, ethanol, isopropanol and phenol, were not able to inactivate HPV 16 [117, 119, 121, 123]. Immersion disinfection methods take the longest treatment time (at least 15 min) and there is an inhalation health risk in poorly ventilated rooms [105, 120].

#### CONCLUSION:

1. Various methods can be used for disinfecting rigid endoscopic ultrasound probes.
2. Disinfection with simple wiping without ensuring that the disinfectant reaches joints and edges does not provide sufficient disinfection in the case of rigid endoscopic ultrasound probes.

### Flexible endoscopic ultrasound

Since endoscopic ultrasound units are inserted through digestive and respiratory tracts populated by microorganisms, bacterial translocation of local flora (primarily alpha hemolytic streptococci and staphylococci) can occur. In an overview regarding the safety of transesophageal echocardiography (TEE), bacteremia rates of 0–17% are specified [124]. In the case of gastrointestinal diagnostic endoscopic ultrasound without intervention, cases of transient bacteremia are registered in approximately 2% of all cases without clinical signs of infection being observed in prospective studies [125, 126]. Apparent infections as complications of noninvasive endoscopic ultrasound are rare and only described in case histories. For example for TEE, legionella infections from contaminated water [127] and *E. coli* pneumonia from an echoendoscope with a defective outer layer have been reported [128].

Endoscopic ultrasound interventions have become an indispensable part of visceral medicine and oncology diagnosis and treatment. According to data of the German Endoscopic Ultrasound Registry of DEGUM, endoscopic ultrasound-guided fine needle aspiration (EUS-FNA) or fine needle biopsy is performed in approximately 13% of all endoscopic ultrasound examinations (EUS) and a therapeutic intervention is performed in almost 3% of cases. All of these interventions have in common that an instru-

ment inserted through the instrument channel contaminated with the bacterial flora of the tracheobronchial system, esophagus, stomach, duodenum or rectum is inserted transmurally into a primarily sterile compartment or also into an infected cavity (necrosis, abscess, empyema). In the case of various puncture and intervention targets, passage of the needle through the peritoneal or pleural cavity cannot be avoided.

A small study (n = 43) showed contamination of endobronchial ultrasound-guided transbronchial aspiration needles (EBUS-TBNA) with local oropharyngeal flora in 15 cases (35%) [129]. Mechanical transmural translocation of local flora is thus a possible epiphenomenon of endoscopic ultrasound interventions. In contrast to percutaneous ultrasound-guided interventions, neither disinfection nor barrier precautions [8, 21, 130, 131] are possible or productive.

### Bacteremia after EUS-FNA and EBUS-TBNA

Three prospective studies with a total of 202 patients examined the rate of bacteremia and infections after EUS-FNA in the upper digestive tract. Bacteremia caused by pathogens that were probably not the result of contamination of the blood cultures was observed in five patients (2.5%). Clinical signs of infection did not occur [125, 126, 132].

The bacteremia rate of 1–2% in prospective studies was comparably low even after EUS-FNA of the lower digestive tract [125, 133, 134]. A bacteremia rate after endoscopic ultrasound of 15% (12% after EUS without FNA, 6% after EUS-FNA) was seen in a small population of 41 patients with liver cirrhosis [135]. A bacteremia rate of 7% was reported for EBUS-TBNA in a small study [129]. These bacteremia rates are in a range that was also reported for flexible bronchoscopy and flexible esophagogastroduodenoscopy (1–7%) [129]. In a prospective animal experiment, the rate of bacteremia after EUS-FNA was not affected by the use of a 0.5% povidone-iodine solution for moistening the mucosa or by temporary treatment with the proton pump inhibitor omeprazole (40 mg/day) [136].

### Fever and infections after EUS-FNA and EBUS-TBNA

A systematic review of 51 studies published by December 2007 regarding EUS-FNA including 10 941 patients found an average complication rate of 0.98% and even 1.72% in prospective studies. Transient fever occurred in 12 cases, and infections in 5 cases (11.2% and 4.7% of all complications, respectively). This corresponds to an incidence of 0.1% (fever) and 0.046% (infection) [137]. In major case series, transient episodes of fever following transduodenal or transgastral EUS-FNA of solid pancreatic lesions were observed in 0.4–1% of patients [138]. After EUS-FNA of the lower digestive tract, episodes of fever occurred in only 0.89% of cases in a large case series [133]. Prospective studies did not find a relevant infection risk after transrectal EUS-FNA. However, the study protocols always included prior complete bowel cleansing as for a colonoscopy [133, 134, 139, 140].

### Mediastinal lymph nodes and tumors

For mediastinal endoscopic ultrasound-guided fine needle aspiration (EUS-FNA and EBUS-TBNA), the cumulative infection rate in a

metaanalysis of 190 studies (16 181 patients) was 0.07% with infectious complications being less common after EBUS-TBNA (0.02%) than after EUS-FNA (0.17%) [141]. However, a multicenter survey analysis from Japan showed a risk of infectious complications and fever after EBUS-TBNA of 0.24%, which was comparable to that of EUS-FNA. The complications included mediastinitis in 0.1%, pneumonia in 0.05%, self-limiting fever in 0.05%, and other infectious complications in 0.03% [142]. A Korean study analyzing 552 EBUS-TBNA procedures reported infectious complications in 0.54% of cases. However, transient fever was observed in a total of 20% of all patients [143]. Comparable data with a rate of severe infectious complications after EBUS-TBNA of 0.16% was reported by three Turkish centers [144].

An overview from the year 2012 included twelve published cases of severe infectious complications after transesophageal EUS-FNA of mediastinal lymph nodes, including ten cases of mediastinitis. Five of these cases occurred in patients with sarcoidosis [138]. The results of a survey in Holland including all 14 075 patients who underwent EUS-FNA of mediastinal lymph nodes between 1999 and 2011 in 89 Dutch hospitals provides a good starting point for the rate of severe infectious complications after EUS-FNA of mediastinal target structures. Severe complications occurred in 22 patients (0.16%) including 15 (0.1%) of an infectious nature (mediastinitis, mediastinal abscess, pleural empyema). There were three deaths as a result of infectious complications, exclusively in patients with a poor performance status [145]. Sarcoidosis may be a risk factor for mediastinal lymph node enlargement. Two centers in Holland reported five cases of mediastinal abscesses after EUS-FNA or EBUS-TBNA in 252 patients with mediastinal lymph node sarcoidosis (2%). A systematic overview from the year 2017 included 17 published cases of mediastinitis and/or pericarditis after EBUS-TBNA [146].

### Subepithelial tumors

The development of intratumoral abscesses after endoscopic ultrasound-guided biopsy of large gastrointestinal stromal tumors was reported in five cases with a fatality in one case [147–150].

### Cystic lesions and edema

The infection risk after EUS-FNA of cystic lesions is significantly higher than after EUS-FNA of solid lesions. It was able to be shown in experiments that EUS-FNA of a container filled with a culture medium through beef tripe contaminated by bacteria resulted in growth in the culture medium in 100% of cases. The transmission risk could be reduced to 20% by treating the tripe with 5% povidone iodine while cleaning with water, chlorhexidine, and high-proof alcohol was not effective [151]. A systematic review found fever and infectious complications in only 0.05% of cases after EUS-FNA of solid pancreatic lesions, but in 0.55% of cases after EUS-FNA of cystic pancreatic lesions even though almost 94% of the included patients with cystic pancreatic lesions received peri-interventional antibiotic prophylaxis [137]. In a current metaanalysis of the risk of EUS-FNA of cystic pancreatic lesions (40 studies including 56 124 patients), the infection rate was 0.44% [152].

The risk of severe infectious complications after EUS-FNA and EBUS-TBNA of cystic mediastinal lesions seems particularly high.

An overview from the year 2012 included eight cases in which mediastinitis occurred after EUS-FNA of mediastinal cysts. Three of these cases occurred in spite of the periinterventional administration of antibiotics [138]. Three additional cases were reported by 2015 [153, 154]. Severe infections were also reported after EBUS-TBNA of mediastinal cysts [141, 144, 155, 156]. It must be taken into consideration that bronchogenic cysts are often relatively dense and contain material that is not anechoic and therefore can be misinterpreted as solid mediastinal lesions on CT and endoscopic ultrasound [155, 157, 158].

EUS-FNA of ascites also has a particular infection risk that probably also applies to pleural and pericardial effusions [138]. One case of death due to sepsis was reported after EUS-FNA of a liver lesion in a patient with untreated obstructive cholestasis probably due to contamination of an obstructed intrahepatic bile duct [159].

### Value of antibiotic prophylaxis

Professional societies such as the European Society for Gastrointestinal Endoscopy (ESGE), the American Society for Gastrointestinal Endoscopy (ASGE), the EFSUMB and the German Society for Gastroenterology, Digestive and Metabolic Diseases (DGVS) recommend periinterventional antibiotic prophylaxis prior to EUS-FNA of cystic pancreatic lesions or generally before transintestinal puncture of cysts and edema [160–163] and evaluate this as a quality indicator in some cases [161, 164, 165]. However, these recommendations are based less on verified evidence than on indirect conclusions and expert opinion. Prospective controlled comparisons are not available.

A retrospective comparative study and a metaanalysis did not show a difference in the rate of cyst infections with and without antibiotic prophylaxis [152, 166]. Three- to five-day oral treatment with gyrase inhibitors or beta-lactam antibiotics is largely used after initial intravenous administration immediately before and during intervention. In retrospective studies, no cyst infection was observed even after intravenous single-shot application of ceftriaxone [167], ciprofloxacin and piperacillin/tazobactam [168] in larger patient populations.

EUS-FNA of mediastinal cysts is considered contraindicated by the DGVS and the EFSUMB guidelines (“should be avoided”) [161, 162].

General antibiotic prophylaxis is not recommended in EUS-FNA, EBUS-TBNA and transrectal EUS-FNA of solid lesions [160–163]. Antibiotic prophylaxis can be considered in individual cases when the needle must pass through bile or pancreatic ducts [139], the needle will touch large necrotic areas within the tumor/lymph node, or the patient is immunocompromised.

### Other preventative measures

By using contrast-enhanced endoscopic ultrasound, necrotic areas can be identified within solid lesions [169–172]. To minimize the risk of infection, it seems useful particularly in large, inhomogeneous solid lesions and in possibly cystic lesions containing material that is not anechoic to perform contrast-enhanced endoscopic ultrasound in order to be able to avoid transmural

puncture of cystic or necrotic areas or to be able to initiate immediate postinterventional antibiotic therapy [138, 162].

Since the risk of infection after EUS-FNA of solid lesions is very low even when performing multiple puncture procedures with a single needle (up to seven needle punctures in solid pancreatic lesions), it is not necessary to change the needle to prevent infection.

Local application of disinfecting substances prior to EUS-FNA, as proposed by an group of authors on the basis of experimental data [151], has not yet been evaluated in studies and does not play a role in clinical practice and in guideline recommendations.

Cystic lesions should be completely drained during puncture [139].

In centers with corresponding expertise, complete colon cleansing is generally performed prior to transrectal or transcolic EUS-FNA [139].

EUS-FNA of liver lesions in untreated obstructive cholestasis should be generally avoided [138, 139].

In patients with clinically relevant bronchopulmonary infections, EBUS-TBNA should only be performed after the infection has been managed.

### Fever and infections after endoscopic ultrasound-guided therapeutic interventions

Compared to endoscopic ultrasound-guided fine needle aspiration, endoscopic ultrasound-guided therapeutic interventions are associated with a higher infection risk. This is true for injection, implantation, and drainage procedures. In addition to procedure-related factors (implants remaining in the body, injection of immunosuppressive drugs and glucocorticoids and other fluids), patient factors are also a contributing factor because many of these methods are used particularly in tumor patients for palliative care [162, 173].

### Injection and implantation procedures

After endoscopic ultrasound-guided blockade of the celiac plexus with triamcinolone, retroperitoneal abscesses were described in four cases and pleural empyema in three, while endoscopic ultrasound-guided neurolysis of the plexus with high-proof alcohol does not seem to have a relevant infection risk [173]. Due to the relatively small number of cases in the available studies, definitive data regarding the risk of further EUS-guided injection and implantation procedures is not available [174, 175].

### Drainage procedures

In expert hands, transmural endoscopic ultrasound-guided drainage of pancreatic pseudocysts, biliomas, and of demarcated (peri-) pancreatic necroses and peri-intestinal abscesses is a relatively safe intervention. However, there is a relevant risk of secondary infections due to occlusion or migration of the implanted plastic or metal stents of 4% (0–26%) in pseudocyst drainage or necrosis drainage and of approx. 2% in biliary drainage [173–176]. To prevent infections, the creation of sufficiently wide and stable transmural accesses and a sufficiently long drainage duration are therefore recommended in endoscopic ultrasound-guided drainage interventions [161, 174].

## Value of antibiotic prophylaxis

For endoscopic ultrasound-guided drainage procedures and blockade of the celiac plexus, the DGVS and EFSUMB generally recommend antibiotic prophylaxis due to the relevant infection risk even though there are no prospective studies showing a reduction of the infection risk as a result of the periinterventional administration of antibiotics [161, 162, 174].

### CONCLUSION:

1. Infectious complications of EUS-FNA and EBUS-TBNA are probably primarily the result of translocation of the oropharyngeal or rectal bacterial flora. They are very rare in fine needle puncture of solid lesions but occur approximately 10 times more often in the puncture of cysts, effusions, and edema. There is a relevant infection risk in selected endoscopic ultrasound-guided transmural interventions.
2. Endoscopic ultrasound-guided fine needle puncture of cystic mediastinal lesions and solid liver lesions in the case of untreated obstructive cholestasis can result in severe infections. Puncture of necrotic areas in solid lesions should be avoided.
3. When puncturing cystic/liquid lesions, complete draining of the lesion via complete aspiration of the lesion (diagnostic puncture) and ensuring sufficiently wide, stable, and long-term transmural accesses (therapy) should be targeted with the goal of minimizing the risk of infection.
4. There is no data regarding periinterventional antibiotic administration in diagnostic endoscopic ultrasound-guided puncture of cystic pancreatic lesions and in endoscopic ultrasound-guided drainage procedures (pseudocysts, abscesses, necroses, obstructed bile and pancreatic ducts). However, this is recommended by professional societies.

## Intraoperative ultrasound

Ultrasound probes are inserted into open body cavities during intraoperative ultrasound. There are no known publications regarding infections in this regard. According to EFSUMB and the KRINKO/BfArM recommendations, intraoperative probes must be sterile [14, 21]. The probes are thermolabile and can only be treated with low-temperature sterilization [16]. This limits their availability.

If these sterilization procedures are not available, scientists from Australia [177] recommend immersion disinfection of the ultrasound probe with a bactericidal (including mycobacteria), fungicidal, and virucidal product (“high-level disinfection”) followed by application of a sterile ultrasound probe cover. The guidelines of the French Radiology Society recommend disinfection with a bactericidal (including mycobacteria), fungicidal, virucidal, and sporicidal product when sterilization is not possible [38].

## DEGUM recommendations

Some points of the hygiene requirements for individual ultrasound-guided procedures in the four risk groups of KRINKO (► **Tab. 1**) must be scrutinized. Therefore, in the authors’ opinion, a number of organ and joint punctures without the need for temporarily setting down tools (e. g. to change the syringe) fulfill the definitions of risk group 1 (breast biopsy) or 2 (uncomplicated diagnostic organ biopsy) but are categorized by KRINKO as group 3 even without infections described in the literature [13]. Moreover, if it is not necessary to set down tools during puncture, a sterile drape/incise drape is not needed even in group 3.

In particular for ultrasound-guided freehand puncture without contact between the needle and the ultrasound probe, a sterile ultrasound probe cover can be dispensed with based on the data from prospective [66, 67] and large retrospective studies [68, 70] and based on guidelines [17]. This is in concordance with the KRINKO recommendations [13].

It is not apparent why the examiner is supposed to wear sterile gloves during transvaginal puncture.

The restriction to alcohol-based skin disinfectants as an alternative to sterile ultrasound gel [13, 15] could be problematic in light of the presumed harmfulness to ultrasound probe surfaces [26, 178]. However, other authors did not see any subjective worsening of image quality with repeated use of alcohol [179]. In addition, a differentiation must be made between skin disinfection and the subsequent use of a coupling medium: effective skin disinfection requires drying of the disinfectant. Therefore, an alcohol-based disinfectant can be used for this purpose. In our opinion, there is no reason not to use non-alcohol-based skin disinfectants as the contact medium.

► **Table 3** provides an overview of ultrasound-guided puncture and the recommended measures for the ultrasound probe, for barrier precautions, and protective clothing.

### General

1. Hygienic hand disinfection by the examiner before and after the examination is a basic hygiene requirement. (Unanimous consensus)
2. Prior to intraoperative ultrasound, the examiner should perform surgical hand disinfection. (Unanimous consensus)
3. Every facility performing ultrasound should define its hygiene measures in a hygiene plan. (Unanimous consensus)
4. Ultrasound probe manufacturers are legally required to specify suitable, validated cleaning and disinfection methods. If the specified disinfectant does not have the spectrum of activity specified below, examiners should request information about suitable methods from the manufacturer (unanimous consensus).

### Use: Percutaneous interventional ultrasound

1. Prior to every ultrasound-guided intervention, the patient’s skin must be disinfected. (Unanimous consensus)
2. In interventions, only sterile ultrasound gel or a skin disinfectant should be used as the contact medium. (Unanimous consensus)

► **Table 3** DEGUM recommendations on ultrasound probe treatment, barrier precautions and protective clothing for various ultrasound procedures.

ultrasound procedure	examples	ultrasound probe	contact medium	barrier precaution	protective clothing	
					examiner	assistance
diagnostic percutaneous ultrasound	abdominal ultrasound	cleaned and disinfected	normal gel	none	none	none
diagnostic ultrasound with contact with mucosa or wound	introtitus ultrasound, postoperative ultrasound	cleaned and disinfected and with sterile cover	sterile gel under the cover, sterile gel or mucosa disinfectant on the skin	none	low-germ gloves	not required
simple diagnostic puncture without the need to set down tools or change the syringe	organ biopsy, diagnostic pleural or ascites puncture, simple joint puncture peripheral indwelling venous cannula, "single-shot" regional anesthesia	cleaned and disinfected and without cover if contact with the needle can be ruled out.	sterile gel or disinfectant	none	low-germ gloves	not required
complex diagnostic puncture with syringe change; drainage using direct puncture technique	single puncture of cysts, abscesses, joint puncture, "single-shot" regional anesthesia, suprapubic bladder fistula, pleural or abscess drainage	cleaned and disinfected with sterile cover	sterile gel under the cover, sterile gel or disinfectant on the skin	none	sterile gloves	not required
insertion of a drain using the Seldinger technique; therapeutic interventions	placing of a central venous catheter pleural or abscess drainage, continuous regional anesthesia, local ablation therapies	cleaned and disinfected with sterile cover	sterile gel under the cover, sterile gel or disinfectant on the skin	sterile drape/incise drape	sterile gloves, surgical mask	sterile gloves in the case of active participation
EUS-guided puncture, rigid EUS probe	transrectal prostate biopsy, transvaginal puncture	cleaned and disinfected and with low-germ cover	normal gel under the cover	none	sterile gloves, surgical mask, surgical cap, sterile long-sleeve gown	sterile gloves, surgical mask, surgical cap, sterile long-sleeve gown in the case of active participation
EUS-guided puncture, flexible EUS probe	EUS pancreatic biopsy	prepared like endoscope	not applicable	none	low-germ gloves, long-sleeve gown	low-germ gloves, long-sleeve gown

- If the ultrasound probe can come into contact with the sterile puncture needle, a sterile probe cover should be used and sterile gloves should be worn. (Unanimous consensus)
- In simple punctures not requiring tools to be set down, a sterile drape/incise drape is not necessary. (Strong consensus)
- Needle holders applied to the ultrasound probe should be affixed under the sterile cover or should be sterile. Needle guides should be used exclusively as sterile (disposable) products. (Unanimous consensus)
- When inserting catheters, performing therapeutic interventions such as PEI or RFA or performing measures including, for example, change of the syringe during an intervention, barrier precautions are required. (Unanimous consensus)

### Preparation: Probes in contact with skin or mucosa, with or without intervention

- Ultrasound probes must be cleaned after every examination but cleaning alone is not sufficient. Disinfectant solutions must additionally be used. (Unanimous consensus)
- In the case of probes with complex surfaces (grooves, notches), both the cleaner and disinfectant must be properly applied to these recesses. (Unanimous consensus)
- The necessary spectrum of activity of the disinfectant to be used is based on the classification (planned application) of the ultrasound probe.
  - Non-critical: bactericidal and yeasticidal activity
  - Semi-critical: bactericidal (including mycobacteria), yeasticidal, fungicidal, and virucidal activity (unanimous consensus)
- Ultrasound probes with a puncture channel should be sterilized. (Strong consensus)

### Use: Endoscopic ultrasound probes

- For rigid endoscopic ultrasound probes (endorectal, endovaginal), the use of low-germ covers is recommended. (Strong consensus)
- For rigid and flexible endoscopic ultrasound probes, only sterile disposable puncture and intervention platforms should be used. (Unanimous consensus)
- Periinterventional administration of antibiotics is essential in transrectal prostate biopsy. (Unanimous consensus)
- In transrectal prostate biopsy, combined prophylaxis (antibiotic plus povidone-iodine enema) or targeted antibiotic prophylaxis based on rectal swabs can be considered in risk patients or in the case of high postinterventional infection rates. (Unanimous consensus)

### Preparation: Endoscopic ultrasound probes

- Rigid endoscopic ultrasound probes must be cleaned after every examination and a suitable disinfection procedure must also be performed. (Unanimous consensus)
- In the case of probes with complex surfaces (grooves, notches), both the cleaner and disinfectant must be properly applied to these recesses. (Unanimous consensus)
- Flexible endoscopic ultrasound probes are prepared analogously to other flexible endoscopes (validated cleaning and

machine chemothermal disinfection methods). (Strong consensus)

- Endoscopic ultrasound probes are semi-critical medical devices. The disinfectant must therefore have bactericidal (including mycobacteria), fungicidal, and virucidal activity. (Strong consensus)

### Use: Intraoperative ultrasound

- Sterile probes can be used without an ultrasound probe cover. (Strong consensus)
- A cleaned and disinfected probe must be provided with a sterile cover. (Unanimous consensus)
- Only sterile ultrasound gel can be used as the contact medium within the cover. (Unanimous consensus)
- Only a sterile fluid can be used as the contact medium outside the cover. (Unanimous consensus)

### Preparation: Intraoperative probes

- Ultrasound probes must be cleaned after every examination and a suitable disinfection procedure must also be performed. (Unanimous consensus)
- In the case of probes with complex surfaces (grooves, notches), both the cleaner and disinfectant must be properly applied to these recesses. (Unanimous consensus)
- As a rule, intraoperative probes must be sterilized. (Strong consensus)
- If sterilization is not available, immersion disinfection can be performed. (Strong consensus)
- Ultrasound probes used intraoperatively are critical medical devices. The disinfectant to be used must have a bactericidal, fungicidal, and limited virucidal spectrum of activity if subsequent sterilization is performed. (Strong consensus)
- If sterilization is not possible, the disinfectant must have a bactericidal (including mycobacteria), yeasticidal, fungicidal, and virucidal (sporicidal) spectrum of activity and final rinsing with sterile or sterile filtered water must also be performed. (Strong consensus)

### ABBREVIATIONS

ASGE	American Society for Gastrointestinal Endoscopy
AWMF	Association of the Scientific Medical Societies in Germany
BfArM	Federal Institute for Drugs and Medical Devices
CMV	Cytomegalovirus
DEGUM	German Society for Ultrasound in Medicine
DGVS	German Society for Gastroenterology, Digestive and Metabolic Diseases
EBUS	Endobronchial ultrasound
EFSUMB	European Federation of Societies for Ultrasound in Medicine and Biology
ESGE	European Society for Gastrointestinal Endoscopy
ESR	European Society of Radiology
EU	European Union
EUS	Endoscopic ultrasound
FNA	Fine needle aspiration

HBV	Hepatitis-B virus
HCV	Hepatitis-C virus
HIV	Human immunodeficiency virus
HPV	Human papilloma virus
IfSG	German Protection against Infection Act
CFU	Colony-forming units
KRINKO	Commission for Hospital Hygiene and Infection Prevention
MPG	Medical Devices Act
MRSA	Methicillin-resistant Staphylococcus aureus
PIUS	Percutaneous interventional ultrasound
RFA	Radiofrequency ablation
RKI	Robert Koch Institute
SEER	Surveillance Epidemiology and End Results
TBNA	Transbronchial needle aspiration
TEE	Transesophageal echocardiography
TRUS	Transrectal ultrasound
UV C	UV radiation of category C
WFUMB	World Federation for Ultrasound in Medicine and Biology

## Conflict of Interest

Heiko Dudwiesus is a former employee of GE Healthcare. The other authors declare that they have no conflict of interest.

## References

- [1] Dietrich CF, Nürnberg D (Hrsg) Interventioneller Ultraschall. Lehrbuch und Atlas für die interventionelle Sonografie. Stuttgart: Thieme; 2011
- [2] Hillmann R, Döffert J. Praxis der anästhesiologischen Sonografie. München: Elsevier; 2016
- [3] Kähler C, Gembruch U, Heling KS et al. Empfehlungen der DEGUM zur Durchführung von Amniozentese und Chorionzottenbiopsie. Ultraschall in Med 2013; 34: 435–440
- [4] Müller T, Blank W. Sonografisch gesteuerte perkutane Punktionen und Therapieverfahren. In: Braun B, Günther R, Schwert WB, (Ed.) Ultraschalldiagnostik. Lehrbuch und Atlas. Landsberg: ecomed; 2011. bk. 47. Ergänzungslieferung, 1–96
- [5] Marhofer P, Schebesta K, Marhofer D. Hygieneaspekte in der ultraschall-gestützten Regionalanästhesie. Anaesthesist 2016; 65: 492–498
- [6] Merz E. Transducer hygiene – an underrated topic? Ultraschall in Med 2005; 26: 7–8
- [7] Shokoohi H, Armstrong P, Tansek R. Emergency department ultrasound probe infection control: challenges and solutions. Open Access Emerg Med OAEM 2015; 7: 1–9
- [8] Nyhsen CM, Humphreys H, Nicolau C et al. Infection prevention and ultrasound probe decontamination practices in Europe: a survey of the European Society of Radiology. Insights Imaging 2016; 7: 841–847
- [9] Infektionsschutzgesetz. <https://www.gesetze-im-internet.de/bundesrecht/ifsg/gesamt.pdf> Letzter Zugriff 27.12.2017
- [10] Medizinproduktegesetz. <https://www.gesetze-im-internet.de/mpg/> Letzter Zugriff 27.12.2017
- [11] Richtlinie 93/42/EWG des Rates vom 14. Juni 1993 über Medizinprodukte. <http://eur-lex.europa.eu/legal-content/DE/TXT/?uri=celex%3A31993L0042> Letzter Zugriff 27.12.2017
- [12] Verordnung über das Errichten, Betreiben und Anwenden von Medizinprodukten (Medizinprodukte-Betreiberverordnung – MPBetreibV). <https://www.gesetze-im-internet.de/mpbetreibv/MPBetreibV.pdf> Letzter Zugriff 27.12.2017
- [13] KRINKO. Anforderungen an die Hygiene bei Punktionen und Injektionen. Bundesgesundheitsbl. 2011; 54: 1135–1144
- [14] KRINKO/BfArM. Anforderungen an die Hygiene bei der Aufbereitung von Medizinprodukten. Bundesgesundheitsbl. 2012; 55: 1244–1310
- [15] KRINKO. Prävention von Infektionen, die von Gefäßkathetern ausgehen: Teil 1 – Nichtgetunnelte zentralvenöse Katheter Empfehlung der Kommission für Krankenhaushygiene und Infektionsprävention (KRINKO) beim Robert Koch-Institut. Bundesgesundheitsbl. 2017; 60: 171–206
- [16] Amann B, Appel T, Aravopouou F et al. Aufbereitung von Ultraschallsonden. Zentralsterilisation. 2017; 3: 195–197
- [17] Arbeitskreis "Krankenhaus- & Praxishygiene" der AWMF. Intraartikuläre Punktionen und Injektionen: Hygienemaßnahmen. AWMF-Register Nr. 029/006, S1-Leitlinie. Hyg Med 2015; 40: 366–368
- [18] Arbeitskreis "Krankenhaus- & Praxishygiene" der AWMF. Hygienemaßnahmen bei intravasalen Punktionen und intravasaler Medikamentenapplikation. AWMF-Register Nr. 029/015, S1-Leitlinie. Hyg Med 2016; 41: 227–229
- [19] Deutsche Gesellschaft für Krankenhaushygiene e. V. Hinweise für die Aufbereitung ausgewählter semikritischer Medizinprodukte. Hyg Med 2016; 41: 317–318
- [20] Kerwat K, Schulz-Stübner S, Steinfeldt T et al. Hygieneempfehlungen für die Regionalanästhesie. Anasthesiol Intensivmed Notfallmed Schmerzther 2015; 56: 34–40
- [21] Lorentzen T, Nolsøe CP, Ewertsen C et al. EFSUMB Guidelines on Interventional Ultrasound (INVUS), Part I. General Aspects (long Version). Ultraschall in Med 2015; 36: E1–E14
- [22] Sanz GE, Theoret J, Liao MM et al. Bacterial contamination and cleanliness of emergency department ultrasound probes. CJEM 2011; 13: 384–389
- [23] Ridge C. Sonographers and the Fight Against Nosocomial Infections: How Are We Doing? J Diagn Med Sonogr 2005; 21: 7–11
- [24] Lawrence MW, Blanks J, Ayala R et al. Hospital-wide survey of bacterial contamination of point-of-care ultrasound probes and coupling gel. J Ultrasound Med 2014; 33: 457–462
- [25] Frazee BW, Fahimi J, Lambert L et al. Emergency department ultrasonographic probe contamination and experimental model of probe disinfection. Ann Emerg Med 2011; 58: 56–63
- [26] Fowler C, McCracken D. US probes: risk of cross infection and ways to reduce it—comparison of cleaning methods. Radiology 1999; 213: 299–300
- [27] Sykes A, Appleby M, Perry J et al. An investigation of the microbiological contamination of ultrasound equipment. Br J Infect Control 2006; 7: 16–20
- [28] Schneider D. Untersuchungen zur Kontamination von transdermalen Ultraschallsonden im klinischen Alltag in Verbindung mit einem Review zur Kontamination von Ultraschallsonden und der klinischen Relevanz. Dissertation. Greifswald, 2013 <http://d-nb.info/1041903901>
- [29] Westerway SC, Basseal JM, Brockway A et al. Potential Infection Control Risks Associated with Ultrasound Equipment – A Bacterial Perspective. Ultrasound Med Biol 2017; 43: 421–426
- [30] Skowronek P, Wojciechowski A, Leszczyński P et al. Can diagnostic ultrasound scanners be a potential vector of opportunistic bacterial infection? Med Ultrason 2016; 18: 326–331
- [31] Sartoretti T, Sartoretti E, Bucher C et al. Bacterial contamination of ultrasound probes in different radiological institutions before and after specific hygiene training: do we have a general hygienical problem? Eur Radiol 2017; 27: 4181–4187



- [32] Rutala W, Weber D. Guideline for disinfection and sterilization in healthcare facilities. <https://stacks.cdc.gov/view/cdc/11560> Letzter Zugriff 27.12.2017
- [33] Middendorf M. Haftungsrechtliche Aspekte der Krankenhaushygiene nach der Reform des Infektionsschutzgesetzes. *Krankenhaushygiene Up2date* 2011; 6: 313–321
- [34] KRINKO. Händehygiene in Einrichtungen des Gesundheitswesens. *Bundesgesundheitsbl.* 2016; 59: 1189–1220
- [35] Heudorf U, Hofmann H, Kutzke G et al. Aufbereitung von Ultraschallsonden im Krankenhaus – ein nicht zu vernachlässigendes Thema. *Hyg Med* 2007; 32: 183–186
- [36] KBV. Vereinbarung von Qualitätssicherungsmaßnahmen nach § 135 Abs. 2 SGB V zur Ultraschalldiagnostik (Ultraschall-Vereinbarung). <http://www.kbv.de/media/sp/Ultraschallvereinbarung.pdf> Letzter Zugriff 27.12.2017
- [37] McDonnell G, Burke P. Disinfection: is it time to reconsider Spaulding? *J Hosp Infect* 2011; 78: 163–170
- [38] Malavaud S, Joffre F, Auriol J et al. Hygiene recommendations for interventional radiology. *Diagn Interv Imaging* 2012; 93: 813–822
- [39] O'doherty AJ, Murphy PG, Curran RA. Risk of *Staphylococcus aureus* transmission during ultrasound investigation. *J Ultrasound Med* 1989; 8: 619–620
- [40] Chittick P, Russo V, Sims M et al. An outbreak of *Pseudomonas aeruginosa* respiratory tract infections associated with intrinsically contaminated ultrasound transmission gel. *Infect Control Hosp Epidemiol* 2013; 34: 850–853
- [41] Cheng A, Sheng WH, Huang YC et al. Prolonged postprocedural outbreak of *Mycobacterium massiliense* infections associated with ultrasound transmission gel. *Clin Microbiol Infect* 2016; 22: 382.e1–382.e11
- [42] Hutchinson J, Runge W, Mulvey M et al. *Burkholderia cepacia* infections associated with intrinsically contaminated ultrasound gel: the role of microbial degradation of parabens. *Infect Control Hosp Epidemiol* 2004; 25: 291–296
- [43] Marigliano A, D'Errico MM, Pellegrini I et al. Ultrasound echocardiographic gel contamination by *Burkholderia cepacia* in an Italian hospital. *J Hosp Infect* 2010; 76: 360–361
- [44] Provenzano DA, Liebert MA, Steen B et al. Investigation of current infection-control practices for ultrasound coupling gel: a survey, microbiological analysis, and examination of practice patterns. *Reg Anesth Pain Med* 2013; 38: 415–424
- [45] Olshtain-Pops K, Block C, Temper V et al. An outbreak of achromobacter xylosoxidans associated with ultrasound gel used during transrectal ultrasound guided prostate biopsy. *J Urol* 2011; 185: 144–147
- [46] Weist K, Wendt C, Petersen LR et al. An outbreak of pyoderma among neonates caused by ultrasound gel contaminated with methicillin-susceptible *Staphylococcus aureus*. *Infect Control Hosp Epidemiol* 2000; 21: 761–764
- [47] Spratt HG, Levine D, Tillman L. Physical therapy clinic therapeutic ultrasound equipment as a source for bacterial contamination. *Physiother Theory Pract* 2014; 30: 507–511
- [48] Gaillot O, Maruéjols C, Abachin E et al. Nosocomial outbreak of *Klebsiella pneumoniae* producing SHV-5 extended-spectrum beta-lactamase, originating from a contaminated ultrasonography coupling gel. *J Clin Microbiol* 1998; 36: 1357–1360
- [49] Schabrun S, Chipchase L, Rickard H. Are therapeutic ultrasound units a potential vector for nosocomial infection? *Physiother Res Int* 2006; 11: 61–71
- [50] Oleszkowicz SC, Chittick P, Russo V et al. Infections associated with use of ultrasound transmission gel: proposed guidelines to minimize risk. *Infect Control Hosp Epidemiol* 2012; 33: 1235–1237
- [51] Belavy D. Brief reports: regional anesthesia needles can introduce ultrasound gel into tissues. *Anesth Analg* 2010; 111: 811–812
- [52] Ejtehad F, Ejtehad F, Teb JC et al. A safe and practical decontamination method to reduce the risk of bacterial colonization of ultrasound transducers. *J Clin Ultrasound* 2014; 42: 395–398
- [53] Bello TO, Taiwo SS, Oparinde DP et al. Risk of nosocomial bacteria transmission: evaluation of cleaning methods of probes used for routine ultrasonography. *West Afr J Med* 2005; 24: 167–170
- [54] Chu K, Obaid H, Babyn P et al. Bacterial contamination of ultrasound probes at a tertiary referral university medical center. *Am J Roentgenol* 2014; 203: 928–932
- [55] Chuan A, Tiong C, Maley M et al. Decontamination of ultrasound equipment used for peripheral ultrasound-guided regional anaesthesia. *Anaesth Intensive Care* 2013; 41: 529–534
- [56] Kac G, Gueneret M, Rodi A et al. Evaluation of a new disinfection procedure for ultrasound probes using ultraviolet light. *J Hosp Infect* 2007; 65: 163–168
- [57] Savasci U, Oren NC, Akpak YK et al. Comparison of probe disinfection procedures in routine ultrasonography: hot water versus antiseptic wiping. *Intern Med Tokyo Jpn* 2014; 53: 2201–2204
- [58] Adhikari S, Blaivas M, Morrison D et al. Comparison of infection rates among ultrasound-guided versus traditionally placed peripheral intravenous lines. *J Ultrasound Med* 2010; 29: 741–747
- [59] Alakkad H, Naeeni A, Chan VWS et al. Infection related to ultrasound-guided single-injection peripheral nerve blockade: a decade of experience at Toronto Western hospital. *Reg Anesth Pain Med* 2015; 40: 82–84
- [60] González-Michaca L, Chew-Wong A, Soltero L et al. Percutaneous kidney biopsy, analysis of 26 years: complication rate and risk factors; comment. *Rev Investig Clin Organo Hosp Enfermedades Nutr* 2000; 52: 125–131
- [61] Nolsøe C, Nielsen L, Torp-Pedersen S et al. Major complications and deaths due to interventional ultrasonography: a review of 8000 cases. *J Clin Ultrasound JCU* 1990; 18: 179–184
- [62] Piccinino F, Sagnelli E, Pasquale G et al. Complications following percutaneous liver biopsy. A multicentre retrospective study on 68276 biopsies. *J Hepatol* 1986; 2: 165–173
- [63] Giorgio A, Tarantino L, de Stefano G et al. Complications after interventional sonography of focal liver lesions: a 22-year single-center experience. *J Ultrasound Med* 2003; 22: 193–205
- [64] Boyum JH, Atwell TD, Schmit GD et al. Incidence and Risk Factors for Adverse Events Related to Image-Guided Liver Biopsy. *Mayo Clin Proc* 2016; 91: 329–335
- [65] Strobel D, Bernatik T, Blank W et al. Incidence of bleeding in 8172 percutaneous ultrasound-guided intraabdominal diagnostic and therapeutic interventions – results of the prospective multicenter DEGUM interventional ultrasound study (PIUS study). *Ultraschall in Med* 2015; 36: 122–131
- [66] Caturelli E, Giacobbe A, Facciorusso D et al. Free-hand technique with ordinary antiseptics in abdominal US-guided fine-needle punctures: three-year experience. *Radiology* 1996; 199: 721–723
- [67] Micu MC, Vlad VM, Bolboacă SD et al. Musculoskeletal ultrasound guided manoeuvres – a security profile. *Med Ultrason* 2014; 16: 214–221
- [68] Cervini P, Hesley GK, Thompson RL et al. Incidence of infectious complications after an ultrasound-guided intervention. *Am J Roentgenol* 2010; 195: 846–850
- [69] Knudsen JM. Persönliche Mitteilung. 2017
- [70] Reisenauer C, Fazzio RT, Hesley G. JOURNAL CLUB: Ultrasound-Guided Breast Interventions: Low Incidence of Infectious Complications With Use of an Uncovered Probe. *Am J Roentgenol* 2017; 208: 1147–1153
- [71] Cartier V, Haenny A, Inan C et al. No association between ultrasound-guided insertion of central venous catheters and bloodstream infection: a prospective observational study. *J Hosp Infect* 2014; 87: 103–108

- [72] Karakitsos D, Labropoulos N, De Groot E et al. Real-time ultrasound-guided catheterisation of the internal jugular vein: a prospective comparison with the landmark technique in critical care patients. *Crit Care* 2006; 10: R162
- [73] Giorgio A, Tarantino L, de Stefano G et al. Complications after percutaneous saline-enhanced radiofrequency ablation of liver tumors: 3-year experience with 336 patients at a single center. *Am J Roentgenol* 2005; 184: 207–211
- [74] Leroy S. Infectious risk of endovaginal and transrectal ultrasonography: systematic review and meta-analysis. *J Hosp Infect* 2013; 83: 99–106
- [75] Masood J, Voulgaris S, Awogu O et al. Condom perforation during transrectal ultrasound guided (TRUS) prostate biopsies: a potential infection risk. *Int Urol Nephrol* 2007; 39: 1121–1124
- [76] Anderson E, Leahy O, Cheng AC et al. Risk factors for infection following prostate biopsy – a case control study. *BMC Infect Dis* 2015; 15: 580
- [77] Borghesi M, Ahmed H, Nam R et al. Complications After Systematic, Random, and Image-guided Prostate Biopsy. *Eur Urol* 2017; 71: 353–365
- [78] Liss MA, Ehdaie B, Loeb S et al. An Update of the American Urological Association White Paper on the Prevention and Treatment of the More Common Complications Related to Prostate Biopsy. *J Urol* 2017; 198: 329–334
- [79] Loeb S, Vellekoop A, Ahmed HU et al. Systematic review of complications of prostate biopsy. *Eur Urol* 2013; 64: 876–892
- [80] Patel U, Dasgupta P, Amoroso P et al. Infection after transrectal ultrasonography-guided prostate biopsy: increased relative risks after recent international travel or antibiotic use. *BJU Int* 2012; 109: 1781–1785
- [81] Raaijmakers R, Kirkels WJ, Roobol MJ et al. Complication rates and risk factors of 5802 transrectal ultrasound-guided sextant biopsies of the prostate within a population-based screening program. *Urology* 2002; 60: 826–830
- [82] Rudzinski JK, Kawakami J. Incidence of infectious complications following transrectal ultrasound-guided prostate biopsy in Calgary, Alberta, Canada: A retrospective population-based analysis. *Can Urol Assoc J* 2014; 8: E301–E305
- [83] Simsir A, Kismali E, Mammadov R et al. Is it possible to predict sepsis, the most serious complication in prostate biopsy? *Urol Int* 2010; 84: 395–399
- [84] Nam RK, Saskin R, Lee Y et al. Increasing hospital admission rates for urological complications after transrectal ultrasound guided prostate biopsy. *J Urol* 2013; 189: S12–S17; discussion S17–18
- [85] Loeb S, Carter HB, Berndt SI et al. Complications after prostate biopsy: data from SEER-Medicare. *J Urol* 2011; 186: 1830–1834
- [86] Williamson DA, Barrett LK, Rogers BA et al. Infectious complications following transrectal ultrasound-guided prostate biopsy: new challenges in the era of multidrug-resistant *Escherichia coli*. *Clin Infect Dis* 2013; 57: 267–274
- [87] Gillespie JL, Arnold KE, Noble-Wang J et al. Outbreak of *Pseudomonas aeruginosa* infections after transrectal ultrasound-guided prostate biopsy. *Urology* 2007; 69: 912–914
- [88] Akduman B, Akduman D, Tokgöz H et al. Long-term fluoroquinolone use before the prostate biopsy may increase the risk of sepsis caused by resistant microorganisms. *Urology* 2011; 78: 250–255
- [89] Kamdar C, Mooppan UMM, Gulmi FA et al. Multi-drug-resistant bacteremia after transrectal ultrasound guided prostate biopsies in hospital employees and their relatives. *Urology* 2008; 72: 34–36
- [90] Liss MA, Taylor SA, Batura D et al. Fluoroquinolone resistant rectal colonization predicts risk of infectious complications after transrectal prostate biopsy. *J Urol* 2014; 192: 1673–1678
- [91] Mosharafa AA, Torkey MH, El Said WM et al. Rising incidence of acute prostatitis following prostate biopsy: fluoroquinolone resistance and exposure is a significant risk factor. *Urology* 2011; 78: 511–514
- [92] Yang L, Gao L, Chen Y et al. Prophylactic Antibiotics in Prostate Biopsy: A Meta-Analysis Based on Randomized Controlled Trials. *Surg Infect* 2015; 16: 733–747
- [93] Zani EL, Clark OAC, Rodrigues Netto N. Antibiotic prophylaxis for transrectal prostate biopsy. *Cochrane Database Syst Rev*. 2011. CD006576.
- [94] Leitlinienprogramm Onkologie. Interdisziplinäre Leitlinie der Qualität S3 zur Früherkennung, Diagnose und Therapie der verschiedenen Stadien des Prostatakarzinoms. [http://www.awmf.org/uploads/tx\\_szleitlinien/043-022OLI\\_S3\\_Prostatakarzinom\\_2016-12.pdf](http://www.awmf.org/uploads/tx_szleitlinien/043-022OLI_S3_Prostatakarzinom_2016-12.pdf) Letzter Zugriff 12.12.2017
- [95] Mottet N, Bellmunt J, Bolla M et al. EAU-ESTRO-SIOG Guidelines on Prostate Cancer. Part 1: Screening, Diagnosis, and Local Treatment with Curative Intent. *Eur Urol* 2017; 71: 618–629
- [96] Cussans A, Somani BK, Basarab A et al. The role of targeted prophylactic antimicrobial therapy before transrectal ultrasonography-guided prostate biopsy in reducing infection rates: a systematic review. *BJU Int* 2016; 117: 725–731
- [97] Fahmy A, Rhashad H, Mohi M et al. Optimizing prophylactic antibiotic regimen in patients admitted for transrectal ultrasound-guided prostate biopsies: A prospective randomized study. *Prostate Int* 2016; 4: 113–117
- [98] Roberts MJ, Williamson DA, Hadway P et al. Baseline prevalence of antimicrobial resistance and subsequent infection following prostate biopsy using empirical or altered prophylaxis: A bias-adjusted meta-analysis. *Int J Antimicrob Agents* 2014; 43: 301–309
- [99] Walker JT, Singla N, Roehrborn CG. Reducing Infectious Complications Following Transrectal Ultrasound-guided Prostate Biopsy: A Systematic Review. *Rev Urol* 2016; 18: 73–89
- [100] Yang L, Tang Z, Gao L et al. The augmented prophylactic antibiotic could be more efficacious in patients undergoing transrectal prostate biopsy: a systematic review and meta-analysis. *Int Urol Nephrol* 2016; 48: 1197–1207
- [101] Pu C, Bai Y, Yuan H et al. Reducing the risk of infection for transrectal prostate biopsy with povidone-iodine: a systematic review and meta-analysis. *Int Urol Nephrol* 2014; 46: 1691–1698
- [102] AbuGhosh Z, Margolick J, Goldenberg SL et al. A Prospective Randomized Trial of Povidone-Iodine Prophylactic Cleansing of the Rectum Before Transrectal Ultrasound Guided Prostate Biopsy. *J Urol* 2013; 189: 1326–1331
- [103] Issa MM, Al-Qassab UA, Hall J et al. Formalin disinfection of biopsy needle minimizes the risk of sepsis following prostate biopsy. *J Urol* 2013; 190: 1769–1775
- [104] Aryanti C. Contamination level of transvaginal ultrasound probes in standard setting: A meta-analysis. *J Physiol Pharm Pharmacol* 2017; 7: 1–12
- [105] Abramowicz JS, Evans DH, Fowlkes JB et al. Guidelines for Cleaning Transvaginal Ultrasound Transducers Between Patients. *Ultrasound Med Biol* 2017; 43: 1076–1079
- [106] AG Praxishygiene der Deutschen Gesellschaft für Krankenhaushygiene. Hygienische Aspekte in der gynäkologischen Praxis. *Hyg Med* 2015; 40: 104–115
- [107] Buescher DL, Möllers M, Falkenberg MK et al. Disinfection of transvaginal ultrasound probes in a clinical setting: comparative performance of automated and manual reprocessing methods. *Ultrasound Obstet Gynecol* 2016; 47: 646–651
- [108] Merz E. Is Transducer Hygiene sufficient when Vaginal Probes are used in the Clinical Routine? *Ultraschall in Med* 2016; 37: 137–139
- [109] Ngu A, McNally G, Patel D et al. Reducing transmission risk through high-level disinfection of transvaginal ultrasound transducer handles. *Infect Control Hosp Epidemiol* 2015; 36: 581–584
- [110] Geißdörfer W, Böhmer C, Pelz K et al. Tuboovarian Abscess Caused by *Atopobium vaginae* following Transvaginal Oocyte Recovery. *J Clin Microbiol* 2003; 41: 2788–2790

- [111] Lesourd F, Izopet J, Mervan C et al. Transmissions of hepatitis C virus during the ancillary procedures for assisted conception. *Hum Reprod* 2000; 15: 1083–1085
- [112] Sharpe K, Karovitch AJ, Claman P et al. Transvaginal oocyte retrieval for in vitro fertilization complicated by ovarian abscess during pregnancy. *Fertil Steril* 2006; 86: 219.e11–219.e13
- [113] Ludwig AK, Glawatz M, Griesinger G et al. Perioperative and post-operative complications of transvaginal ultrasound-guided oocyte retrieval: prospective study of >1000 oocyte retrievals. *Hum Reprod* 2006; 21: 3235–3240
- [114] Hignett M, Claman P. High rates of perforation are found in endovaginal ultrasound probe covers before and after oocyte retrieval for in vitro fertilization-embryo transfer. *J Assist Reprod Genet* 1995; 12: 606–609
- [115] Klett S, Heeg P. Zur Notwendigkeit der regelhaften Aufbereitung von transvaginalen Ultraschallsonden/ Ultraschallsonden mit Schleimhautkontakt. *Hyg Med* 2006; 31: 348–349
- [116] Schwabke I, Eggers M, Gebel J et al. Prüfung und Deklaration der Wirksamkeit von Desinfektionsmitteln gegen Viren zur Anwendung im human-medizinischen Bereich: Stellungnahme des Arbeitskreises Viruzidie beim Robert Koch-Institut. *Bundesgesundheitsbl* 2017; 60: 353–363
- [117] Combs CA, Fishman A. A proposal to reduce the risk of transmission of human papilloma virus via transvaginal ultrasound. *Am J Obstet Gynecol* 2016; 215: 63–67
- [118] M'Zali F, Bounizra C, Leroy S et al. Persistence of microbial contamination on transvaginal ultrasound probes despite low-level disinfection procedure. *PloS One* 2014; 9: e93368
- [119] Meyers J, Ryndock E, Conway MJ et al. Susceptibility of high-risk human papillomavirus type 16 to clinical disinfectants. *J Antimicrob Chemother* 2014; 69: 1546–1550
- [120] Heeg P, Gauer J. Automatische, validierte, nicht-toxische High-level-Desinfektion (HLD) von Ultraschallsonden. *Krankenh- Hyg Infekt* 2014; 36: 126–135
- [121] Ryndock E, Robison R, Meyers C. Susceptibility of HPV16 and 18 to high level disinfectants indicated for semi-critical ultrasound probes. *J Med Virol* 2016; 88: 1076–1080
- [122] Bloc S, Mercadal L, Garnier T et al. Evaluation of a new disinfection method for ultrasound probes used for regional anesthesia: ultraviolet C light. *J Ultrasound Med* 2011; 30: 785–788
- [123] Meyers C, Milici J, Robison R. UVC radiation as an effective disinfectant method to inactivate human papillomaviruses. *PLOS ONE* 2017; 12: e0187377
- [124] Côté G, Denault A. Transesophageal echocardiography-related complications. *Can J Anaesth J Can Anesth* 2008; 55: 622–647
- [125] Janssen J, König K, Knop-Hammad V et al. Frequency of bacteremia after linear EUS of the upper GI tract with and without FNA. *Gastrointest Endosc* 2004; 59: 339–344
- [126] Levy MJ, Norton ID, Wiersema MJ et al. Prospective risk assessment of bacteremia and other infectious complications in patients undergoing EUS-guided FNA. *Gastrointest Endosc* 2003; 57: 672–678
- [127] Levy PY, Teyssie N, Etienne J et al. A nosocomial outbreak of *Legionella pneumophila* caused by contaminated transesophageal echocardiography probes. *Infect Control Hosp Epidemiol* 2003; 24: 619–622
- [128] Werner M, Valenza G, Castellanos I et al. Eine schadhafte Echokardiografie-Sonde als Ursache für einen Kolonisations- und Infektionsausbruch mit 3 MRGN *E. coli* auf einer interdisziplinären operativen Intensivstation. [http://www.krankenhausinfektionen-ulmer-symposium.de/index.php?eID=tx\\_nawsecured1&u=0&g=0&t=901487342700&h-ash=19f48777d844bb807652b383ed8ebaed57fd64d&file=fileadmin/congress/media/usk2017/pdf/USK2017\\_Programmheft.pdf](http://www.krankenhausinfektionen-ulmer-symposium.de/index.php?eID=tx_nawsecured1&u=0&g=0&t=901487342700&h-ash=19f48777d844bb807652b383ed8ebaed57fd64d&file=fileadmin/congress/media/usk2017/pdf/USK2017_Programmheft.pdf) Letzter Zugriff 27.12.2017
- [129] Steinfurt DP, Johnson DF, Irving LB. Incidence of bacteraemia following endobronchial ultrasound-guided transbronchial needle aspiration. *Eur Respir J* 2010; 36: 28–32
- [130] Dietrich CF, Lorentzen T, Appelbaum L et al. EFSUMB Guidelines on Interventional Ultrasound (INVUS), Part III – Abdominal Treatment Procedures (Long Version). *Ultraschall in Med* 2016; 37: E1–E32
- [131] Sidhu PS, Brabrand K, Cantisani V et al. EFSUMB Guidelines on Interventional Ultrasound (INVUS), Part II. Diagnostic Ultrasound-Guided Interventional Procedures (Long Version). *Ultraschall in Med* 2015; 36: E15–E35
- [132] Barawi M, Gottlieb K, Cunha B et al. A prospective evaluation of the incidence of bacteremia associated with EUS-guided fine-needle aspiration. *Gastrointest Endosc* 2001; 53: 189–192
- [133] Levy MJ, Abu Dayyeh BK, Fujii LL et al. Prospective evaluation of adverse events following lower gastrointestinal tract EUS FNA. *Am J Gastroenterol* 2014; 109: 676–685
- [134] Levy MJ, Norton ID, Clain JE et al. Prospective study of bacteremia and complications With EUS FNA of rectal and perirectal lesions. *Clin Gastroenterol Hepatol Off Clin Pract J Am Gastroenterol Assoc* 2007; 5: 684–689
- [135] Fernández-Esparrach G, Sendino O, Araujo I et al. Incidence of bacteremia in cirrhotic patients undergoing upper endoscopic ultrasonography. *Gastroenterol Hepatol* 2014; 37: 327–333
- [136] Li N, Qi H, Liu Z et al. Effect of Povidone-iodine Washing of Gastrointestinal Mucosa or Taking Proton Pump Inhibitors on Bacteremia after Endoscopic Ultrasonography-guided Fine Needle Aspiration. *Endosc Ultrasound* 2012; 1: 90–95
- [137] Wang KX, Ben QW, Jin ZD et al. Assessment of morbidity and mortality associated with EUS-guided FNA: a systematic review. *Gastrointest Endosc* 2011; 73: 283–290
- [138] Jenssen C, Alvarez-Sánchez MV, Napoléon B et al. Diagnostic endoscopic ultrasonography: assessment of safety and prevention of complications. *World J Gastroenterol* 2012; 18: 4659–4676
- [139] Fujii LL, Levy MJ. Basic techniques in endoscopic ultrasound-guided fine needle aspiration for solid lesions: Adverse events and avoiding them. *Endosc Ultrasound* 2014; 3: 35–45
- [140] Gleeson FC, Clain JE, Rajan E et al. EUS-FNA assessment of extramesenteric lymph node status in primary rectal cancer. *Gastrointest Endosc* 2011; 74: 897–905
- [141] von Bartheld MB, van Breda A, Annema JT. Complication rate of endosonography (endobronchial and endoscopic ultrasound): a systematic review. *Respir Int Rev Thorac Dis* 2014; 87: 343–351
- [142] Asano F, Aoe M, Ohsaki Y et al. Complications associated with endobronchial ultrasound-guided transbronchial needle aspiration: a nationwide survey by the Japan Society for Respiratory Endoscopy. *Respir Res* 2013; 14: 50
- [143] Kim SY, Lee JW, Park YS et al. Incidence of Fever Following Endobronchial Ultrasound-Guided Transbronchial Needle Aspiration. *Tuberc Respir Dis* 2017; 80: 45–51
- [144] Çağlayan B, Yılmaz A, Bilaçeroğlu S et al. Complications of Convex-Probe Endobronchial Ultrasound-Guided Transbronchial Needle Aspiration: A Multi-Center Retrospective Study. *Respir Care* 2016; 61: 243–248
- [145] von Bartheld MB, Annema JT. Endosonography-related mortality and morbidity for pulmonary indications: a nationwide survey in the Netherlands. *Gastrointest Endosc* 2015; 82: 1009–1015
- [146] Vaidya PJ, Munavar M, Leuppi JD et al. Endobronchial ultrasound-guided transbronchial needle aspiration: Safe as it sounds. *Respirol* 2017; 22: 1093–1101
- [147] DeWitt J, Al-Haddad M, Fogel E et al. Endoscopic transduodenal drainage of an abscess arising after EUS-FNA of a duodenal GI stromal tumor. *Gastrointest Endosc* 2009; 70: 185–188

- [148] Eckardt AJ, Adler A, Gomes EM et al. Endosonographic large-bore biopsy of gastric subepithelial tumors: a prospective multicenter study. *Eur J Gastroenterol Hepatol* 2012; 24: 1135–1144
- [149] Grandval P, Picon M, Coste P et al. Infection of submucosal tumor after endosonography-guided needle biopsy. *Gastroenterol Clin Biol* 1999; 23: 566–568
- [150] Polkowski M, Gerke W, Jarosz D et al. Diagnostic yield and safety of endoscopic ultrasound-guided trucut [corrected] biopsy in patients with gastric submucosal tumors: a prospective study. *Endoscopy* 2009; 41: 329–334
- [151] Sing J, Erickson R, Fader R. An in vitro analysis of microbial transmission during EUS-guided FNA and the utility of sterilization agents. *Gastrointest Endosc* 2006; 64: 774–779
- [152] Zhu H, Jiang F, Zhu J et al. Assessment of morbidity and mortality associated with endoscopic ultrasound-guided fine-needle aspiration for pancreatic cystic lesions: A systematic review and meta-analysis. *Dig Endosc* 2017; 29: 667–675
- [153] Iwashita T, Yasuda I, Uemura S et al. Infected mediastinal cyst following endoscopic ultrasonography-guided fine-needle aspiration with rupture into the esophagus. *Dig Endosc* 2012; 24: 386
- [154] Mahady SE, Moss A, Kwan V. EUS-guided drainage of a mediastinal collection complicating FNA of a bronchogenic cyst. *Gastrointest Endosc* 2011; 73: 1306–1308
- [155] Maturu VN, Dhooria S, Agarwal R. Efficacy and Safety of Transbronchial Needle Aspiration in Diagnosis and Treatment of Mediastinal Bronchogenic Cysts: Systematic Review of Case Reports. *J Bronchol Interv Pulmonol* 2015; 22: 195–203
- [156] Onuki T, Kuramochi M, Inagaki M. Mediastinitis of bronchogenic cyst caused by endobronchial ultrasound-guided transbronchial needle aspiration. *Respirol Case Rep* 2014; 2: 73–75
- [157] Westerterp M, van der Berg JG, van der Lanschot JJB et al. Intramural bronchogenic cysts mimicking solid tumors. *Endoscopy* 2004; 36: 1119–1122
- [158] Wildi SM, Hoda RS, Fickling W et al. Diagnosis of benign cysts of the mediastinum: the role and risks of EUS and FNA. *Gastrointest Endosc* 2003; 58: 362–368
- [159] ten Berge J, Hoffman BJ, Hawes RH et al. EUS-guided fine needle aspiration of the liver: indications, yield, and safety based on an international survey of 167 cases. *Gastrointest Endosc* 2002; 55: 859–862
- [160] Early DS, Acosta RD, ASGE Standards of Practice Committee et al. Adverse events associated with EUS and EUS with FNA. *Gastrointest Endosc* 2013; 77: 839–843
- [161] Denzer U, Beilenhoff U, Eickhoff A et al. S2k guideline: quality requirements for gastrointestinal endoscopy, AWMF registry no. 021-022. *Z Gastroenterol* 2015; 53: E1–E227
- [162] Jenssen C, Hocke M, Fusaroli P et al. EFSUMB Guidelines on Interventional Ultrasound (INVUS), Part IV – EUS-guided Interventions: General aspects and EUS-guided sampling (Long Version). *Ultraschall in Med* 2016; 37: E33–E76
- [163] Polkowski M, Jenssen C, Kaye P et al. Technical aspects of endoscopic ultrasound (EUS)-guided sampling in gastroenterology: ESGE Technical Guideline. *Endoscopy* 2017; 49: 989–1006
- [164] Wani S, Wallace MB, Cohen J et al. Quality indicators for EUS. *Gastrointest Endosc* 2015; 81: 67–80
- [165] Wani S, Wallace MB, Cohen J et al. Quality indicators for EUS. *Am J Gastroenterol* 2015; 110: 102–113
- [166] Guarner-Argente C, Shah P, Buchner A et al. Use of antimicrobials for EUS-guided FNA of pancreatic cysts: a retrospective, comparative analysis. *Gastrointest Endosc* 2011; 74: 81–86
- [167] Klein A, Qi R, Nagubandi S et al. Single-dose intra-procedural ceftriaxone during endoscopic ultrasound fine-needle aspiration of pancreatic cysts is safe and effective: results from a single tertiary center. *Ann Gastroenterol* 2017; 30: 237–241
- [168] Marinos E, Lee S, Jones B et al. Outcomes of single-dose peri-procedural antibiotic prophylaxis for endoscopic ultrasound-guided fine-needle aspiration of pancreatic cystic lesions. *United Eur Gastroenterol J* 2014; 2: 391–396
- [169] Ignee A, Jenssen C, Hocke M et al. Contrast-enhanced (endoscopic) ultrasound and endoscopic ultrasound elastography in gastrointestinal stromal tumors. *Endosc Ultrasound* 2017; 6: 55–60
- [170] Piscaglia F, Nolsøe C, Dietrich CF et al. The EFSUMB Guidelines and Recommendations on the Clinical Practice of Contrast Enhanced Ultrasound (CEUS): update 2011 on non-hepatic applications. *Ultraschall in Med* 2012; 33: 33–59
- [171] Seicean A, Jinga M. Harmonic contrast-enhanced endoscopic ultrasound fine-needle aspiration: Fact or fiction? *Endosc Ultrasound* 2017; 6: 31–36
- [172] Yamashita Y, Kato J, Ueda K et al. Contrast-Enhanced Endoscopic Ultrasonography for Pancreatic Tumors. *BioMed Res Int* 2015; 2015: 491782
- [173] Alvarez-Sánchez MV, Jenssen C, Faiss S et al. Interventional endoscopic ultrasonography: an overview of safety and complications. *Surg Endosc* 2014; 28: 712–734
- [174] Fusaroli P, Jenssen C, Hocke M et al. EFSUMB Guidelines on Interventional Ultrasound (INVUS), Part V. *Ultraschall in Med – Eur J Ultrasound* 2016; 37: 77–99
- [175] Fabbri C, Luigiano C, Lisotti A et al. Endoscopic ultrasound-guided treatments: are we getting evidence based—a systematic review. *World J Gastroenterol* 2014; 20: 8424–8448
- [176] Chantarojanasiri T, Aswakul P, Prachayakul V. Uncommon complications of therapeutic endoscopic ultrasonography: What, why, and how to prevent. *World J Gastrointest Endosc* 2015; 7: 960–968
- [177] Moshkanbaryans L, Meyers C, Ngu A et al. The importance of infection prevention and control in medical ultrasound. *Australas J Ultrasound Med* 2015; 18: 96–99
- [178] Koibuchi H, Fujii Y, Kotani K et al. Degradation of ultrasound probes caused by disinfection with alcohol. *J Med Ultrason* 2011; 38: 97–100
- [179] Shukla B, Howell V, Griffiths A et al. Superiority of chlorhexidine 2%/alcohol 70% wipes in decontaminating ultrasound equipment. *Ultrasound* 2014; 22: 135–140