



Triple Stentriever “Bouquet” Deployment with Zoom 88 Large-Bore Aspiration and Walrus Balloon-Guide Catheter for the Definitive Thrombectomy of a Carotid Free-Floating Thrombus

Jessica K. Campos¹ Benjamin M. Meyer² Muhammad W. Khan³ David A. Zarrin⁴
Jonathan C. Collard de Beaufort⁵ Gizal Amin³ Li-Mei Lin³ Alexander L. Coon³

¹ Department of Neurological Surgery, University of California Irvine, Orange, California, United States

² University of Arizona, College of Medicine, Tucson, Arizona, United States

³ Department of Neurological Surgery, Carondelet Neurological Institute, St. Joseph's Hospital, Tucson, Arizona, United States

Address for correspondence Jessica K. Campos, MD, Department of Neurosurgery, University of California, Irvine, Irvine, CA 92697, United States (e-mail: camposjk@hs.uci.edu).

⁴ Department of Neurosurgery, University of California Los Angeles, Los Angeles, California, United States

⁵ College of Arts and Science, Syracuse University, Syracuse, New York, United States

J Neurol Surg Rep 2024;85:e17–e22.

Abstract

Formation of a carotid free-floating thrombus (CFFT) is a rare and life-threatening condition without an optimal management plan. A 78-year-old woman with a history of prior right internal carotid artery (ICA) mechanical thrombectomy and antiplatelet noncompliance presented with transient ischemic attacks secondary to a recurrent CFFT in the right ICA. Given her symptoms and recurrent CFFT, endovascular mechanical thrombectomy was performed. A balloon guide-catheter (BGC) and a Zoom 88 distal access catheter were brought into the right distal common carotid artery and proximal ICA bulb, respectively. Three 0.021-inch microcatheters, each loaded with a unique stentriever, were navigated beyond the thrombus into the upper cervical ICA and deployed in a bouquet fashion. The BGC was inflated to achieve flow arrest, and the Zoom 88 aspiration catheter was tracked over the three bouquet stentriever to ingest the thrombus. Follow-up angiography demonstrated recanalization of the proximal cervical ICA without evidence of residual thrombus. Twenty-four-hour postoperative computed tomography imaging did not reveal any evidence of new infarction. The patient was discharged home with an intact neurological examination, compliant on aspirin and apixaban. We demonstrate a novel technique utilizing a large-bore catheter with a triple stentriever “bouquet” to thrombectomize a CFFT.

Keywords

- ▶ carotid free-floating thrombus
- ▶ triple stentriever
- ▶ zoom bouquet
- ▶ mechanical thrombectomy

Background and Importance

A carotid free-floating thrombus (CFFT) is a rare but potentially devastating condition. This occurs when a thrombus forms and stays attached to the vessel wall in the proximal

cervical internal carotid artery (ICA) but does not frankly restrict flow or distally embolize.¹ The concern is that the artery could occlude with complete thrombosis and resultant ischemia,² or the clot could dislodge and cause distal ischemia from resultant emboli. The treatment for this

received
September 14, 2023
accepted after revision
December 2, 2023

DOI <https://doi.org/10.1055/s-0044-1778695>.
ISSN 2193-6358.

© 2024. The Author(s).

This is an open access article published by Thieme under the terms of the Creative Commons Attribution-NonDerivative-NonCommercial-License, permitting copying and reproduction so long as the original work is given appropriate credit. Contents may not be used for commercial purposes, or adapted, remixed, transformed or built upon. (<https://creativecommons.org/licenses/by-nc-nd/4.0/>)

Georg Thieme Verlag KG, Rüdigerstraße 14, 70469 Stuttgart, Germany

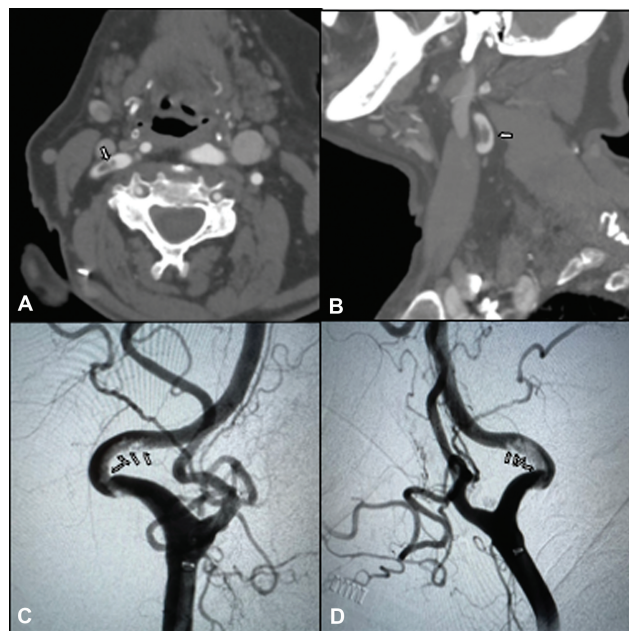


Fig. 1 (A) Axial and sagittal (B) computed tomography angiography view of a carotid free-floating thrombus (white arrows) demonstrating a typical cross-sectional donut sign. (C) Anteroposterior and lateral (D) angiography views of the floating thrombus in the internal carotid artery (white arrows).

condition has long been medical management with anti-coagulants and antiplatelet medications,^{3,4} yet significant morbidity and mortality prevail.⁵

There have been several recent reports about the successful mechanical thrombectomy of CFFT.^{6–17} These studies have

demonstrated the challenges of safely performing mechanical thrombectomy due to significant clot burden, lack of tools, and techniques designed to perform cerebrovascular thrombectomy. In total, the literature to date has provided no conclusive techniques for safe and reliable removal of CFFTs.^{5,18}

Recent technological improvements in aspiration catheters and stentriever has made mechanical thrombectomy of cerebral vessels increasingly safe^{6–17} and effective.^{19,20} Among these developments are large-bore aspiration catheters (0.088" ID)^{21,22} that are built both with and without compliant balloons for flow arrest and aspiration/flow reversal. Stentriever technology has evolved to include devices that can be opened and closed to control tension and expansion at the clot interface.^{23,24}

In this report, we demonstrate a novel technique that utilizes a combined approach of 0.088" large-bore aspiration with a triple-stentriever "bouquet" in the setting of flow arrest with concomitant aspiration to safely and definitively thrombectomy a proximal CFFT. We additionally review current CFFT treatment literature and discuss the proposed technique in this context.

Clinical Presentation

A 78-year-old female with a history of a right proximal CFFT 2 months status post-mechanical thrombectomy for right carotid artery occlusion, presented with symptomatic transient ischemic attack noncompliant on her prescribed antiplatelet regimen. Computed tomography (CT) angiography demonstrated a recurrent CFFT in the right ICA (→Fig. 1). The decision was made to offer definitive endovascular

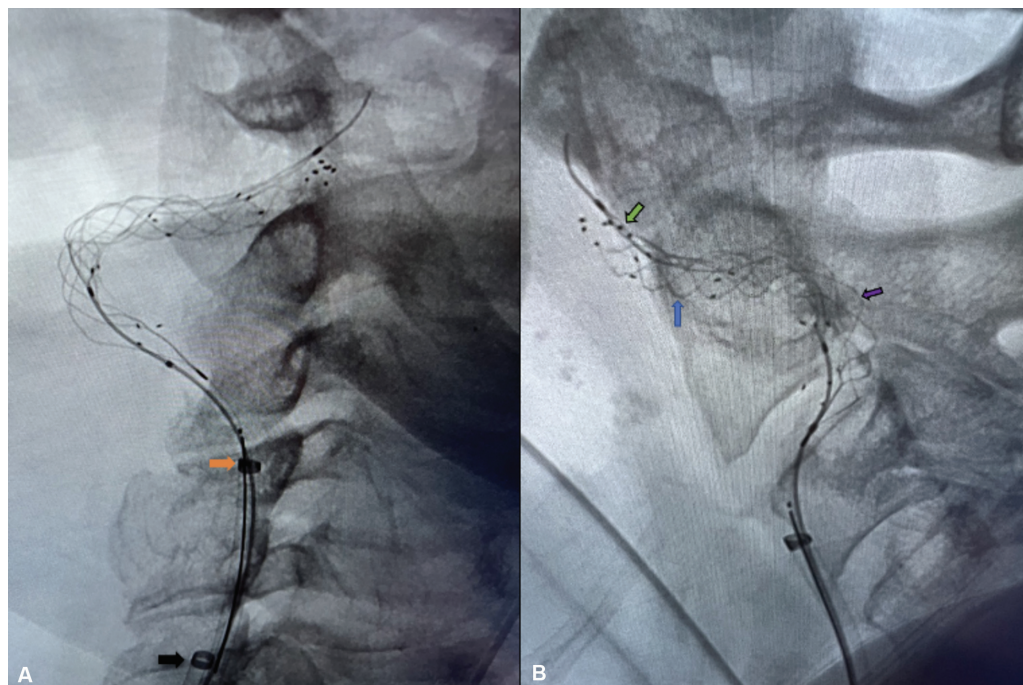


Fig. 2 (A) Anteroposterior angiography of the Zoom 88 catheter deployment (orange arrow) and Walrus balloon guide-catheter at the level of C6 (black arrow) positioned in the internal carotid artery and common carotid artery, respectively. (B) Lateral angiography demonstrating deployment of the 0.021-inch stent retrievers: Tigertriever (green arrow; Rapid Medical, Yokneam, Israel), Trevo (blue arrow; Stryker Neurovascular), SolitaireX (purple arrow; Medtronic Neurovascular, Irvine, California, United States).

mechanical thrombectomy for the lesion given its recurrent and symptomatic nature.

The procedure was performed under general anesthesia with biplanar flat panel X-ray fluoroscopy. A heparin bolus (5,000 units intravenously) was administered at the start of the procedure and a standard heparin flush was maintained thereafter. Bifemoral arterial access was obtained using Seldinger technique for 8-French (Fr) sheath placement.

Under real-time fluoroscopy, an 8-Fr Walrus balloon-guide catheter (BGC) (Q'Apel Medical, Fremont, California, United States) was brought into the right distal common carotid artery via the right femoral access site and put on continuous flush. Using the left femoral access site, the 8-Fr Zoom 88 (Imperative Care, Campbell, California, United States) catheter was then positioned in the right proximal ICA bulb. Angiography confirmed the presence of a CFFT greater than 2 cm in length (►Fig. 1). A triple-headed rotating hemostatic valve was attached and three 0.021-inch microcatheters were carefully navigated beyond the thrombus into the upper cervical ICA, taking care to avoid disrupting the thrombus. Each 0.021-inch catheter was loaded with a different unique stentriever: Tigertriever (Rapid Medical, Yokneam, Israel), Trevo (Stryker Neurovascular), SolitaireX (Medtronic Neurovascular, Irvine, California, United States), from distal to proximal, respectively. Each device was subsequently deployed via a traditional unsheath technique in a "bouquet" fashion (►Fig. 2). In the case of the Tigertriever, it was deployed using its proprietary crimping technique.

The microcatheters were then stripped off the Solitaire and Trevo stentriever. The balloon of the Walrus BGC was inflated to achieve flow arrest, and a sequence of flow reversal aspiration utilizing the Medella (Stryker) commenced. The Zoom 88 aspiration catheter (with Penumbra suction running) was tracked over the three deployed bouquet of stentriever, ingested the clot, and subsequently corked within the Zoom 88 catheter (►Fig. 3, ►Supplementary Video 1). The Walrus BGC was deflated and the Zoom 88 catheter with the corked stentriever "bouquet"/clot was synchronously removed while aspiration continued (►Fig. 3, ►Supplementary Video 2).

Final angiography of the head through the Walrus BGC demonstrated successful mechanical thrombectomy with thrombolysis in cerebral infarction (TICI) 3 recanalization of the proximal cervical ICA without evidence of residual thrombus, branch occlusion, distal embolism, or other perioperative complication. All catheters were subsequently removed

Supplementary Video 2

Native view, the balloon was subsequently deflated and under continuous aspiration the corked bouquet stentriever and Zoom 88 system is retracted from the circulation. Online content including video sequences viewable at: <https://www.thieme-connect.com/products/ejournals/html/>.

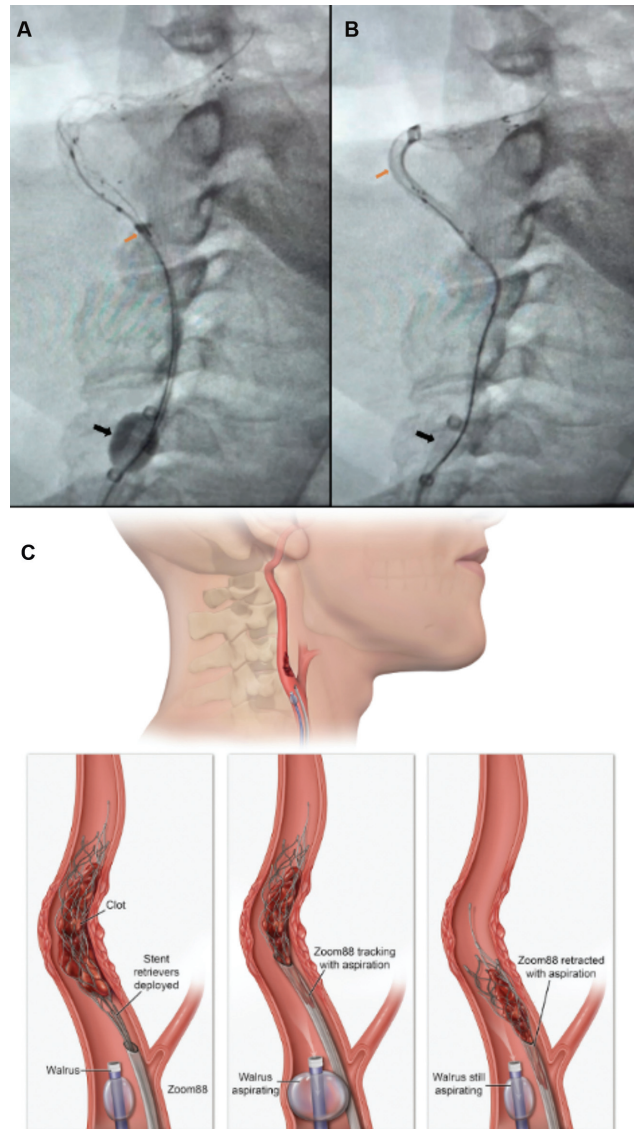


Fig. 3 (A) Native anteroposterior view of "bouquet" retrieval of stentriever (A–B). (A) Zoom 88 catheter (Imperative Care, Campbell, California, United States) tracking (orange arrow) to the intercalated thrombus and stentriever, with the Walrus BGC (Q'Apel Medical, Fremont, California, United States) inflated for flow arrest under continuous aspiration (black arrow). (B) The Zoom 88 aspiration catheter (with pump-suction aspiration) was tracked over the three deployed bouquet of stentriever, ingested the clot, and subsequently corked within the Zoom 88 catheter, Walrus BGC was deflated. (C) Illustration of the triple stentriever "bouquet" deployment, which capitalizes on the large-bore Zoom 88 catheter inner diameter and concomitant flow arrest provided by the Walrus BGC, balloon guide-catheter.

Supplementary Video 1

Native view, flow arrest is achieved with the balloon inflated on the balloon-guide catheter and flow reversal achieved under aspiration. The Zoom 88 is tracked over the delivery wires of the three stentriever bouquet to engage and ingest the thrombus. Online content including video sequences viewable at: <https://www.thieme-connect.com/products/ejournals/html/>.

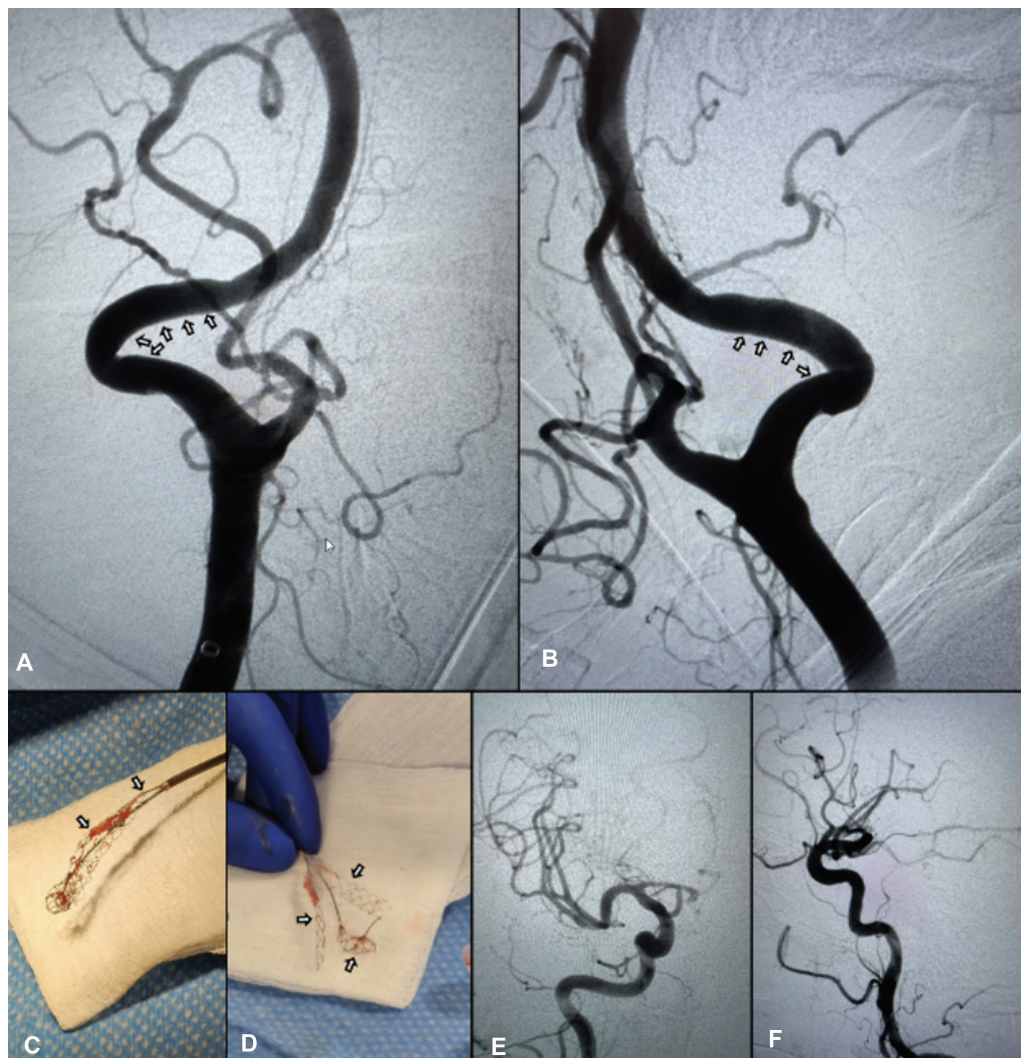


Fig. 4 (A) Anteroposterior and lateral (B) angiography demonstrating complete resolution of the CFFT (arrows). (C) Gross thrombus specimen measuring over 2 cm in length (arrows). (D) Collection of the three 0.021-inch microcatheters with intercalated thrombus (arrows). (E, anteroposterior; F, lateral) Final control injection angiography of procedure demonstrating TICI 3 recanalization of the proximal cervical internal carotid artery without evidence of residual thrombus, branch occlusion, and distal embolism. CFFT, carotid free-floating thrombus; TICI, thrombolysis in cerebral infarction 3.

(→ **Fig. 4**). A total of 21.6 minutes of combined anteroposterior and lateral fluoroscopy, with 18 mL of Isovue 300, was reported for the procedure. The patient was subsequently reversed and extubated and remained at her neurological baseline. Follow-up head CT imaging revealed no evidence of new frank infarction. The patient was discharged home on postoperative day 8 compliant on aspirin and apixaban.

Discussion

We report here a novel technique for the mechanical thrombectomy of CFFTs using a 0.088" aspiration catheter with a stentriever "bouquet" with simultaneous flow reversal/aspiration. Currently, there is insufficient data/evidence to compare the different procedural modalities in managing CFFTs.^{6,7,10,13,14,16–18,25,26} A retrospective study of 525 cases with CFFTs found no significant difference in outcomes of

patients receiving antiplatelet and anticoagulant therapy versus procedural management with endovascular or surgical carotid endarterectomy (CEA).⁵

With its minimally invasive nature and advanced modern catheters and devices, endovascular thrombectomy, as opposed to CEA, has become the preferred choice for the procedural management of CFFTs at many centers.^{6–17} Since the last major literature review conducted in 2019,⁵ there have been an additional 27 cases managed with endovascular treatment in the literature. Although these reports have not demonstrated a standardized technique for the mechanical thrombectomy of CFFTs, numerous methods including stentriever, reversal of carotid flow with occlusion balloons, and distal filter wire placement have been reported.^{6–17} Recently, direct aspiration, with or without the utilization of proximal and distal protection devices have been described.^{11,20,27}

To harness all the benefits of previously reported techniques we employed a triple stentriever "bouquet" technique for

the mechanical thrombectomy of a CFFT. This stentriever technique was combined with flow reversal aspiration with an 088-balloon-guide and direct thromboaspiration with a Zoom 88 thrombectomy catheter. The three stentriever devices that were deployed simultaneously (as a bouquet) provided two distinct benefits. First, each of the devices had its own unique way of integrating into the thrombus, which maximized the grip on the clot. Second, the three devices could intercalate with each other to form a mesh or snare that would prevent distal embolization of the clot upon retrieval. When this was combined with the direct thromboaspiration of the Zoom 88 with flow arrest/reversal aspiration with the Walrus BGC, a single-pass removal with no distal embolus was achieved. This access platform and microcatheter system also provides the benefit of the ability to perform intracranial mechanical thrombectomy if embolism is encountered.

Our findings are limited by those inherent to case reports, and future application of the described technique should occur only after careful consideration of case specifics, patient anatomy, and risk factors. A systematic comparison of risks associated with different mechanical thrombectomy techniques for CFFTs is necessary to delineate optimal treatment for patients with CFFT.

Conclusion

We describe the novel use of a Zoom bouquet technique for the successful treatment of CFFT. Our experience advocates for the use of Zoom bouquet technique as a safe and effective option for patients with medically refractory CFFT. Prospective studies are warranted to determine the most favorable technique for CFFTs that are managed procedurally.

Presentation

This material was accepted as an e-poster at the 2023 Annual Society of NeuroInterventional Surgery meeting in San Diego, California, United States.

Authors' Contribution

J.K.C., B.M.M., M.W.K., J.C.C.d.B. assisted with the conception and design of the manuscript. J.K.C., B.M.M., and D.A.Z. drafted and revised the manuscript for important intellectual content. J.K.C., B.M.M., and G.A. assisted with the data acquisition and analysis. L.M.L. and A.L.C. reviewed the important intellectual content presented in the manuscript. A.L.C., J.K.C., and M.W.K. performed treatment procedures and critically revised the important intellectual content. All authors read and approved the final manuscript.

Patient Consent

All individual identifying information, including age and sex, have been meticulously anonymized to achieve appropriate anonymity in the manuscript. The patient provided her informed consent to participate in this study and for the publication of his case report.

Conflict of Interest

A.L.C. is a consultant for Medtronic Neurovascular, MicroVention-Terumo, Stryker Neurovascular, Cerenovus, Rapid Medical, Avail MedSystems, Imperative Care, Deinde, InNeuroCo, Q'Apel; a proctor for MicroVention-Terumo, Stryker Neurovascular, and Medtronic Neurovascular. L.M.L. is a proctor for Medtronic Neurovascular, Stryker Neurovascular, MicroVention-Terumo; and a consultant for Medtronic Neurovascular, Stryker Neurovascular, MicroVention-Terumo, Rapid Medical, and Balt.

References

- 1 Dowlatshahi D, Lum C, Menon BK, et al. Aetiology of extracranial carotid free-floating thrombus in a prospective multicentre cohort. *Stroke Vasc Neurol* 2023;8(03):194–196
- 2 Imahori T, Tanaka K, Arai A, Kohmura E. Surgical thromboendarterectomy for free-floating thrombus associated with cervical carotid artery dissection: a case report. *Ann Vasc Surg* 2020; 68:572.e9–572.e14
- 3 Gülcü A, Gezer NS, Men S, Öz D, Yaka E, Öztürk V. Management of free-floating thrombus within the arcus aorta and supra-aortic arteries. *Clin Neurol Neurosurg* 2014;125:198–206
- 4 Vassileva E, Daskalov M, Stamenova P. Free-floating thrombus in stroke patients with nonstenotic internal carotid artery—an ultrasonographic study. *J Clin Ultrasound* 2015;43(01):34–38
- 5 Fridman S, Lownie SP, Mandzia J. Diagnosis and management of carotid free-floating thrombus: a systematic literature review. *Int J Stroke* 2019;14(03):247–256
- 6 Wang P, Wang Z, Pan J, Lu K, Sun L, Geng Y. Case report: ultrasound-assisted endovascular therapy for carotid artery floating thrombus. *Front Cardiovasc Med* 2022;9:961760
- 7 Christian ZK, Hoang AN, Dang H, et al. Use of transcarotid artery revascularization for mechanical thrombectomy and treatment of symptomatic high-grade carotid artery stenosis associated with free-floating thrombus: illustrative case. *J Neurosurg Case Lessons* 2022;3(10):CASE21553
- 8 Mareedu R, Hwang J, Vyakaranam S, Inkollu S. Use of transcarotid artery revascularization to treat symptomatic carotid artery stenosis associated with free-floating thrombus. *Ann Vasc Surg* 2021;70:568.e1–568.e3
- 9 Sugie A, Yamada M, Yokoyama K, et al. Carotid free-floating thrombus in a stent 6 months after carotid artery stenting. *World Neurosurg* 2020;141:236–239
- 10 Bhogal P, AlMatter M, Aguilar Pérez M, Bänzner H, Henkes H, Hellstern V. Carotid stenting as definitive treatment for free floating thrombus-review of 7 cases. *Clin Neuroradiol* 2021;31 (02):449–455
- 11 Denezpi TM, Green RS, Carlson AP. Use of distal protection filter device for rescue mechanical thrombectomy for symptomatic free-floating thrombus of the cervical internal carotid artery. *Interv Neuroradiol* 2021;27(03):440–443
- 12 Toudou-Daouda M, Ouanounou G, Aghasaryan M, et al. Floating aortic arch thrombus involving the left common carotid artery complicated with ischemic stroke associated with cocaine use. *Neurol Sci* 2022;43(09):5629–5632
- 13 Tomoyose R, Tsumoto T, Hara K, et al. Mechanical thrombectomy and carotid artery stenting for stenosis of the internal carotid artery with free-floating thrombosis: illustrative case. *J Neurosurg Case Lessons* 2021;2(09):CASE21338
- 14 Ali AB, Hui SH, Mouawad NJ. Mechanical thrombectomy of symptomatic carotid stenosis with free-floating thrombus in a patient with COVID-19 using transcarotid artery revascularization. *J Vasc Surg Cases Innov Tech* 2021;7(04):725–729
- 15 Al-Jehani H, Alhamid MA, Alkhalaf Y, Alabbas F. A case of coincidental free floating thrombus in the vertebral artery in a

- patient presenting with an anterior circulation stroke and literature review. *Neurointervention* 2020;15(03):144–153
- 16 Ojha P, Goel G, Chatterjee A, Singhal V, Mahajan A. “Double protection closed compartment” aspiration technique for left internal carotid artery (ICA) free floating thrombus. *Ann Indian Acad Neurol* 2022;25(02):320–322
 - 17 Inoue H, Oomura M, Nishikawa Y, Mase M, Matsukawa N. Direct advancement of balloon-guide catheter distal to the carotid free-floating thrombus achieves smart mechanical thrombectomy. *Cureus* 2022;14(02):e22439
 - 18 Müller MD, Raptis N, Mordasini P, et al. Natural history of carotid artery free-floating thrombus-a single center, consecutive cohort analysis. *Front Neurol* 2022;13:993559
 - 19 Fitzpatrick N, Motyer R, Gibney B, et al. Expanding the role of stent-retriever endovascular thrombectomy: a case series of free-floating thrombus. *J Neurointerv Surg* 2018;10(12):1164–1167
 - 20 Yamaoka A, Miyata K, Iihoshi S, Mikuni N. Endovascular treatment of asymptomatic free-floating thrombus in the carotid artery bifurcation: a direct aspiration first-pass technique under double balloon protection. *BMJ Case Rep* 2019;12(08):e230295
 - 21 Lin LM, Bender MT, Colby GP, et al. Use of a next-generation multi-durometer long guide sheath for triaxial access in flow diversion: experience in 95 consecutive cases. *J Neurointerv Surg* 2018;10(02):137–142
 - 22 Lin L-M, Colby GP, Iyer RR, et al. Pentaxial access platform for ultra-distal intracranial delivery of a large-bore hyperflexible DIC (distal intracranial catheter): a technical note. *Interdiscip Neurosurg* 2016;6:29–34
 - 23 Fischer S, Will L, Phung T, Weber W, Maus V, Nordmeyer H. The Tigertriever 13 for mechanical thrombectomy in distal and medium intracranial vessel occlusions. *Neuroradiology* 2022;64(04):775–783
 - 24 Sirakov A, Minkin K, Penkov M, Ninov K, Karakostov V, Sirakov S. Comaneci-assisted coiling as a treatment option for acutely ruptured wide neck cerebral aneurysm: case series of 118 patients. *Neurosurgery* 2020;87(06):1148–1156
 - 25 Xu W, Ma Q, Luo J, Tao W, Ma Y, Jiao L. Free-floating thrombus of internal carotid artery presenting as thromboembolism. *J Vasc Surg* 2023;77(06):1804–1805
 - 26 Cancer-Perez S, Alfayate-García J, Vicente-Jiménez S, et al. Symptomatic Common carotid free-floating thrombus in a COVID-19 patient, case report and literature review. *Ann Vasc Surg* 2021;73:122–128
 - 27 Giragani S, Komal RNK, Potluri A, Sharma VK. Bilateral symptomatic carotid free floating thrombi. *Neurol India* 2021;69(03):770–771