



# SFM Fetal Therapy Practice Guidelines: Fetal Shunts

K. Manikandan<sup>1</sup> Reema Bhatt<sup>2</sup>

<sup>1</sup>Department of Fetal Therapy, The Fetal Clinic, Pondicherry, India

<sup>2</sup>Department of Fetal Medicine and Perinatology, Amrita Hospital and Research Institute, Faridabad, Haryana, India

Address for correspondence Reema Bhatt, MS, DNB, FICOG, MNAMS, Prof and Head Fetal Medicine and Perinatology, Amrita Hospital and Research Institute, Faridabad, Haryana, 121002, India (e-mail: reemakumarbhatt@gmail.com).

J Fetal Med 2023;10:158–163.

## Abstract

Fetal shunt is placed into the fetus in order to drain fluid from a fluid-filled fetal area into the amniotic cavity. The main indications are hydrothorax, congenital pulmonary airway malformation (CPAM) with dominant cyst, and lower urinary tract obstruction. Fetal shunt is indicated if the hydrothorax is primary or hypertensive. In case of reaccumulation after a diagnostic tap or if the primary hydrothorax has led to a secondary nonimmune hydrops provided the primary nature is clearly established and in cases where gestational age is less than 34 weeks.

## Keywords

- ▶ CPAM with dominant cyst
- ▶ hydrothorax
- ▶ KCH-rocket fetal bladder stent
- ▶ lower urinary tract obstruction
- ▶ Harrison fetal bladder stent

A shunt in CPAM is indicated in case of CPAM with a dominant cyst where the CPAM volume ratio (CVR) is greater than 1.6, where macrocysts are visible within the lesion, where the diameter of the dominant cyst is more than one-third of the largest diameter of the lesion and where presence of hydrops is not a contraindication for shunting. In case of lower urinary tract obstruction, fetal shunt may be indicated if the following conditions are met. The etiology of lower urinary tract obstruction is posterior urethral valve with oligohydramnios and fetal urinalysis is favorable.

In order to drain fluid from a fluid-filled fetal area into the amniotic cavity, a shunt is placed through the uterus into the fetus.

## Indications

1. Hydrothorax
2. CPAM with dominant cyst
3. Lower urinary tract obstruction (LUTO)

## Selection Criteria for Shunts

### 1. Fetal hydrothorax

A fetal shunt is indicated if the following conditions are met:

- a. The hydrothorax is primary. It should not be part of a generalized hydrops disease

- b. The hydrothorax is hypertensive. This is evidenced by signs of intrathoracic tension such as flattening of the diaphragm, mediastinal shift to the contralateral side, and compression of the lungs
- c. Reaccumulation after a diagnostic tap
- d. The primary hydrothorax has led to a secondary non-immune hydrops provided the primary nature is clearly established
- e. Gestational age is less than 34 weeks

### 2. CPAM with a dominant cyst

A shunt in congenital pulmonary airway malformation (CPAM) is indicated if the following conditions are met:

- a. The CVR is greater than 1.6
- b. There are macrocysts visible within the lesion
- c. The diameter of the dominant cyst is more than one-third of the largest diameter of the lesion

article published online  
March 20, 2024

DOI <https://doi.org/10.1055/s-0044-1778738>.  
ISSN 2348-1153.

© 2024. Society of Fetal Medicine. All rights reserved.

This is an open access article published by Thieme under the terms of the Creative Commons Attribution-NonDerivative-NonCommercial-License, permitting copying and reproduction so long as the original work is given appropriate credit. Contents may not be used for commercial purposes, or adapted, remixed, transformed or built upon. (<https://creativecommons.org/licenses/by-nc-nd/4.0/>)

Thieme Medical and Scientific Publishers Pvt. Ltd., A-12, 2nd Floor, Sector 2, Noida-201301 UP, India

- d. The presence of hydrops is not a contraindication for shunting

### 3. Lower Urinary Tract Obstruction (LUTO)

Fetal shunt may be indicated if the following conditions are met

- The etiology of LUTO is posterior urethral valve
- Oligohydramnios
- Fetal urinalysis is favorable (see box)

#PLUTO study results are not encouraging

Indicators of preserved renal function (fetal urine\*)

Na < 100 mEq/L

Cl < 90 mEq/L

Osm < 210 mEq/L

Ca < 2 mmol/L

PO<sub>4</sub> < 2 mmol/L

β<sub>2</sub>-microglobulin < 6 mg/L

\*Third successive bladder tap every 24 h interval

### Maternal Risks

Risks to the mother are rare: less than 1 in 1,000

- Injury to the bowel or bladder
- Injury to inferior epigastric vessels leading to rectus sheath hematoma
- Injury to superficial uterine artery branches leading to hemoperitoneum

### Fetal Risks

Thoracoamniotic shunt (uncommon, < 1 in 100)

- Injury to intercostal arteries
- Injury to a rib
- Injury to the descending aorta
- Injury to the heart

Vesicoamniotic shunt (uncommon, < 1 in 100)

- Injury to the umbilical cord
- Injury to fetal bowel
- Herniation of fetal bowel

### Other Risks

- Preterm pre-labor rupture of membranes (5–10%)
- Procedure related miscarriage (within 2 weeks of procedure) (2–5%)
- Shunt expulsion from position (25% within first week)
- Chorionic vessel rupture (in a transplacental needle entry)
- Rh alloimmunization (Rh-negative pregnancy)

### Sample Counseling Statement for Hydrothorax

#### Fetal Hydrothorax

Detailed evaluation of the fetus revealed a massive (unilateral/bilateral) hydrothorax with signs of intrathoracic tension such as diaphragmatic inversion and significant mediastinal shift. Subtle findings such as mild subcutaneous

edema of the upper body and distended vena cava indicate impending hydrops. The following counseling points were discussed with the couple in detail:

- Primary hydrothorax, as in this fetus, is associated with a better prognosis than secondary hydrothorax.
- In view of the tension hydrothorax and imminent hydrops, the following management plan is recommended:
  - Immediate fetal karyotyping to rule out Down syndrome as there is a 5% reported association
  - Diagnostic thoracocentesis to tap the fluid and test for cell count, differential count, and viral markers
  - Close follow-up to exclude reaccumulation, which may warrant a pleuroamniotic shunt placement
- The prognosis improves from around 50% survival to more than 90% survival with treatment after ruling out secondary causes in isolated fetal hydrothorax
- The fetus needs to be under monitoring to rule out shunt migration, reaccumulation
- Delivery needs to be in a center with a tertiary neonatal intensive care unit (NICU) facility as postnatally the neonate needs to be under monitoring.

In the vast majority of primary chylothorax, postnatally there is spontaneous resolution.

### Sample Counseling Statement for Fetal CPAM with a Dominant Cyst

Detailed evaluation of the fetus revealed a massive echogenic lesion of the lung, and CPAM with a dominant cyst.

- The CPAM is large and causes significant mass effect. A dominant cyst more than one-third the total size of the CPAM is evident
- Since the CVR is more than 1.6, the risk of developing fetal hydrops is more than 75%
- Effective decompression of the dominant cyst by a thoracoamniotic shunt would increase the perinatal survival
- Post shunt, the fetus needs to be followed up for shunt failure, CPAM growth/regression, and fetal growth.
- Delivery needs to be in a tertiary setup with a NICU facility and pediatric surgery facility as many infants may require postnatal surgical intervention

### Sample Counseling Statement for Fetal Lower Urinary Tract Obstruction

Detailed evaluation of the fetus reveals findings consistent with LUTO secondary to the posterior urethral valve. There is bilateral hydronephrosis, distended thickened bladder, and proximal urethral dilatation.

- The decreasing trend of amniotic fluid is suggestive of progressive obstructive uropathy
- The renal parenchyma appears nondysplastic by ultrasound at present
- The renal function needs to be determined by serial bladder tap
- If serial bladder tap urinalysis reveals favorable findings, a vesicoamniotic shunt may be considered to relieve bladder obstruction



**Fig. 1** Harrison fetal bladder stent.

- The shunt increases the chance of perinatal survival but is unlikely to have a major impact on renal health in the long term

### Equipment, Devices, and Vendors

There are two principal types of shunts systems in use: **– Figs. 1 and 2**

- Harrison fetal bladder stent
- KCH-Rocket fetal bladder stent

### Preoperative Checklist and Patient Preparation

- Consent
- Antibiotic prophylaxis: 1 g Ceftriaxone 30 m before needle insertion
- Lignocaine test dose
- Confirm Rh status

- IV access for the mother
- Vaginal micronized progesterone 200 mg on the day and then for 2 days
- Nitroglycerine (NTG) patch 2 hours before the procedure
- Indomethacin 50mg per oral stat followed by 25 mg Q6h (until 48 h postprocedure)

### Personnel Required

- Operator
- Assistant trained in deploying the shunt or handling the ultrasound probe
- Circulating nurse to set tray and provide things
- Sonographic assistant to handle ultrasound machine

### Operating Room Requirement

The procedure may be performed in a clean ultrasound procedure room or an operation theatre.

A good resolution color Doppler ultrasound machine is required.

#### Tray Setting

- Sterile Prep Kit (sterile drapes, probe cover, sterile gel, SS cup, sponge forceps, gauzes)
- 1% Lignocaine 5mL for maternal anesthesia
- 11-blade scalpel
- Atracurium + fentanyl for fetal anesthesia
- Shunt kit: Pigtail catheter, introducer needle with a trocar, positioner, guidewire
- Suction apparatus (if amnioreduction is planned)
- 5 mL syringe (for lignocaine), 1 mL syringe (for fetal anesthesia), 23 g spinal needle (for fetal anesthesia)

### Procedure Steps

Before prepping the maternal abdomen, fetal accessibility is ascertained. Maternal repositioning to lateral decubitus,

Aspect	Harrison	KCH rocket
Catheter	Double Pig Tail, 5-Fr outer diameter (1.67 mm) Outer pigtail is double coil. Inner pigtail is single coil. Both pigtails orthogonal to shaft	Double Pig Tail, 2mm outer diameter. Proximal double coil and outer pigtail single coil and inner pigtail double coil. Only the outer pigtail is orthogonal to the shaft. Nonmagnetic steel inserts at the tips for ultrasound-enhanced visibility
Catheter shaft length	1.5–3.5 cm	
Guidewire	0.038 inch dia, 40 cm long	0.035 inch dia, 80 cm long
Introducer needle	13G (2.41 mm outer diameter) needle with trocar, 18 cm long	Proprietary trocar, 3 mm diameter, 15 cm long
Positioner/Pusher	Single, radiolucent Vinyl, 5-Fr, 24 cm long, with two “marking” levels	Set of two rods: short and long for deployment of the distal and proximal coils respectively
Vendor	Cook Medical Device Pvt. Ltd. 4/249A, Rasim Enclave, Poonamalee High Road Goparasanallur, Kattupakkam, Chennai Tamil Nadu, India - 600056 Phone: +91 44 26793000 Fax: +91 44 26791143 E-mail: india.orders@cookmedical.com	Vardhman Medicare Pvt Ltd Umesh Bhardwaj L-90/164, 2nd Floor, Street 7 Mahipalpur Extension New Delhi - 110037. INDIA Tel: +91-26786207, 26786208 Fax: +91-26786206 Help Line: +91-9811226146 Web: www.vardmanmedicare.net



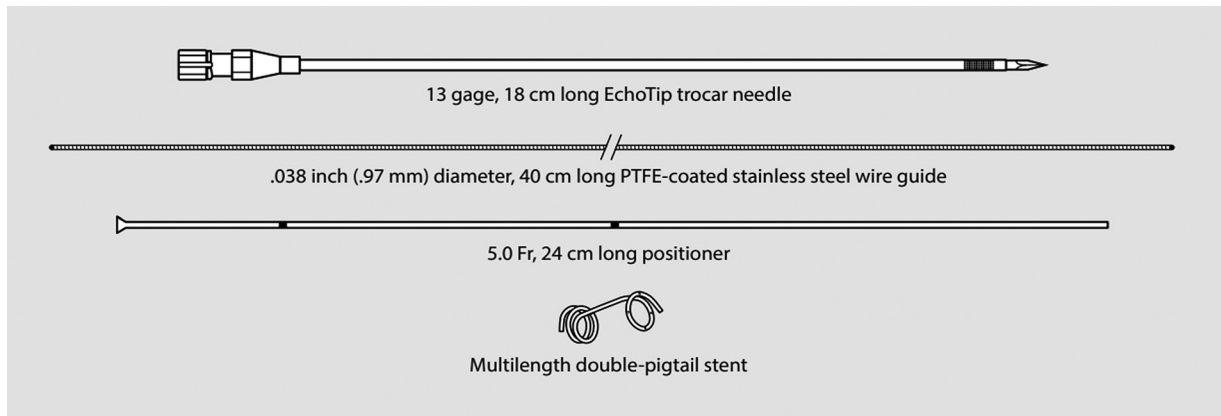
**Fig. 2** KCH-rocket fetal bladder stent.

Trendelenburg position, and external version of the fetus may all be employed as necessary to manipulate the fetus into a reasonable position.

1. The maternal abdomen is prepped and draped as usual
2. The ultrasound probe is sanitized with antiseptic and draped in a sterile manner
3. Access route is planned:
  - a. No maternal vessels in the abdominal wall or uterine serosa with color Doppler or power doppler at pulse repetition frequency (PRF) set around 1KHz
  - b. Nonplacental access to the amniotic cavity
  - c. For thoraco-amniotic shunt—aim for the posterior aspect of the fetal chest, below the scapula  
For a vesicoamniotic shunt—aim for the anterior abdominal wall, midline, below the cord insertion
  - d. Beware of a tightly wound cord around the fetal trunk in the line of fire (color Doppler)
4. Fetal anesthesia: Atracurium (0.4 mg/kg estimated fetal weight [EFW]) + fentanyl (15 mcg/kg EFW) mixed in a single syringe and given through a 23 g spinal needle directly into the fetal buttock, deltoid or umbilical vein, whichever is easiest to access.
5. Maternal lignocaine infiltration from the skin up to the peritoneum. Infiltration up to the myometrium decreases the discomfort of needle entry slightly but comes with the cost of myometrial focal contraction that makes subsequent needle manipulation difficult
6. A small 0.5 mm stab incision is made in the skin using an 11-blade. The introducer needle with trocar is then passed percutaneously through the myometrium into the amniotic cavity with a sharp controlled jab to avoid tenting the membranes.
7. Once inside the amniotic cavity, fine manipulation of the needle as well the anesthetized fetus is to be done such that the needle entry is in the desired target zone as stated above  
Tip: In the case of vesicoamniotic shunt, anhydramnios or severe oligohydramnios may hinder the deployment of the outer pigtail (step 15a). In such situations, infusion of

500mL of lukewarm Ringer lactate through the needle is recommended.

8. The fetus is entered with a sharp controlled jab.
  - Tip 1: Keep the needle tip absolutely perpendicular to the fetal trunk surface at the point of entry—otherwise the needle may glance off and cause damage to the uterine wall
  - Tip 2: The entry must be sharp otherwise fetus will roll away
  - Tip 3: The jab should be well controlled otherwise overshoot injury to the fetus or mother can happen
9. Once inside the thorax (effusion/cyst) or urinary bladder, a fine adjustment of the depth of the needle tip is made. When there is no fetal edema, the tip is kept at 2 cm deep inside the cyst or bladder. If there is edema, the tip is kept at 1 cm deep inside the cyst/effusion.
10. The guidewire is loaded with the catheter only after the needle entry is made and placed in the target location inside the fetus. This is to avoid the memory loss of coils.
11. The guidewire is loaded in the following manner: first, the positioner is threaded such that the fetal end of the positioner points toward the distal tip of the guidewire. Then the catheter is threaded such that the outer pigtail (double coil) is first threaded and the inner pigtail (single coil) is toward the distal tip of the guidewire.  
The orientation of the different components is as per the image (► Fig. 3).  
For the rocket KCH shunt, the positioner is not loaded over the guidewire.
12. The loaded guidewire is inserted into the needle trocar and pushed down toward the target zone  
Tip: while removing the trocar, immediately place the thumb over the needle hub, otherwise fluid will drain out making the deployment of the inner pigtail difficult
13. a. Harrison shunt  
Partially withdraw the guidewire by about 6 cm such that it is out of the catheter but still inside the positioner (although the manufacturer advises to remove it entirely, the positioner does not have enough tensile strength to push out the coil in many instances)
- b. Rocket shunt



**Fig. 3** The orientation of the different components.

Fully remove the guidewire and insert the short pushing rod.

14. a. Harrison shunt

Push the positioner (reinforced with the guidewire) down until the first marking reaches the needle hub. At this point, the inner pigtail will be deployed inside the target zone

b. Rocket shunt

Fully push the short rod inside.

15. a. Harrison shunt

Once the inner pigtail is deployed inside the fetus, hold the positioner firmly in place. Gently and slowly pull the needle out till the hub ascends up to the second marking on the positioner. This may require fine screwing motion of the needle to have a fine control. Once the needle is pulled up to the second marking, the outer pigtail (double coil) will be deployed in the amniotic cavity.

Tip 1: for successful deployment in the amniotic cavity, a good pocket of amniotic fluid is required. (see step 7, tip)

Tip 2: if the fluid pocket between the fetus and uterine wall is very limited, after exiting the fetal trunk, keep the needle tip inside the fluid pocket and do not proceed with further withdrawal. Use the positioner to push the outer pigtail into the amniotic cavity.

b. Rocket shunt

Once the inner pigtail is deployed inside the fetus, pull the needle and the pusher rod outside the fetus such that the needle tip is in the amniotic cavity. Remove the short rod and insert the long rod and push the outer pigtail completely out of the needle into the amniotic cavity.

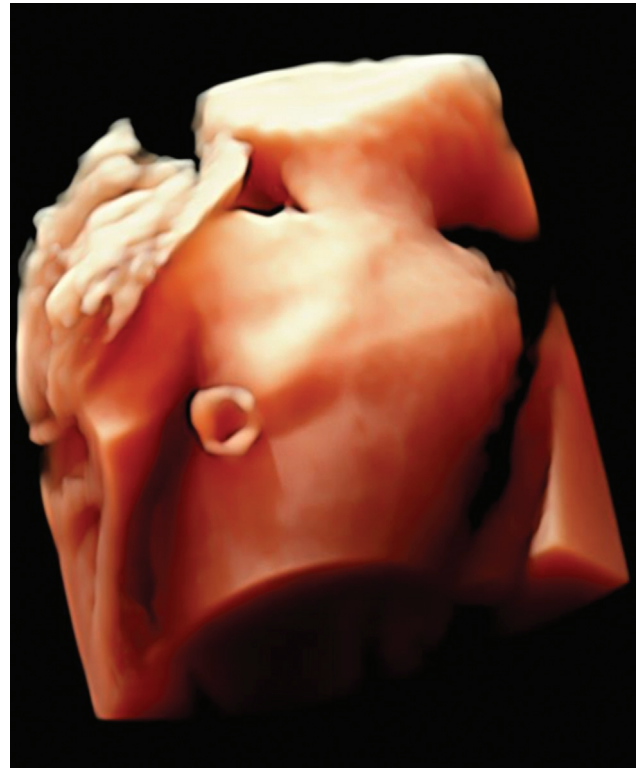16. After successfully deploying both the inner and outer pigtails, verify with ultrasound the correct placement.

There will be streaming of the fluid at the outer pigtail with the concomitant collapse of the fluid collection within the fetus (→ **Fig. 4**).

17. Remove the needle along with the positioner/pusher rod gently out. The stab incision generally does not require a stitch. An adhesive skin tape is applied.

### Postoperative Checklist

1. Document no free fluid in maternal flanks by ultrasound immediately at the end of the procedure and 3 hours postprocedure



**Fig. 4** Shunt in situ.

2. Document fetal heart activity and also show it to the mother at the end of the procedure and after 3 hours
3. Mother is given a couch for lying down for about 30 minutes after which she is allowed to ambulate and remain within the premises for the next 3 or 4 hours.
4. If there are no complaints from her, she is allowed to go home with the following advice:
  - a. Avoid overstraining/lifting heavy weights for a week
  - b. About 2 to 3% may experience light spotting of fluid or blood per vaginum—this is of no consequence
  - c. Report to the hospital immediately if there is substantial leaking, bleeding, pain, generalized feeling of unwellness or fever
  - d. Continue indomethacin 25 mg 6 hourly for a total of 48 hours

- e. Continue vaginal progesterone 200 mg once daily for two more days
5. A detailed procedure report is generated and one copy is handed over to the mother at the time of discharge.

### Postoperative Monitoring of Mother and Fetus

1. Mother's pulse and blood pressure (BP) recorded before the procedure, during the procedure, and immediately after the procedure
2. Pulse and BP recorded 30 minutes, 1 hour, and 3 hours after the procedure. If no tachycardia, no further monitoring is required.
3. Fetal heart activity is documented during and at the end of the procedure. Document after 3 hours before sending mother home
4. Maternal flanks are to be imaged and looked at for free fluid 3 hours after the procedure. Free fluid with normal vitals, usually is indicative of leaked amniotic fluid. This will usually get absorbed over 24 hours but may necessitate painkillers. If in doubt regarding the nature of the fluid, admission and close monitoring with or without a diagnostic tap will be required
5. Follow-up scans are scheduled after 1, 2, and 4 weeks from the procedure and thereafter according to the clinical situation.
6. Shunt migration is expected in about 15 to 20% of cases. The decision to reshunt depends on the findings and the discussion between the operator, the referring physician, and the patient's family
7. At the time of delivery,
  - a. For thoracoamniotic shunt in situ, the NICU team should be notified. The external coil is clamped immediately at birth and removed after adequate resuscitation
  - b. For vesicoamniotic shunt, it is left in situ until transurethral catheterization or if that is not possible definitive treatment is done

### Invasive Report Template

Patient name  
 Age  
 Husband name  
 Hospital ID  
 Gestational age  
 Indication  
 Procedure name  
 Maternal anesthesia  
 Fetal anesthesia  
 Control: continuous ultrasound guidance  
 Insertion needle: 23 g/3 mm  
 Shunt system used: Harrison/Rocket  
 Uterine entry: Midline, right/left, upper/lower quadrant  
 No of attempts: Single/double/multiple  
 Amnioinfusion: Yes /no  
 Amniodrainage: Yes/no  
 Fetal entry: Subscapular/lateral thoracic/subumbilical  
 Intraoperative complications:  
 Postoperative advice

**Conflict of Interest**  
 None declared.

**Acknowledgment**  
 Dr. Ashok Khurana for initiating and guiding to take forward this review article.

### Suggested Reading

- 1 Morris RK, Malin GL, Quinlan-Jones E, et al; Percutaneous vesicoamniotic shunting in Lower Urinary Tract Obstruction (PLUTO) Collaborative Group. Percutaneous vesicoamniotic shunting versus conservative management for fetal lower urinary tract obstruction (PLUTO): a randomised trial. *Lancet* 2013;382(9903):1496–1506
- 2 Nicolaidis KH, Azar GB. Thoraco-amniotic shunting. *Fetal Diagn Ther* 1990;5(3–4):153–164
- 3 Peranteau WH, Adzick NS, Boelig MM, et al. Thoracoamniotic shunts for the management of fetal lung lesions and pleural effusions: a single-institution review and predictors of survival in 75 cases. *J Pediatr Surg* 2015;50(02):301–305