



# Transumbilical Arterial Access for Embolization of a Hepatic Vascular Tumor in a Critically Ill Premature Neonate

Joe Khoury<sup>1</sup> Christopher D. Yeisley<sup>2</sup> 

<sup>1</sup> Department of Radiology, Cohen Children's Medical Center, Queens, New York, United States

<sup>2</sup> Department of Radiology, David Grant USAF Medical Center, Fairfield, California, United States

**Address for correspondence** Joe Khoury, DO, MBA, Department of Radiology, Cohen Children's Medical Center, 269-01 76th Ave, Queens, NY 11040, United States (e-mail: jkhourydo@gmail.com).

J Clin Interv Radiol ISVIR

## Abstract

Catheter-based interventions are relatively rare in the neonate population but serve as an invaluable tool in managing many pathologies. Here we present a case report of a neonate with a vascular hepatic tumor managed by embolization via transumbilical access. In neonates, the small size of the common femoral artery makes cannulation difficult and is thought to increase the risk of catheter-associated thrombosis and ischemia. Often, these patients reside in the neonatal intensive care unit (NICU) and already have an umbilical artery catheter (UAC) in place, which can be used as an effective alternative route of vascular access to carry out life-saving interventions.

## Keywords

- ▶ transumbilical
- ▶ embolization
- ▶ neonate

## Introduction

Catheter-based interventions are relatively rare in the pediatric population but serve as an invaluable tool in managing many pathologies. Here we present a case report of a neonate with a vascular hepatic tumor managed by embolization via transumbilical access. Transarterial embolization for hepatic lesions is a commonly performed procedure in adults, which is typically performed via a common femoral or radial artery puncture. In neonates, the femoral artery is small in caliber, making cannulation technically difficult. In this patient population, the umbilical artery is an ideal vessel for arterial access.<sup>1</sup> Transumbilical access for intervention in the neonate is rare, but has been performed safely and is described in the literature for embolization of vein of Galen malformations.<sup>2</sup>

## Case Report

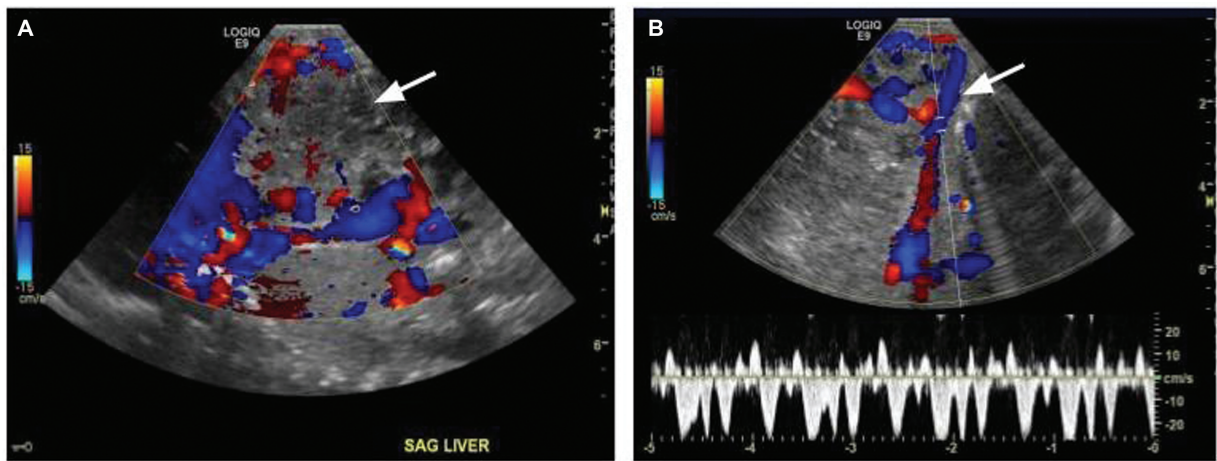
The patient was a premature male born at 31.5 weeks of gestation via emergent caesarean section for preterm labor to a 25-year-old G2P1 woman. Antepartum ultrasound (US) demonstrated hydrops fetalis (polyhydramnios and subcutaneous edema of the scalp, chest, and abdomen) and hepatomegaly with heterogeneous echogenicity and an area of increased vascularity. The birth was complicated by poor respiration and muscular tone requiring immediate intubation and transfer to the neonatal intensive care unit (NICU). An umbilical artery catheter (UAC) was placed on the first day of life. On subsequent US, the baby was found to have a 6.6-cm vascular hepatic mass occupying the left hepatic lobe, most consistent with a large hepatic congenital hemangioma (▶ **Fig. 1**). Echocardiography performed at 2 days

DOI <https://doi.org/10.1055/s-0044-1779015>.  
ISSN 2457-0214.

© 2024. Indian Society of Vascular and Interventional Radiology. All rights reserved.

This is an open access article published by Thieme under the terms of the Creative Commons Attribution-NonDerivative-NonCommercial-License, permitting copying and reproduction so long as the original work is given appropriate credit. Contents may not be used for commercial purposes, or adapted, remixed, transformed or built upon. (<https://creativecommons.org/licenses/by-nc-nd/4.0/>)

Thieme Medical and Scientific Publishers Pvt. Ltd., A-12, 2nd Floor, Sector 2, Noida-201301 UP, India

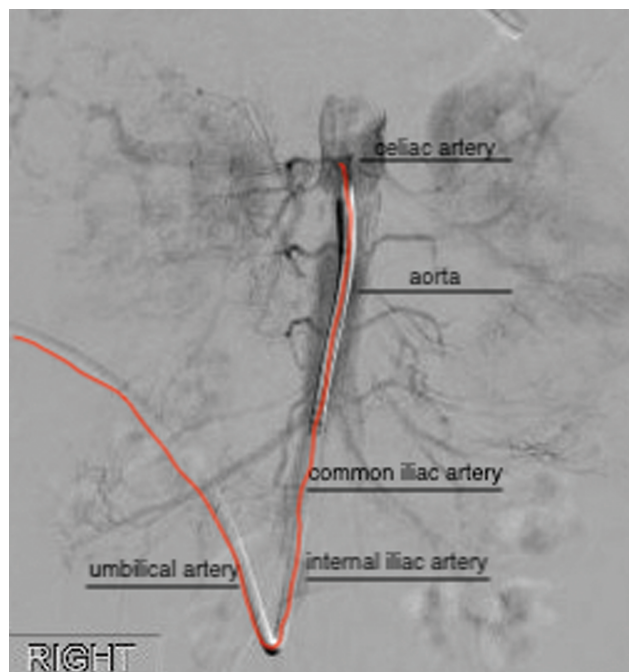


**Fig. 1** (A) Peripartum ultrasound demonstrating a heterogenous mass occupying the left hepatic lobe with areas of increased vascularity. (B) Color Doppler imaging of the hepatic lesion demonstrates dilated and tortuous hepatic veins at the periphery of the lesion with no definite evidence of arteriovenous malformation or fistula. Note: The first arrow is pointing to the vascular mass, as described.

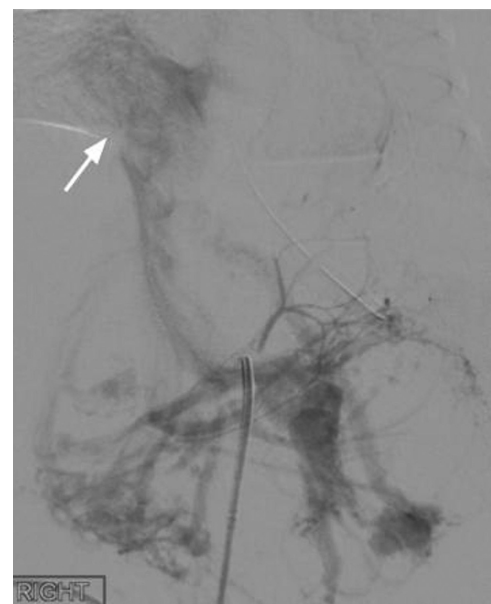
old showed an ejection fraction (EF) of 25% and multichamber cardiac dilatation.

Additionally, vascular shunting resulted in hepatic dysfunction and significant consumptive coagulopathy, with laboratory values including an international normalized ratio (INR) of 4.26 and thrombocytopenia as low as 36,000/ $\mu$ L. Multiple transfusions of fresh frozen plasma, packed red blood cells, and platelets were administered prior to intervention, which only modestly improved the patient's coagulopathy. Therefore, the decision was made to proceed to angiography.

The patient was brought to the angiosuite at 4 days old for arteriography and hepatic mass embolization. An initial aortogram was performed through the indwelling UAC. The umbilical artery access was preserved and the remainder of the case, including selective arteriography and embolization, was performed via a transumbilical approach (**Fig. 2**). The UAC was exchanged for a Merit 4-Fr Cobra 2 catheter (65 cm) over a guidewire. Arteriography demonstrated hypertrophy of the common hepatic and left hepatic arteries with a large area of tumor vascularity in the superior and left aspects of the tumor. Extensive



**Fig. 2** Diagram of the path of the diagnostic catheter from a transumbilical approach. Note: The arrow is pointing to the dilated hepatic veins, as described.



**Fig. 3** Extensive arteriovenous shunting (*arrow*) through the middle hepatic vein into the inferior vena cava (IVC). Note: The arrow is pointing to the arteriovenous shunting, as described.

arteriovenous shunting was noted from the inferior phrenic artery and left hepatic artery (►Fig. 3) and into the middle hepatic vein into the inferior vena cava (IVC).

Subselective arteriography was performed with a 2.3-Fr J&J MedTech Prowler Plus microcatheter (150 cm) and a 0.016-in Terumo Headliner guidewire. Embolization of the left hepatic artery (►Fig. 4A), a dominant right-sided branch of the left inferior phrenic artery, a left-sided branch of the inferior phrenic artery, and distal main left inferior phrenic artery (►Fig. 4B) was performed with a combination of 2- to 4-mm Medtronic Concerto detachable microcoils and 5- to 6-mm Medtronic microvascular plugs (MVPs). Postembolization arteriograms demonstrated successful occlusion of the left hepatic and left inferior phrenic artery branches with nonvisualization of the previously seen tumor vascularity and arteriovenous shunting. The procedural catheter was exchanged for a 3.5-Fr UAC, and the patient was transferred back to the NICU in stable condition.

Postprocedure, the patient's thrombocytopenia and coagulopathy improved. A repeat echocardiography at 1 day postprocedure demonstrated improved cardiac function with an EF of 52%. A repeat study 4 months later showed normal cardiac anatomy and function. The patient was discharged home and followed up with serial US over the next 2 years, demonstrating interval stability.

## Discussion

The small size of the common femoral artery in neonates makes cannulation difficult and is thought to increase the risk of catheter-associated thrombosis and ischemia.<sup>1</sup> Lower patient weight or younger patient age at the time of femoral artery access are associated with a significantly elevated

risk of arterial injury.<sup>3,4</sup> Additional complications include iliofemoral stenosis, claudication, and possible leg length discrepancies.<sup>5</sup>

Umbilical artery catheterization is a useful tool to administer fluid/medications, obtain blood gasses, and monitor blood pressure in critically ill neonates. A portion of the umbilical artery normally regresses within hours of birth becoming the medial umbilical ligament. However, if catheterized, the artery will remain patent and can serve as vascular access for interventional procedures.<sup>1</sup> Once the umbilical artery is catheterized, a wire and a catheter can be passed into the anterior division of the iliac artery and then the aorta and eventually to the location of interest.<sup>1</sup>

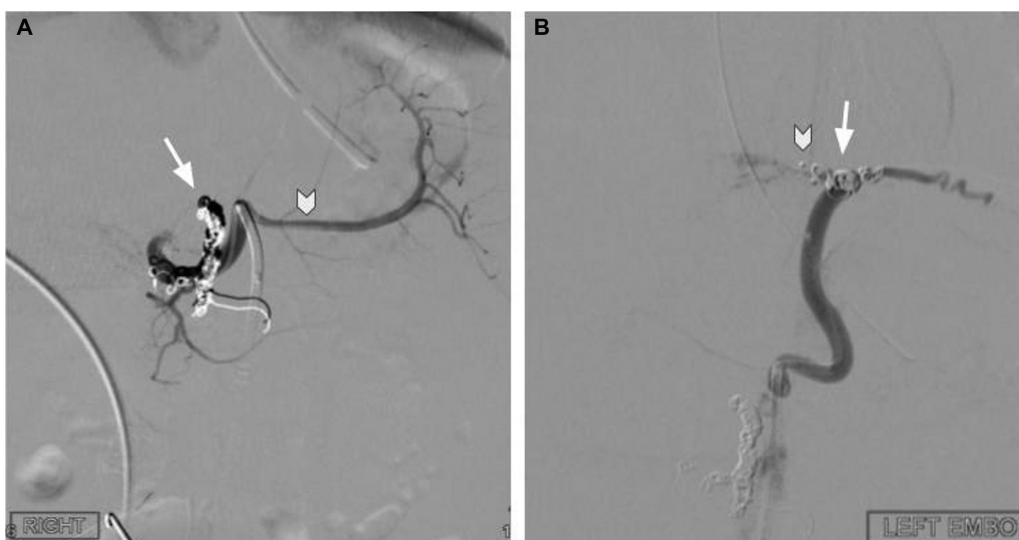Although crucial to survival for many patients, umbilical vascular catheters are not without risk of complications. UACs have been associated with an increased risk of vessel injury, vessel thrombosis, and infection.<sup>6</sup> Possible complications of transumbilical access for intervention are similar to femoral arterial access, but without the need or risk associated with a direct arterial puncture, and it allows for femoral or brachial artery preservation.<sup>1</sup>

## Conclusion

The management of critically ill premature neonatal patients requires careful consideration and a multidisciplinary team. When intervention is required, the umbilical artery offers safe vascular access with a lower complication profile than direct femoral cannulation, especially when the patients already have an indwelling UAC in place.

### Conflict of Interest

None declared.



**Fig. 4** (A) Coil embolization of the left hepatic artery (arrow) with nonvisualization of the previously seen tumor vascularity and arteriovenous shunting. Improved visualization of the splenic artery (arrowhead) after embolization. (B) Microvascular plug (MVP) occlusion of the dominant right-sided branch of the left inferior phrenic artery (arrowhead), and coil embolization of the left-sided branch of the inferior phrenic artery, and distal main left inferior phrenic artery (arrow) with nonvisualization of the previously seen tumor vascularity and arteriovenous shunting.

Note: The arrows and arrow heads are well described.

## References

- 1 Costa S, De Carolis MP, Di Stasi C, Papacci P, Fusco F, Romagnoli C. Transumbilical embolization of hepatic arteriovenous malformation in a neonate with heart failure. *Eur J Pediatr* 2006;165(11):807–809
- 2 Puvabanditsin S, Mehta R, Palomares K, et al. Vein of Galen malformation in a neonate: a case report and review of endovascular management. *World J Clin Pediatr* 2017;6(01):103–109
- 3 Bulbul ZR, Galal MO, Mahmoud E, et al. Arterial complications following cardiac catheterization in children less than 10 kg. *Asian Cardiovasc Thorac Ann* 2002;10(02):129–132
- 4 Vitiello R, McCrindle BW, Nykanen D, Freedom RM, Benson LN. Complications associated with pediatric cardiac catheterization. *J Am Coll Cardiol* 1998;32(05):1433–1440
- 5 Andraska EA, Jackson T, Chen H, Gallagher KA, Eliason JL, Coleman DM. Natural history of iatrogenic pediatric femoral artery injury. *Ann Vasc Surg* 2017;42:205–213
- 6 Sobczak A, Klepacka J, Amrom D, Żak I, Kruczek P, Kwinta P. Umbilical catheters as vectors for generalized bacterial infection in premature infants regardless of antibiotic use. *J Med Microbiol* 2019;68(09):1306–1313