





# Ureteroinguinal Herniation with Consecutive Ureteral Stricture in a 2-Month-Old Infant: Case Report

Carlos Delgado-Miguel<sup>1</sup> Antonio Jesus Muñoz-Serrano<sup>2</sup> Pablo Aguado<sup>2</sup> Ennio Fuentes<sup>2</sup> Ricardo Díez<sup>2</sup>

<sup>1</sup> Department of Pediatric Surgery, Hospital Universitario La Paz, Madrid, Spain

<sup>2</sup> Department of Pediatric Surgery, Hospital Universitario Fundación Jiménez Díaz, Madrid, Spain

**Address for correspondence** Carlos Delgado-Miguel, MD, Department of Pediatric Surgery, Hospital Universitario La Paz, Paseo de la Castellana, 261 Madrid, Madrid 28046, Spain (e-mail: carlosdelgado84@hotmail.com).

European J Pediatr Surg Rep 2024;12:e16–e19.

## Abstract

Inguinal herniation of ureter is an uncommon finding among children, with scarce reported cases in the literature to date, that can potentially lead to obstructive uropathy. We report a case of ureteroinguinal herniation discovered during an inguinal hernia repair in a patient with antenatally ultrasound finding of hydronephrosis. A 2-month-old infant with antenatal left hydronephrosis presented with left inguinal mass. Preoperative ultrasound showed an anechoic tubular image producing a mass effect on the left testicle, with suspected bladder herniation and/or dilated ureter toward the inguinal canal. An open surgical inguinal exploration was performed, where the left inguinal canal revealed a peritoneal sac and sliding of the dilated left ureter behind the sac, with a significant change in diameter, corresponding to the para-peritoneal variant of ureteroinguinal herniation. Ligation of the sac and replacement of the ureter into the retroperitoneum were performed, with improvement in the hydronephrosis observed on the ultrasound 1 month after the intervention. However, 6 months later, hydronephrosis worsening as well as the obstructive pattern observed in the diuretic renogram required removal of the stenotic ureteral segment and reimplantation of the healthy proximal segment in the bladder by open approach (Cohen's reimplantation). Follow-up ultrasound of the renal tract showed no dilatation of the upper renal tract and the renal function tests were normal. Currently, the patient is 2 years old and he remains asymptomatic. In conclusion, signs of ureteral obstruction such as hydronephrosis in patients with inguinal herniation may suggest the possibility of an ureteroinguinal hernia. Preoperative diagnostic suspicion is essential.

## Keywords

- ▶ ureteroinguinal hernia
- ▶ herniation of the ureter
- ▶ hydronephrosis
- ▶ upper urinary tract obstruction

## Introduction

Inguinal herniation of ureter is an uncommon finding among adults and even more so in children that can potentially lead to obstructive uropathy.<sup>1</sup> While inguinal hernias involving

the bladder are well described, ureter involvement remains an uncommon phenomenon, as it is a retroperitoneal structure.<sup>2</sup> There have been over 140 reported cases in adults, but only a few concerning pediatric patients.<sup>3</sup> We report a case of inguinal herniation of ureter discovered during an inguinal

received

May 18, 2023

accepted after revision

October 21, 2023

DOI <https://doi.org/10.1055/s-0044-1779253>.

ISSN 2194-7619.

© 2024. The Author(s).

This is an open access article published by Thieme under the terms of the Creative Commons Attribution License, permitting unrestricted use, distribution, and reproduction so long as the original work is properly cited. (<https://creativecommons.org/licenses/by/4.0/>)

Georg Thieme Verlag KG, Rüdigerstraße 14, 70469 Stuttgart, Germany

hernia repair in a patient with antenatally hydronephrosis ultrasound finding.

## Case Presentation

A male patient with antenatal left hydronephrosis, in whom an inguinal mass was discovered by the parents incidentally during bathing at 2 months of age. Examination revealed a reducible mass in the left inguinal region. Remaining physical examination was unremarkable, with both testes found in the scrotum. Preoperative ultrasound showed an anechoic tubular image producing a mass effect on the left testicle, with suspected bladder herniation and/or dilated ureter toward the inguinal canal.

An open surgical inguinal exploration was performed, where the left inguinal canal revealed a peritoneal sac and sliding of the dilated left ureter behind the sac, with a significant change in diameter, corresponding to the paraperitoneal variant of ureteroinguinal herniation (→Fig. 1A). The ureter emanated from the retroperitoneum and a loop lay inside the inguinal canal. Kinking and partial obstruction occurred at the level of the structure, leading to proximal dilation (→Fig. 1B). Ligation of the sac and replacement of the ureter into the retroperitoneum was performed. The patient was discharged the same day, few hours after surgery, without postoperative complications. One month after the intervention, an improvement in the hydronephrosis was observed on the ultrasound, so we decided to manage it conservatively, maintaining the antibiotic prophylaxis (amoxicillin), which had been started after birth. Renal scintigraphy showed no differences in size or renal function between the two kidneys (right kidney: 49.8%, 6.1 × 2.8 cm; and left kidney: 50.2%, 6.3 × 4 cm).

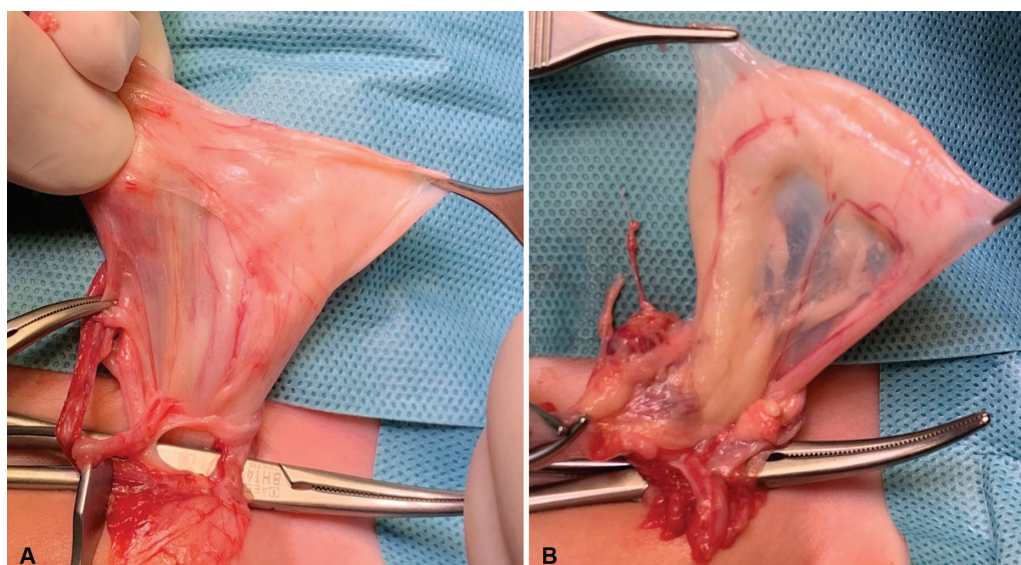
However, at 6 months postoperatively, a worsening of hydronephrosis was observed on ultrasound examination. Diuretic renogram showed a delayed arrival of the radiotracer on the left side compared with the right side, with a dilated

middle and proximal third of the left ureter compatible with ureteral obstruction. Due to these findings, an elective resection of the stenotic left ureter (5 cm in length) with remodeling and ureteral reimplantation according to Cohen's technique was performed using the Pfannenstiel approach. A double J stent was placed. The patient was discharged the following day. Six months later, after verifying complete correction of the hydronephrosis by ultrasound, double J stent was removed without incident. Follow-up ultrasound of the renal tract after double J stent removal showed no dilatation of the upper renal tract and the renal function tests were normal. Currently, the patient is 2 years old and he remains asymptomatic. We obtained the approval of the institutional ethics committee and the hospital review board (PI-6410). Written informed consent was obtained from parents of the patient to publish this study.

## Discussion

This case and literature review provide valuable insight into preoperative diagnostic difficulties, as well as the intra- and postoperative management of ureteroinguinal hernia in children, highlighting the importance of accurate diagnosis, close follow-up, and appropriate surgical intervention associated with this disease. While most cases of inguinal ureteral herniation have been reported in adults, only a few cases have been reported in children,<sup>4–13</sup> interestingly all of them in boys, with no description of this entity in girls to date. The median age reported at diagnosis was 4 months of age (range: 1 month–14 years), which is uncommon in children older than 18 months. Only two cases have been reported in adolescents, one with a past medical history of left inguinal hernia surgery when he was 1 year old, and the other case with a complex malformation (cloacal exstrophy).<sup>10,11</sup>

There are two variants of ureteroinguinal hernias based on their anatomical structure: the paraperitoneal type (80%),



**Fig. 1** Intraoperative images. (A) Hernia sac with sliding of the dilated left ureter behind the sac. (B) Significant change in ureteral diameter after hernia sac ligation.

with a true hernia sac that drags the ureter into the inguinal canal via traction, and the extraperitoneal type (20%), which does not have an associated hernia sac and is believed to be related to abnormal development of the urinary system, such as abnormal development of the Wolffian duct and adhesion between the primitive ureter and the genitofemoral ligaments.<sup>14</sup> Indeed, many cases of extraperitoneal hernias are associated with malformations of the kidney and urinary tract, such as wandering kidney and crossed renal ectopia, while paraperitoneal types are more commonly associated with vesicoureteral reflux, posterior urethral valve, giant ureter, and polycystic dysplastic kidney.<sup>15</sup> In this aspect, our case is atypical as it presents a ureteroinguinal herniation with no other associated renal anomalies.

In both types, there are often no specific symptoms other than distention of the inguinal region due to slipping of the ureter. As in our case, children with ureteral hernias rarely have any urinary symptoms and usually present with a mass in the inguinal or scrotal area. Symptoms owing to obstructive uropathy are not frequently seen, with hydronephrosis being described in only two of the other nine case reports. Most patients are asymptomatic, and routine urographic studies are usually not obtained preoperatively in these patients. For this reason, the diagnosis of ureteroinguinal hernia is often missed until surgical exploration.<sup>4</sup> However, if signs of ureteral obstruction, such as hydronephrosis or hydroureter, are observed in cases of inguinal herniation, the possibility of an inguinal ureteral hernia should be considered. Hydronephrosis may be secondary to angulation of the ureter or due to direct ureteral compression because of inflammation of other herniated contents.<sup>10</sup> In our case, the prenatal diagnosis of left hydronephrosis and the presence of the inguinoscrotal bulge on the same side put us on alert and we requested a scrotal ultrasound prior to surgery, which is not routinely performed in most children with suspected inguinal hernia. Other authors have reported preoperative intravenous urography or micturating cystourethrogram,<sup>8</sup> although these imaging tests involve ionizing radiation.

After diagnosis confirmation during surgical exploration, there are different treatment options depending on the individual appearance of the herniated loop of ureter. If there is no ureteral injury, most authors have repositioned the herniated ureters back into the retroperitoneum along with hernial repair.<sup>3,6,9,11</sup> However, in case of questionable viability, injury or severe dilated ureters, partial resection and anastomosis should be performed.<sup>10</sup> Temporary ureterocutaneostomy has been reported for extremely dilated ureters, with the intention of later reimplantation.<sup>7,8</sup> In cases with widespread ureteral involvement, ureteric repair can also be performed using transureteroureterostomy and appendiceal interposition.<sup>4</sup> In our case, although there was a significant change in ureteral caliber, we assumed that the ureteral kinking within the inguinal hernia was responsible for the dilatation of the proximal ureter and hydronephrosis due to the extrinsic compression, so the ureter was reintroduced into the abdominal cavity without performing any other associated surgical procedure. The presence of the ureter inside the hernia may have probably occurred during

pregnancy, which could explain the diameter change observed. Due to the good appearance of the ureter during surgery, well perfused, and not ischemic, we decided to perform conservative management and give an option for resolution of the hydronephrosis after correction of the hernia and repositioning of the ureter in the retroperitoneum. Postoperative monitoring for urinary tract obstruction is important in these patients, due to the risk of pyelonephritis or worsening of hydronephrosis.<sup>12</sup> Regular ultrasound scans are essential during follow-up, as they provide information on the dilatation of the urinary tract. Preventing pyelonephritis and subsequent renal scarring is essential in patients with ureterohydronephrosis, in whom antibiotic prophylaxis should be started soon after diagnosis.<sup>13,16</sup> In the case of breakthrough infections, early surgical intervention is required to prevent renal damage in the long term.<sup>1</sup> In our patient, the transient improvement in hydronephrosis after surgery allowed us to continue conservative management. However, hydronephrosis worsening 6 months after surgery and the obstructive pattern observed in the diuretic renogram required removal of the stenotic ureteral segment and subsequently healthy proximal segment reimplantation. Although ureteral release from the inguinal canal allowed an initial urinary tract dilatation improvement, the fibrosis of the stenotic ureteral segment required resection and reimplantation for definitive resolution of the hydronephrosis.

Laparoscopic approach in these patients is controversial. Although it may provide better visualization of the ureter entering the inguinal canal, hernia repair may require an open approach, as reported by Cianci et al.<sup>11</sup> In our case, laparoscopic approach would have determined the ureter entering the inguinal canal, next to the hernial sac, corresponding to the paraperitoneal variant of ureteroinguinal hernia, but ureteral dissection would have been more difficult and with less vascular control than with open surgery. Due to the preoperative suspicion of ureteroinguinal hernia, we performed a very careful inguinal dissection to avoid ureteral injury.

## Conclusion

Even though ureteral herniation in infants occurs sporadically, it is important to recognize to prevent ureteral damage during inguinal hernia repair or, as was described here, as it may lead to obstructive nephropathy. If there is a recognized urinary tract anomaly associated ipsilaterally as the hernia such as hydronephrosis, then ureteroinguinal hernia should be sought for preoperatively. Conversely, if one encounters ureteroinguinal hernia during routine herniotomy, an associated urinary tract anomaly should also be ruled out.

## Note

Ureteroinguinal hernia is an uncommon finding among children that can potentially lead to obstructive uropathy patients. The concomitant association of inguinal hernia and ipsilateral hydronephrosis should lead us to suspect this type of hernia. Preoperative suspicion is essential to avoid possible iatrogenic lesions in the ureter.

**Conflict of Interest**

None declared.

**References**

- 1 Bosschieter J, van Roij K, Ahmadi N, Bokenkamp A, van der Horst HJR. Kidney blow out due to inguinal herniation of the ureter in an infant. *Urol Int* 2018;100(04):488–490
- 2 Smith MT, Wong NC, Coleman JA. Inguinal hernia of the distal ureter causing hydronephrosis: a rare case. *Urol Case Rep* 2020;35:101549
- 3 Hosoda T, Hijikata K, Ishioka S. Rare case of inguinal ureteral hernia in a child diagnosed by drip infusion pyelography-computed tomography. *Int J Surg Case Rep* 2022;94:107007
- 4 Handu AT, Garge S, Peters NJ, Kanojia RP, Rao KL. Undiagnosed ureteroinguinal hernia with solitary kidney in a child with ureteric injury during herniotomy. *J Pediatr Surg* 2012;47(04):799–802
- 5 Morris LL, Caldicott WJ, Savage JP. Inguinal herniation of the ureter. *Pediatr Radiol* 1977;6(02):107–108
- 6 Powell MC, Kapila L. Bilateral megaureters presenting as an inguinal hernia. *J Pediatr Surg* 1985;20(02):175–176
- 7 Burgu B, Reşorlu B, Süer E, Soygür T. Scrotal hernia of the ureter in association with posterior urethral valves. *J Pediatr Urol* 2010;6(01):87–88
- 8 Sripathi S, Rajagopal K, Kakkar C, Polnaya A. Case report-inguinoscrotal ureteral hernia diagnosed on micturating cystourethrography. *Indian J Radiol Imaging* 2011;21(03):199–201
- 9 Cao K, Turner M, Mishrah P, Cuckow P. The rare case of an extraperitoneal ureteral herniation into the inguinal canal of a 12-year-old boy. *Ann R Coll Surg Engl* 2019;101(01):e32–e34
- 10 Wishahi M. Congenital primary obstructed megaureter presenting as inguinal hernia in an infant. *Clin Case Rep* 2022;10(04):e05677
- 11 Cianci MC, Tocchioni F, Mantovani A, Ghionzoli M, Morini F. Unexpected pediatric uretero-inguinal hernia: case-report and literature review. *Urology* 2023;176:178–182
- 12 Verbeeck N, Niedercorn JB, Mc Intyre D, Pouthier D, Lamy S. Assessment of renal graft obstruction due to ureteral inguinal hernia: US detection and 3D MR confirmation. *JBR-BTR* 2007;90(02):132–134
- 13 Autore G, Bernardi L, Ghidini F, et al; The Uti-Ped-Er Study Group. Antibiotic prophylaxis for the prevention of urinary tract infections in children: guideline and recommendations from the Emilia-Romagna Pediatric Urinary Tract Infections (UTI-Ped-ER) study group. *Antibiotics (Basel)* 2023;12(06):1040
- 14 Giglio M, Medica M, Germinale F, et al. Scrotal extraperitoneal hernia of the ureter: case report and literature review. *Urol Int* 2001;66(03):166–168
- 15 Rocklin MS, Apelgren KN, Slomski CA, Kandzari SJ. Scrotal incarceration of the ureter with crossed renal ectopia: case report and literature review. *J Urol* 1989;142(2 Pt 1):366–368
- 16 Holzman SA, Braga LH, Zee RS, et al. Risk of urinary tract infection in patients with hydroureter: an analysis from the Society of Fetal Urology Prenatal Hydronephrosis Registry. *J Pediatr Urol* 2021;17(06):775–781