Article published online: 2024-04-21

Demystifying the Mystery of Genes: A Case Report on Constitutional Mismatch Repair Deficiency

Jose Siju[1] Arpita Sahu[1] Kajari Bhattacharya[1] Maya Prasad[2] Rajiv Sarin[3] Tejpal Gupta[3]

[1] Department of Radiodiagnosis, Tata Memorial Hospital, Mumbai, Maharashtra, India
[2] Department of Paediatric Medical Oncology, Tata Memorial Hospital, Mumbai, Maharashtra, India
[3] Department of Radiation Oncology, Tata Memorial Hospital, Mumbai, Maharashtra, India

Address for correspondence Arpita Sahu, MD, Department of Radiodiagnosis, Tata Memorial Hospital, Mumbai 400012, Maharashtra, India (e-mail: drarpitasahu@gmail.com).

Indian J Radiol Imaging 2024;34:562–565.

Abstract

Constitutional mismatch repair deficiency (CMMRD) is a rare childhood cancer predisposition syndrome that results from biallelic germline mutations in one of the four MMR genes, MLH1, MSH2, MSH6, or PMS2. This syndrome is characterized by a broad spectrum of early-onset malignancies, including hematologic malignancies, colorectal malignancies, brain tumors, and other malignancies. It is common to have more than one malignancy in an individual diagnosed with CMMRD. In addition to malignancies, primary immunodeficiency in the form of low or absent immunoglobulin levels can also be seen in CMMRD. Congenital abnormalities such as agenesis of the corpus callosum (ACC), cavernous hemangioma, and other non-neoplastic diseases can also be linked to it. In this case report, we discussed the case of a girl born out of consanguineous marriage initially identified as having T-cell acute lymphoblastic lymphoma and later found to have selective immunoglobulin A (IgA) deficiency. Her younger sibling with a pontine cavernous hemangioma was also diagnosed with lymphoma. The girl exhibited brain lesions on magnetic resonance imaging (MRI), which were initially diagnosed as posterior reversible encephalopathy syndrome (PRES) related changes; however, one of the lesions persisted and remained stable over a period of 2 years and more in favor of diffuse glioma. The younger sibling also showed a solitary lesion in the brain. Based on the clinical and radiological findings, a diagnosis of CMMRD was suspected. Next-generation sequence (NGS) analysis of her blood sample was done. The results showed a homozygous mutation in the MSH6 gene was diagnostic of CMMRD.

Keywords
- CMMRD
- IgA
- MMR
- MSH6

article published online
April 21, 2024

DOI https://doi.org/10.1055/s-0044-1779586.
ISSN 0971-3026.

© 2024. Indian Radiological Association. All rights reserved.
This is an open access article published by Thieme under the terms of the Creative Commons Attribution-NonDerivative-NonCommercial-License, permitting copying and reproduction so long as the original work is given appropriate credit. Contents may not be used for commercial purposes, or adapted, remixed, transformed or built upon. (https://creativecommons.org/licenses/by-nc-nd/4.0/)
Thieme Medical and Scientific Publishers Pvt. Ltd., A-12, 2nd Floor, Sector 2, Noida-201301 UP, India

Introduction

Constitutional mismatch repair deficiency (CMMRD) is a rare childhood cancer predisposition syndrome that results from biallelic germline mutations in one of the four MMR genes, MLH1, MSH2, MSH6, or PMS2. These genes can identify and correct incorrect base insertion, deletion, and disincorporation that may occur during deoxyribonucleic acid (DNA) damage, replication, and recombination.[1] These genes are also associated with immunoglobulin (Ig) class switch recombination.[2,3] This condition is characterized by a wide range of early-onset malignancies, such as brain tumors, colorectal cancers, hematologic cancers, and others.[4]

Here we presented the case of a girl child patient with T-cell acute lymphoblastic lymphoma and selective immunoglobulin A (IgA) deficiency who was later diagnosed with CMMRD.

Case History

An 11-year-old girl who was born out of a consanguineous marriage presented with a history of dyspnea and orthopnea. Chest radiography and computed tomography (CT) scan revealed the presence of an anterior mediastinal mass that was diagnosed as T-cell acute lymphoblastic lymphoma, for which she was started with chemotherapy. She experienced repeated seizures shortly after that, along with vision loss, which was treated with antiepileptic drugs. The frontal and parietal lobes on magnetic resonance imaging (MRI) displayed multiple cortical and subcortical T2/fluid attenuated inversion recovery (FLAIR) hyperintensities showing subtle enhancement; these did not exhibit any diffusion restriction (►**Fig. 1**). Blood culture and cerebrospinal fluid (CSF) analysis did not reveal any signs of infection. However, a thorough clinical history revealed that hypertension was present at the time of the seizure events. A diagnosis of hypertension-induced posterior reversible encephalopathy syndrome (PRES) was given and she was managed with antiepileptics and antihypertensives.

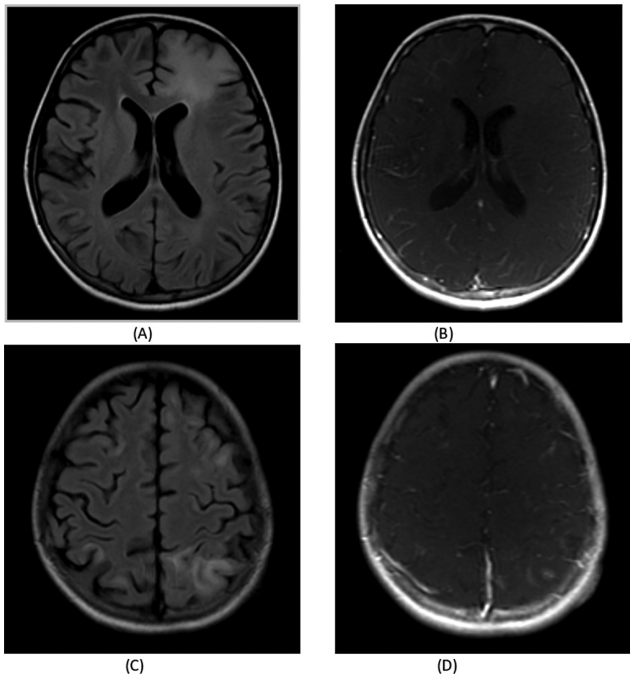

Fig. 1 (A–D) Baseline magnetic resonance imaging (MRI) of the brain of the girl shows multiple cortical and subcortical T2/fluid attenuated inversion recovery (FLAIR) hyperintensities in bilateral frontoparietal lobes showing subtle enhancement.

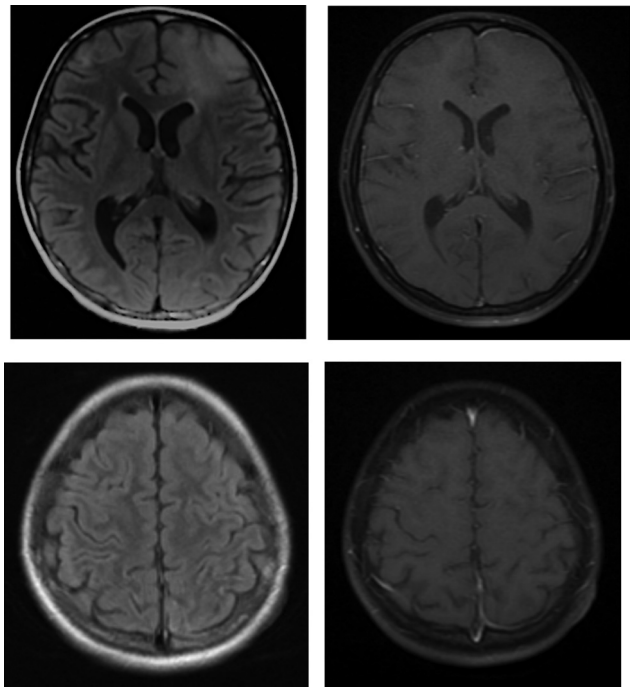

Fig. 2 Follow-up magnetic resonance imaging (MRI) of the brain after 2 years showing persistence of left frontal lobe signal and disappearance of the bilateral high frontoparietal lobe lesions.

A follow-up scan was done after 3 months, which showed partial resolution of the brain lesions in the bilateral frontoparietal lobes, and later at 2 years, they showed complete resolution. However, the lesion in the left frontal lobe subcortical and deep white matter location persisted, which was subtly enhancing, T2/FLAIR hyperintense, and showed no diffusion restriction (►**Fig. 2**). Magnetic resonance spectroscopy (MRS) study showed elevated choline levels with depressed N-acetyl aspartate (NAA) levels in the lesion, having a choline-to-NAA ratio of 1.81. This raised the suspicion of diffuse glioma in addition to the already known diagnosis of PRES. She also began experiencing recurrent lower respiratory tract infection (LRTI) attacks and was repeatedly hospitalized as a result. The existence of a polymicrobial infection involving *Cladophialophora* and *Haemophilus influenza* spp. was discovered by bronchoalveolar lavage. The girl had a specific IgA deficiency, as determined by an Ig panel.

In addition to having a comparable history of dyspnea, her younger sibling also had an anterior mediastinal tumor that was later determined to be a T-cell acute lymphoblastic lymphoma. He had a pontine cavernous hemangioma, which was known. A routine follow-up MRI revealed a single subcortical T2/FLAIR hyperintensity in the left high frontal lobe in the subcortical white matter, which showed no enhancement and no restricted diffusion (►**Fig. 3**).

 © 2024. Indian Radiological Association. All rights reserved.

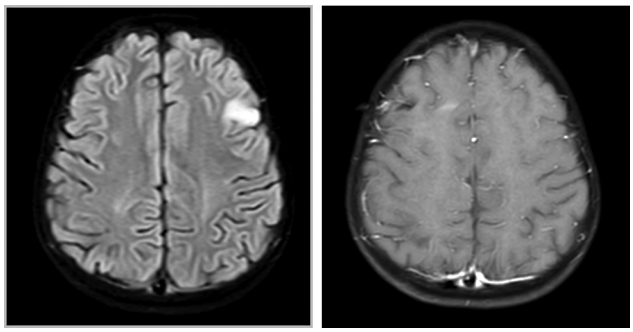

Fig. 3 Magnetic resonance imaging (MRI) of the brain of the younger sibling showing nonenhancing T2/fluid attenuated inversion recovery (FLAIR) hyperintensity in the subcortical region of the left frontal lobe.

A syndrome that could explain these findings was suspected and the case was discussed in a multidisciplinary clinic. Later, it was discovered that the girl had a homozygous MSH6 gene mutation, which was indicative of constitutional mismatch repair impairment (CMMRD). Later her brother was also tested and he was also found to have a homozygous MSH6 gene mutation.

Discussion

One of the four MMR genes—MLH1, MSH2, MSH6, or PMS2—can develop a biallelic germline mutation that causes CMMRD, a syndrome that predisposes people to cancer. It has a substantial correlation with hematologic cancers, high-grade gliomas (HGGs) in the brain, and colon cancers of the Lynch syndrome (LS) spectrum.[4,5] It is not unusual for someone with CMMRD to have multiple primary cancers. It also resembles neurofibromatosis type 1 (NF1) phenotypically.[6]

According to Wimmer et al,[4] of all the hematologic malignancies associated with CMMRD, the most commonly seen is non-Hodgkin's lymphoma (NHL) accounting for about 14% of all CMMRD-associated malignancies. Among these, 65% of CMMRD-associated NHL were of T-cell lineage and at least 42% were T-cell lymphoblastic lymphomas.[4,7] Both the siblings mentioned in the case were initially diagnosed with T-cell acute lymphoblastic lymphoma.

Less cases of CMMRD have been documented in which selective IgA deficiency was reported. It leads to more serious and persistent infections. Yet, neither is this finding too uncommon in the general population nor is it a finding specifically for CMMRD. Impaired Ig class switch recombination has been found to result from a constitutional deficit of the PMS2 and MSH6 genes.[8,9] IgG2, IgG4, and IgA levels may drop or disappear as a result, and IgM levels may rise. The same argument can be made for parents who were married consanguineously, as consanguinity is common among many ethnic and religious groups and cannot be considered unique to CMMRD.[4]

Both neoplastic and non-neoplastic characteristics may be present in imaging that are frequently observed in CMMRD. The most frequent malignant findings are diffuse astrocytoma and glioblastoma.[10,11] Developmental venous anomalies (DVAs) and cavernous hemangiomas are examples of non-neoplastic abnormalities.[12,13] A known incidence of pontine cavernous hemangioma in the sibling mentioned in the case added to the suspicion of CMMRD. In addition, individuals with CMMRD can exhibit nonspecific subcortical T2/FLAIR hyperintensities, primarily in the frontal and parietal lobes. They typically do not exhibit diffusion restriction or enhancement. Most of the time, these lesions are stable, although they can develop into gliomas later on due to malignant change.[10,14] Thus, imaging should be used to periodically monitor such lesions. The index case had subcortical T2/FLAIR hyperintensities involving the left frontal lobe and bilateral high frontoparietal lobe, which were subtly enhancing and showed no diffusion restriction (►**Fig. 1**). They were initially thought to be PRES-related changes. The bilateral high frontoparietal lobe lesions gradually resolved over the next 2 years, but the frontal lobe lesion persisted (►**Fig. 2**). It was also seen involving the deep white matter. Further, an MRS study of this lesion showed elevated choline levels with depressed NAA levels and choline-to-NAA ratio of 1.81. MRS is a noninvasive imaging method that detects metabolite signals, like choline-containing compounds (Cho), NAA, and creatine (Cr). This can help identify malignant lesions like gliomas and can also help in grading gliomas into low-grade gliomas (LGGs) and HGG. Studies have shown that Cho:NAA values between 1.2 and 1.8 (mean: 1.6) are suggestive of LGGs and those between 2.0 and 7.5 (mean: 5.1) are suggestive of HGGs.[15] Hence, the lesion seen in the index case was more in favor of diffuse infiltrative glioma. The younger sibling also showed solitary T2/FLAIR hyperintensity in the subcortical region of the high frontal lobe, which was nonenhancing and showed no diffusion restriction (►**Fig. 3**). It could represent a nonspecific subcortical T2/FLAIR hyperintensity usually seen in cases of CMMRD or could be a diffuse glioma.

For several reasons, a CMMRD diagnosis that is both accurate and early is crucial. Providing screening or surveillance for the often-linked malignancies can increase long-term survival rates because these people are more likely to develop numerous malignancies over time.[16] The increased likelihood that family members would develop cancer is still another cause for concern. Siblings may have a 25% chance of recurrence, and heterozygous mutation carriers—especially both parents—had a higher risk of LS-related malignancy.[4] Hence, it is important to keep an eye on your first-degree relatives. Through genetic counseling, the families of those who are afflicted should be made aware of the illness and its effects.

A 3-point scoring system for clinical indicators that should trigger suspicion for CMMRD has been proposed by the European consortium "Care for CMMRD." According to Wimmer et al,[4] the girl, in this case, had a score of 5, which raised a strong suspicion for CMMRD.

Conclusion

CMMRD is a rare cancer predisposition syndrome, which necessitates the importance of surveillance and screening of both the affected individuals and their close relatives. The

 © 2024. Indian Radiological Association. All rights reserved.

available information regarding this syndrome is substantial, but further focused systematic studies are necessary for collecting data on screening and treatment of this condition. This will help in formulating better recommendations for the management of CMMRD.

Funding
None.

Conflict of Interest
None declared.

References

1 Jiricny J. The multifaceted mismatch-repair system. Nat Rev Mol Cell Biol 2006;7(05):335–346
2 Péron S, Metin A, Gardès P, et al. Human PMS2 deficiency is associated with impaired immunoglobulin class switch recombination. J Exp Med 2008;205(11):2465–2472
3 Martin A, Scharff MD. AID and mismatch repair in antibody diversification. Nat Rev Immunol 2002;2(08):605–614
4 Wimmer K, Kratz CP, Vasen HF, et al; EU-Consortium Care for CMMRD (C4CMMRD) Diagnostic criteria for constitutional mismatch repair deficiency syndrome: suggestions of the European consortium "care for CMMRD" (C4CMMRD). J Med Genet 2014;51(06):355–365
5 Scott RH, Mansour S, Pritchard-Jones K, Kumar D, MacSweeney F, Rahman N. Medulloblastoma, acute myelocytic leukemia and colonic carcinomas in a child with biallelic MSH6 mutations. Nat Clin Pract Oncol 2007;4(02):130–134
6 Whiteside D, McLeod R, Graham G, et al. A homozygous germ-line mutation in the human MSH2 gene predisposes to hematological malignancy and multiple café-au-lait spots. Cancer Res 2002;62(02): 359–362
7 Scott RH, Homfray T, Huxter NL, et al. Familial T-cell non-Hodgkin lymphoma caused by biallelic MSH2 mutations. J Med Genet 2007;44(07):e83
8 Gardès P, Forveille M, Alyanakian MA, et al. Human MSH6 deficiency is associated with impaired antibody maturation. J Immunol 2012;188(04):2023–2029
9 Péron S, Metin A, Gardès P, et al. Human PMS2 deficiency is associated with impaired immunoglobulin class switch recombination. J Exp Med 2008;205(11):2465–2472
10 Kerpel A, Yalon M, Soudack M, et al. Neuroimaging findings in children with constitutional mismatch repair deficiency syndrome. Am J Neuroradiol 2020;41(05):904–910
11 Johannesma PC, van der Klift HM, van Grieken NC, et al. Childhood brain tumours due to germline bi-allelic mismatch repair gene mutations. Clin Genet 2011;80(03):243–255
12 Shiran SI, Ben-Sira L, Elhasid R, et al. Multiple brain developmental venous anomalies as a marker for constitutional mismatch repair deficiency syndrome. Am J Neuroradiol 2018;39(10): 1943–1946
13 Jones BV, Linscott L, Koberlein G, Hummel TR, Leach JL. Increased prevalence of developmental venous anomalies in children with intracranial neoplasms. Am J Neuroradiol 2015;36(09): 1782–1785
14 Michaeli O, Tabori U. Pediatric high grade gliomas in the context of cancer predisposition syndromes. J Korean Neurosurg Soc 2018;61(03):319–332
15 Hasan AMS, Hasan AK, Megally HI, et al. The combined role of MR spectroscopy and perfusion imaging in preoperative differentiation between high- and low-grade gliomas. Egypt J Radiol Nucl Med 2019;50:72
16 Vasen HF, Ghorbanoghli Z, Bourdeaut F, et al; EU-Consortium Care for CMMR-D (C4CMMR-D) Guidelines for surveillance of individuals with constitutional mismatch repair-deficiency proposed by the European Consortium "Care for CMMR-D" (C4CMMR-D). J Med Genet 2014;51(05):283–293

 © 2024. Indian Radiological Association. All rights reserved.