Article published online: 2024-02-16

Delineation of *ADPRHL2* Variants: Report of Two New Patients with Review of the Literature

Sibel Öz Yıldız[1] Dilek Yalnızoğlu[1] Pelin Özlem Şimsek Kiper[2] Rahşan Göçmen[3] Merve Soğukpınar[2] Gülen Eda Utine[2] Göknur Haliloğlu[1]

[1] Division of Pediatric Neurology, Department of Pediatrics, Hacettepe University Faculty of Medicine, Ankara, Turkey
[2] Division of Pediatric Genetics, Department of Pediatrics, Hacettepe University Faculty of Medicine, Ankara, Turkey
[3] Department of Radiology, Hacettepe University Faculty of Medicine, Ankara, Turkey

Address for correspondence Göknur Haliloğlu, MD, Division of Pediatric Neurology, Department of Pediatrics, Hacettepe University Faculty of Medicine, 06230, Ankara, Turkey (e-mail: gtuncer@hacettepe.edu.tr).

Neuropediatrics 2024;55:156–165.

Abstract

ADPRHL2 is involved in posttranslational modification and is known to have a role in physiological functions such as cell signaling, DNA repair, gene control, cell death, and response to stress. Recently, a group of neurological disorders due to *ADPRHL2* variants is described, characterized by childhood-onset, stress-induced variable movement disorders, neuropathy, seizures, and neurodegenerative course. We present the diagnostic pathway of two pediatric patients with episodic dystonia and ataxia, who later had a neurodegenerative course complicated by central hypoventilation syndrome due to the same homozygous *ADPRHL2* variant. We conducted a systematic literature search and data extraction procedure following the Preferred Reporting Items for Systematic Review and Meta-Analysis 2020 statement in terms of patients with *ADPRHL2* variants, from 2018 up to 3 February, 2023. In total, 12 articles describing 47 patients were included in the final analysis. Median age at symptom onset was 2 (0.7–25) years, with the most common presenting symptoms being gait problems ($n = 19$, 40.4%), seizures ($n = 16$, 34%), ataxia ($n = 13$, 27.6%), and weakness ($n = 10$, 21.2%). Triggering factors (28/47; 59.5%) and regression (28/43; 60.4%), axonal polyneuropathy (9/23; 39.1%), and cerebral and cerebellar atrophy with white matter changes (28/36; 77.7%) were the other clues. The fatality rate and median age of death were 44.6% ($n = 21$) and 7 (2–34) years, respectively. *ADPRHL2* variants should be considered in the context of episodic, stress-induced pediatric and adult-onset movement disorders and seizures.

Keywords
- *ADPRHL2*
- episodic ataxia
- dystonia
- dyskinesia
- central hypoventilation

Introduction

ADP-ribosylation (ADPr) is the transfer of a single or poly-ADP-ribose unit(s) from nicotinamide adenine dinucleotide (NAD) onto target protein substrates. It is a reversible posttranslational modification (PTM) involved in numerous physiological functions, such as cell signaling, DNA repair, gene control, and cell death.[1] Poly-ADP ribosyl synthesis increases rapidly under stress by up to 500-folds.[2] After the resolution of the original stress factors, ADP ribose polymers (PAR) are removed from the environment by ADP ribosyl

received
September 27, 2023
accepted after revision
December 29, 2023
article published online
February 16, 2024

© 2024. Thieme. All rights reserved.
Georg Thieme Verlag KG,
Rüdigerstraße 14,
70469 Stuttgart, Germany

DOI https://doi.org/10.1055/s-0044-1779618.
ISSN 0174-304X.

This document was downloaded for personal use only. Unauthorized distribution is strictly prohibited.

hydrolase (ARH) and poly-ADP-ribose glycohydrolase (PARG). The ARH3, which shows hydrolytic activity against proteins modified by ADPr, is encoded by the *ADPRHL2* gene (MIM #610624). Although PAR modification may protect the cell from death in the cellular stress environment, excessive cumulation of PAR or the inability to reverse PAR modification may trigger a cell death response cascade. Posttranslational splicing of proteins during physiological stress is eliminated by this enzyme. As a result of ARH3 deficiency, PAR, which can be cytotoxic and proapoptotic, accumulates and leads to cell death.[3] Neurodegeneration, childhood-onset, stress-induced, with variable ataxia and seizures (CONDSIAS, MIM #618170) is a recently discovered autosomal recessive neurodegenerative disorder with onset in the first years of life following normal early development. The genetic etiology of this rare entity, due to homozygous variants in the *ADPRHL2*, has been revealed in 2018.[4,5] In this article, we aimed to present two new patients with *ADPRHL2 (ADPRS* or *ARH3)* variants and to review the literature.

Materials and Methods

Patients

Two children who presented to our Division of Pediatric Neurology with *ADPRHL2* variants were included. Clinical, laboratory, and diagnostic pathway details of the patients with follow-up findings and outcome were reported.

Search Strategy for Systematic Literature Review

We conducted a systematic literature search and data extraction procedure following the Preferred Reporting Items for Systematic Review and Meta-Analysis (PRISMA) 2020 statement.[6] We screened PubMed/MEDLINE and Scopus. We entered the keywords of "Adprhl2," or "Adprs," or "Arh3" and searched all literature from the inceptions of the databases 2018 to 2023. Articles in English were assessed for eligibility using the title, abstract, or full text, as necessary. The publications of the same research group were closely analyzed for overlapping datasets. Case reports/series, original research articles, editorials, and review articles including patients with *Adprhl2/Adprs/Arh3* variants were evaluated. The articles, including data on patients with these variants, have been evaluated in the final analysis. Two authors (G.H. and S.Ö.Y.) independently screened titles, abstracts, and full texts of all relevant articles. Current age or age of death, outcomes of the patients, gender, age at symptom onset, presenting symptom, age of progressive disease course, consanguinity, developmental milestones, clinical symptoms, triggering factors, respiratory insufficiency, endocrine, cardiac abnormalities and electroencephalogram (EEG), nerve conduction studies, muscle biopsy, and magnetic resonance imaging (MRI) findings were included whenever available.

Statistical Analysis

Minimum, maximum, and median values were calculated as descriptive statistics in the IBM SPSS statistics 22 program. The percentage of each data is calculated based on the number of data accessed in the articles rather than the total number of patients and is marked with * in ►**Table 1**.

Results

Case 1

A 2-year-9-month-old boy presented to our Pediatric Neurology outpatient clinic with an onset of episodic head tilt during the last 6 months. These attacks were characterized by alternative tilt of the head to left or right, lasting for 5 minutes without loss of consciousness. There were no abnormal eye deviations. At the time of head tilt to either side, he had ipsilateral leg limping as well. These episodes usually occurred once per week and lasted for about 2 months and resolved without any treatment. However, there has been a recurrence of these attacks within the last 6 weeks. During the follow-up, there has been a marked increase in frequency. These attacks were accompanied by progressive gait disturbances and frequent falls and resulted in gradual loss of independent ambulation.

Prenatal, natal, and postnatal histories were uneventful. Other than a delay in expressive language, developmental milestones were reported to be age appropriate. The parents were first cousins. Family history was otherwise negative. Anthropometric measurements revealed, head circumference 49.5 cm (75p), body weight 15.5 kg (75–90p), and height 102 cm (>97p). Physical examination was normal. Neurological examination revealed mild ataxic gait with preserved deep tendon reflexes and the absence of Babinski sign and clonus. A review of the home-based videos provided by the parents showed left-side flexion posture of the trunk and neck due to dystonic ataxia before the hospital admission. Episodic ataxias, ion-channel disorders, GLUT1-deficiency syndrome, and ataxia telangiectasia were among differential diagnosis. Two weeks later, the patient presented with fever and worsening of symptoms. He was brought to the pediatric emergency department with an inability to walk. He was encephalopathic and was unable to move his fingers. He had watery, mucous diarrhea several times a day for the past 2 days. Pulse oxygen saturation was 40% and heart rate was 70 beats/min with shallow breathing. He was intubated because of respiratory failure. Treatment with a mitochondrial cocktail was initiated for a possible mitochondrial disorder. Metabolic screening tests, including serum ammonia, lactate, pyruvate, blood gas analysis, serum and urine amino acid chromatography, tandem mass spectrometry, urine organic acid profile, and thyroid function tests were all normal. Autoimmune encephalitis panel and paraneoplastic screening were normal. Brain MRI on admission showed mild cerebral atrophy (►**Fig. 1A,B**), MR-spectroscopy (MR-S) and EEG evaluation were normal. Echocardiogram showed mild left ventricular hypertrophy which was considered to be secondary to hypoxia. During the follow-up, the patient had a respiratory arrest, developed central hypoventilation, and required ventilation through tracheostomy. He was fed through a nasogastric tube because of swallowing difficulties. He regained consciousness following ventilatory support and the reversal of carbon dioxide retention. He was

 © 2024. Thieme. All rights reserved.

This document was downloaded for personal use only. Unauthorized distribution is strictly prohibited.

Table 1 General characteristics of the patients with *ADPRHL2* mutations in the literature and our cases

	Systematic review results ($n = 47$)	Case 1	Case 2
Current age, years, median (min–max)	16 (1.8–40)		3 y 11 mo
Age of death, years, median (min–max)	7 (2–34)	3 y	
Fatalities, *n* (%)	21/47 (44.6)	Fatal	Alive
Gender, female, *n* (%)	29/47 (61.7)	Male	Female
Consanguinity, present, *n* (%)	30/42[a](71.4)	+	+
Age at symptom onset, years, median (min–max)	2 (0.7–25)	2 y 3 mo	1 y 8 mo
Age of progressive disease course, years, median (min–max) (Not available = 14, Nonprogressive = 6)	6 (1.2–33)	2 y 9 mo	2 y 7 mo
Presenting symptom, *n* (%)			
-Gait problems (abnormal broad-based gait, stumbling, walking instability, unsteady gait, balance difficulties, difficulty in walking)	19/47 (40.4)	Episodic ataxic-dystonic posture	Episodic ataxic-dystonic posture Febrile seizure
-Seizure	16/47 (34)		
-Ataxia	13/47 (27.6)		
-Weakness	10/47 (21.2)		
-Psychiatric problems (psychosis, delusion, hallucination, depression)	5/47 (10.6)		
-Episodic ataxic-dystonic posture	5/47 (10.6)		
-Episodic torticollis attack	1/47 (2.1)		
-Dystonic torticollis	1/47 (2.1)		
Developmental milestones, *n* (%)			
-Normal	11/43[a] (25.5)	Language delay	Regression
-Regression	26/43[a] (60.4)		
-Delayed	7/43[a] (16.2)		
Clinical symptoms, *n* (%)			
-Weakness -Gait problems -Episodic/Nonepisodic ataxia -Seizure -Ocular findings (nystagmus, strabismus, ptosis, restricted abduction of the eyes, and upward gaze) -Scoliosis -Pes cavus deformity -Dystonic posture -Perioral/Facial myoclonus -Orofacial dyskinesis - Head tremor/titubation, nodding of the head -Tremor -Sensorineural hearing loss -Dysarthria -Foot drop -Restrictive pulmonary functions -Gastrointestinal disturbances	27/47 (57.4) 24/47 (51) 17/47 (36.1) 11/47 (23.4) 15/47 (31.9) 13/47 (27.6) 10/47 (21.2) 5/47 (10.6) 3/47 (6.3) 3/47 (6.3) 3/47 (6.3) 7/47 (14.8) 6/47 (12.7) 6/47 (12.7) 6/47 (12.7) 3/47 (6.3) 2/47 (4.2)	Gait disturbance, Ataxia Weakness Oral dyskinesias Gastrointestinal disturbance Episodic head tilt	Facial and extremities myoclonia, dyskinesias and spasticity
Triggering factors, *n* (%) -Illness and/or stress (infections, surgery, trauma, diarrhea, exercise, and cold water)	28/47 (59.5)	Infection	Infection
Respiratory insufficiency, *n* (%)	14/47 (29.7)	+	+
Cardiac involvement, *n* (%) -Sinus arrhythmia, bundle block, and ventricle hypertrophy	7/47 (14.8)	+	−

This document was downloaded for personal use only. Unauthorized distribution is strictly prohibited.

 © 2024. Thieme. All rights reserved.

Table 1 (*Continued*)

	Systematic review results ($n = 47$)	Case 1	Case 2
Autonomic dysfunction, *n* (%) -Lack of sweating, hyperthermia, and postural orthostatic tachycardia	5/47 (10.6)	+	−
Endocrine abnormalities, *n* (%) -Thyroid hormone abnormalities and mild hypogonadism with elevated FSH values	3/47 (6.3)	−	Central diabetes insipidus, adrenal insufficiency, hypothyroidism
EEG results, *n* (%)			
-Normal	8/24[a] (33.3)	+	+
-Epileptic discharge/slowing/cerebral dysfunction	16/24[a] (66.6)		
EMG/NCS results, *n* (%)			
-Normal	4/23[a] (17.3)		
-Axonal polyneuropathy ± sensory involvement	9/23[a] (39.1)		
-Chronic neurogenic changes and bilateral dorsal column dysfunction	2/23[a] (8.6)		
-Mild sensory neuropathy	1/23[a] (4.3)		
-Axonal motor neuropathy	2/23[a] (8.6)		
-Axonal neuropathy	1/23[a] (4.3)		
-Axonal sensorimotor peripheral neuropathy	1/23[a] (4.3)		
-Generalized pure motor, distal symmetrical axonopathy with posterior column involvement at the dorsolumbar level	1/23[a] (4.3)		
-Absent sensory responses	1/23[a] (4.3)		
-Neurogenic and myogenic lesions	1/23[a] (4.3)		
MRI findings, *n* (%)			
Normal Abnormal -Normal at first imaging study but abnormal during follow-up -Cerebral/cerebellar atrophy, white matter signal changes -Hippocampal diffusion restriction -Hippocampal sclerosis -Spinal cord involvement (spinal cord atrophy, T2 hyperintensity, transverse myelopathy, and parenchymal abnormalities)	8/36[a] (22.2) 28/36[a] (77.7) 7/28[a] (25) 25/28[a] (89.2) 1/28[a] (3.5) 1/28[a] (3.5) 7/12[a] (58.3)	Mild cerebral atrophy on admission	Mild atrophy and thin corpus callosum, progressive cortical cerebral and cerebellar atrophy within a year
Mutation results, *n* (%)			
ADPRHL2	41/47 (87.2%)	Homozygous	Homozygous
-Homozygous mutation	40/41 (97.5%)		
-Compound heterozygous mutation	1/41 (2.4%)		
ADPRS	4/47 (8.5%)		
- Homozygous	3/4 (75%)		
- Compound heterozygous mutation	1/4 (25%)		
ARH3 (Homozygous)	2/47 (4.2%)		

Abbreviations: EEG, electroencephalography; EMG, electromyelography; NCS, nerve conduction studies; MRI, magnetic resonance imaging.
[a]This denominators in the table represent the number of patients whose characteristics can be accessed in the articles. Ratios have also been calculated according to these denominators.

This document was downloaded for personal use only. Unauthorized distribution is strictly prohibited.

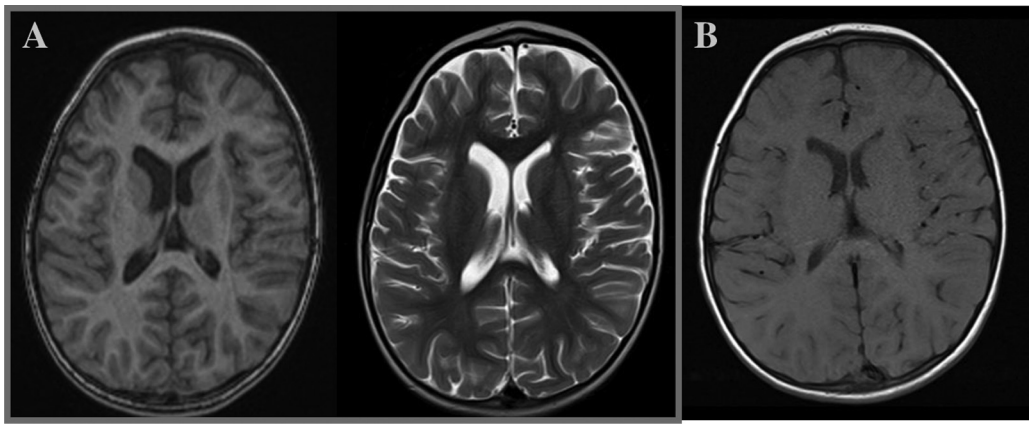

Fig. 1 (**A–B**) Brain magnetic resonance imaging of the patient 1. Axial T1W and T2W images show mild cerebral atrophy on admission.

able to communicate with parents. He had no manifest clinical seizures. During his stay in the hospital, symptoms of autonomic dysfunction such as tachycardia, abdominal distension, and hypertension emerged. He was given an intravenous immunoglobulin (IVIG) for 5 days at 0.4 g/kg for a possible autoimmune disease without any response. He developed severe quadriparesis, hypotonia, and oral dyskinesias during the course. He had no response to L-dopa treatment. He was discharged with supportive/palliative care and was deceased at home without any intervention probably due to respiratory and secondary cardiac autonomic dysfunction. Despite extensive work-up, no definite diagnosis could be established. After informed consent was taken from the parents, exome sequencing (ES) was performed in the index patient with Illumina NextSeq 550 next-generation sequencing platform. ES revealed a previously reported homozygous missense c.235A > C mutation [RefSeq Number: NM_017825.2; p.(Thr79Pro)] in *ADPRHL2*. The homozygous mutation revealed with the aid of ES was further confirmed by Sanger sequencing and the apparently unaffected and asymptomatic parents were heterozygous for the same mutation. Segregation analysis could not be performed on the unaffected 11-year-old brother due to the lack of DNA sampling.

Case 2

A $2^{8/12}$-year-old girl was brought to our outpatient clinic with complaints of language delay, gait abnormalities, and loss of consciousness after a seizure accompanied by fever. Early developmental milestones were normal with a regression in language and speech domains at the age of 18 months. By the age of 20 months, she had left left-sided head and trunk bending for 1 minute. This episodic attacks lasted about a month, and she recovered spontaneously. At the age of $2^{7/12}$ years, she had a generalized seizure with fever, lasting for 1 minute, and she gradually lost the ability to walk, speak, and swallow within the following 3 weeks. She was on levetiracetam treatment.

Prenatal, natal, and postnatal histories were uneventful. The parents were first cousins, and family history was otherwise unremarkable. Anthropometric measurements revealed, head circumference 49 cm (25–50p), body weight 14 kg (25–50p), and height 92 cm (50p). She was unresponsive to the environment, unable to sit without support and lacked head control. She had pre-existing bilateral outward gaze paralysis, and myoclonic movements on the face and extremities (►**Supplementary Video 1**, available in the online version). Muscle tone was increased, deep tendon reflexes were brisk, and Babinski sign and clonus were bilaterally positive. Differential diagnosis included a wide range of disorders, including infectious, postinfectious, autoimmune, paraneoplastic, neurometabolic, and neurodegenerative diseases. Screening for metabolic disorders, laboratory tests including complete blood count, blood biochemistry, and cerebrospinal fluid analysis, were noncontributory. Brain MR-S was normal, EEG showed diffuse slowing suggestive of encephalopathy. Brain MRI at the age of 21 months showed mild bilateral anterior frontal atrophy and diffuse thin corpus callosum (►**Fig. 2A-C**). In the interval period, within a year, follow-up MRI showed progressive cortical cerebral and cerebellar atrophy (►**Fig. 2D-F**). She had hypoventilation attacks during sleep without any signs of infection. She was intubated due to shallow breathing and bradycardia and underwent tracheostomy due to central hypoventilation. Ceftriaxone, acyclovir treatments were introduced for presumed encephalitis. Gabapentin was initiated for dyskinesias and spasticity. Despite improved EEG features, clinical response was not prominent. IVIG was given for 5 days at 0.4 g/kg for a possible antibody-negative immune encephalitis. L-dopa and benzodiazepines were also ineffective. Treatment efforts all failed and no significant clinical improvement could be achieved. During the follow-up, she developed hypernatremia and was diagnosed with central diabetes insipidus; desmopressin was started. She developed hypoglycemia and had an insufficient response to adrenocorticotropic hormone test and was diagnosed with adrenal insufficiency; hydrocortisone was initiated. She was given levothyroxine for hypothyroidism. After informed consent was taken from the parents, ES was performed in the index patient with Illumina NextSeq 550 next-generation sequencing platform. Interestingly, the same previously reported, homozygous, missense variant c.235A > C [RefSeq Number: NM_017825.2; p.(Thr79Pro)] in *ADPRHL2* which

 © 2024. Thieme. All rights reserved.

This document was downloaded for personal use only. Unauthorized distribution is strictly prohibited.

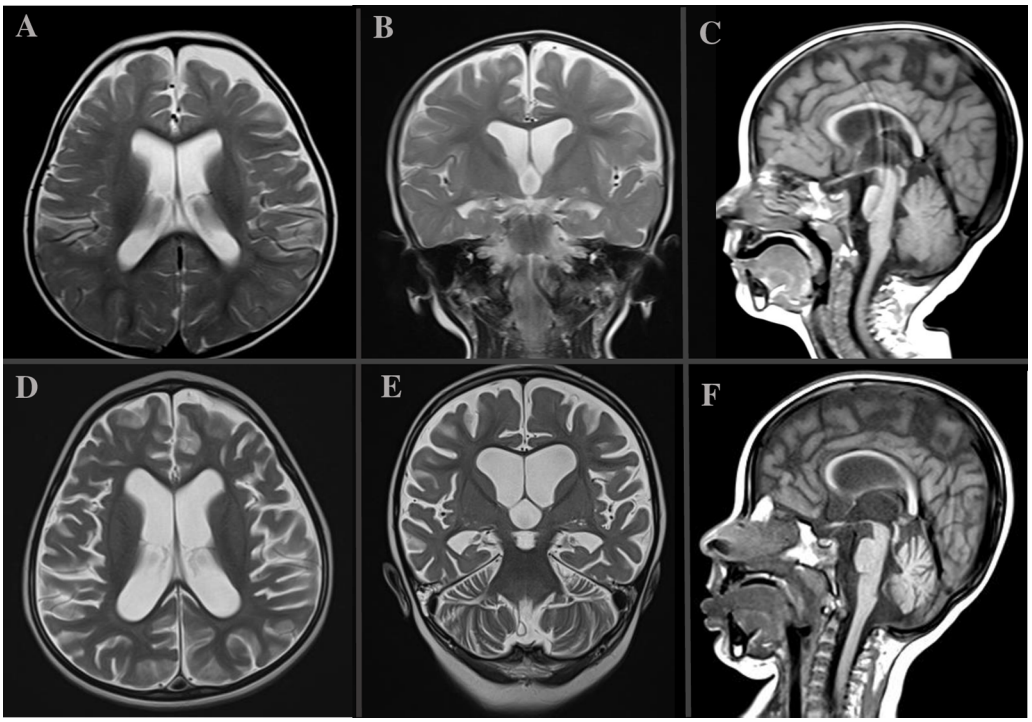

Fig. 2 (**A–F**) Brain magnetic resonance imaging (MRI) of the patient 2. Axial (**A**) and coronal (**B**) T2-weighted images show mild atrophy and thin corpus callosum (**C**) at the age of 21 months. Follow-up MRI after a year showed progressive cortical cerebral and cerebellar atrophy (**D–F**).

was found in the first patient was detected in this patient as well. The homozygous variant which was found by ES was further confirmed by Sanger sequencing. Segregation analysis in the unaffected parents was done and confirmed that both parents were heterozygous for the same mutation. The patient was discharged with ventilation through tracheostomy and palliative care. At the follow-up examination 1 year later, she was able to sit with truncal ataxia and to walk with support. She has a wide-based, spastic and ataxic gait. She has single words, and obeys simple, single commands (►**Supplementary Videos 2** and **3**, available in the online version).

Supplementary Video 1

Hyperkinetic movements in the upper extremities with orofacial dyskinesias and myoclonia. Online content including video sequences viewable at: https://www.thieme-connect.com/products/ejournals/html/10.1055/s-0044-1779618.

Supplementary Video 2

Sitting unsupported with truncal ataxia. Online content including video sequences viewable at: https://www.thieme-connect.com/products/ejournals/html/10.1055/s-0044-1779618.

Supplementary Video 3

Wide-based, spastic and ataxic gait. Online content including video sequences viewable at: https://www.thieme-connect.com/products/ejournals/html/10.1055/s-0044-1779618.

Results of the Systematic Review

This systematic literature review was reported according to PRISMA 2020 statement. The overview of the systematic literature review process is shown in ►**Fig. 3**. We identified 12 articles describing 47 patients with *ADPRHL2/ADPRS/ARH3* mutation during the literature search.[4,5,7–16] Of these studies, two were large reports in which the disease was first described ($n = 16$, and $n = 12$ respectively), three were single-case reports, three were letters involving four patients, and four were original/research article involving 12 patients. Characteristics of the *ADPRHL2/ADPRS/ARH3* mutation found in the literature up to February 3rd, 2023 and our cases are summarized in ►**Table 1**. The most prevalent variants were located in exon 6 ($n = 22$, 48.9%) in patients with homozygous variants ($n = 45$); and missense ($n = 23$, 51.1%), nonsense ($n = 12$, 26.7%), and frameshift variants ($n = 8$, 17.8%) were most commonly reported.[4,5,11,12] Among the 47 patients, the median age at symptom onset was 2 (0.7–25) years. The most common presenting symptoms were gait problems ($n = 19$, 40.4%), seizure ($n = 16$, 34%), ataxia ($n = 13$, 27.6%), and weakness ($n = 10$, 21.2%). In 42 patients, 71.4% had a history of

 © 2024. Thieme. All rights reserved.

This document was downloaded for personal use only. Unauthorized distribution is strictly prohibited.

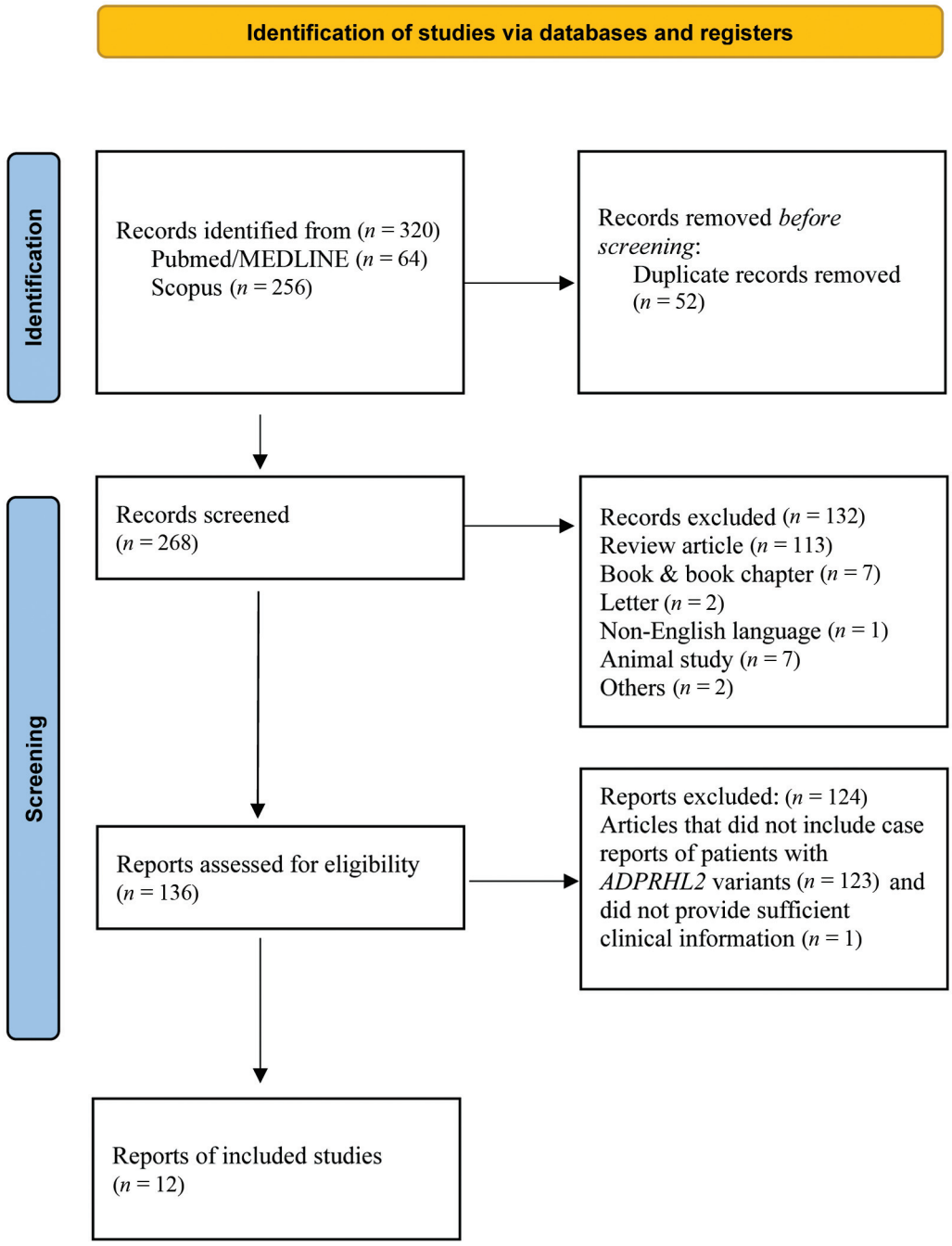

Fig. 3 The PRISMA flow diagram of literature screening.

consanguinity. Of 43 patients, 60.4% had a regression in developmental milestones, 16.2% were delayed, and 25.5% were normal. The most frequent clinical symptoms were weakness ($n = 27$, 57.4%), gait problems ($n = 24$, 51%), episodic/nonepisodic ataxia ($n = 17$, 36.1%), abnormal ocular findings (nystagmus, strabismus, ptosis, restricted abduction of the eyes, and upward gaze; $n = 15$, 31.9%), and seizure ($n = 11$, 23.4%). Triggering factors such as infections, surgery, trauma, diarrhea, exercise, and cold water were reported in 59.5% ($n = 28$) of the patients. Electromyelography or nerve conduction studies were performed in 23 patients, 9 patients showed axonal polyneuropathy with/without sensory involvement. MRI was performed in 36 of the patients, and 77.7% ($n = 28$) of them was abnormal. Of note, the initial imaging of 25% ($n = 8$) of these patients was normal, and follow-up studies demonstrated abnormal findings. Cerebral/cerebellar atrophy and white matter signal changes were reported most frequently. The fatality rate was 44.6% ($n = 21$), and median age of death was 7 (2–34) years. Rare accompanying features are documented in ►**Supplementary Table S1** (available in the online version).

Discussion

Recently, loss of function variants in the *ADPRHL2* gene on chromosome 1p34.3, which encodes *ARH3*, is described to

 © 2024. Thieme. All rights reserved.

This document was downloaded for personal use only. Unauthorized distribution is strictly prohibited.

cause a rare, stress-related childhood-onset neurodegenerative disease.[4,5] In this study with these two affected individuals, we further expanded the clinical phenotype of this rare neurodegenerative disorder which presents with episodic dystonia and mild developmental delay in the expressive language domain, progressing to gait abnormalities, ataxia, and eventual quadriparesis with central hypoventilation syndrome requiring invasive ventilatory support. Progressive neurological course with involvement of other systems in both of our patients led to a wide differential diagnostic list including infectious, postinfectious, autoimmune diseases, and particularly inherited neurodegenerative disorders in the presence of parental consanguinity.

At the time of progressive deterioration, both patients were extensively evaluated in terms of laboratory and neuroimaging investigations and they were managed with a concern of not to miss any treatable condition. Although laboratory tests were normal and cranial MRI in the first patient revealed mild cerebral atrophy, EEG and cranial MRI revealed diffuse encephalopathy and cortical, cerebral, and cerebellar atrophy in the second patient. A previously reported homozygous, missense mutation in *ADPRHL2* in both patients was detected through ES in these two patients from two unrelated families with a probable diagnosis of a neurodegenerative disorder. The detected mutation is "likely pathogenic" according to ACMG criteria[17] and has been previously reported as "pathogenic "in the ClinVar database as well. Interestingly, the same homozygous variant, c.235C > A in *ADPRHL2* was previously reported in five different Turkish patients.[4,7,14] The identification of the same variant in seven unrelated families might be due to a probable founder effect in Turkish population, a country with a high consanguineous marriage rate.[18] Expression of this missense variant in *Escherichia coli* demonstrated that it caused protein destabilization, suggesting that the missense variants may have a loss-of-function effect.[4] The c.235C > A missense variant is located in exon 2 and is found in a total of seven patients including the two patients described in the present study. The age of clinical onset of our two patients along with the five previously reported patients was as follows: 18 months, 20 months, 27 months, 30 months, 3.5 years, 4 years, and 7.5 years.[4,7,14] No other missense variants but c.235C > A have been described in exon 2 so far. However, a frameshift variant (c.292delG) has been described in exon 2 in two other patients with age at clinical onset of 14 and 15 years.[5] Taking these points into consideration, we may conclude that not only the affected region of the gene but also the type of the variant may have a significant role in the clinical phenotype.

Moreover, the most prevalent variants are located in exon 6 ($n = 22$, 48.9%) in 45 patients with homozygous variants. One family had nine affected members due to a nonsense variant in exon 6.[4] Although the age of onset in this family ranged from 15 months to 24 months, the age of onset for missense variants in exon 6 ($n = 12$, 26.7%) reported in other studies varied from 1 to 32 years.[5,11,12] Patients with missense variants in exon 2 had an earlier clinical onset compared to that of patients with variants in exon 6. Nevertheless, since variants in other exons reported in the literature are very rare, these suggestions may be misleading. Therefore, the current data are insufficient to establish a definite genotype-phenotype correlation since the disease is very rare and has only been recently defined. The type and location of mutations reported in the literature are documented in ►**Supplementary Table S2** (available in the online version).

Ghosh et al described homozygous variants in the *ADPRHL2* gene in 16 children from 6 families with normal birth and early developmental stages (except one and mild delay), between 9 months and 13 years of age.[4] Most of these children showed regression of linguistic and motor milestones with the onset of attacks associated with illness/stress. Convulsions, paralysis, ataxia, loss of previously acquired developmental milestones, and progressively worsening clinical conditions with apnea attacks contributed to fatal course.[4] The authors proposed that an increase in PAR or the inability to reverse PAR modification could set off a cascade of events resulting in progressive neurodegeneration.[4] Danhauser et al demonstrated biallelic pathogenic variants in *ADPRHL2* in 12 children from 8 different families with symptoms of onset in childhood. Developmental delay/regression, mental impairment, gait abnormalities, ataxia, neuropathy, and seizures were defined as the main clinical findings.[5]

Cerebellar atrophy and vermis atrophy were frequently reported MRI findings in the literature, along with cerebral atrophy, spinal cord atrophy, basal ganglia involvement, corpus callosum hyperintensity, and other abnormalities.[4,5,7–15] Even while some patients' MRI results might be normal or show mild atrophy, such as our first patient, these changes might be time dependent and atrophy might occur and progress over the course of the illness.[4,5,8–11]

This neurodegenerative disease was also described in five adult patients.[11,16] Four of them showed stress-related episodic psychosis, ataxia, motor neuropathy, and pyramidal abnormalities.[11] All four patients (20 years or older) have homozygous variants in *ADPRHL2*, and compared to patients presented in the pediatric age group, adult-onset patients were reported to have a milder clinical course.[11] The most crucial common signature was the episodic pattern and symptoms associated with stress (fever, infection, illness, trauma, or surgery) in all age groups. The other adult patient had hypothyroidism, obesity, early menopause, postural orthostatic tachycardia, mild sensory neuropathy, anxiety, and depression, and she was relatively mildly affected than her 8-year-old sibling with the same homozygous *ARH3* mutation.[16] Interestingly, in a study in which next generation sequencing was performed in 73 families with hereditary motor neuropathy, *ADPRHL2* homozygous variants were found in three individuals from two families. In these patients on the mild end of the spectrum, slow disease progression, noticeable peripheral neuropathy, and distal muscle weakness were defined as common features.[12]

A muscle or nerve biopsy was performed on 11 patients. Although mostly neurogenic changes have been reported, myogenic or normal changes also exist.[4,5,7,9,11,13] Muscle biopsy was performed on our first patient, and unfortunately, the sample size was not sufficient for evaluation.

This document was downloaded for personal use only. Unauthorized distribution is strictly prohibited.

There have been 47 cases described so far in the literature, 21 of which have deceased.[4,5,7,8,10,12,15] Respiratory failure and cardiopulmonary arrest were the main reasons for mortality in the majority of cases. Respiratory failure and autonomic dysfunction may underlie the fatal course in our first patient as well.

The underlying mechanism of this neurodegenerative disease is worth discussing. In reversible PTM of proteins, poly-ADP ribose polymerase (PARP) especially PARP1, which is derived from ADP ribosyl transferase, catalyzes the binding of an ADP-ribose unit from NAD+ to the protein's target site. ARHs and PARGs enzymes reverse this reaction, thus provide de-ADPr.[19] Dysregulation of ADPr leads to many diseases in human, especially cancers and neurologic diseases.[20] Activity of PARP1, the most abundant PARP in PTM, increases and causes excessive PAR, in some subtypes of spinocerebellar ataxia and ataxia oculomotor apraxia, neurodegenerative diseases such as Parkinson's disease, amyotrophic lateral sclerosis, and Alzheimer's disease.[21,22] PAR-dependent cell death, also known as "parthanatos," occurs as a result of excessive PAR and leads to neuronal cell loss.[23] ARH3 allows the separation of ADP riboses from PARs in PTM, and so it prevents uncontrolled accumulation of PARs which is a trigger of PAR-dependent cell death. It is also the primary enzyme in charge of PAR hydrolysis in the mitochondrial matrix. As a result, the ARH3's PAR-destructive activity has a crucial role in the cell's stress response pathway.[24]

Although experimental research demonstrated that ARH3 deficiency-related cellular damage is prevented by PARP inhibitors, the effect size in patients is not studied.[4,5,16] Mashimo et al showed that the fibroblast samples from patients and ARH3-deficient mice were more susceptible to stress caused by H_2O_2 and ischemia-reperfusion injury, resulting in PAR accumulation and cell death. They determined that treatment of patient fibroblasts with the PARP inhibitor PJ34 prior to H_2O_2 exposure reduced the PAR content in fibroblasts exposed to H_2O_2. Also, they demonstrated in a mice model that veliparib, one of the anticancer PARP inhibitor drugs, attenuates parthanatos-mediated neuronal cell death after ischemic brain injury.[16] Any disease-specific treatment and/or modifying therapy is not yet available but we hope these observations may be reflected in future treatment strategies.

Our patients in line with the so far reported patients, clinically evolved from episodic ataxia to a neurodegenerative course with central hypoventilation syndrome, further complicated by multisystemic involvement including endocrine dysfunction. Patients with *ADPRHL2* variants can show a wide clinical phenotype at different age groups and different prognoses from progressive fatal course in childhood to a static course with survival up to third decade in adulthood[4,5,7–16] (►**Table 1**). A clear genotype-phenotype correlation is quite challenging to establish based on current knowledge. *ADPRHL2* variants should be suspected in patients with episodic dystonia and ataxia, head-tilt, gait disturbances, and/or seizures that are triggered by stress in children or adults who either have prior mild developmental delay or are completely healthy.

Author Roles

1. Research project: A. Conception, B. Organization, and C. Execution.
2. Statistical analysis: A. Design, B. Execution, and C. Review and critique.
3. Manuscript preparation: A. Writing of the first draft and B. Review and Critique.

S.Ö.Y.: 1A, 2A, 2B, 3A; D.Y.: 3B; P.Ö.Ş.K.: 1A, 3B; R.G.: 3B; M.S.: 3B; G.E.U.: 3B; and G.H.: 1A, 1B, 1C, 2C, 3B.

Ethical Compliance Statement

The authors confirm that the approval of an institutional review board was not required for this work. Written and verbal consent from the parents were obtained for this study, including case presentations and video images. We confirm that we have read the journal's position on issues involved in ethical publication and affirm that this work is consistent with those guidelines.

Financial Disclosures of all Authors

None.

Informed Consent

Informed consent was obtained.

Funding

The authors received no financial support for research, authorship, and/or publication of this article.

Conflict of Interest

None declared.

Acknowledgment

Our patients and their families are greatly acknowledged for their participation in this study.

References

1 Cohen MS, Chang P. Insights into the biogenesis, function, and regulation of ADP-ribosylation. Nat Chem Biol 2018;14(03): 236–243
2 Dantzer F, Amé JC, Schreiber V, Nakamura J, Ménissier-de Murcia J, de Murcia G. Poly(ADP-ribose) polymerase-1 activation during DNA damage and repair. Methods Enzymol 2006;409:493–510
3 Mashimo M, Moss J. Functional role of ADP-ribosyl-acceptor hydrolase 3 in poly(ADP-ribose) polymerase-1 response to oxidative stress. Curr Protein Pept Sci 2016;17(07):633–640
4 Ghosh SG, Becker K, Huang H, et al. Biallelic mutations in ADPRHL2, encoding ADP-ribosylhydrolase 3, lead to a degenerative pediatric stress-induced epileptic ataxia syndrome. Am J Hum Genet 2018;103(03):431–439
5 Danhauser K, Alhaddad B, Makowski C, et al. Bi-allelic ADPRHL2 mutations cause neurodegeneration with developmental delay, ataxia, and axonal neuropathy. Am J Hum Genet 2018;103(05): 817–825
6 Page MJ, McKenzie JE, Bossuyt PM, et al. The PRISMA 2020 statement: an updated guideline for reporting systematic reviews. BMJ 2021;372(71):n71
7 Ozturk G, Ayaz A, Topcu Y, et al. Stress-induced Childhood Onset Neurodegeneration with Ataxia and Seizures (CONDSIAS) presenting with torticollis attacks: phenotypic variability of the

 © 2024. Thieme. All rights reserved.

This document was downloaded for personal use only. Unauthorized distribution is strictly prohibited.

same mutation in two Turkish patients. Ann Indian Acad Neurol 2022;25(02):292–294
8 Aryan H, Razmara E, Farhud D, et al. Novel imaging and clinical phenotypes of CONDSIAS disorder caused by a homozygous frameshift variant of ADPRHL2: a case report. BMC Neurol 2020;20(01):291
9 Lu A, Dong C, Chen B, Xie L, Hu H. Case report: stress-induced childhood-onset neurodegeneration with ataxia-seizures syndrome caused by a novel compound heterozygous mutation in *ADPRHL2*. Front Neurol 2022;13:807291
10 Ma J, Qian Q, Yan S, Dou H, Li C, Sun D. Child-onset cerebellar ataxia caused by two compound heterozygous variants in *ADPRS* Gene: a case report. Front Genet 2022;12:788702
11 Durmus H, Mertoğlu E, Sticht H, et al. Episodic psychosis, ataxia, motor neuropathy with pyramidal signs (PAMP syndrome) caused by a novel mutation in ADPRHL2 (AHR3). Neurol Sci 2021;42(09):3871–3878
12 Beijer D, Agnew T, Rack JGM, et al. Biallelic *ADPRHL2* mutations in complex neuropathy affect ADP ribosylation and DNA damage response. Life Sci Alliance 2021;4(11):e202101057
13 Mishra B, Fatima S, Agarwal A, Radhakrishnan DM, Garg A, Srivastava AK. Dystonia and myelopathy in a case of stress-induced Childhood-Onset Neurodegeneration with Ataxia and Seizures (CONDSIAS). Mov Disord Clin Pract (Hoboken) 2020;8(01):156–158
14 Paketci C, Karakaya M, Edem P, et al. Clinical, electrophysiological and genetic characteristics of childhood hereditary polyneuropathies. Rev Neurol (Paris) 2020;176(10):846–855
15 Bajaj S, Shah P, Shah A, Setty PN, Seenappa V, Hingwala D. An Indian child with CONDSIAS due to a novel variant in *ADPRHL2* gene. Ann Indian Acad Neurol 2022;25(06):1190–1192
16 Mashimo M, Bu X, Aoyama K, et al. PARP1 inhibition alleviates injury in ARH3-deficient mice and human cells. JCI Insight 2019;4 (04):e124519
17 Richards S, Aziz N, Bale S, et al. ACMG Laboratory Quality Assurance Committee. Standards and guidelines for the interpretation of sequence variants: a joint consensus recommendation of the American College of Medical Genetics and Genomics and the Association for Molecular Pathology. Genet Med 2015;17(05): 405–424
18 Turkey Demographic and Health Survey. Hacettepe University Institute of population studies 2014. Turkey Demographic and Health Survey Report. 2018
19 Mueller-Dieckmann C, Kernstock S, Lisurek M, et al. The structure of human ADP-ribosylhydrolase 3 (ARH3) provides insights into the reversibility of protein ADP-ribosylation. Proc Natl Acad Sci U S A 2006;103(41):15026–15031
20 Rack JGM, Palazzo L, Ahel I. (ADP-ribosyl)hydrolases: structure, function, and biology. Genes Dev 2020;34(5-6):263–284
21 Palazzo L, Mikolčević P, Mikoč A, Ahel I. ADP-ribosylation signalling and human disease. Open Biol 2019;9(04):190041
22 Kam TI, Mao X, Park H, et al. Poly(ADP-ribose) drives pathologic α-synuclein neurodegeneration in Parkinson's disease. Science 2018;362(6414):eaat8407
23 Park H, Kam TI, Dawson TM, Dawson VL. Poly (ADP-ribose) (PAR)-dependent cell death in neurodegenerative diseases. Int Rev Cell Mol Biol 2020;353:1–29
24 Pourfarjam Y, Ventura J, Kurinov I, Cho A, Moss J, Kim IK. Structure of human ADP-ribosyl-acceptor hydrolase 3 bound to ADP-ribose reveals a conformational switch that enables specific substrate recognition. J Biol Chem 2018;293(32):12350–12359

This document was downloaded for personal use only. Unauthorized distribution is strictly prohibited.