



Clinical Conundrum of ACTH-Independent Cushing's Syndrome in a Child with Adrenal Cortical Carcinoma: A Case Report and Review of Literature

Prashant Patil¹ Joewin Monteiro¹ Sajid Qureshi² Nupur Karnik³

¹ Department of Paediatric Endocrinology, SRCC Children's Hospital, Mumbai, Maharashtra, India

² Department of Paediatric Surgical Oncology, SRCC Children's Hospital, Mumbai, Maharashtra, India

³ Department of Pathology, Tata Memorial Hospital, Mumbai, Maharashtra, India

Address for correspondence Prashant Patil, MD, PDCC, Department of Paediatric Endocrinology, SRCC Children's Hospital, Haji Ali, Mumbai, 400034, Maharashtra, India (e-mail: dr_prash4u@yahoo.com).

Ind J Med Paediatr Oncol

Abstract

Keywords

- ▶ ACTH-independent Cushing's syndrome
- ▶ adrenal cortical carcinoma
- ▶ adrenalectomy
- ▶ mitotane

Adrenocorticotrophic hormone-independent Cushing's syndrome (CS) secondary to cortisol-secreting adrenal cortical carcinoma (ACC) in children has been seldom reported. We report on a 6-year-old girl diagnosed with CS due to a right-sided ACC. She presented with rapid onset obesity, virilization, and hypertensive urgency. Postserial diagnostic evaluation, control of hypertension, right adrenalectomy with en bloc resection of tumor mass were performed. The child had an excellent clinical and biochemical recovery with significant weight loss and return to normal serum cortisol levels.

Introduction

Cushing's syndrome (CS) is an infrequent entity in the pediatric age group, which results from prolonged and excessive secretion of cortisol with significant morbidity and mortality.^{1,2} Adrenocorticotrophic hormone (ACTH)-independent CS constitutes 15 to 20% of the total CS cases, and is usually caused by unilateral adrenal adenomas or carcinomas secreting excessive cortisol.¹ ACTH-independent CS is also caused by very rare disorders like unilateral adrenal adenoma, bilateral ACTH-independent macronodular adrenal hyperplasia, and bilateral primary pigmented nodular adrenocortical disease.³

Adrenal cortical carcinoma (ACC) is a rare but aggressive neoplasm more common in females (female to male ratio of 3:1).⁴ The incidence of ACC is approximately one to two per million population per year. There is a bimodal age distribution in ACC, with first peak before the age of 5 years

and second peak in the fourth to fifth decades of life.⁵ Patients often present with symptoms of hormone hypersecretion like excessive weight gain, hypertension and hirsutism. The prognosis for patients with ACC is often very poor if not diagnosed early. We report a case of a 6-year-old female with ACTH-independent CS due to cortisol-secreting ACC, which was diagnosed early and managed with adrenalectomy followed by adjuvant chemotherapy with mitotane.

Case Report

A 6-year, 2-month-old girl was admitted with generalized tonic clonic convulsions secondary to hypertensive urgency. Her blood pressure was 190/110 mmHg (above 99th percentile for age) in supine position. She also complained of sudden weight gain (13 kg in 2 months) and appearance of excessive hair development for 2 months (→Figs 1a & 1b.).

DOI <https://doi.org/10.1055/s-0044-1780522>.
ISSN 0971-5851.

© 2024. The Author(s).

This is an open access article published by Thieme under the terms of the Creative Commons Attribution License, permitting unrestricted use, distribution, and reproduction so long as the original work is properly cited. (<https://creativecommons.org/licenses/by/4.0/>)

Thieme Medical and Scientific Publishers Pvt. Ltd., A-12, 2nd Floor, Sector 2, Noida-201301 UP, India

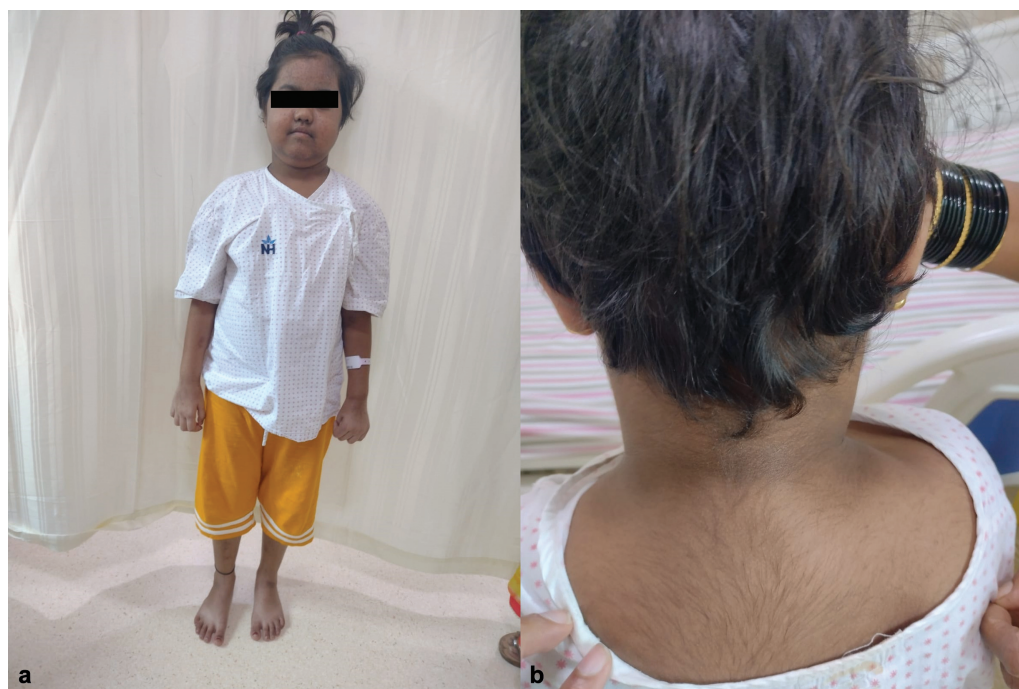

Fig. 1 (a) Clinical image of child central obesity, facial plethora with typical moon face. (b) acanthosis nigricans, and hirsutism.

There was no history of steroid drug use. She had marked central obesity, facial plethora with typical moon face, acanthosis nigricans, and increased body hair. She also had pitting edema with distended abdomen without hepatosplenomegaly. Her height was 108 cm (height z score, 1.14), weight 34 kg (z score, 2.45), with body mass index (BMI) of 29.15 (z score, 3.82). Initially, child was admitted in intensive care unit and started on injection labetalol infusion followed by three antihypertensive medicines, viz., prazosin, atenolol, and nifedipine.

On biochemical evaluation she had higher cortisol levels with 8 a.m. serum cortisol of 35.18 µg/dL (normal: 6–23 µg/dL) with a significantly lower ACTH level of less than 1.60 pg/mL (normal range: 5–46 pg/mL). Her 24-hour urinary-free cortisol (UFC) increased to 724.8 µg/24 hours (reference range: 20.26–127.55 µg/24 hours). On giving 1 mg dexamethasone at 11 p.m. (dexamethasone suppression test), her 8 a.m. serum cortisol was significantly elevated to 16.1 mcg/dl (reference range: <1.8/dL) indicating CS. Her 24-hour urine catecholamines were normal, while 24-hour urinary steroid profile (by liquid chromatography-mass spectrometry method) was showing increased excretion of androstenedione, cortisol, 11-deoxycortisol, and dehydroepiandrosterone sulfate (DHEAS). Her serum electrolytes, renal profile, and blood sugar levels were normal (►Table 1). Ultrasonography of the kidney showed well-defined heterogenous mass with size of 7.8 × 4.9 × 5.5 cm arising from right adrenal with increased vascularity, and areas of hemorrhagic necrosis infiltrating into segment VI of liver. Renal Doppler confirmed right-sided heterogeneous suprarenal mass of 6.8 × 5.5 × 5.6 cm size with local extension of the tumor into intrahepatic inferior vena cava (IVC) with near complete thrombosis. There was no family history of carcinoma.

Contrast-enhanced computed tomography (CT) abdomen was confirmative of sonographic findings with well-defined, heterogeneously enhancing mass lesion in right suprarenal region with partial lumen occluding thrombus in intrahepatic IVC (►Fig. 2a).

Her positron emission tomography (PET) scan revealed fluorodeoxyglucose (FDG) avid right suprarenal soft tissue mass with size of 5.96 × 5.7 × 7.14 cm, with calcification and necrotic component with mass infiltrating into IVC (►Fig. 2b). After stabilization of blood pressure, she underwent right-sided complete adrenalectomy with en bloc resection of the tumor along with IVC thrombectomy. Histopathology confirmed adrenal carcinoma with marked atypical cells. Tumor cells were positive for synaptophysin and inhibin and negative for chromogranin A, melan A, calretinin, and S100p on immunohistochemistry (Weiss score = 6). Large areas of necrosis were found with vascular emboli with presence of tumor thrombus within a vein (►Fig. 3).

During intraoperative and immediate postoperative period, she developed marked hypotension, which was managed by extra fluids and injectable hydrocortisone. Steroid was later tapered and omitted over the next 4 weeks. Mitotane was initiated at a very low dose (1.25 g/m²/day) in daily four divided doses and gradually increased to 2.5 g/m²/day every 2 weeks depending upon side effects like nausea and anorexia. We could not measure serum levels due to logistic difficulties. As mitotane is known to cause adrenal insufficiency, the patient was started on a very low physiological replacement of hydrocortisone (6 mg/m²/day, oral). During the first 2 months after diagnosis, the patient developed general weakness and epigastric discomfort, which gradually subsided over the next couple of weeks. Postoperatively, her

Table 1 Pre and Post-operative investigation chart

Test	Result	Reference Range
8 AM cortisol	35.18 mcg/dL	6-23mcg/dL
ACTH	<1.60 pg/mL	5-46 pg/mL
24 hour Urinary Free Cortisol	724.8 mcg/24h	20.26-127.55 mcg/24 h
ONDST Serum Cortisol	16.1 mcg/dL	<1.8 mcg/dL
Aldosterone	14 ng/L	40-271 ng/L
Androstenidione	5160 ng/L	80-500 ng/L
Cortisol	233 mcg/L	25-230 mcg/L
Cortisone	23.4 mcg/L	2.3-17.7 mcg/L
Corticosterone	2.7 mcg/L	1-20 mcg/L
11 Deoxycortisol	5.74 mcg/L	0.2-2.5 mcg/L
DHEAS	2990 mcg/L	74-468 mcg/L
17 OH Progesterone	3.67 mcg/L	0.03-0.9 mcg/L
Testosterone	1.69 mcg/L	0.02-0.20 mcg/L
24 h Urine Metanephrine	57.5 mcg/24 h	<350 mcg/24 h
Sodium	140 mEq/L	135-145 mEq/L
Potassium	3.8 mEq/L	3.5-4.5 mEq/L
4 months after surgery		
8 AM cortisol (Post surgery)	9 mcg/dL	6-23 mcg/dL
24h UFC (Post surgery)	12.8 mcg/ 24 h	20.26-127.55mcg/ 24 h

repeat PET scan was negative without any source FDG avid mass and sonography was normal.

Mitotane was stopped after 6 months of therapy.

After 4 months of surgery, she lost 6 kg weight with BMI of 21.49 (between median and 1 standard deviation); her blood pressure was in normal range, 98/74 mmHg, with total resolution of moon face, acanthosis nigricans, and facial hair (► **Fig. 4**). There was near total biochemical recovery of cortisol excess with normal 8 a.m. serum cortisol of 9 µg/dL (normal value: 6–23 µg/dL) along with normal levels of 24-hour UFC to 12.8 µg/24 hours (normal range: 20.26–127.55 µg/24 hours).

Discussion

CS consists of all the secondary manifestations of chronic glucocorticoids excess, few of which can be associated with hypersecretion of mineralocorticoids, or androgens. The differential diagnosis of pediatric CS represents one of the major diagnostic challenges that endocrinologists face especially in a context of limited resources. A sequential work up, beginning with screening tests to confirm endogenous cortisol hypersecretion followed by the establishment of ACTH dependency or independency and ending with various dynamic biochemical tests and imaging techniques aimed at localizing the original source, is essential for correct diagnosis and an effective therapeutic plan.⁶ In children, ACTH-independent CS with adrenal autonomous secretion is seen in 15% of cases. In majority of cases, ACTH-independent CS is due to cortical adenomas and rarely due to ACC.⁷

ACC is an extremely rare entity in the pediatric age group. Majority of the ACCs are sporadic; however, infrequently familial ACC is seen in association with Li-Fraumeni syndrome, Beckwith-Weidemann syndrome, and Multiple Endocrine Neoplasia (MEN) 1.⁸

They have a characteristic bimodal age distribution with first peak before 4 years of age (incidence of 0.4 cases per million) and second peak in the late fourth or fifth decade.⁴ Our patient was atypical and unique in this regard with her age of presentation at 6 years. The etiopathogenesis of ACC is complex and incompletely understood. Abnormalities in the insulin-like growth factor (IGF) II, mutation in a tumor suppressor gene Tp53,⁹ steroidogenic factor 1 overexpression,¹⁰ and mutations of the *β catenin* gene are some of the postulated mechanisms that have been described previously.¹¹ P53 mutation is the commonest genetic abnormality seen in approximately 80 to 90% of all pediatric adrenocortical tumors. Ribeiro et al have described in Brazilian cohort with a distinct germline p53 mutation, TP53 R337H, with ACC.¹² This mutation leads to an abnormal folding of the TP53 protein. Loss of heterozygosity at this locus is implicated to be involved in tumor genesis. Due to financial constraints, we could not do genetic evaluation for TP53 gene mutation in our patient.

Childhood ACC unlike adults has distinct clinical and biochemical features. In pediatric patients with ACCs, almost 90% of them are functional and most of them are androgen-secreting tumors. In adults, majority of ACCs are nonfunctional and, if functional, they present with cortisol excess.

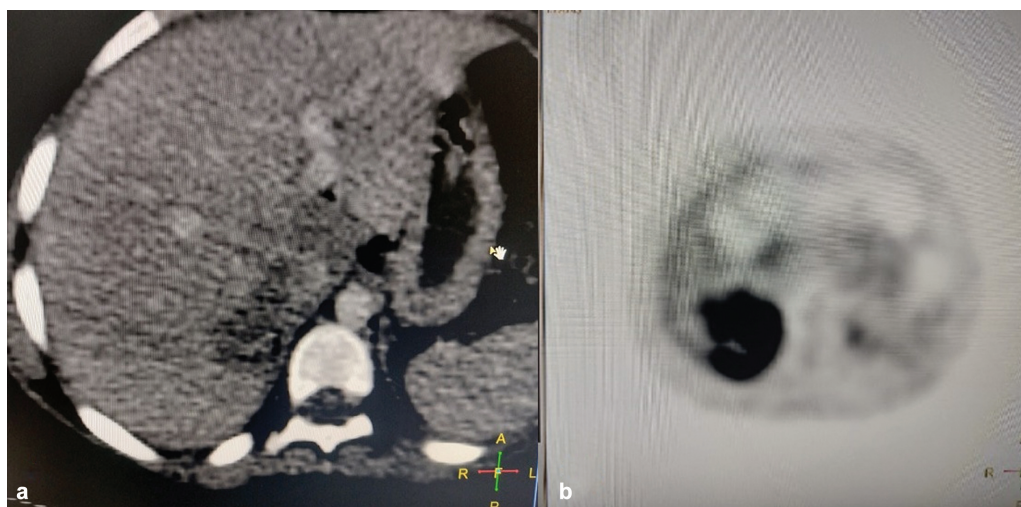


Fig. 2 (a) Contrast-enhanced computed tomography (CT) abdomen depicting well-defined, heterogeneously enhancing mass lesion in right suprarenal region with partial lumen occluding thrombus in intrahepatic IVC. (b) Positron emission tomography (PET) scan depicting fluorodeoxyglucose (FDG) avid right suprarenal soft tissue mass infiltrating into IVC.

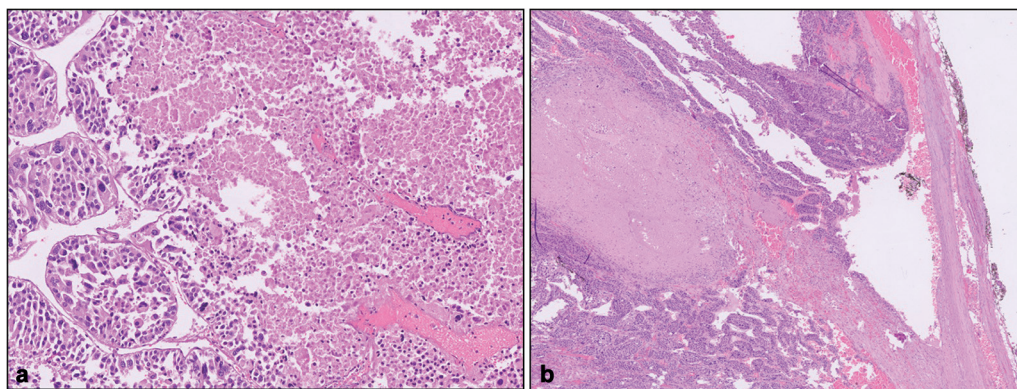


Fig. 3 Histopathology depicting adrenal carcinoma with marked atypical cells. Large areas of necrosis with vascular emboli and presence of tumor thrombus within a vein.

Michalkiewicz et al described that exclusive virilization is the commonest presentation in 55% of cases with pediatric ACC. Another 29% presented had mixed presentation with virilization and overproduction of other adrenal hormones. Unlike adults, only 5.5% presented with isolated CS and it is observed in older children with median age of around 12.6 years.⁴ Lefevre et al in France in their analysis of 42 children with ACC observed similar results with virilization in more than 90% of cases.¹³

The predominant androgen-producing tendency of childhood ACC could be linked to its relation with the fetal adrenal cortex. The fetal adrenal cortex is composed of the outer definitive zone and an inner fetal zone that produces steroid hormones throughout gestation. The histopathology features of ACCs in children suggest that they arise from inner fetal zone that has a tendency toward androgen production due to expression of steroidogenic enzymes in development. The DHEAS, primary steroid produced by the fetal adrenal cortex, which serves as the precursor of placental estrogen possibly, explains their predominant secretion of androgens.¹⁴ Our patient was among one of the rare cases where both androgen and glucocorticoid excess had started simultaneously

with hypertensive urgency as a presenting feature. She exhibited classic features of glucocorticoid excess including obesity, hypertensive urgency, acne, facial plethora, and a buffalo hump. She had biochemical evidence for excessive glucocorticoid production. Her suppressed ACTH level was consistent with a peripheral source. The unilateral adrenal mass in sonography and CT scan indicated an adrenal mass, and histopathological findings confirmed an ACC.

The next step in adrenal mass evaluation is imaging. Imaging is essential to localize site of tumor, plan the surgical intervention, and evaluate the locoregional spread, distant metastases, and staging of the disease. Though visualization of a small tumor is not always possible, ultrasonography is the first-line examination for adrenal tumors. The presence of intratumoral hemorrhage or necrosis gives a typical heterogeneous appearance that favors the adrenal carcinoma.¹⁵ It is also useful in detecting the tumor spread into the IVC. CT scan is the gold standard imaging modality in cases of an adrenal mass in children.¹⁵ It can detect tumors with diameter as small as 0.5 to 1 cm. It is also useful in detection of venous extension, distant hepatic and pulmonary metastases, and periaortic adenopathies. It is often difficult to



Fig. 4 Postoperative 4 months of surgery, with resolution of moon face and weight loss.

differentiate between a benign adrenal adenoma and ACC, but there are features that might favor ACC,¹⁶ like tumor size more than 4 cm; irregular margins; heterogeneous intensity due to hemorrhage, necrosis, and fibrosis; calcifications¹⁷ attenuation more than 10 Hounsfield unit (HU); and less than 50% contrast washout. Our patient had a tumor diameter of 6 to 7 cm, which favors adrenal carcinoma.

FDG-PET is being used increasingly in the initial evaluation of ACC and in postoperative follow-up.¹⁸ FDG-PET can differentiate between benign and malignant mass. Adenomas will show an uptake that is less compared with that of the liver, while ACC has a higher uptake. Maurea et al¹⁹ showed that FDG-PET has nearly 100% sensitivity, specificity, and a negative predictive value in detecting malignant lesions of nonsecreting adrenal lesions. FDG-PET aids in detecting the distant metastases as described by Mackie et al and it is also helpful in staging and local recurrence.²⁰ FDG-PET has also been used successfully to detect local recurrences. The intensity of the FDG uptake has also been used to prognosticate ACC. A maximal standardized uptake values (SUVs) of more than 10 and FDG uptake volume of more than 150 mL is associated with a poor prognosis.²¹ Although recent guideline advises against fine needle aspiration cytology due to the possibility of capsular breach, causing seeding of tumor cells, it is performed during initial evaluation especially for prediction of malignant potential

and to prognosticate lesion.²² A scoring system like Weiss score system on histopathological examination can predict a malignant lesion. This system is based on five parameters with score of more than or equal to 3 being highly indicative of malignancy.²³ According to the European Network for the Study of Adrenal Tumors, Weiss score rather than tumor staging is essential for prognosis.²⁴ A retrospective study on eight patients with ACC (median age of 6 years) revealed 2-year survival postdiagnosis was 100% for stage II and 75% for stage IV without any statistical significance, but in patients with a Weiss score less than 6, the 2-year survival rate was 100%, which was statistically significantly higher as compared with Weiss score of at least 6 or more who had a 2-year survival rate of 35% ($p=0.043$).²⁴ Our patient had good recovery despite high Weiss score of 6.

K_i-67, an index of proliferation, is also emerging as a useful prognostic marker based on the immunohistochemistry. A K_i-67 value of least 15% represents predictor of poor prognosis in the pediatric age group.²⁵

Staging in childhood ACC varies from that in adults and involves the size, weight, and amount of resection of the tumor. Stage I is a tumor less than 5 cm, weighing less than 200 g, with complete resection; stage II, more than 5 cm, more than 200 g, with complete resection; stage III, local spread to lymph nodes, kidney, IVC, or incomplete resection; and stage IV, distant metastases to either lung or liver or to both.²⁶ Surgical removal of the tumor, wherever feasible, remains cornerstone of therapy; procedures of approach may vary, but successful tumor removal represents a major predictor of favorable outcome.²⁷ Open adrenalectomy surgery remains the most preferred approach while laparoscopic adrenalectomy is generally avoided due to high rate (80%) of locoregional recurrences. As per a multicentric European study with individuals with ACC aged younger than 18 years ($n=82$), the 3-year progression-free survival rate was 51%, while the overall survival rate was 55%.²⁸ Similarly, Michalkiewicz reported 5-year event-free survival rate of 91% in children with completely resected tumors weighing less than 200 gm and without distant metastasis.⁴ Poor prognostic factors were: capsular invasion, incomplete surgery, co-presence of metastases, large tumor volume, and a high Weiss score.²⁹

Our patient has a favorable prognosis despite high Weiss score, relatively large-sized tumor, and metastases to IVC and liver. She underwent complete en bloc surgical resection followed by adjuvant mitotane therapy and her hormonal evaluation was normal with no new recurrence albeit short-time follow-up.

Those patients with advanced disease with unresectable or recurrent tumors require some form of chemotherapy. The combination of mitotane, etoposide, Adriamycin, and cisplatin is most commonly used in cases of ACC to improve prognosis.²⁴ Mitotane is an adrenal-selective and cytotoxic drug derived from the insecticide Dichloro Diphenyl Trichloro ethane (DDT).³⁰ It causes adrenal necrosis, especially of cells in the zona glomerulosa and zona fasciculata, and is associated with favorable prognosis.^{30,31} Based on multiple case series or registries, stage III or IV disease is typically

treated with mitotane in combination with cisplatin-based chemotherapy^{32,33} with response rates incomparable to adults. Mitotane has also been used as neoadjuvant therapy for inoperable tumors³² with limited success. Mitotane plasma concentration of 14 to 20 mg/L appears to be the optimal therapeutic range similar to adults.³⁴ There remains debate about the optimal duration of treatment with mitotane: the European Cooperative Study Group for Pediatric Rare Tumours/Pediatric Rare Tumours Network - European Registry recommendations suggest a treatment duration of 1 to 2 years, depending on compliance and tolerance.³² Adrenal insufficiency, increased hepatic enzymes, high cholesterol, gynecomastia, and primary hypothyroidism and precocious puberty are dose-dependent side effects. Mitotane is generally well tolerated, with most adverse events reversible with dose reduction or treatment interruption.

Newer futuristic modalities like an anti-IGF 1R monoclonal antibody, multikinase inhibitors like sorafenib and sunitinib, mammalian target of rapamycin (mTOR) inhibitors everolimus and temsirolimus, epidermal growth factor receptor and vascular endothelial growth factor inhibitors, and Wnt signaling inhibitors are being investigated to treat ACC. Percutaneous radiofrequency ablation, radionuclide therapy, is currently being investigated as a novel therapy for short-term local control of ACC of smaller size.³⁵

Very short follow-up, inability to perform genetic studies, and serum mitotane levels due to financial constraints were few limitations of our case study.

Conclusion

Although rare, ACCs should be considered in the differential diagnosis of CS in the pediatric age group. Early diagnosis, adequate perioperative multidisciplinary management with specific emphasis on postoperative glucocorticoid replacement, complete excision of tumor, and close follow-up for recurrence and metastases are crucial to improve overall survival.

Authors' Contributions

P.P. was involved in conceptualization, designing, literature search, data acquisition, manuscript preparation, manuscript editing, and manuscript review. J.M. helped in literature search, data acquisition, data analysis, manuscript preparation, and manuscript editing. S.Q. contributed to data acquisition and manuscript review. N.K. was involved in data acquisition.

Patient Consent

Informed and written consent taken from the patient through the declaration in the Patient Consent Form.

Source of Funding None.

Conflict of Interest

None declared.

Acknowledgment

None.

References

- 1 Newell-Price J, Bertagna X, Grossman AB, Nieman LK. Cushing's syndrome. *Lancet* 2006;367(9522):1605–1617
- 2 Graversen D, Vestergaard P, Stochholm K, Gravholt CH, Jørgensen JO. Mortality in Cushing's syndrome: a systematic review and meta-analysis. *Eur J Intern Med* 2012;23(03):278–282
- 3 Lacroix A, Bourdeau I. Bilateral adrenal Cushing's syndrome: macronodular adrenal hyperplasia and primary pigmented nodular adrenocortical disease. *Endocrinol Metab Clin North Am* 2005;34(02):441–458, x
- 4 Michalkiewicz E, Sandrini R, Figueiredo B, et al. Clinical and outcome characteristics of children with adrenocortical tumors: a report from the International Pediatric Adrenocortical Tumor Registry. *J Clin Oncol* 2004;22(05):838–845
- 5 Ng L, Libertino JM. Adrenocortical carcinoma: diagnosis, evaluation and treatment. *J Urol* 2003;169(01):5–11
- 6 Nieman LK, Biller BMK, Findling JW, et al. The diagnosis of Cushing's syndrome: an endocrine society clinical practice guideline. *J Clin Endocrinol Metab* 2008;93(05):1526–1540
- 7 Lam AK. Update on adrenal tumours in 2017 World Health Organization (WHO) of endocrine tumours. *Endocr Pathol* 2017;28(03):213–227
- 8 Sutter JA, Grimberg A. Adrenocortical tumors and hyperplasias in childhood—etiology, genetics, clinical presentation and therapy. *Pediatr Endocrinol Rev* 2006;4(01):32–39
- 9 Patalano A, Brancato V, Mantero F. Adrenocortical cancer treatment. *Horm Res* 2009;71(Suppl 1):99–104
- 10 Almeida MQ, Soares IC, Ribeiro TC, et al. Steroidogenic factor 1 overexpression and gene amplification are more frequent in adrenocortical tumors from children than from adults. *J Clin Endocrinol Metab* 2010;95(03):1458–1462
- 11 Tissier F, Cavard C, Groussin L, et al. Mutations of beta-catenin in adrenocortical tumors: activation of the Wnt signaling pathway is a frequent event in both benign and malignant adrenocortical tumors. *Cancer Res* 2005;65(17):7622–7627
- 12 Ribeiro RC, Sandrini F, Figueiredo B, et al. An inherited p53 mutation that contributes in a tissue-specific manner to pediatric adrenal cortical carcinoma. *Proc Natl Acad Sci U S A* 2001;98(16):9330–9335
- 13 Lefevre M, Gerard-Marchant R, Gubler JP, Chaussain JL, Lemerle J. Adrenocortical carcinoma in children: 42 patients treated from 1958 to 1980 at Villejuif. In: Humphrey GB, Grindey GB, Dehner LP, Acton RT, Pysher TJ, eds. *Adrenal and Endocrine Tumors in Children*. New York, NY: Springer; 1983:265–276
- 14 Coulter CL. Fetal adrenal development: insight gained from adrenal tumors. *Trends Endocrinol Metab* 2005;16(05):235–242
- 15 Libé R. Adrenocortical carcinoma (ACC): diagnosis, prognosis, and treatment. *Front Cell Dev Biol* 2015;3:45
- 16 Young WF Jr. Clinical practice. The incidentally discovered adrenal mass. *N Engl J Med* 2007;356(06):601–610
- 17 Ribeiro J, Ribeiro RC, Fletcher BD. Imaging findings in pediatric adrenocortical carcinoma. *Pediatr Radiol* 2000;30(01):45–51
- 18 Pacak K, Eisenhofer G, Goldstein DS. Functional imaging of endocrine tumors: role of positron emission tomography. *Endocr Rev* 2004;25(04):568–580
- 19 Maurea S, Klain M, Mainolfi C, Ziviello M, Salvatore M. The diagnostic role of radionuclide imaging in evaluation of patients with nonhypersecreting adrenal masses. *J Nucl Med* 2001;42(06):884–892
- 20 Mackie GC, Shulkin BL, Ribeiro RC, et al. Use of [18F]fluorodeoxyglucose positron emission tomography in evaluating locally recurrent and metastatic adrenocortical carcinoma. *J Clin Endocrinol Metab* 2006;91(07):2665–2671
- 21 Leboulleux S, Dromain C, Bonniaud G, et al. Diagnostic and prognostic value of 18-fluorodeoxyglucose positron emission tomography in adrenocortical carcinoma: a prospective

- comparison with computed tomography. *J Clin Endocrinol Metab* 2006;91(03):920–925
- 22 Schteingart DE, Doherty GM, Gauger PG, et al. Management of patients with adrenal cancer: recommendations of an international consensus conference. *Endocr Relat Cancer* 2005;12(03):667–680
 - 23 Aubert S, Wacrenier A, Leroy X, et al. Weiss system revisited: a clinicopathologic and immunohistochemical study of 49 adrenocortical tumors. *Am J Surg Pathol* 2002;26(12):1612–1619
 - 24 Li J, Zhang W, Hu H, Zhang Y, Wen Y, Huang D. Adrenocortical carcinoma in eight children: a report and literature review. *Cancer Manag Res* 2021;13:1307–1314
 - 25 Martins-Filho SN, Almeida MQ, Soares I, et al. Clinical impact of pathological features including the Ki-67 labeling index on diagnosis and prognosis of adult and pediatric adrenocortical tumors. *Endocr Pathol* 2021;32(02):288–300
 - 26 Teinturier C, Pauchard MS, Brugières L, Landais P, Chaussain JL, Bougnères PF. Clinical and prognostic aspects of adrenocortical neoplasms in childhood. *Med Pediatr Oncol* 1999;32(02):106–111
 - 27 Ardicli B, User IR, Ciftci AO, et al. Adrenocortical tumours in children: a review of surgical management at a tertiary care centre. *ANZ J Surg* 2021;91(05):992–999
 - 28 Cecchetto G, Ganarin A, Bien E, et al. Outcome and prognostic factors in high-risk childhood adrenocortical carcinomas: a report from the European Cooperative Study Group on Pediatric Rare Tumors (EXPeRT). *Pediatr Blood Cancer* 2017;64(06):64
 - 29 Gulack BC, Rialon KL, Englum BR, et al. Factors associated with survival in pediatric adrenocortical carcinoma: an analysis of the National Cancer Data Base (NCDB). *J Pediatr Surg* 2016;51(01):172–177
 - 30 Terzolo M, Angeli A, Fassnacht M, et al. Adjuvant mitotane treatment for adrenocortical carcinoma. *N Engl J Med* 2007;356(23):2372–2380
 - 31 Redlich A, Boxberger N, Strugala D, et al. Systemic treatment of adrenocortical carcinoma in children: data from the German GPOH-MET 97 trial. *Klin Padiatr* 2012;224(06):366–371
 - 32 Virgone C, Roganovic J, Vorwerk P, et al. Adrenocortical tumours in children and adolescents: the EXPeRT/PARTNER diagnostic and therapeutic recommendations. *Pediatr Blood Cancer* 2021;68(Suppl 4):e29025
 - 33 Rodriguez-Galindo C, Krailo MD, Pinto EM, et al. Treatment of pediatric adrenocortical carcinoma with surgery, retroperitoneal lymph node dissection, and chemotherapy: the Children's Oncology Group ARAR0332 protocol. *J Clin Oncol* 2021;39(22):2463–2473
 - 34 Zancanella P, Pianovski MA, Oliveira BH, et al. Mitotane associated with cisplatin, etoposide, and doxorubicin in advanced childhood adrenocortical carcinoma: mitotane monitoring and tumor regression. *J Pediatr Hematol Oncol* 2006;28(08):513–524
 - 35 Tacon LJ, Prichard RS, Soon PS, Robinson BG, Clifton-Bligh RJ, Sidhu SB. Current and emerging therapies for advanced adrenocortical carcinoma. *Oncologist* 2011;16(01):36–48