



# Clinical Study of 162 Cases of Peritonsillar Abscess Diagnosed by Contrast-Enhanced Computed Tomography

Tadahiko Saiki<sup>1</sup> Teruhiro Ogawa<sup>1</sup> Takenori Haruna<sup>1</sup> Kazuaki Kuroda<sup>2</sup>

<sup>1</sup>Department of Otorhinolaryngology, Himeji St. Mary's Hospital, Hyogo, Japan

<sup>2</sup>Kuroda ENT Aki Clinic, Japan

**Address for correspondence** Tadahiko Saiki, Department of Otorhinolaryngology, Himeji St. Mary's Hospital, 650 Nibuno, Himeji, Hyogo, 670-0801, Japan (e-mail: saiki-t@himemaria.or.jp).

Int J Pract Otolaryngol 2024;7:e8–e15.

## Abstract

In this retrospective clinical study of peritonsillar abscesses, we reviewed the data of 162 patients (116 males and 46 females) with peritonsillar abscess aged 8 to 86 years (mean age, 37.0 years) who had been diagnosed by contrast-enhanced computed tomography (CT), hospitalized, and treated for the abscess between January 2017 and December 2022. The abscess occurred on the left side in 72 (44.4%) patients, on the right side in 80 (49.4%) patients, and bilaterally in 10 (6.2%) patients. The abscess was of the superior oval type on 85 (49.4%) sides, the superior cap type on 41 (23.8%) sides, the inferior oval type on 25 (14.5%) sides, and the inferior cap type on 21 (12.2%) sides. Among 111 patients, bacteriological examination of the abscess fluid for the causative bacteria yielded 78 causative strains, including 24 strains of aerobic bacteria, predominantly *Streptococcus pyogenes* (51.6%), and 47 strains of anaerobic bacteria; the remainder were mixed bacterial strains. Bacterial resistance rates to antibiotics were as follows: 5.8% for piperacillin, 3.4% for ceftriaxone, 2.6% for meropenem, 11.5% for clindamycin, 28.6% for levofloxacin, and 15.4% for minocycline. Of the 162 patients, 83 (48.3%) were treated by incision, 25 (14.5%) by puncture, 62 (36.0%) with antibiotics, and 2 (1.2%) via abscess tonsillectomy. The most frequently used antibiotics (87.2% cases) were ampicillin/sulbactam combined with clindamycin and/or dexamethasone. The peritonsillar abscess recurred in 14 (8.6%) patients, and the recurrence occurred within 3 months of the initial onset in 8 (57.1%) of these patients. In conclusion, contrast-enhanced CT should be performed to accurately diagnose the location, size, and shape of a peritonsillar abscess and select the optimal treatment.

## Keywords

- ▶ peritonsillar abscess
- ▶ contrast-enhanced CT
- ▶ bacteriological examination
- ▶ ampicillin/sulbactam

## Introduction

Peritonsillar abscess is a frequently observed acute infection in routine clinical practice. When exacerbated, peritonsillar abscesses progress downward from the parapharyngeal space and can be fatal. Therefore, rapid and appropriate

treatment is required. In general, when peritonsillar abscess is suspected, the presence of an abscess is confirmed by puncture, after which incision and drainage are often performed. However, for a definite diagnosis and to select the most appropriate treatment method, it is important to determine the location, size, and shape of the abscess.

received  
August 17, 2023  
accepted after revision  
November 2, 2023

DOI <https://doi.org/10.1055/s-0044-1782146>.  
ISSN 2569-1783.

© 2024. The Author(s).

This is an open access article published by Thieme under the terms of the Creative Commons Attribution-NonDerivative-NonCommercial-License, permitting copying and reproduction so long as the original work is given appropriate credit. Contents may not be used for commercial purposes, or adapted, remixed, transformed or built upon. (<https://creativecommons.org/licenses/by-nc-nd/4.0/>)

Georg Thieme Verlag KG, Rüdigerstraße 14, 70469 Stuttgart, Germany

## Materials and Methods

We clinically examined peritonsillar abscesses in which the pathophysiology was accurately diagnosed by contrast-enhanced computed tomography (CT) and treated by inpatient hospital care.

### Subjects and Examination Items

The subject sample included 162 patients (172 sides) with peritonsillar abscess diagnosed by contrast-enhanced CT at the Department of Otorhinolaryngology, Himeji St. Mary's Hospital who were treated on an inpatient basis during the 6-year period from January 2017 to December 2022. Furthermore, patients with concurrent deep neck abscesses at the time of the initial examination were excluded as they would follow a different treatment plan.

During the study period, the model of the contrast-enhanced CT device was changed, and at present, the Siemens 128-slice CT (SOMATOM Definition AS+) is used. The scanning conditions were as follows: tube voltage: 120 kV; auto-exposure control modality: CARE DOSE 4D; rotation time: 1.0 seconds; beam pitch: 0.8 mm/s; beam collimation: 128 × 0.6 mm; slice thickness/interval: 3.0/3.0 mm; and field of view: 200 × 200 mm. At the initial examination, the area extending from the external auditory canal to the upper border of the aortic arch was scanned at 150 seconds after administering a contrast medium injection (Optiray 350 injectable) at a rate of 1 mL/s.

Examination items included the following: (1) age and sex, (2) affected side, (3) number of patients according to type classification, (4) abscess diameter, (5) proportion of type per age, (6) bacteriological test results, (7) drug resistance, (8)

treatment method according to type and diameter of abscess, (9) state of drug usage, (10) recurrence rate, and (11) recurrence time. However, when examining items 3, 4, 5, and 8, bilateral abscesses were treated as two separate cases or two sides.

We performed statistical processing using a Mini Stat-Mate, with a Kruskal–Wallis H-test for multiple comparisons and a median test and a Mann–Whitney *U* test for multiple group comparisons. A *p*-value of <0.05 was considered a statistically significant difference.

The present study was conducted with the approval of the ethical review board for clinical research at Himeji St. Mary's Hospital (approval no. S023-06).

## Results

### Age and Sex

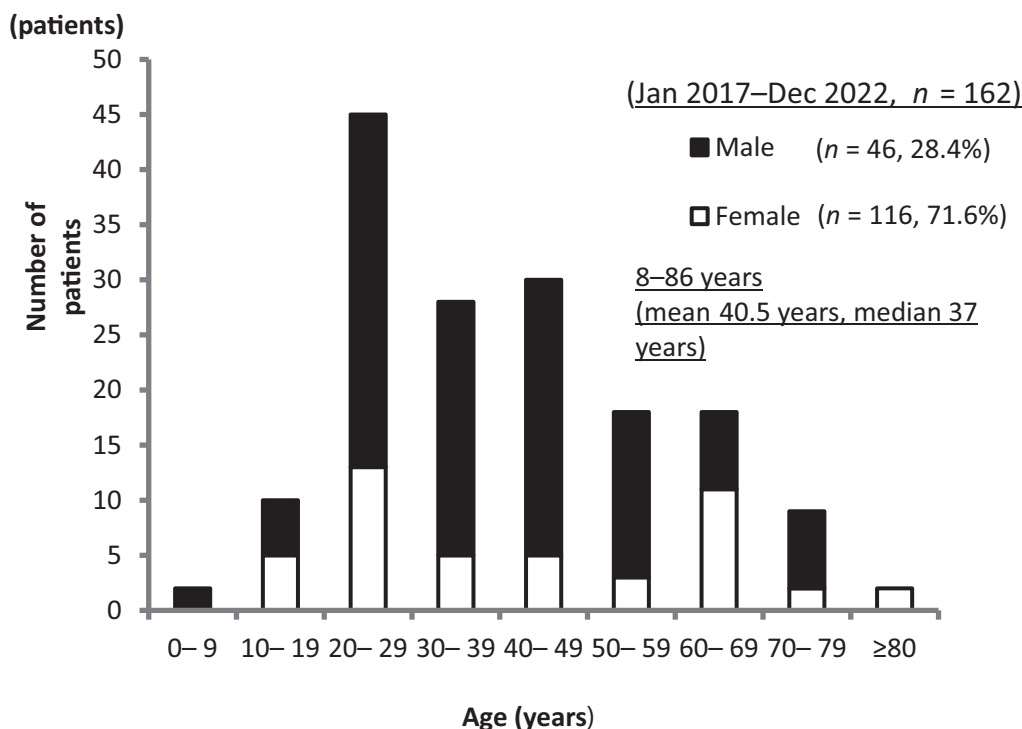
Patients were aged 8 to 86 years; however, they were most commonly aged 20 to 29 years, with a mean age of 40.5 years and a median age of 37 years. Regarding sex, there were 116 male patients (71.6%) and 46 female patients (28.4%), with male patients accounting for more than 70% of the sample size (→Fig. 1).

### Affected Side

The affected side was the left side in 72 patients (44.4%), the right side in 80 patients (49.4%), and both sides in 10 patients (6.2%).

### Number of Patients According to Type Classification

In accordance with the classification of Ohori et al,<sup>1</sup> we classified the abscess type by contrast-enhanced CT; i.e., we measured the maximum diameter of the abscess by contrast-enhanced CT in the axial plane. When the site of the maximum



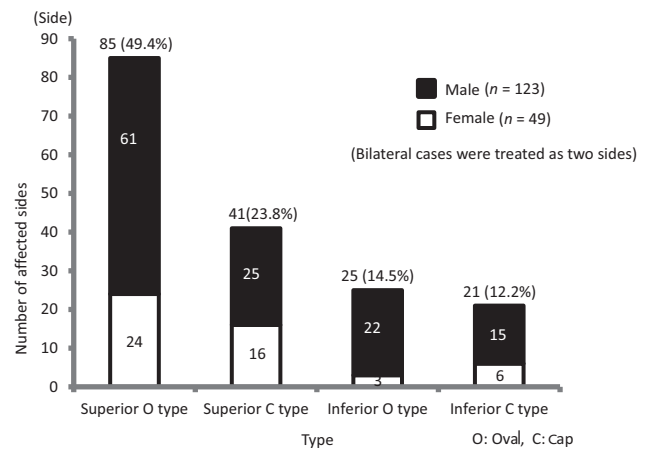
**Fig. 1** Age and sex. Most patients were in their 20s, and male patients accounted for at least 70%.

diameter was cranial to the uvula tip, it was classified as a superior type, and when caudal, it was classified as an inferior type. Furthermore, based on the shape of the abscess, elliptic abscesses arising inside the tonsillar capsule were classified as the oval type, and crescent-shaped abscesses arising outside of the tonsillar capsule were classified as the cap type. Accordingly, we classified four types of contrast-enhanced CT images using the classification method above (► Fig. 2).

Upon examining the incidence per type for 172 sides that underwent contrast-enhanced CT, in descending order, we found superior oval type on 85 sides (49.4%), superior cap type on 41 sides (23.8%), inferior oval type on 25 sides (14.5%), and inferior cap type on 21 sides (12.2%). Furthermore, we found the superior type on 86 sides among male patients (68.3%) and 40 sides among female patients (31.7%), whereas the inferior type was found on 37 sides among male patients (80.4%) and 9 sides among female patients (19.6%), indicating a high proportion of male patients with the inferior type. The site of onset was the superior type on 126 sides (73.3%) and the inferior type on 46 sides (26.7%), and the shape was oval on 110 sides (64.0%) and cap type on 62 sides (36.0%) (► Fig. 3).

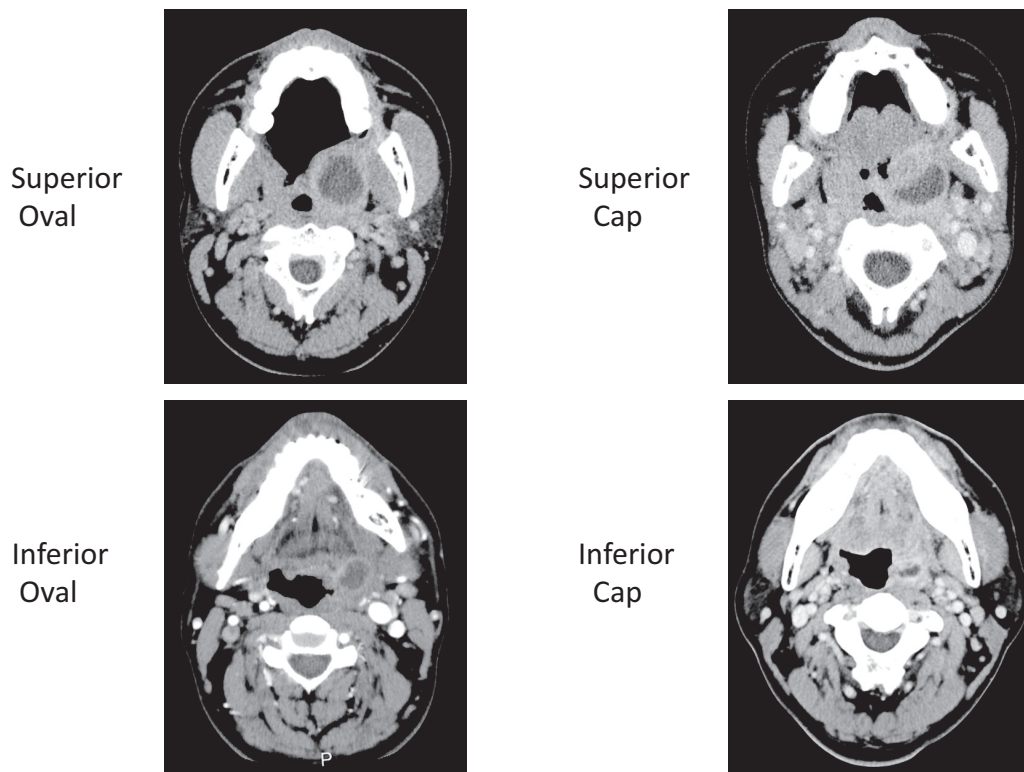
**Abscess Diameter**

Upon measuring the abscess size using the maximum diameter on contrast-enhanced CT in the axial plane, the mean diameter was 16.6 mm and the median diameter was 16.0 mm. According to type, the mean and median were 18.4 and 19 mm for the superior oval type, 16.1 and 15.5 mm



**Fig. 3** Number of patients according to type. The superior oval type accounted for approximately half of the cases, followed in descending order by the superior cap type, inferior oval type, and inferior cap type. Furthermore, a higher proportion of male patients had the inferior type.

for the superior cap type, 13.8 and 15 mm for the inferior oval type, and 15.4 and 16 mm for the inferior cap type. We found a statistically significant difference only between the mean diameters of the superior and inferior oval types ( $p < 0.05$ ), and there were no significant differences between the other types. Furthermore, although there was no significant difference between the abscess types in terms of the median



**Fig. 2** Classification of Ohori et al.<sup>1</sup> We measured the maximum diameter of the abscess cavity using contrast-enhanced CT in the axial plane. When the site of the maximum diameter was cranial to the uvula tip, it was classified as the superior type and as the inferior type when it was caudal. Furthermore, based on the shape of the abscess, elliptic abscesses arising inside the tonsillar capsule were classified as the oval type, and crescent-shaped abscesses arising outside of the tonsillar capsule were classified as the cap type.

diameters, the superior oval type tended to have a greater median diameter than the other types.

**Proportion of Type Per Age**

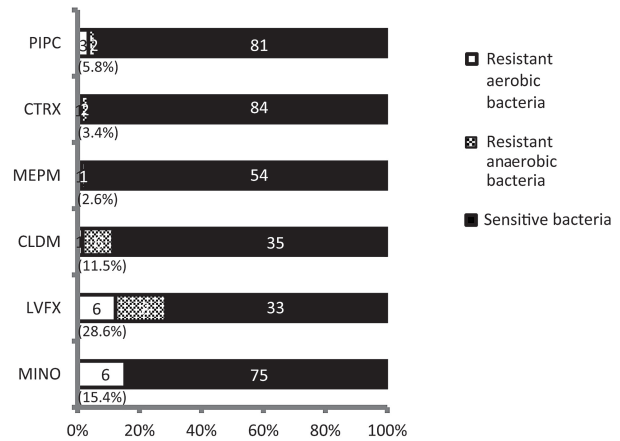
Upon comparing the type of abscess according to the patient's age (<40 years vs. ≥40 years), the superior type accounted for 73 patients aged <40 years (76.8%, oval type in 50 patients and cap type in 23 patients) and 53 patients aged ≥40 years (68.8%, oval type in 35 patients and cap type in 18 patients). On the contrary, the inferior type accounted for 22 patients aged <40 years (23.2%, oval type in 15 patients and cap type in 7 patients) and 24 patients aged ≥40 years (31.2%, oval type in 10 patients and cap type in 14 patients). Although we found no statistically significant difference between the groups, the proportion of inferior type tended to be higher in patients aged ≥40 years than in those aged <40 years (► Fig. 4).

**Bacteriological Test Results**

Bacteriological tests revealed aerobic bacteria strains in 24 patients (21.6%), anaerobic bacteria in 47 patients (42.3%), and mixed aerobic and anaerobic bacterial strains in 7 patients (6.3%), whereas normal bacterial flora or negative test results were found in 33 patients (29.7%). Anaerobic bacterial strains cannot be identified at our hospital; therefore, when presenting strains of aerobic bacteria only, *Streptococcus pyogenes* was the most common in 16 patients (51.6%), followed by *Streptococcus anginosus* in 6 (19.4%), *Streptococcus constellatus* in 3 (9.7%), *Staphylococcus aureus* in 2 (6.5%), and other strains in 4 (12.9%).

**Drug Resistance**

Upon comparing the bacterial resistance to antimicrobials, the resistance rates were low: 5.8% for piperacillin (PIPC), 3.4% for

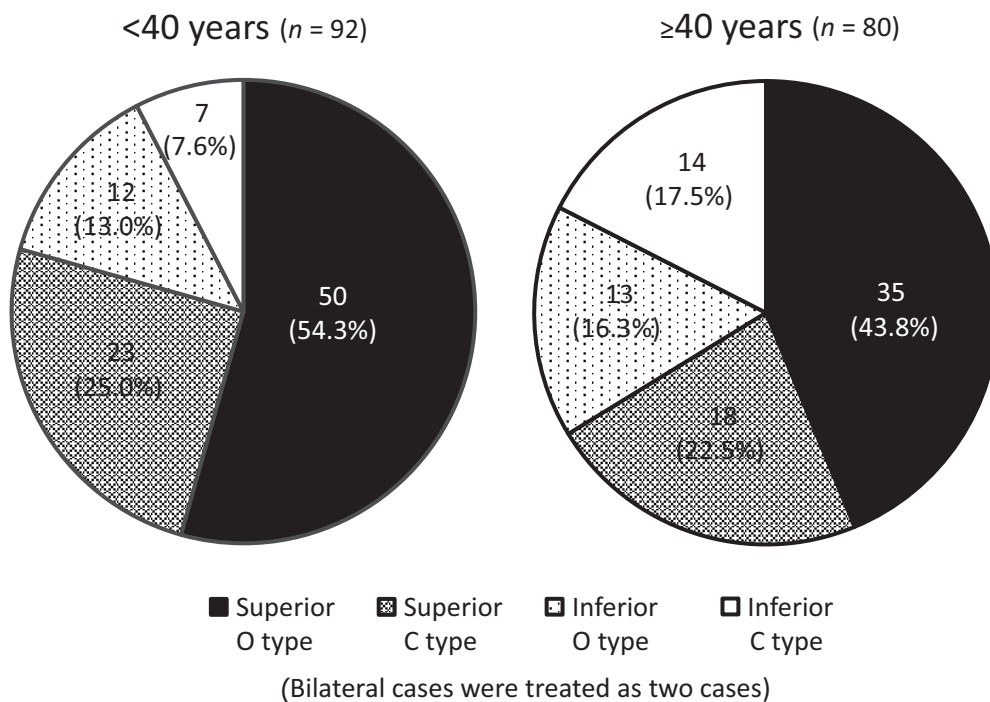


**Fig. 5** Drug resistance. The resistance rates were low for piperacillin (PIPC), ceftriaxone (CTRX), and meropenem (MEPM), but high for clindamycin (CLDM), levofloxacin (LVFX), and minocycline (MINO).

ceftriaxone (CTRX), and 2.6% for meropenem (MEPM). Conversely, the resistance rates were high at 11.5% for clindamycin (CLDM), 28.6% for levofloxacin (LVFX), and 15.4% for minocycline (MINO) (all of which were *S. pyogenes*) (► Fig. 5).

**Treatment Method According to the Type and Diameter of the Abscess**

In terms of treatment method, incision and drip infusion were performed in 83 patients (48.3%), making it the most common treatment, followed by drip infusion alone in 62 patients (36.0%), puncture and drip infusion in 25 patients (14.5%), and abscess tonsillectomy in 2 patients (1.2%). Furthermore, the two patients who underwent abscess



**Fig. 4** Proportion of type per age. Patients aged ≥40 years tended to have a higher rate of inferior-type abscesses than those aged <40 years; O, Oval; C, Cap.

**Table 1** Treatment method according to the type and diameter of the abscess

	Superior Oval		Superior Cap		Inferior Oval		Inferior Cap		Total (side)
	<16 mm	≥16 mm	<16 mm	≥16 mm	<16 mm	≥16 mm	<16 mm	≥16 mm	
Incision + drip infusion	11	40	5	12	4	7	2	2	83 (48.3%)
Puncture + drip infusion	3	7	2	5	2	4	0	2	25 (14.5%)
Drip infusion alone	16	7	13	5	7	1	7	6	62 (36.0%)
Abscess tonsillectomy	0	1	0	0	0	1	0	0	2 (1.2%)
Total	30	55	20	22	13	13	9	10	172 (100%)

Note: Incision and drip infusion comprised the most common treatment, accounting for approximately half of cases, followed in descending order by drip infusion alone, puncture and drip infusion, and abscess tonsillectomy. For patients with the superior type and abscess size ≥16 mm, incisions were often used common, and for patients with an abscess size <16 mm in all types, there was a higher rate of treatment by drip infusion alone. \*The bilateral cases are treated as two sides.

tonsillectomy were boys aged 8 and 9 years. For patients with the superior type and abscess size ≥16 mm, incision was common. Conversely, for patients with an abscess size <16 mm in all types, there was a higher rate of treatment by drip infusion alone (►Table 1).

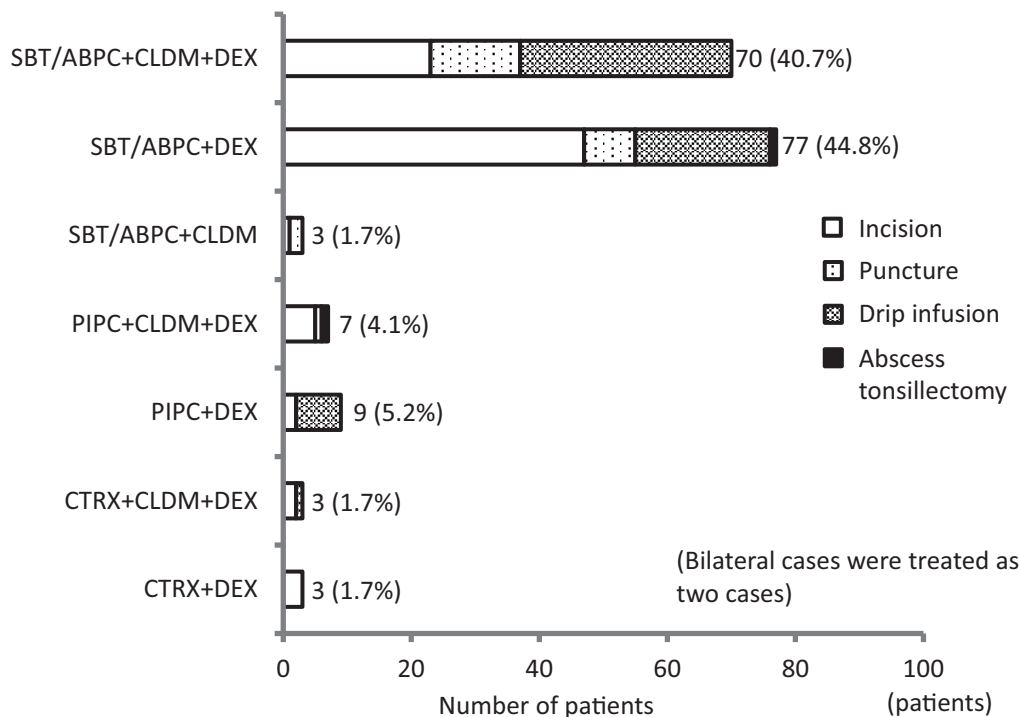
**State of Drug Usage**

The most commonly used antibiotics were ampicillin/sulbactam (SBT/ABPC), which accounted for 87.2%. Upon examining drug combinations, the most commonly used drugs concurrently included SBT/ABPC with dexamethasone (DEX), which was administered in 77

patients (44.8%), followed by SBT/ABPC with CLDM and DEX in 70 patients (40.7%), PIPC and DEX in 9 patients (5.2%), and PIPC with CLDM and DEX in 7 patients (4.1%) (►Fig. 6).

**Recurrence Rate**

Recurrence of peritonsillar abscess was found in 14 of 162 patients (8.6%). For the classification type on contrast-enhanced CT, we found the superior oval type on 11 sides, the superior cap type on 4 sides, the inferior oval type on 1 side, and the inferior cap type on 0 sides, with the superior type found in 15 of 16 sides (the two patients with bilateral



**Fig. 6** State of drug usage. The most commonly used antibiotics were ampicillin/sulbactam (SBT/ABPC), which accounted for 87.2%. CLDM, clindamycin; CTRX, ceftriaxone; DEX, dexamethasone; PIPC, piperacillin.

abscesses presented the superior oval type, both of which were treated as two sides). The side of recurrence was the same as the initial side in 12 patients (85.7%), and 2 patients (14.3%) who initially presented with unilateral abscesses had bilateral abscesses at recurrence. Furthermore, among the 162 patients who were examined in the present study, 18 (11.1%) underwent elective tonsillectomy after experiencing a peritonsillar abscess, and among them were 8 of the 14 patients (57.1%) who experienced recurrence.

### Recurrence Time

Upon examining the time to recurrence of peritonsillar abscess, we found that recurrence developed within 3 months after discharge in eight patients (57.1%) and 12 to 36 months in six patients (42.9%) (→Fig. 7).

### Discussion

In the present study, we included patients who underwent contrast-enhanced CT and in whom the site, size, and shape of the peritonsillar abscess were accurately identified. Although the lesion range can be confirmed on plain CT, it is difficult to assess abscesses in detail. Furthermore, to achieve a rapid, definite diagnosis and select the best treatment method, the initial examination is the appropriate time to perform a contrast-enhanced CT scan; however, in mild cases, contrast-enhanced CT can be performed when conservative treatment is first provided and exacerbation of symptoms is subsequently observed.

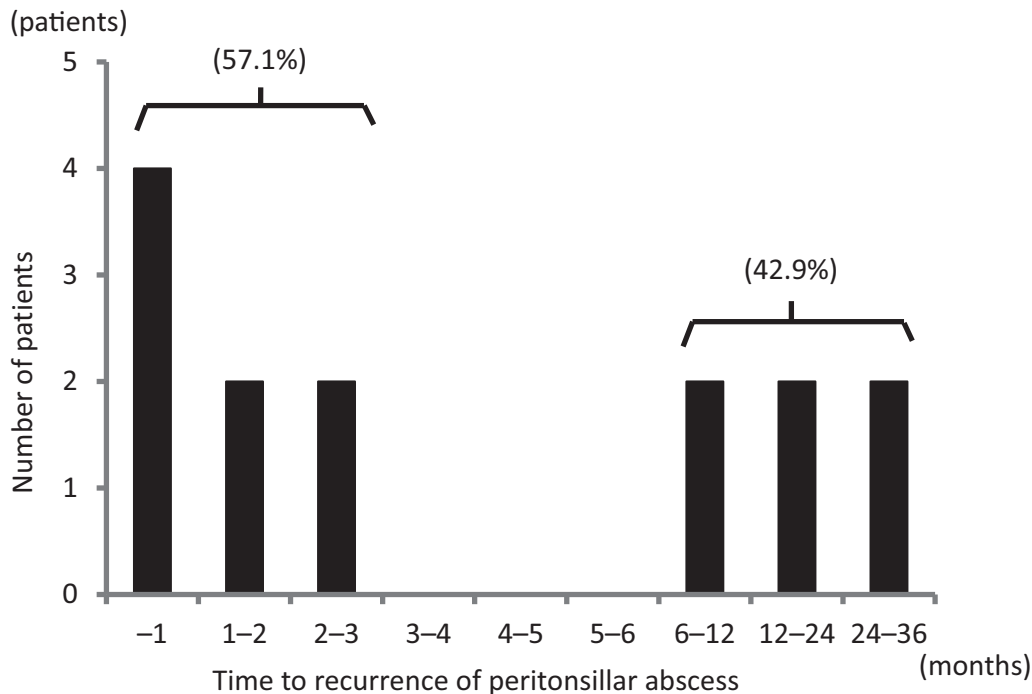
Many reports indicate that the most common age group when peritonsillar abscess occurs is 20 to 39 years,<sup>2-6</sup> which

is consistent with the results obtained in our patients. The reason for this can be attributed to the reduced immunity of the tonsils at those ages and the active growth of tonsillar connective tissue at the site of infection.<sup>7,8</sup>

Regarding sex, many reports have indicated that male patients account for approximately 60 to 80% of cases,<sup>3-6,9-11</sup> which is consistent with our results. As the reason underlying the frequent onset among males, it has been reported that males are at greater risk of infection than females<sup>12</sup> and that the female hormone estrogen exerts an inhibitory action against inflammation through its antiplasmin activity.<sup>7,13</sup>

Regarding the affected side, many reports have indicated that there is no difference between the left and right sides and that bilateral cases account for approximately 1 to 5%.<sup>2-6,10,11</sup> In our patients, the rate of bilateral cases was somewhat high (6.2%), which could be attributed to the fact that all patients underwent contrast-enhanced CT and had lesions precisely evaluated in the present study. We believe that bilateral cases are more common than those reported to date.

The site of onset was more frequently the superior type than the inferior type, with the former accounting for approximately 60 to 80%,<sup>2,3,5,9,11</sup> and the results in our patients were also similar, with the superior type accounting for 73.8%. The superior type is thought to be common because this condition is caused by infection of the salivary glands (Weber's glands), located in the superior pole of the tonsils.<sup>1,14</sup> Kraitrakul et al<sup>13</sup> pointed out that the minor salivary glands in the peritonsillar space are not located solely in the superior pole of the tonsils but are rather distributed across all areas. Accordingly, peritonsillar



**Fig. 7** Recurrence time. Recurrence developed within 3 months after discharge in 8 patients (57.1%).



abscesses can potentially form as a result of infection of the minor salivary glands located in all peritonsillar areas; however, cases of abscess formation within the tonsils can also be caused by occluded crypts.

In the present study, we classified contrast-enhanced CT features into four types according to the classification of Ogori et al<sup>1</sup> as follows: superior oval type, superior cap type, inferior oval type, and inferior cap type. It is inferred that the oval type is an intracapsular abscess that forms due to infection of the peritonsillar minor salivary glands, whereas the cap type is an extracapsular abscess that forms due to recurrent tonsillar and peritonsillar inflammation that causes irregular tissue structure.<sup>1</sup> Upon comparing the types according to age, we found that the inferior type accounted for a high proportion of cases among patients aged 40 years and older. The inferior type may be common among older adult patients because the crypts of the palatine tonsils enlarge with aging; therefore, in older adults, there is a reduction in the area of the tonsillar crypts, which makes it difficult for bacteria to accumulate in the crypts, and by contrast, the relativity of the crypt depth decreases in both the superior and inferior poles.<sup>15</sup> Furthermore, compared with the superior types and inferior oval types, the inferior cap type had a significantly higher frequency of laryngeal swelling and tracheostomy and has been reported to readily cause airway obstruction.<sup>1</sup>

On measurements using the maximum diameter on contrast-enhanced CT in the axial plain, the abscess size was a mean of 16.6 mm and a median of 16 mm. Furthermore, upon comparing abscess size according to type, although we found no statistically significant difference, the size of the superior oval type tended to be larger than the other types. Oka et al<sup>9</sup> reported that the maximum abscess diameter was a mean of 19.4 mm for the superior type and 13.6 mm for the inferior type, which indicates that the superior type was significantly larger.

In the bacteriological tests, aerobic bacterial strains were found in 27.9% of our patients and anaerobic bacterial strains were found in 48.6%, indicating that anaerobic strains accounted for a higher proportion of the detected bacterial strains. Suzuki et al<sup>16</sup> also noted that the detection rate of anaerobic bacterial strains increased gradually.

In terms of treatment, incision and drainage has been performed in 60 to 90%, needle aspiration in 10 to 30%, and conservative treatment in several to 20% of cases.<sup>2,4,5,10,11</sup> As the inferior type abscess develops near the carotid artery, vagal nerve, and hypoglossal nerve, incision and drainage carry the risk of injury; thus, incision must be performed only after the blood vessels and abscess location have been accurately identified, such as by contrast-enhanced CT.<sup>5</sup> Furthermore, researchers have reported that with inferior cap-type peritonsillar abscesses, laryngeal swelling can readily occur, making drainage via the oral cavity difficult. In these cases, surgical treatment is needed, such as abscess tonsillectomy, to fully drain the abscess.<sup>1,17</sup> Among our patients, abscess tonsillectomy was performed in only two boys aged 8 and 9 years because puncture and incision under

local anesthesia as well as subsequent treatment would be difficult.

Although some reports found no difference in therapeutic outcomes between incision and drainage in contrast to needle aspiration,<sup>4,9,10,18</sup> incision and drainage not only have the effect of reducing pus but also improve the acidic environment, inhibit proliferation of anaerobic strains, and have the advantage that a bactericidal effect of oxygen against anaerobic strains can be expected.<sup>19</sup> In our department, incisions are proactively attempted on patients who are able to undergo incision and drainage. Transoral pharyngeal ultrasonography-guided puncture for the peritonsillar has been reported.<sup>20</sup> However, to further improve the hit rate of puncture and incision in the future, we anticipate the development of a peritonsillar abscess-specific probe with a puncture needle guide.

The indication of conservative treatment involves abscess size. Many reports have shown that when the abscess diameter is less than 15 to 16 mm, there is a high chance of a cure with conservative treatment.<sup>4,9,19,21</sup> The rate of conservative treatment was also high among our patients with an abscess diameter of <16 mm. Therefore, as an index to select conservative treatment, it is useful to accurately evaluate the size and shape of the abscess using contrast-enhanced CT.

In terms of drug resistance, Wakisaka et al<sup>11</sup> reported CLDM resistance in 17% and no resistance to SBT/ABPC. In the present study, we also found resistance of anaerobic strains to CLDM. Although CLDM has often been used to date to treat anaerobic strains, for *Prevotella* strains, which are the most common anaerobic bacteria in peritonsillar abscesses, the sensitivity to CLDM is 55%<sup>16</sup> and 25% of group A hemolytic *Streptococcus* are resistant to CLDM.<sup>22</sup> Thus, some researchers currently believe that CLDM cannot be called a suitable drug for treatment.<sup>23</sup> Resistance to LVFX was found in 28.6% of cases. It was reported that the antimicrobial activity of new quinolones is attenuated in acidic environments; therefore, new quinolones are not recommended for patients who develop neck abscesses.<sup>24</sup> On the contrary, considering that *S. pyogenes* still have no resistance to penicillin, most anaerobic bacterial strains produce beta-lactamase, and given the presence of resistant strains, the use of SBT/ABPC, which is a combination drug of penicillin and a beta-lactamase inhibitor, is recommended.<sup>25</sup> Similarly, in our patients, the most commonly used antibacterial agent was SBT/ABPC, accounting for 87.2%. Furthermore, adrenocortical hormone preparations should be used in severe cases and in patients with laryngeal swelling.

Regarding prognosis, some reports have indicated a 5.2 to 14% recurrence rate of peritonsillar abscess.<sup>2,4,5,11</sup> In addition, because some patients might consult a different hospital at recurrence, it is inferred that the actual recurrence rate is higher. One study reported that the time to recurrence was <3 months in 47% and ≥3 years in 27% of patients,<sup>11</sup> whereas other reports indicated a time to recurrence of <2 months in 36.7% and 1 year or more in 40% of patients.<sup>2</sup> Among our patients, 57.1% experienced recurrence within 3 months

after discharge, possibly because the abscess was not completely cured and was in a “smoldering” state.

## Conclusion

We conducted a clinical study of 162 patients (172 sides) with peritonsillar abscess confirmed by contrast-enhanced CT at the Department of Otorhinolaryngology, Himeji St. Mary's Hospital, who were treated on an inpatient basis during a 6-year period from January 2017 to December 2022. The age of the patients ranged from 8 to 86 years; however, most patients were aged 20 to 29 years, with a mean age of 40.5 years and a median age of 37 years. There were 116 male patients (71.6%) and 46 female patients (28.4%).

The left side was the affected side in 72 patients (44.4%), the right side in 80 patients (49.4%), and bilateral abscess was found in 10 patients (6.2%).

In descending order, the numbers of patients according to type based on the contrast-enhanced CT scan were as follows: superior oval type in 85 patients (49.4%), superior cap type in 41 patients (23.8%), inferior oval type in 25 patients (14.5%), and inferior cap type in 21 patients (12.2%). The maximum abscess diameter had a mean of 16.6 mm and a median of 16.0 mm. The superior oval type tended to be larger than the other types. A high proportion of patients aged 40 years and older tended to have the inferior type.

Anaerobic strains were detected in 48.6% of patients, and resistance to CLDM was found in 11.5%.

Many patients with superior-type abscesses of 16 mm or larger were treated by incision, and among patients with all types and abscess sizes smaller than 16 mm, there was a high proportion of those treated by drip infusion alone. The use of SBT/ABPC was most common, at 87.2%.

There were 14 patients (8.6%) with recurrence of peritonsillar abscess, among whom 8 (57.1%) developed recurrence within 3 months.

We conclude that the accurate diagnosis of the peritonsillar abscess site, size, and shape by contrast-enhanced CT is useful for selecting the most appropriate treatment method.

### Funding

None.

### Conflict of interest

None declared.

## References

- Ohori J, Umakoshi M, Miyashita K, Hayamizu Y, Harada M, Kurono Y. Computed tomography image analysis of peritonsillar abscess [in Japanese]. *Nihon Jibiinkoka Gakkai Kaiho* 2013;116(08):947–952
- Saiki T, Sakaki M, Watanabe F. Clinical study of 215 cases of peritonsillar abscess. *Oto-Rhino-Laryngologica* 2010;103:1021–1027
- Bando N, Goto T. A retrospective study of peritonsillar abscess. *The J Jpn Soc Infect Aerosol Orl* 2017;5:5–10
- Adachi M, Tobita T, Akizuki H. A study on 140 hospitalized patients with peritonsillar abscess. *Oto-Rhino-Laryngologica* 2019;112:47–53
- Koizumi S, Watanabe K, Ishigaki K, Unuma M, Oda K, Oyama K. Peritonsillar abscess: a retrospective analysis of 210 cases. *Nihon Jibiinkoka Gakkai Kaiho* 2021;124:1013–1020
- Miyagi M, Miyamoto Y, Kai T, et al. Clinical study of hospitalized patients with peritonsillar abscess. *Otologia Fukuoku* 2022;68:258–265
- Matsuoka A, Shitara T, Yao K, et al. A clinical study of peritonsillar abscess. *The J Jpn Soc Tonsil Problem* 1989;28:162–168
- Kato H, Wada I, Nakada H, et al. A clinical and statistical study of admitted peritonsillar abscess cases. *Stomato-Pharyngol* 2006;18:421–428
- Oka A, Makihara S. Study of CT findings and clinical course of peritonsillar abscesses. *J Jpn Bronchoesophagol Soc* 2017;68:217–221
- Umibe A, Anazawa U, Kessoku H, et al. Clinical analyses of 115 patients with peritonsillar abscess. *Nihon Jibiinkoka Gakkai Kaiho* 2015;118(10):1220–1225
- Wakisaka R, Kumai T, Kishibe K, et al. Clinical study of 107 hospitalized patients with peritonsillar abscess. *Int J Pract Otolaryngol* 2021;4:e11–e16
- Kanabayashi H, Ogawa Y, Yamanishi T, et al. Clinical investigation of the peritonsillar abscess. *O.R.L. Tokyo* 2003;46:284–288
- Kraitrakul S, Sirithunyaporn S, Yimtae K. Distribution of minor salivary glands in the peritonsillar space. *J Med Assoc Thai* 2001;84(03):371–378
- Passy V. Pathogenesis of peritonsillar abscess. *Laryngoscope* 1994;104(02):185–190
- Kawabata M, Umakoshi M, Matsumoto H, et al. The clinical characteristics of inferior pole peritonsillar abscesses. *Stomato-Pharyngol* 2018;31:187–192
- Suzuki K, Kurono Y, Ikeda K, et al. The sixth nationwide surveillance of clinical isolates from patients with six otolaryngological field infections and antimicrobial susceptibility pattern in the isolated pathogens in Japan. *The J Jpn Soc Infect Aerosol Orl* 2020;8:193–211
- Maruyama Y, Tsukada Y, Kitagawa Y, Yoshikawa T, Kojima S, Yoshizaki T. Usefulness of abscess tonsillectomy for the treatment of severe peritonsillar abscess. *Nihon Jibiinkoka Tokeibugeka Gakkai Kaiho* 2021;124:1398–1405
- Kobayashi K, Imai R. Study of both the axial length of the peritonsillar abscess and the clinical course by the method of treatment. *Stomato-Pharyngol* 2014;27:81–86
- Aoi N. The indication for and the limit of needle aspiration or incision and drainage for the treatment of peritonsillar abscess. *Stomato-Pharyngol* 2013;26:1–6
- Hagiwara Y, Kikuchi T, Akasu Y, et al. Transoral pharyngeal ultrasonography guiding puncture for peritonsillar abscess: the application of transoral carotid ultrasonography. *Neurosonology* 2020;33:45–49
- Kobayashi K, Imai R. Clinical investigation of peritonsillar abscess and CT findings (3rd Report). *Stomato-Pharyngol* 2013;26:131–136
- Takahashi T, Arai K, Lee DH, et al. Epidemiological study of erythromycin-resistant *Streptococcus pyogenes* from Korea and Japan by emm genotyping and multilocus sequence typing. *Ann Lab Med* 2016;36(01):9–14
- Yano H. Peritonsillar abscess-causing bacteria and selection of antimicrobials. *Johns* 2022;38:1435–1437
- Suzuki K. Countermeasures against AMR in the treatment of neck infections. *Johns* 2021;37:823–825
- Bando N, Harabuchi Y. Abscess management and pitfalls. Abscess in the oral floor and Ludwig's angina (cellulitis of the floor of the mouth). *J Jpn Soc H&N Surg* 2015;87:134–140