




A Study of Outcome of Detethering in Delayed Presentation of Tethered Cord Syndrome

Hemant Kumar Beniwal¹  N. Pratap K.² Prakash Rao G.² K. Srinivas² Krishnamurthy Talari²
Uday Goutam Nookathota²

¹ Department of Neurosurgery, Beniwal Sadan, Churu, Rajasthan, India

² Department of Neurosurgery, Gandhi Medical College and Hospital, Secunderabad, Telangana, India

Address for correspondence Hemant Kumar Beniwal, MBBS, MS, MCH, Department of Neurosurgery, Beniwal Sadan, Ward No 42, Pragati Nagar, Sujangarh, Churu, Rajasthan 331507, India (e-mail: sujanheamnat@gmail.com).

Indian J Neurosurg 2025;14:219–224.

Abstract

Introduction Tethered cord syndrome (TCS) is a stretch-induced functional disorder associated with tethering of caudal spinal cord to dura mater with inelastic tissue, limiting its movement. It not only manifests in childhood but also noted in adults. Here, we studied the role of detethering on delayed presentation of TCS.

Material and Methods All patients of symptomatic TCS from January 2011 to December 2019 were included. Preoperative evaluation was done through X-ray; ultrasonography kidney, ureter, urinary bladder; magnetic resonance imaging spine and brain; and urodynamic studies. Detethering was done and associated pathology was excised. Preoperative and postoperative comparison was done through Necker functional score using chi-squared system.

Results Age range was 8 to 30 years with mean age of 13.8 years. Most common presentation was urological manifestations in ~61.1% of cases followed by pain in 41.6%, sensory deficits in 38.8%, asymmetric weakness in 30.5%, orthopaedic and trophic ulcers in 22.2% each, and bowel abnormalities in 13.8% of cases. Mean duration of symptoms was 5.52 years. Improvement in urological manifestations was in 71.4% patients, pain in 80%, sensory dysfunctions in 71.4%, bowel dysfunctions in 80%, motor weakness in 90.9%, and trophic ulcer in 100% patients. On comparison, chi-squared value was 25.9993 and *p*-value was 0.000032, which was significant (<0.05).

Conclusion Detethering in early ages is already proven with good results. In our study, detethering showed statistically significant improvement even in delayed presentation. So, authors recommend to surgically interfere by detethering, even if tethering is detected late with significant deficits.

Keywords

- ▶ tethered cord syndrome (TCS)
- ▶ Necker functional score
- ▶ chi-squared value

Introduction

Tethered cord syndrome (TCS) is a stretch-induced functional disorder, which is defined as tethering of caudal spinal cord to dura mater with inelastic tissue that limits its movement.¹ This abnormal attachment is associated with

progressive stretching and increased tension on the spinal cord during vertebral column movement and childhood growth spurts, resulting in a variety of neurological and other symptoms.

If the spinal cord is tethered at its caudal end with inelastic tissue to dura mater, and the spinal cord is unable

article published online
May 3, 2024

DOI <https://doi.org/10.1055/s-0044-1782689>.
ISSN 2277-954X.

© 2024. The Author(s).

This is an open access article published by Thieme under the terms of the Creative Commons Attribution License, permitting unrestricted use, distribution, and reproduction so long as the original work is properly cited. (<https://creativecommons.org/licenses/by/4.0/>).

Thieme Medical and Scientific Publishers Pvt. Ltd., A-12, 2nd Floor, Sector 2, Noida-201301 UP, India

to undergo the natural regress in childhood, the spinal cord is stretched beyond its physiological tolerance. This causes various metabolic abnormalities in the spinal cord, resulting in various neurological symptoms of this disorder. Pathophysiologically, neuronal dysfunction in TCS results from inability of the spinal cord neurons to utilize oxygen, that is, the impaired oxidative metabolism,² due to lack of oxygen supply (ischemic effect) and ion channel dysfunction directly related to neuronal membrane stretching. Clinically, it manifests by progressive sensory motor, urological, and musculoskeletal deformities.³⁻⁶

There is proven role of surgical detethering in early age presentation because of the probability of irreversibility of the symptoms.⁷⁻¹¹ Improvement after detethering in delayed presentation of TCS is still on debate and limited literature is available on it. Therefore, we studied the role of detethering on delayed presentation of TCS.

Materials and Methods

A prospective study on all patients admitted in Neurosurgery Department of Gandhi Hospital, Secunderabad, with a diagnosis of TCS from 2011 to 2019 was done.

Inclusion Criteria

All symptomatic cases of TCS presenting at or after secondary growth spurt (8–10 years).

Exclusion Criteria

Symptomatic cases of TCS presenting before the secondary growth spurt (<8 years).

Preoperative assessment was done by clinical features, plain X-ray; ultrasound kidney; ureter, urinary bladder (KUB); magnetic resonance imaging (MRI) brain and spine; and urodynamic studies. Necker functional scoring (NFS) system (–Table 1) was used to grade the patients based on their deficits. Orthopaedic and urological evaluation was done by the respective departments.

All patients were subjected to detethering of the cord in standard manner by excising the thickened filum terminale (–Fig. 3), and associated factors that cause tethering like lipomenigocele, adhesive bands. Intraoperative neuromonitoring was done in selected cases.

Follow-up assessment of patients was done by clinical examination, MRI of the whole spine, and ultrasound KUB at 3, 6, and 12 months and annually.

Results

Out of total 36 patients, 22 patients were male and 14 were female. Mean age of patients was 13.8 years, in which minimum age was 8 years and maximum age was 30 years. Primary cases were 23 (63.8%) and rest 13 (36.2%) cases were secondary, which underwent spinal surgery previously or tethering due to other secondary causes. Various presentations are shown in –Table 2. Urological manifestations were found as most common presentation in 22(61.1%) patients. Mean duration of symptoms was 5.52 years. Various cutaneous manifestations (–Fig. 1) were associated with 13(56.5%) primary cases, which are enlisted in –Table 3. Most common radiological finding was thickened filum terminale in 28 (77.7%) cases, followed by low lying conus (below L2) in 15 (41.6%) cases (–Table 3, –Fig. 2).

After detethering, significant improvement was noted in all these manifestations (–Table 3). Pain improved in 85%, sensory dysfunctions improved in 70%, and bowel dysfunctions improved in 80% patients. All patients of motor weakness and trophic ulcer showed improvement. Least improvement was noted in orthopaedic manifestations. Postsurgical complications were found in total four patients.

The overall functional outcome of detethering was satisfactory. Preoperatively, only 25% of patients scored above 15 in NFS system, while postoperatively, 86.1% of patients were at this score. Comparison of preoperative and postoperative NFS was done by statistical analysis using chi-squared system. Through this analysis, chi-square value was 25.9993 and *p*-value was 0.000032, which was <0.05, showing high significance.

Discussion

TCS is a stretch-induced mechanical damage to neural tissue leading to functional disorder. Normally, during regression of spinal cord, growth rate of vertebral column and neural

Table 1 Necker functional scoring system

Score	Motor	Sensory	Bladder	Bowel
1	Wheelchair Major deficit ^a	Skin ulceration Amputation	Day and night incontinence Incontinence ^a	Incontinence
2	Major orthosis Two crutches	Pain	Night incontinence Retention ^a	Painful constipation Digital maneuvers ^a
3	Distal orthosis	Painless deficit	Intermittent catheterization	Constipation
4	Fatigue on walking	Normal	Dysuria, stress incontinence	Normal
5	Normal		Normal	

^aFor children less than 3 years.

Maximum score is 18; those who scores above 15 can lead a normal life.

Table 2 Various presentations and postoperative improvement of 36 patients

Features	No of patients	Percentage	Postoperative improvement
Presentations			
Low backache	15	41.6	12 (80%)
Sensory deficits	14	38.8	10 (71.4%)
Weakness of lower limbs	11	30.5	10 (90.9%)
Urological deficits	22	61.1	16 (72.7%)
Trophic ulcers	8	22.2	8 (100%)
Bowel abnormalities	5	13.8	4 (80%)
Orthopaedic deficits	8	22.2	3 (51.1%)

tissue is different, which leads to ascent of cord up to L1 to L2 level in vertebral column.

True TCS is caused mechanically by an inelastic thickened filum terminale,¹² which is considered as primary TCS, while TCS caused by spinal cord tumors, lipomas, dermoids, or scar tissue of previous spinal surgeries is considered as secondary.

During development, differential growth of spinal cord and vertebral column occurs. If tethering of cord is present, it restricts movement of spinal cord in thecal sac,^{1,13} which leads to progressive stretching and increased tension on the

spinal cord during vertebral column movement and childhood growth spurts, resulting in a variety of neurological and other symptoms.^{1,3}

TCS commonly manifests in childhood, with limited number of studies describing in adults.^{5,6} Children with TCS become symptomatic for the first time during the first growth spurt up to 5 years and at secondary growth spurt or pubertal growth spurt after the age of 8 years.

In our study, all cases of TCS were included who presented late or were neglected at initial presentation of disease. Mean age of the study was 13.8 years and maximum age of 30 years was found in one patient. Maximum patients 13(36.1%) were found in age group between 8 and 10 years followed by 12 (33.3%) in 11 to 15 years age group. Total 25 patients out of 36 were found in pubertal growth spurt age, while 11 patients were found in between 16 and 30 years age.

Garg et al reported a study on management of adult TCS, in which total 24 patients were included having age group of ≥ 16 years.¹⁴

Patients with TCS may present with neurological, orthopaedic, and urological manifestations as well as pain, along with some associated cutaneous manifestations, which are common in primary cases. TCS is a gradually progressive condition, which becomes symptomatic during growth spurts. There are various precipitating or aggravating factors. Presentation of TCS in children and adults may also vary, where main presenting symptom in adults is pain while in children neurourological symptoms are common.

In our study, maximum 22 cases (61.1%) presented with urological complains like bladder incontinence, nocturnal enuresis, retention, and urinary tract infections. Irrespective of gender, urological presentation was more common on comparison of other presentations. Second most common presentation was pain, mainly at lower back region in 15 patients (41.6%).

In Garg et al study, common presentation was pain in 66.7% cases followed by urological manifestations in 50%, motor dysfunction in 37.5%, sensory dysfunction in 25%, and bowel dysfunction in 25% cases. In this study, age group was >16 years. Bowman et al reported that 26% patients presented with urological manifestations, while 17% cases presented with pain. Age restriction was not done in this

Table 3 Various parameters of 36 patients

Features	No of patients	Percentage
Demographic profile		
Mean age	13.8 years	
Male	22	61
Female	14	39
Primary	23	63.8
Secondary	13	36.2
Cutaneous manifestations	(primary cases-23)	
Dermal sinus	5	
Dimpling of skin	3	
Tuft of hairs	4	
Subcutaneous dermoid	1	
Radiological findings		
Thickened filum terminale	28	77.7
Low lying conus	15	41.6
Adhesive bands	4	11.1
Split cord	4	11.1
Hemivertebra	1	2.7
Syrinx	2	5.5
Dermal sinus tract	2	5.5
Dermoid	3	8.33
Terminal lipoma	2	5.5

study and maximum cases were found in between 1 and 9 years. Scoliosis was found in 40% cases and motor dysfunction was found in 41% cases.¹⁵

It is commonly believed that children, who have a congenital tethered cord, get benefit from surgical detethering because it prevents neurological deterioration.¹⁶⁻¹⁸ The same rationale is extended to adult TCS also. It is believed that patients with primary tethered cord will sooner or later experience worsening of neurological deficits if they do not undergo spinal cord detethering.^{19,20} If this condition is treated promptly after the appearance of deficits, it shows better postoperative outcome.^{17,18}

Klekamp studied 85 adult TCS patients and concluded that surgery in adult patients with a TCS reserved for those with symptoms and a conservative approach was warranted in adult patients without neurological deficits.²¹

In our series, we detethered filum at the lowest possible level as close to the thecal attachment as possible and this will avoid any injury to roots and neural tissue and preferential beyond L5 to S1 level. This approach is very much beneficial where intraoperative neuromonitoring is not available. Before detethering, filum terminale was always inspected and all roots adherent to it were dissected free and then detethering was achieved. Associated anomalies were dealt by excision of various causative elements like lipoma, dermoid, epidermoid, dermal sinus, adhesive band, or bony or membranous septum. Intraoperative neuromonitoring was used in only few cases, with the help of other center, and we found it useful in identifying neural elements precisely. However, intraoperative electromyography may be useful in these cases. Pang and Wilberger and Haro et al have argued that intraoperative spinal cord monitoring is indispensable to safe operation because functional neural elements are often found embedded within lipomatous tissue.^{22,23}

The urinary system was the most frequently affected due to traction on the cauda conus. Detethering improves the oxidative metabolism in cauda conus, thereby increasing the reflex arc of the bladder and showing better results in bladder function compared with other deficits. In our study, we observed significant improvement in urinary symptoms in 72.7% of the patients. Clinically, all of these patients were able to feel the fullness of bladder and control of voiding of urine. On ultrasonography, all of these patients showed decreased postoperative postvoidal residual volume as compared with their preoperative status. Postoperative residual volume less than 50 mL was noted as 100% improvement in urological functions. In 27.3% of the patients, no improvement was noted in urological functions clinically and radiologically on early postoperative examination. So, urodynamic studies were done in these cases and their urodynamic parameters were found to be improved on 6 months of follow-up. These 27.3% of patients suffered from neurogenic bladder since childhood and because of chronicity of the symptoms, the expectant outcome could not be achieved.

Guerra et al²⁴ found 7% decrease in bladder overactivity in 50% of their patients and increase of 43% in bladder capacity. Khoury et al¹⁰ showed 72% improvement in urinary incontinence and 59% reduction in bladder overactivity. Palmer et al¹¹ reported improvement in bladder capacity in only six (30%) of their patients. Kumar et al²⁵ found decrease in bladder compliance in one-third of their patients and improvement in Post Void Residual (PVR) in one-third of their patients. Palmer et al¹¹ also found decrease in compliance in some of their patients. Fone et al²⁶ found no change in compliance. Elmesallamy²⁷ reported the 73% improvement in urodynamic studies after detethering. The utility of urodynamic studies in assessing the bladder function on preoperative and postoperative periods is invaluable and accuracy of these studies is more when compared with renal ultrasound and serial cystometrography.

In present study, more than 85% patients had improvement in their pain. Yamada et al reported improvement in pain and motor functions in all patients in their series, but they only included those with a tethered cord caused by a fibrous or lipomatous filum terminale.⁶ Pang and Wilberger reported that a majority of patients were free of pain following surgery.²² Iskandar et al found improvement in pain status in over 80% of their patients.²⁸

In our study, asymmetric weakness was improved in all patients as assessed by manual muscle testing. The bulk of the muscle was also improved as they grew up, and returned to full activity. Gait was improved significantly. Schoenmakers et al⁹ showed stable lower extremity strength in 82% and improvement in only 7% of their patients.

In our study, more than 70% patients had improvement in sensory dysfunction. The improvement was better in children when compared with adults. Once the sensations were improved in lower extremity, trophic ulcers healed in all patients. Neuro-orthopaedic syndrome showed least response following detethering (only in 37.5% patients). Usually, we recommend detethering prior to orthopaedic corrective procedures, especially in scoliosis and limb length discrepancy. A corrective orthopaedic procedure without prior release of tethered cord will not prevent further orthopaedic deformity.

On the basis of NFS, preoperative and postoperative comparison was done by statistical analysis using chi-squared system. Through this analysis, chi-squared value was 25.9993 and *p*-value was 0.000032, which was <0.05, showing high significance. This highly significant statistical analysis suggests detethering even in delayed presentation or neglected cases of TCS.

On comparison with other similar studies (► **Table 4**), rate of symptomatic improvement was better in our study. Reason behind this good outcome may be early detethering after presentation, before development of irreversible changes. Selection of cases, good surgical skills, adequate postoperative physiotherapy, and regular and long follow-up may be other reasons. Despite of all these, a study with a greater number of cases of TCS is needed to strengthen our results.

Table 4 Comparison of postoperative improvement in various studies

Various manifestations	Present study	Garg k et al 2014 ¹⁴	Quiñones-Hinojosa et al 2004 ²⁹	Lee et al 2006 ⁵	Iskander et al 1998 ²⁸	Garcés-Ambrossi et al 2009 ³⁰
Back pain	80% better	83% better	63% better	78% better	81% better	81% better
Sensory symptoms	71% better	–	50% better	45% better	–	79% better
Motor weakness	91% better	78% better	50% better	64% better	48% better	69% better
Bladder dysfunctions	73% better	50% better	60% better	50% better	61% better	47% better

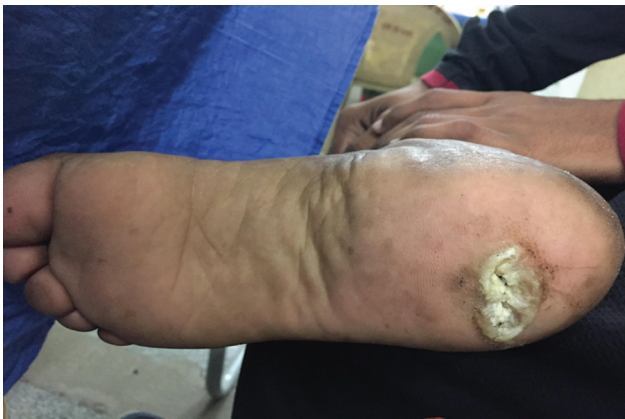

Fig. 1 Trophic ulcer—sensory symptom of tethered cord syndrome.

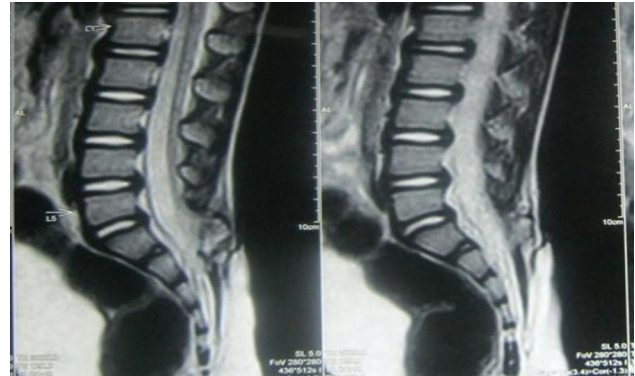


Fig. 2 Radiological (magnetic resonance imaging) image of tethering of cord to dermal elements at lumbosacral level.

Conclusion

TCS is a disease of childhood, but sometimes it can be seen in adults also. Detethering in early ages is already proven with good results. In our study, detethering showed statistically

significant improvement even in delayed presentation. So, authors recommend to surgically interfere by detethering, even if tethering is detected late with significant deficits.

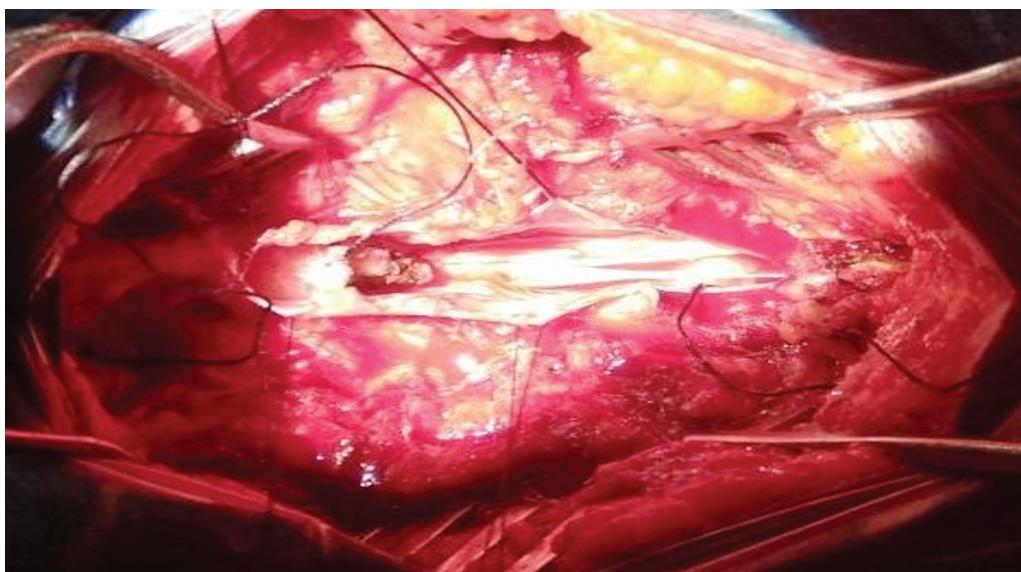


Fig. 3 Intraoperative image of thickened filum terminale.

Conflict of Interest

None declared.

References

- 1 Filippidis AS, Kalani MY, Theodore N, ReKate HL. Spinal cord traction, vascular compromise, hypoxia, and metabolic derangements in the pathophysiology of tethered cord syndrome. *Neurosurg Focus* 2010;29(01):E9
- 2 Tani S, Yamada S, Knighton RS. Extensibility of the lumbar and sacral cord. Pathophysiology of the tethered spinal cord in cats. *J Neurosurg* 1987;66(01):116–123
- 3 Cornips EM, Vereijken IM, Beuls EA, et al. Clinical characteristics and surgical outcome in 25 cases of childhood tight filum syndrome. *Eur J Paediatr Neurol* 2012;16(02):103–117
- 4 Fitz CR, Harwood-Nash DC. The tethered conus. *AJR Am J Roentgenol* 1975;125(03):515–523
- 5 Lee GY, Paradiso G, Tator CH, Gentili F, Massicotte EM, Fehlings MG. Surgical management of tethered cord syndrome in adults: indications, techniques, and long-term outcomes in 60 patients. *J Neurosurg Spine* 2006;4(02):123–131
- 6 Yamada S, Siddiqi J, Won DJ, et al. Symptomatic protocols for adult tethered cord syndrome. *Neurol Res* 2004;26(07):741–744
- 7 Kondo A, Kato K, Kanai S, Sakakibara T. Bladder dysfunction secondary to tethered cord syndrome in adults: is it curable? *J Urol* 1986;135(02):313–316
- 8 De Gennaro M, Lais A, Fariello G, et al. Early diagnosis and treatment of spinal dysraphism to prevent urinary incontinence. *Eur Urol* 1991;20(02):140–145
- 9 Nogueira M, Greenfield SP, Wan J, Santana A, Li V. Tethered cord in children: a clinical classification with urodynamic correlation. *J Urol* 2004;172(4 Pt 2):1677–1680, discussion 1680
- 10 Khoury AE, Hendrick EB, McLorie GA, Kulkarni A, Churchill BM. Occult spinal dysraphism: clinical and urodynamic outcome after division of the filum terminale. *J Urol* 1990;144(2 Pt 2):426–428, discussion 428–429, 443–444
- 11 Palmer LS, Richards I, Kaplan WE. Subclinical changes in bladder function in children presenting with nonurological symptoms of the tethered cord syndrome. *J Urol* 1998;159(01):231–234
- 12 Garceau GJ. The filum terminale syndrome (the cord-traction syndrome). *J Bone Joint Surg Am* 1953;35-A(03):711–716
- 13 Hsieh MH, Perry V, Gupta N, Pearson C, Nguyen HT. The effects of detethering on the urodynamics profile in children with a tethered cord. *J Neurosurg* 2006;105(5, Suppl):391–395
- 14 Garg K, Tandon V, Kumar R, Sharma BS, Mahapatra AK. Management of adult tethered cord syndrome: our experience and review of literature. *Neurol India* 2014;62(02):137–143
- 15 Bowman RM, Mohan A, Ito J, Seibly JM, McLone DG. Tethered cord release: a long-term study in 114 patients. *J Neurosurg Pediatr* 2009;3(03):181–187
- 16 Drennan JC. Spina bifida occulta: orthopaedic, radiological and neurosurgical aspects. *JBJS* 1982;64(03):478
- 17 Khoshhal KI, Murshid WR, Elgamal EA, Salih MA. Tethered cord syndrome: a study of 35 patients. *J Taibah Univ Med Sci* 2012;7(01):23–28
- 18 Vepakomma D, Kumar N, Alladi A. Tethered cord syndrome-role of early surgery. *J Indian Assoc Pediatr Surg* 2019;24(02):124–128
- 19 Al-Mefty O, Kandzari S, Fox JL. Neurogenic bladder and the tethered spinal cord syndrome. *J Urol* 1979;122(01):112–115
- 20 Kaplan WE, McLone DG, Richards I. The urological manifestations of the tethered spinal cord. *J Urol* 1988;140(5 Pt 2):1285–1288
- 21 Klekamp J. Tethered cord syndrome in adults. *J Neurosurg Spine* 2011;15(03):258–270
- 22 Pang D, Wilberger JE Jr. Tethered cord syndrome in adults. *J Neurosurg* 1982;57(01):32–47
- 23 Haro H, Komori H, Okawa A, Kawabata S, Shinomiya K. Long-term outcomes of surgical treatment for tethered cord syndrome. *J Spinal Disord Tech* 2004;17(01):16–20
- 24 Guerra LA, Pike J, Milks J, Barrowman N, Leonard M. Outcome in patients who underwent tethered cord release for occult spinal dysraphism. *J Urol* 2006;176(4 Pt 2):1729–1732
- 25 Kumar R, Singhal N, Gupta M, Kapoor R, Mahapatra AK. Evaluation of clinico-urodynamic outcome of bladder dysfunction after surgery in children with spinal dysraphism - a prospective study. *Acta Neurochir (Wien)* 2008;150(02):129–137
- 26 Fone PD, Vapnek JM, Litwiller SE, et al. Urodynamic findings in the tethered spinal cord syndrome: does surgical release improve bladder function? *J Urol* 1997;157(02):604–609
- 27 Elmesallamy W, AbdAlwanis A, Mohamed S. Tethered cord syndrome: surgical outcome of 43 cases and review of literatures. *Egypt J Neurosurg* 2019;34(01):1–9
- 28 Iskandar BJ, Fulmer BB, Hadley MN, Oakes WJ. Congenital tethered spinal cord syndrome in adults. *J Neurosurg* 1998;88(06):958–961
- 29 Quiñones-Hinojosa A, Gadkary CA, Gulati M, et al. Neurophysiological monitoring for safe surgical tethered cord syndrome release in adults. *Surg Neurol* 2004;62(02):127–133, discussion 133–135
- 30 Garcés-Ambrossi GL, McGirt MJ, Samuels R, et al. Neurological outcome after surgical management of adult tethered cord syndrome. *J Neurosurg Spine* 2009;11(03):304–309