Article published online: 2024-03-27

Unusual Cause of Hemobilia

Majid Khalil Rather[1] Nisar A. Shah[2] Mohamad Muzafar Mir[1] Asif Iqbal Shah[1] Showkat Ahmad Kadla[1]

[1] Department of Gastroenterology, GMC, Srinagar, J&K, India
[2] Department of Medicine and Gastroenterology, GMC, Srinagar, J&K, India

J Digest Endosc

Address for correspondence Nisar Ahmad Shah, DM, Consultant Department of Medicine and Gastroenterology, Govt. Medical college, Srinagar, J&K 190011, India (e-mail: nisarshah19@gmail.com).

Abstract

Hemobilia is one of the rare causes of upper gastrointestinal (GI) bleeding. Causes of hemobilia vary from benign lesions, malignant tumors, to vascular causes. Rupture of a hepatic artery aneurysm into common bile duct is rarely encountered in clinical practice, and sometimes can be very tricky to diagnose if the clinician is not aware of this cause of GI bleeding. We diagnosed a young female who has had a recent gallbladder surgery and presented with a massive upper GI bleeding. She was managed with coil embolization of the right hepatic artery.

Keywords
- hemobilia
- hepatic artery aneurysm
- cholecystectomy
- coil embolization

Introduction

Hepatic artery aneurysms account for nearly one-fifth of all visceral artery aneurysms.[1] The incidence of hepatic artery aneurysm has been on the rise due to the increasing numbers of imaging studies and hepatobiliary procedures being performed. The classical presentation of Quincke's triad, comprising abdominal pain, obstructive jaundice, and hemobilia, has been reported in only one-third of the cases.[2] While the vast majority of cases remain asymptomatic, those who present clinically are the ones which rupture having a mortality of around 40%.[3]

Visceral artery aneurysms are uncommon but significant vascular lesions. More than 2,500 cases of visceral artery aneurysms have been published; the most commonly involved vessels are the splenic (60%), hepatic (20%), superior mesenteric (5.5%), celiac (4%), and gastroduodenal arteries.[4] Bleedings from the biliary tract usually play a minor role in the differential diagnosis of upper gastrointestinal bleedings. The causes for hemobilia vary from trauma, neoplastic transformations, vascular malformation, and iatrogenic causes.[5] Postoperative bleedings from the biliary tract after a cholecystectomy have been reported for both laparoscopic and open surgery.[6,7] We report a case of right hepatic artery pseudoaneurysm after open cholecystectomy successfully treated by transarterial coil embolization.

Case Presentation

A 30-year-old female underlying hypothyroidism with a history of open cholecystectomy 3 weeks back presented to hospital with multiple episodes of melena and one episode of hematemesis. On examination, patient was conscious, oriented to time place and person, hemodynamically stable with investigation revealing hemoglobin of 8.8, total leucocyte count of 6.1, platelet of 248, hematocrit of 27, mean corpuscular volume of 89, and mean corpuscular hemoglobin of 28.

Kidney function, liver function, and coagulation were normal.

Patient underwent an upper gastrointestinal endoscopy within 6 hours of bleeding, showing blood in second part of duodenum; however, no lesion could be seen. Side-view duodenoscopy was done few hours later that showed normal papilla with no blood in duodenum.

Patient was kept under observation overnight. However, the patient again developed multiple episodes of melena overnight with significant drop in blood pressure. Hemoglobin dropped from 8.8 to 5.5 gm/dL and patient required five units of blood transfusion. Repeat esophagogastroduodenoscopy was done the next day showing fresh blood in second part of duodenum and blood seen coming out of papilla and an impression of hemobilia was made.

DOI https://doi.org/10.1055/s-0044-1785224.
ISSN 0976-5042.

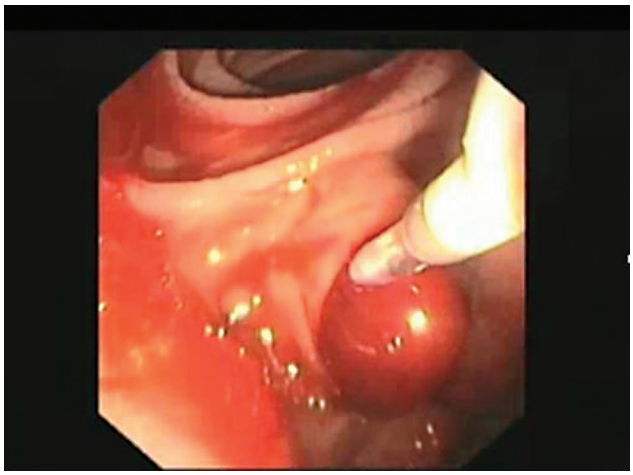

Fig. 1 Blood and clots across papilla.

Patient was subjected to endoscopic retrograde cholangiopancreatography with cholangiogram showing common bile duct filling defect with small communicating cavity with right hepatic duct like pseudoaneurysm. Papillotomy was done and lots of clots came out (►**Fig. 1**). Patient underwent computed tomography angiogram that revealed right hepatic artery pseudoaneurysm (►**Fig. 2**). Following this patient underwent radiological intervention with coil embolization of the right hepatic artery (►**Figs. 3** and **4**) and was discharged from hospital in the next 2 days.

Discussion

Hemobilia occurs in 2.5% of accidental hepatic traumas and in 3 to 7% of incidental hepatic traumas, and its onset may be observed several months after the trauma.[8]

In the past decades, the development of pseudoaneurysms after cholecystectomy has only been described in case reports or smaller case series.[9] The precise pathogenesis, underlying the development of postoperative pseudoaneurysms, is unclear. Mechanical or thermal injuries probably are the main factors.[10] Furthermore, the cytotoxic character of bile acids might cause vascular damage after a bile leak.[11] There are several case reports with a symptomatic manifestation of the pseudoaneurysm only 1 to 2 weeks after a laparoscopic cholecystectomy for acute cholecystitis. In these cases, the inflammatory process presumably plays a major role as an additional etiological factor.[12] Laparoscopic cholecystectomy is associated with increased incidence of

Fig. 3 Coil being introduced into right hepatic artery.

Fig. 2 Computed tomography angiogram revealing right hepatic artery pseudoaneurysm.

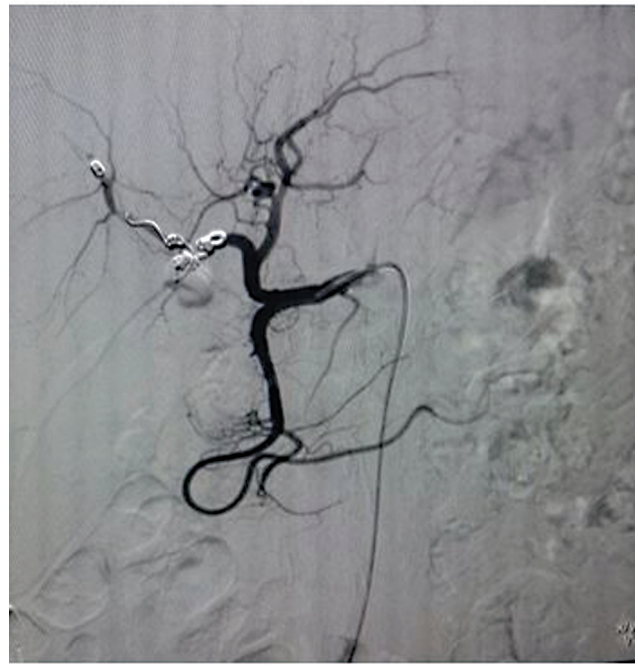

Fig. 4 Embolized pseudoaneurysm and right hepatic artery.

biliary as well as vascular injuries. Biliary injuries occur in around 0.2 to 1% of cases with 10-fold increase as compared to open cholecystectomy, while vascular complication occur in 0.25 to 0.5% of cases.[13]

Currently, selective arterial embolization constitutes the treatment of choice with a cure rate above 90%, and is associated with lower morbidity and mortality as compared with surgical treatment that should be reserved for those cases where embolization fails to succeed.[8,14,15] Nowadays, there is a wide availability of embolic agents such as detachable balloons, coils, polyvinyl alcohol particles, and *n*-butyl cyanoacrylate.[16] Gelfoam is a nonexpensive, easily available, and absorbable gelatin powder. Coils allow a greater accuracy, but they make the procedure more expensive. Complications from arterial embolization include hepatic infarction, gallbladder necrosis, gastrointestinal bleeding, acute pancreatitis, and are related to the incorrect selection of embolic agents and inappropriate utilization of the super selective embolization technique.[16]

Conclusion

Pseudoaneurysmal bleedings as a complication after cholecystectomy (open or laparoscopic) is a rare possibility and should be kept in mind. Latency time until manifestation of the first symptoms can be days to weeks after the surgery. Embolization is the treatment of choice with success rates of approximately 85%.

Conflict of Interest

None declared.

References

1 Suárez-Grau JM, Rubio-Chaves C, Pareja-Ciuró F, Gómez-Bravo MA, Diez-Canedo JS, García-González I. [Obstructive jaundice secondary to hepatic artery aneurysm]. Cir Cir 2008;76(03):253–256

2 Bronstein J, Cohen J, Sehgal S, Kolasinski S. Hepatic artery aneurysm: an unusual case of biliary obstruction. Vasc Med 2010;15 (01):75–77

3 Abbas MA, Fowl RJ, Stone WM, et al. Hepatic artery aneurysm: factors that predict complications. J Vasc Surg 2003;38(01):41–45

4 Sessa C, Tinelli G, Porcu P, Aubert A, Thony F, Magne JL. Treatment of visceral artery aneurysms: description of a retrospective series of 42 aneurysms in 34 patients. Ann Vasc Surg 2004;18(06): 695–703

5 Merrell SW, Schneider PD. Hemobilia–evolution of current diagnosis and treatment. West J Med 1991;155(06):621–625

6 Green MH, Duell RM, Johnson CD, Jamieson NV. Haemobilia. Br J Surg 2001;88(06):773–786

7 Madariaga JR, Dodson SF, Selby R, Todo S, Iwatsuki S, Starzl TE. Corrective treatment and anatomic considerations for laparoscopic cholecystectomy injuries. J Am Coll Surg 1994;179(03): 321–325

8 Wani NA, Gojwari TA, Khan NA, Kosar TL. Hemobilia in a child due to right hepatic artery pseudoaneurysm: multidetector-row computed tomography demonstration. Saudi J Gastroenterol 2011;17 (02):152–154

9 Dobbins JM, Rao PM, Novelline RA. Posttraumatic hemobilia. Emerg Radiol 1997;4:180–183

10 Madanur MA, Battula N, Sethi H, Deshpande R, Heaton N, Rela M. Pseudoaneurysm following laparoscopic cholecystectomy. Hepatobiliary Pancreat Dis Int 2007;6(03):294–298

11 Hofmann AF. Bile acids: the good, the bad, and the ugly. News Physiol Sci 1999;14:24–29

12 Muehlenberg K, Löffler A. [Clip migration in the common bile duct and consecutive calculus formation after laparoscopic cholecystectomy]. Z Gastroenterol 1995;33(02):108–111

13 Connor S, Garden OJ. Bile duct injury in the era of laparoscopic cholecystectomy. Br J Surg 2006;93(02):158–168

14 López AC, Villar JM, Álvarez-Arenas IB, et al. Hemobilia: a rare cause of massive gastrointestinal bleeding. Cir Esp 2007; 82:368–372

15 Shapira Z, Lavy R, Altshuler A, Peer A, Copel L, Halevy A. Hemobilia as a presenting sign of hepatic artery to portal vein fistula caused by percutaneous transhepatic biliary drainage. Isr Med Assoc J 2011;13(01):64–65

16 Xu ZB, Zhou XY, Peng ZY, Xu SL, Ruan LX. Evaluation of selective hepatic angiography and embolization in patients with massive hemobilia. Hepatobiliary Pancreat Dis Int 2005;4(02):254–258

