





Reconstructive Head and Neck Microsurgery in a High-Volume Cancer Center—Long-Term Impact of an Early Experience

Bipin T. Varghese¹ Shaji Thomas¹ Sourabh Arora² Preethi George³ Iype EM¹ Balagopal PG¹
Aniraj R.⁴ Vijayakumar P.⁵ Deepthi Simon⁴ Amrita Rao⁶

¹Head and Neck Surgery, Department of Surgical Services, Regional Cancer Centre, Thiruvananthapuram, Kerala, India

²Max Super Specialty Hospital, New Delhi, India

³Department of Epidemiology and Biostatistics, Regional Cancer Centre, Thiruvananthapuram, Kerala, India

⁴Govt Dental and Medical Colleges, Thiruvananthapuram, Kerala, India

⁵S. P. Fort Hospital, Thiruvananthapuram, Kerala, India

⁶Kerala Institute of Medical Sciences, Thiruvananthapuram, Kerala, India

Address for correspondence Bipin T. Varghese, MS, DNB, MCh, PhD, Head and Neck Surgery, Division of Surgical Services, Regional Cancer Centre, Thiruvananthapuram 695011, Kerala, India (e-mail: bipintv@gmail.com).

South Asian J Cancer

Abstract



Bipin T. Varghese

Objectives The aim of this study was to evaluate a 16-year-long outcome of an evolving practical approach to reconstructive microsurgery in a high volume, resource-constrained, head and neck cancer care setting.

Patients and Methods Seventy-three consecutive cases of free flap reconstruction done by the Head and Neck Surgical Oncology team of Regional Cancer Centre, Thiruvananthapuram, from October 2004 to May 2020 were prospectively studied for flap viability, cosmesis, morbidity, and oncologic safety. The cases were selected based on their “emphatic” superiority to the conventional alternative as determined by two or more surgeons of the head and neck team or the recommendations of the head and neck tumor board.

Results With the long-term results, this article discusses and validates our strategy for controlled patient recruitment for reconstructive microsurgery to ensure the best resource utilization in a tertiary cancer care center.

Conclusions Adequate training and optimal application are the key factors determining success in microvascular reconstructive surgery in resource-constrained, high-volume cancer care facilities.

Keywords

- ▶ head and neck cancer
- ▶ highly restricted reconstructive microsurgery
- ▶ high volume
- ▶ tertiary cancer center

DOI <https://doi.org/10.1055/s-0044-1785445> ISSN 2278-330X

How to cite this article: Varghese BT, Thomas S, Arora S, et al. Reconstructive Head and Neck Microsurgery in a High-Volume Cancer Center—Long-Term Impact of an Early Experience. *South Asian J Cancer* 2024;00(00):00–00.

© 2024. MedIntel Services Pvt Ltd. All rights reserved.

This is an open access article published by Thieme under the terms of the Creative Commons Attribution-NonDerivative-NonCommercial-License, permitting copying and reproduction so long as the original work is given appropriate credit. Contents may not be used for commercial purposes, or adapted, remixed, transformed or built upon. (<https://creativecommons.org/licenses/by-nc-nd/4.0/>)

Thieme Medical and Scientific Publishers Pvt. Ltd., A-12, 2nd Floor, Sector 2, Noida-201301 UP, India

Introduction

Free flap reconstruction is state of the art in oncologic head and neck reconstruction, and in most of the advanced cancer centers, it is done by a separate dedicated team of reconstructive microsurgeons.¹ However, it is not cost-effective in a high volume, limited resource setup with a scarcity of trained hands where the practice of reconstructive microsurgery is occasional. With generous intramural and extramural support for training and infrastructure development, the author and colleagues have optimally supplemented reconstructive microsurgery to the conventional, cost-effective armamentarium of head and neck reconstructions in their center. Analysis of a consecutive case series of the 73 free flaps done over 16 years is presented, and the salient features of the (highly restricted) reconstructive microsurgery program are discussed.

This study emphasizes that even with the continued use of the traditional workhorse—pectoralis major myocutaneous (PMMC) flap and the emerging usage of carefully harvested, pedicled, local and regional skin, mucosal and myo-mucosal island to save operating time and resources,^{2–6} pragmatic free flap reconstruction is feasible in a high-volume, low-resource cancer center, provided the case selection and resource utilization is optimal.

Aim

The aim of this study was to prospectively evaluate the strategy of a highly controlled head and neck free flap recruitment program at a high-volume cancer center for its long-term cosmetic and functional benefits and oncologic impact.

Patients and Methods

Seventy-three consecutive cases of oncologic head and neck ablative surgery and microvascular reconstructions at the regional cancer center between October 2004 and May 2020 were studied for flap viability, cosmesis, function (speech and swallowing), locoregional recurrence, and survival. Free flap reconstruction was planned in all these cases either because it was the only available option or far superior to the conventional alternative. The decision was based on the consensus between two or more surgeons of the head and neck team or the recommendations of the head and neck tumor board.

Demographic data and the reconstruction details were entered prospectively into a proforma and regularly updated during the patient's follow-up visits. The entire data was then transferred into a Microsoft Excel sheet for analysis. The institutional review board approved the study, and an interim analysis of the flap success rate was done after the first 35 cases and the accrual continued to generate data for survival estimation and propensity-matched comparisons of outcomes with conventional alternatives.

Results

There were 48 male and 25 female patients, the ages of whom ranged from 13 to 75 years with a mean \pm standard deviation (SD) of 45 ± 14 years, who were followed up for a duration ranging from 6 to 180 months with a median follow-up of 79 months. Fifty-two cases were squamous cell carcinomas, three were soft tissue sarcomas, one was intraosseous carcinoma, one was chondrosarcoma, ten were osteosarcomas, five were recurrent ameloblastomas, and one was a recurrent basal cell carcinoma. **Table 1** shows the site

Table 1 Demographics of the patient, tumor, and surgical treatment

Site	Nos	Stage	Nos	Primary resection	Nos	Neck dissection	Nos
Tongue	26	T2 N0	05	Wide excision (lip tongue upper alveolus (UA), BM, palate)	32	Level 1a and b	13
Mandibular arch	07	T2 N1	01	Wide excision with marginal mandibulectomy	04	Level 1,2,&3	16
Lateral mandible	21	T3 N0	13	Wide excision with segmental/hemimandibulectomy	10	Level 1,2,3,&4	20
Buccal mucosa/skin	10	T4 N0	31	Wide excision with central segmental mandibulectomy	04	FND	07
Lip commissure and UA	04	T4a N2a	1	Lateral segmental mandibulectomy	08	Level 1b clearance	11
Soft palate	01	T4a N2b	1	Central segmental mandibulectomy	03	ESOND	05
Maxilla	02	Others	21	Full-thickness wide excision (without bone)	04	Neck dissection not done	01
Orbit	01			Full-thickness wide excision (with marginal/segmental mandibulectomy)	06		
Retromolar trigone	01			Skin excision (cover only)/midface maxilla	02		

Abbreviations: BM, buccal mucosa; ESOND, extended supraomohyoid neck dissection; FND, functional neck dissection.

Table 2 Flap demographics, pharmacological agents used, and outcomes

Flap		Donor vessels		Artery versus venous ratio	Numbers/failures	Pharmacological agent used		Special considerations		Distribution of failures	
ALT	10	DLCF	10	1:1	56/6	Heparin infusion	7	Additional perforator anastomosed	2	ALT	2
FF	26	PAV	26	1:2	17/1	Heparin irrigation with bolus	2	Opposite vessel anastomosis	2	FF	0
RAFFF	37					Heparin and Lomodex	1	PNI	1	RAFFF	5
		RAV	2			Lomodex and bolus heparin	5	Postchemotherapy	3	Age > 50 years Vessel depletion	3 3
		RC	35			Lomodex	27	Postoperative chemotherapy	3		

Abbreviations: ALT, anterolateral thigh; DLCF, descending branch of lateral circumflex femoral; FF, free fibular; PAV, peroneal artery and vein; PNI, perineural invasion; RAFFF, radial artery forearm free flap; RAV, radial artery and vein Anastomosis, RC, radial artery and cephalic vein.

distribution of the cases studied and the flap chosen for reconstruction, and **Table 2** shows the frequency distribution of the type of neck dissections done. Thirty-seven cases were radial forearm free flaps, 10 were anterolateral thigh (ALT) flaps, and 26 were free fibular flaps, 14 of which were osteocutaneous. Free fibular flap showed the highest success rate (100%), followed by radial forearm (86.5%) and ALT (80%). However, the skin island of one of the osteocutaneous fibulas (used for the arch of the mandible reconstruction) went in for late necrosis, which was immediately replaced by a nasolabial flap. Except for those patients who had undergone neck dissection as part of previous surgery or those with ameloblastoma or soft tissue sarcomas, all the patients underwent neck dissection or at least a level Ib clearance along with the wide excision of the primary lesion. Facial vessels were recipients in all the cases, and in four vessel depleted ipsilateral necks, the opposite facial vessels were used for the microvascular anastomosis. However, only two (40%) out of those five cases who had undergone re-exploration and redo anastomosis were successful. The follow-up period ranged from 7 to 180 months, with a mean of 53 months and a median of 24 months. The operating time went from 4 to 16 hours with a mean of 8 hours \pm SD of \pm 2 hours. Sixty-six cases were uneventful, and seven flaps failed, placing our current microvascular reconstruction success rate at 90.4%. This included two cases of late failures after the 5th postoperative day and two early losses that could not be salvaged despite re-explorations. One patient had a no-flow phenomenon despite repeated redos, and the flap was excised on the table. Primary closure of the tongue defect was done to prevent any morbidity related to flap failure. We experienced a similar dilemma during two repeated re-explorations for a failing anteromedial thigh (AMT) flap, which was effectively salvaged with a deltopectoral flap.³ The flap was planned to be raised as an ALT, but it was changed to that of an AMT because of aberrant perforators. In one patient with late failure of the flap, a decision was taken against re-exploration, and the flap was excised

for a planned late reconstruction of the residual defect. One patient was re-explored after 16 hours, that is, on the 1st postoperative day. The flap could be salvaged after excising the thrombosed superficial venous system entirely and using the deep vein (venae comitantes of radial artery) for the reanastomosis after the arterial anastomosis was found to be intact by confirming the flow at distal end.

In the first seven cases, we used continuous heparin—low molecular weight dextran (Lomodex) drip (5000 IU of heparin in 500 ml of Lomodex normal saline) at the rate of 20 microdrops per minute) for 5 days; however, this practice was discontinued, and for the subsequent two cases, we did not use any pharmacological agents. We further refined this strategy by using plain Lomodex saline drip for the first 5 days till we did the 42nd case, after which the practice of routine use of pharmacological agents was discontinued altogether and reserved for post-re-exploration cases only. Heparin in saline (9 cases), papaverine (6 cases), lignocaine (32 cases), and nifedipine (5 cases) were used as additional aid to prepare the vessels for anastomosis. None of these patients required prophylactic tracheostomy, avoidance of which is a practice that we routinely follow for conventional flaps. The size of the skin paddle ranged from 3 \times 3 cm to 10 \times 6 cm, with a mean \pm SD size of 5 \times 4 cm \pm 1.4 \times 1 cm, and the bone segment of free fibula ranged from 6 to 11 cm with an average of 4.5 cm and SD of 2.2 cm. Until the 41st case, we tried to save the ischemia time by performing as much flap crafting as possible before detaching the pedicle for the flaps transfer to the recipient area (**Fig. 1**), after which it was discontinued as more trained hands joined the program. Among the first 21 successful free fibular transfers, 11 of which were those of central mandibular defects; there were three instances of anomalous skin perforators, and in all of them, careful intraoperative decisions to reroute the perforator(s) or supercharge the skin island or as a last resort to opt for a contralateral harvest instead of proceeding with the same side were taken.⁷ In one patient with a recurrence in the remnant native mandible, a second fibular flap reconstruction was done.

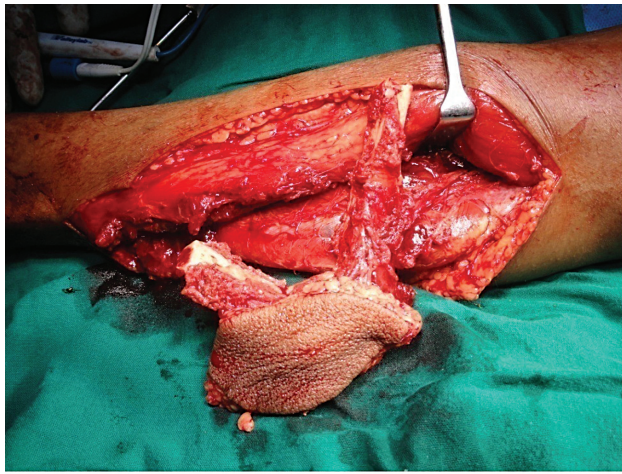


Fig. 1 Free flap crafting before pedicle detachment.

► **Tables 1 and 2** show the patient, tumor and flap demographics, salvage steps undertaken, and outcomes. ► **Figs. 2 and 3** show the yearly flap frequency and long-term overall survival trends. Two patients with tongue cancers and one patient with retromolar trigone cancer were salvaged by delayed primary closure of the defect. One patient was rehabilitated with a prosthesis, and one patient refused further reconstruction. Two patients among the flap failures developed recurrence while on follow-up with the healed residual defect. Twenty-four patients were alive without the disease, three were alive with the disease, and eight were dead due to disease at the time of completion of the first 7 years of accrual and an interim analysis for its first presentation at an international meeting. Three patients had locoregional disease recurrence, and two had distant metastasis. One patient developed a metachronous second primary, which was salvaged by surgical resection.

The donor site scars of all the patients were uncomplicated and acceptable. After a further follow-up of 9 years of the interim cohort of the cases selected during the first 7 years of reconstructive microsurgery, during which more cases were added on, the survival rates estimated by Kaplan–Meier method were comparable to our historical estimates with conventional/alternate forms of reconstruction and the experience with submental artery island flaps.^{3–6} Over the same period, our free flap failure rates with the subsequent cases have come down drastically (almost to the tune of < 1%), and the conventional options have further diversified with the advent of island nasolabial flaps, facial artery myomucosal flaps, Infrahyoid island flaps, and the supraclavicular island flaps.^{4,5} Since the case selection was controlled and stringent among the free flaps, there were no lasting swallowing or significant speech impairment. ► **Table 3** shows the absolute figures for cosmetic and functional benefits, mandibular preservation and restoration, tracheostomy avoidance, swallowing, and shoulder dysfunction. The most significant observation in this study was the superiority of free fibular reconstruction of mandibular defects in tracheostomy avoidance and preservation of swallowing and shoulder function, followed by the potential for mandibular preservation and restoration in advanced cases, which would not have been possible if a PMMC flap reconstruction was considered. Shoulder morbidity is yet another disadvantage of a PMMC reconstruction. Although there were seven flap failures, our recruitment and perioperative management strategies ensured that none of the cases had lasting morbidity.

Average operative time was 9.3 hours (range: 5 to 15 hours; preoperative hemoglobin was in the range of 10 to 17 g/dL and blood transfusion was required in 13 patients (18%) that included two pints of packed red cells (PRC) in three patients; one pint of PRC in four patients; 10, 17, and 35 pints in one patient each; and 2 whole blood or fresh frozen plasma in 6

2004	100%	1
2005	75%	8
2006	100%	4
2007	80%	6
2008	75%	10
2009	100%	3
2010	80%	11
2011	100%	6
2012	100%	5
2013	100%	6
2014	100%	1
2015		0
2016	100%	1
2017	100%	6
2018	100%	1
2019	100%	1
2020	100%	3

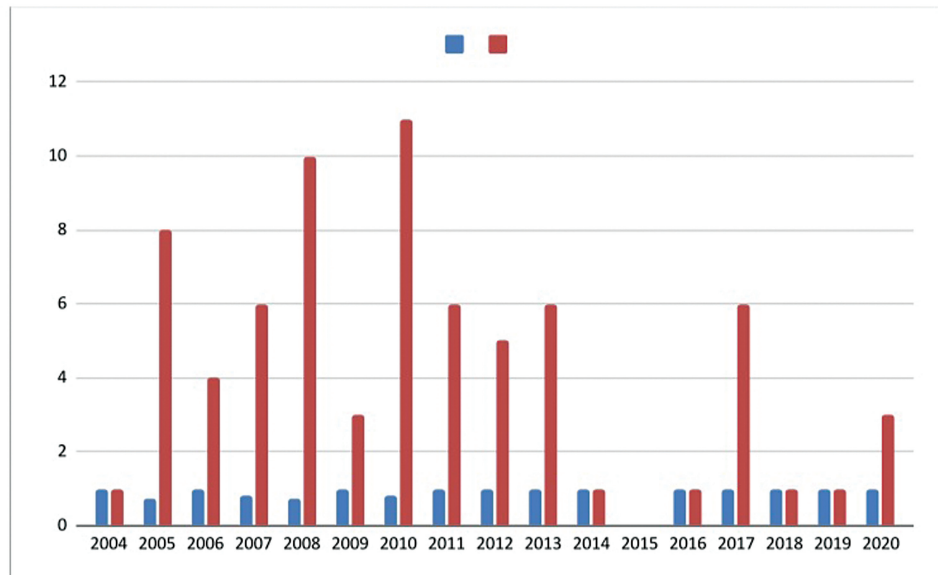


Fig. 2 Temporal trends of success rates and absolute numbers of free flaps per year.

	Censored	Dead					
	d						
Ameloblastoma	5	0					
Carcinoma	44	9					
Sarcoma	5	3					
Overall	54	12					

	Ameloblastoma		Carcinoma		Sarcoma		
Time (years)	Survival probability	SE	Survival probability	SE	Survival probability	SE	p-value
1	100	-	93.3	3.7	87.5	11.7	0.166
3	100	-	81.1	6.0	58.3	18.6	
5	100	-	78.3	6.5	58.3	18.6	

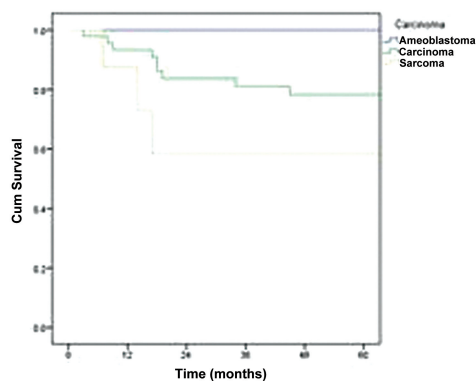


Fig. 3 Maintenance of historic survival trends among the cases studied shown by Kaplan–Meir curves. SE, standard error.

patients. The use of pharmacological agents was predominantly restricted to redo and re-exploration cases and the details of our experience are already given in the body of this article. A urine output of 30 mL was ensured for each hour for the next 48 hours after the patient was transferred to intensive care unit or ward by giving 5% dextrose, dextrose normal saline or normal saline with or without 5,000 units of heparin at the rate of 20 microdrops per minute. Elective ventilation with or without muscle relaxant was not needed in any of the cases,

but the endotracheal tube was retained with the T piece until the next day. Hospital stays ranged from 6 to 14 days with a mean \pm SD of ± 3.8 days. A preoperative Doppler study was done only among free fibula cases to rule out peroneal dominance and to mark perforators. In radial forearm flaps, we relied on the preoperative and intraoperative Allen's test. Hand-held Doppler was used in a few cases to ascertain flow in the perforators preoperatively as in all pedicled perforator-based flaps (e.g., supraclavicular island flap).

Table 3 The cosmetic and functional outcome of the reconstructed area, mandibular preservation and restoration, mitigation of swallowing, and shoulder dysfunction and avoidance of tracheostomy facilitated by the use of free flaps

Free flap (n = 73)	
Cosmetic and functional benefit	67
Mandibular preservation by myocutaneous	7
Mandibular reconstruction	26
Mandibular preservation by avoidance of access procedures	4
Swallowing and shoulder function	73
Prophylactic tracheostomy	0

Discussion

Free flaps that are generally used in head and neck oncologic reconstruction include radial artery forearm flap, ALT flap, lateral arm flap, scapular and parascapular flaps, latissimus dorsi flap, free fibula flap, deep circumflex iliac artery flap, transverse rectus abdominis muscle and myocutaneous flaps, gracilis muscle flap, jejunal and gastro-omental flaps. Three among them are the most valuable workhorses, namely the radial artery forearm flap, described by Yang et al in 1981,⁸ very often referred to as the poor man's free flap due to its ease of harvest, the free fibula flap, which is regarded as the best donatable flap, and the ALT flap. These flaps have been our mainstay in our limited practice of reconstructive microsurgery.^{3,7-11}

Within the constraints of infrastructure, we have produced the best possible outcome of reconstructive microsurgery, as this study indicates. Even those cases of flap failures did not have to endure severe morbidity because of our careful strategy of initial recruitment of patients and judicious preoperative and postoperative decisions.⁹⁻¹³ The predominant recipient vessel being the facial artery, we have constantly been checking the flow from the facial stump (to rule out spasms, atheroma, or organized thrombus), and in addition, in radial artery forearm flaps, it is our standard practice to check the arterial patency after anastomosis by opening the distal-most end of the radial artery and visualizing the arterial spurt. This has helped us in the assessment of immediate postanastomotic arterial flow in these cases and also during re-exploration wherein these maneuvers (distal radial artery flow check followed by proximal facial artery stump patency check before a redo) are done to assess (and if needed re-establish) the patency of the arterial anastomosis. This method, not described in literature hitherto, has helped us abandon the procedure and consider an immediate salvage option in one of our cases where the patient had an unexplained lack of blood flow from the facial arterial stump. We also did similar salvaging in another case found to have an early flap failure and a missed opportunity for a timely re-exploration.

We believe that avoiding end-to-side anastomosis to major vessels and prophylactic tracheostomy⁸⁻¹¹ has been instrumental in preventing any major postoperative complication and decreasing immediate and intermediate postoperative morbidity in the cases studied. Likewise, onsite crafting of the initial 42 flaps seems to have played an essential role in tiding over our learning curve. It has been our routine practice to avoid prophylactic tracheostomy for all conventional head and neck oncologic reconstruction except when a central segment of the mandible has been lost and not reconstructed, in which case, a tongue falls back and airway obstruction is more or less inevitable. With the advent of the free fibular flap, we have overcome this hurdle, too. Careful anchoring of the cut end of the geniohyoid and other muscles of the floor of the mouth to the reconstructed mandible with 1 "0" Prolene sutures prevented tongue fallback. None of the patients in the current series required prophylactic tracheostomy, and so far, we have not ventured into pharyngeal reconstructions.¹⁴

Failure of re-explorations was predominantly due to the inappropriate timing as the present microvascular facility of our institution is not available round the clock. Despite the stringent flap monitoring,^{15,16} very often, the compromise in flap circulation was picked by the nurses and residents when the operating room with the microvascular facility was engaged. Vessel depletion¹⁷ was also a probable factor in the failure of flaps, as indicated by the low (25%) success rate in cases where anastomosis was done to the opposite facial vessels. A critical observation of this study is the quicker learning curve against a published standard range of 71 to 91% at the 100th case.¹⁸ No flow phenomenon and donor or recipient vasospasm were the basis for the observed failures; the age of the patient and intrinsic anomalies in the internal vasculature of the harvested flap were other minor factors influencing the success rate of our cases. The number of veins anastomosed, and the pharmacologic adjuncts¹⁸ used were factors of insignificance. Therefore, the essential goal during microvascular anastomosis should be to bypass a "reperfusion injury" rather than to overcome it. With these discussions on the teething problems of establishing microvascular surgery in a low-resource-high-volume cancer center, it is hoped that this article would set an example for resource-constrained cancer hospitals, venturing into reconstructive microsurgery amid ever-emerging alternate reconstructive options.^{2-5,20}

Other than the central arch we did free flaps only when the expected result was deemed to be far superior to that of a conventional flap as assessed by more than one consultant surgeon in a multidisciplinary team meeting or when a conventional reconstructive option had run out. As in the case of all conventional reconstructions, the threshold of preoperative hemoglobin was kept at 10, as postchemotherapy patients were also included. Blood transfusion was unnecessary in most cases, as in our conventional reconstructions. So far, we have not started osseointegrated implants due to cost escalation and oncologic concerns (need for adjuvant radiotherapy/chemotherapy). We have not relied on reverse

mapping or three-dimensional printing for the same reasons. In the present series, there has been no significant differences in the charges between conventional and free flap reconstructions, but recently, the charges for microvascular reconstruction have been revised. From the above study, we have generated a matched pair data of head-to-head comparisons of free flap outcomes with conventional reconstructive options (cosmesis, swallowing and shoulder function and oncologic outcomes) and the comparison of quality of life of patients after free flap vis-a-vis conventional flap reconstruction is also being made.

Conclusion

- The judicious addition of three free flaps, that is, radial forearm, ALT, and fibular flaps, can improve the overall outcomes of conventional head and neck reconstruction in high-volume centers.
- The long vascular pedicle of the radial forearm flap permits the utilization of contralateral recipient vessels in vessel-depleted (ipsilateral) necks.
- Failed free flaps are salvaged more cost-effectively with conventional options (rather than second free flap) in resource-constrained high-volume settings.

With an ongoing increase in the recruitment of carefully harvested local and regional skin, mucosal and myomucosal islands on a defined vascular pedicle, the requirement for free flap reconstruction in a high-volume setting has drastically reduced. Highly controlled case selection and resource utilization, prudent morbidity restriction, adequate training, supervision, and optimal application are the key factors determining the effectiveness of “occasional” microvascular reconstructive surgery in resource-constrained cancer care facilities with heavy case load. Free flap reconstruction in a resource-constrained setting should always be done by surgeons who have crossed their learning curve in microvascular anastomosis.

Conflict of Interest

None declared.

The interim report of the study was presented at the 4th International Congress of the International Association of Oral Oncology (IAOO), Rhode Island, Greece, May 16 to 19, 2013.

Acknowledgment

The microvascular facility was established in RCC Thiruvananthapuram with the financial support of the Department of Science and Technology (DST), Government of India.

The authors also wish to thank the Union for International Cancer Control (UICC) for the International Cancer Technology Transfer ICRET grants for the workforce training and Drs. Kurian Cherian and Liz George for their assistance in capturing, compiling, and entering the data into excel software.

References

- 1 Wong CH, Wei FC. Microsurgical free flap in head and neck reconstruction. *Head Neck* 2010;32(09):1236–1245
- 2 Mallet Y, El Bedoui S, Penel N, Ton Van J, Fournier C, Lefebvre JL. The free vascularized flap and the pectoralis major pedicled flap options: comparative results of reconstruction of the tongue. *Oral Oncol* 2009;45(12):1028–1031
- 3 Varghese BT, Arora S. Immediate deltopectoral flap salvage of a failing anterolateral thigh free flap. *Oral Oncol* 2020; 100:104451
- 4 Janardhan D, George CK, Thomas S, et al. Island NLF or island FAMM flap in reconstruction of oral malignancy defects? *Indian J Surg Oncol* 2020;11(02):188–191
- 5 Thomas S, Janardhan D, Varghese BT, Patil S, Suresh S. Versatility of supraclavicular artery pedicled flap in reconstruction after laryngectomy. *Am J Otolaryngol Head Neck Surg* 2020;3(01):1084
- 6 Thomas S, Varghese BT, Ganesh SA, et al. Oncological safety of submental artery island flap in oral reconstruction - analysis of 229 cases. *Indian J Surg Oncol* 2016;7(04):420–424
- 7 Varghese BT, Vijayakumar P, Ani Raj R, Thomas S. Salvaging skin loss of free fibular osteo-cutaneous flaps in oral oncological reconstruction. *Oral Oncol* 2019;97:131–132
- 8 Soutar DS, Scheker LR, Tanner NS, McGregor IA. The radial forearm flap: a versatile method for intra-oral reconstruction. *Br J Plast Surg* 1983;36(01):1–8
- 9 Anehosur VS, Karadiguddi P, Joshi VK, Lakkundi BC, Ghosh R, Krishnan G. Elective tracheostomy in head and neck surgery: our experience. *J Clin Diagn Res* 2017;11(05):ZC36–ZC39
- 10 Divya GM, Zinia N, Balagopal PG, et al. Risk factors for post-operative complications in primary oral cancer surgery-a prospective study. *Indian J Surg Oncol* 2018;9(01):28–34PMID
- 11 Gao LL, Basta M, Kanchwala SK, Serletti JM, Low DW, Wu LC. Cost-effectiveness of microsurgical reconstruction for head and neck defects after oncologic resection. *Head Neck* 2017;39(03): 541–547
- 12 Genden EM, Rinaldo A, Suárez C, Wei WI, Bradley PJ, Ferlito A. Complications of free flap transfers for head and neck reconstruction following cancer resection. *Oral Oncol* 2004;40(10): 979–984Review
- 13 Novakovic D, Patel RS, Goldstein DP, Gullane PJ. Salvage of failed free flaps used in head and neck reconstruction. *Head Neck Oncol* 2009;1(01):33[Epubahead of print]
- 14 Sumer BD, Gastman BR, Nussenbaum B, Gao F, Haughey BH. Microvascular flap reconstruction of major pharyngeal resections with the intent of laryngeal preservation. *Arch Otolaryngol Head Neck Surg* 2009;135(08):801–806
- 15 Kudpaje A, Thankappan K, Rajan RP, et al. Outcomes of re-exploration procedures after head and neck free flap reconstruction. *Indian J Surg Oncol* 2021;12(03):530–537
- 16 Yoshimoto S, Kawabata K, Mitani H. Analysis of 59 cases with free flap thrombosis after reconstructive surgery for head and neck cancer. *Auris Nasus Larynx* 2010;37(02):205–211
- 17 Jacobson AS, Eloy JA, Park E, Roman B, Genden EM. Vessel-depleted neck: techniques for achieving microvascular reconstruction. *Head Neck* 2008;30(02):201–207
- 18 Griffin JR, Thornton JF. Microsurgery: free tissue transfer and replantation. In *Selected Readings in Plastic Surgery*. Volume 10, Number 5, Part 2. South West Baylor College; 2005 page 6.
- 19 Rinkinen J, Halvorson EG. Topical vasodilators in microsurgery: what is the evidence? *J Reconstr Microsurg* 2017;33(01):1–7
- 20 Schonauer F, Di Martino A, Nele G, Santoro M, Dell'Aversana Orabona G, Califano L. Submental flap as an alternative to microsurgical flap in intraoral post-oncological reconstruction in the elderly. *Int J Surg* 2016;33(Suppl 1):S51–S56