



Primary Renal Leiomyoma

Rashmi Joshi¹  Mayur Parkhi²  Debajyoti Chatterjee² Girdhar S. Bora³

¹ Department of Pathology, Postgraduate Institute of Medical Education and Research, Chandigarh, India

² Department of Histopathology, Postgraduate Institute of Medical Education and Research, Chandigarh, India

³ Department of Urology, Postgraduate Institute of Medical Education and Research, Chandigarh, India

Address for correspondence Debajyoti Chatterjee, MD, DM, Assistant Professor, Department of Histopathology, 5th Floor, Research Block A, Postgraduate Institute of Medical Education and Research, Chandigarh 160012, India (e-mail: devchat1984@gmail.com).

Ind J Med Paediatr Oncol

Sir,

Renal leiomyoma is a rare smooth muscle tumor accounting for 0.3% of all nephrectomies and 1.5% of all benign neoplasms.¹ They predominantly affect the female population between the second and fifth decades of life. Renal leiomyoma is predominantly asymptomatic and discovered incidentally on autopsy or when the patient is screened for some other symptoms. The most common presentations are abdominal mass, flank pain, and/or microscopic haematuria.² In the kidney, the lower pole is commonly involved. Leiomyomas are mostly subcapsular (53%) or capsular (37%), and these occur less often in the renal pelvis (10%) as these sites normally contain smooth muscles.² Macroscopically, these tumors are well circumscribed. The cut surfaces appear tan to white with a whorling pattern. Cystic degeneration is common.³ Microscopically, long interlacing fascicles of spindle cells are seen. The presence of necrosis, atypia, or mitosis warrants the diagnosis of leiomyosarcoma and is hence looked for. Clinically, the important differential diagnosis includes renal cell carcinoma (RCC) and oncocytoma. Microscopically, stromal predominant angiomyolipoma (AML) also needs exclusion through thorough tissue sampling. Immunohistochemically, the diagnosis of leiomyoma is supported by diffuse smooth muscle actin (SMA) positivity and negativity for melanocytic markers (HMB45 and/or Melan-A). Both AML and oncocytoma are benign and require nephron-sparing surgery (NSS) like leiomyoma. However, RCCs are the most common outcome of contrast-enhancing renal mass and need elaborate management.⁴ In the case of renal leiomyoma, the choice between partial and radical nephrectomy depends upon the tumor size and its location. There is no documentation of metastasis to date in the literature and most of the patients remain alive.⁵

A 56-year-old lady presented with a history of on and off right flank pain for 3 to 4 years. The pain was mild, dull

aching and subsided on oral medication. There was no history of hematuria, burning micturition, or any previous significant past medical illness. She was hypertensive for 3 years with regular medication. On evaluation, the complete hemogram and renal and liver function tests were within normal limits. Contrast-enhanced computed tomography (CECT) showed a well-defined soft-tissue lesion measuring 3.6 × 3.0 × 3.1 cm in the mid-pole cortex of the right kidney. On the noncontrast CT scan, the lesion appeared slightly hyperdense to isodense and showed plain CT attenuation of 33 to 46 HU. Furthermore, on the postcontrast scan, the lesion showed mild enhancement of up to 78 HU (maximum); however, it appeared hypodense with respect to renal parenchyma. The lesion showed a slight smooth exophytic bulge into overlying fat at the lateral aspect. Medially, the lesion appeared to merge with the mid-pole pelvicalyceal system. In addition, there was chronic calculous cholecystitis and uterine fibroid measuring 3.0 × 2.2 cm. A robot-assisted laparoscopic right NSS was performed. The specimen was sent for histopathological evaluation. Grossly, the right NSS specimen measured 4 × 3.7 × 2.5 cm. An encapsulated solid tumor was seen measuring 3.6 × 2.5 × 2.6 cm. The cut surface was homogeneous, white, and firm with a whorling texture (→ Fig. 1A). No areas of hemorrhage, necrosis, or calcification were noted. A peripheral rim of normal renal parenchyma was identified, measuring 0.3 cm. The histopathological sections showed a well-circumscribed tumor composed of smooth muscle cells arranged in long and short interlacing fascicles (→ Fig. 1B). Additionally, individual tumor cells showed a mild degree of nuclear pleomorphism with spindle-shaped morphology and a moderate amount of eosinophilic cytoplasm. The nuclei appeared cigar shaped with both blunt ends, fine chromatin, and inconspicuous nucleoli (→ Fig. 1C).

DOI <https://doi.org/10.1055/s-0044-1785455>.
ISSN 0971-5851.

© 2024. The Author(s).

This is an open access article published by Thieme under the terms of the Creative Commons Attribution License, permitting unrestricted use, distribution, and reproduction so long as the original work is properly cited. (<https://creativecommons.org/licenses/by/4.0/>)

Thieme Medical and Scientific Publishers Pvt. Ltd., A-12, 2nd Floor, Sector 2, Noida-201301 UP, India

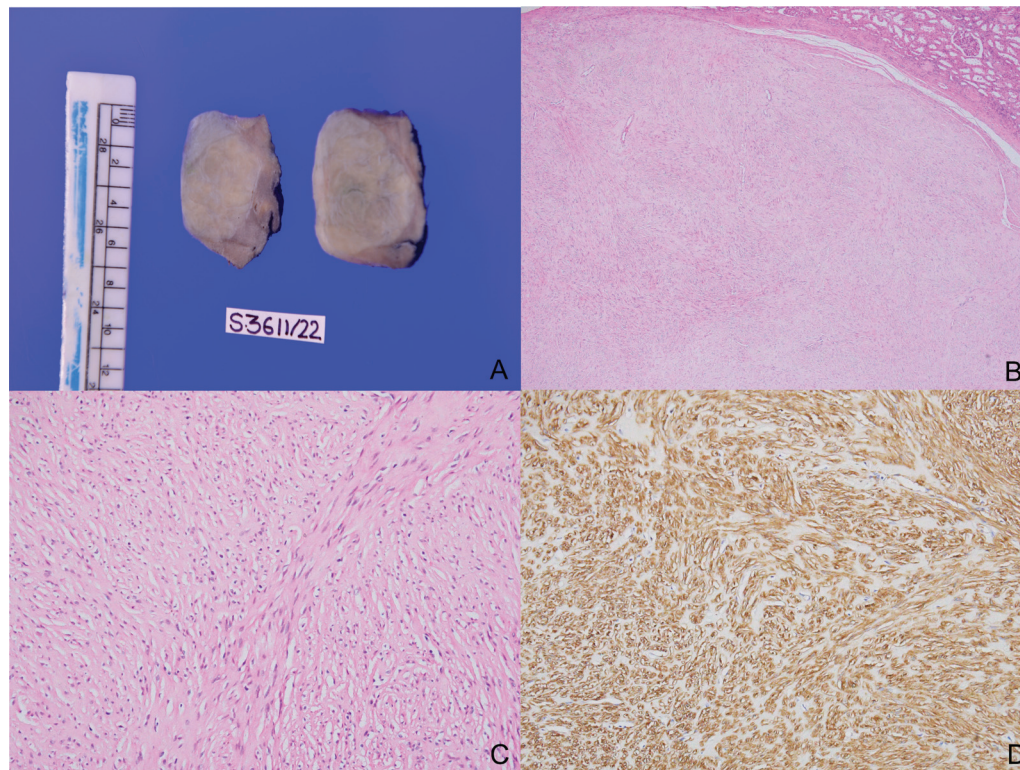


Fig. 1 (A) Gross specimen showing a well-circumscribed tumor. The tumor has tan to white color, rubbery texture, and whorled cut surface (scale bar = 2 cm). (B) The microphotograph showing a sharp demarcation from the surrounding normal renal parenchyma (hematoxylin and eosin [H&E]; $\times 100$). (C) The tumor cells are arranged in intersecting fascicles (H&E; $\times 200$). (D) Smooth muscle actin (SMA) immunohistochemistry shows diffuse strong positivity ($\times 200$).

Mitotic activity was infrequent ($<1/10$ hpf). No nuclear atypia, mitosis, or necrosis was seen. No perinephric fat extension was identified. On immunohistochemistry, the tumor cells exhibited diffuse cytoplasmic positivity for SMA (**Fig. 1D**). Melan-A immunostain was negative. The Ki-67 proliferation index was less than 1%. The surgical resection margin was not involved. In view of morphology and immunohistochemistry, a diagnosis of leiomyoma (pT1a pNx; American Joint Committee on Cancer [AJCC] staging manual, 8th edition) was made. To the best of our knowledge, the association between renal and uterine leiomyomas was not found in the English literature. The patient is doing well after the surgery, and at the 1-year follow-up, she had no recurrence.

Author Contributions

R.J. and M.P. contributed to the analysis of the pathologic findings and manuscript writing. D.C. contributed to the pathologic analysis and manuscript editing. G.S.B. collected and critically analyzed the clinical data. The manuscript has been read and approved by all the authors, the requirements for authorship have been met, and each author believes that the manuscript represents honest work.

Ethics Statement

The authors obtained written informed consent for publication from the patient, and the manuscript as per the Institutional Ethics Committee requirements.

Funding

None.

Conflict of Interest

None declared.

References

- Romero FR, Kohanim S, Lima G, Permpongkosol S, Fine SW, Kavoussi LR. Leiomyomas of the kidney: emphasis on conservative diagnosis and treatment. *Urology* 2005;66(06):1319
- Steiner M, Quinlan D, Goldman SM, et al. Leiomyoma of the kidney: presentation of 4 new cases and the role of computerized tomography. *J Urol* 1990;143(05):994–998
- Takezaki T, Nakama M, Ogawa A. Renal leiomyoma with extensive cystic degeneration. *Urology* 1985;25(04):401–403
- Frank I, Blute ML, Chevillie JC, Lohse CM, Weaver AL, Zincke H. Solid renal tumors: an analysis of pathological features related to tumor size. *J Urol* 2003;170(6, Pt 1):2217–2220
- Patil PA, McKenney JK, Trpkov K, et al. Renal leiomyoma: a contemporary multi-institution study of an infrequent and frequently misclassified neoplasm. *Am J Surg Pathol* 2015;39(03):349–356