



# Evaluation of Volumetric Changes between Pediatric Rotary Files and Manual Files during Canal Preparation of Primary Mandibular Canine: A Nano-CT Analysis

Balaji Suresh<sup>1</sup> Ganesh Jeevanandan<sup>1</sup> Vignesh Ravindran<sup>1</sup> Satish Vishwanathaiah<sup>2</sup> Suman Panda<sup>2</sup>  
Ather Ahmed Syed<sup>2</sup> Sultan Altowairqi<sup>3</sup> Aram AlShehri<sup>4,5</sup> Ali Alaqla<sup>4,5</sup> Sanjeev Khanagar<sup>5,6</sup>  
Prabhadevi Maganur<sup>2</sup>

<sup>1</sup> Department of Pediatric and Preventive Dentistry, Saveetha Dental College & Hospitals, Saveetha Institute of Medical and Technical Sciences, Chennai, Tamil Nadu, India

<sup>2</sup> Department of Preventive Dental Sciences, Division of Pediatric dentistry, College of Dentistry, Jazan University, Jazan, Saudi Arabia

<sup>3</sup> College of Dentistry, Jazan University, Jazan, Saudi Arabia

<sup>4</sup> Restorative and Prosthetic Dental Sciences Department, College of Dentistry, King Saud bin Abdulaziz University for Health Sciences, Riyadh, Saudi Arabia

<sup>5</sup> King Abdullah International Medical Research Center, National Guard Health Affairs, Riyadh, Saudi Arabia

<sup>6</sup> Department of Preventive Dental Science, College of Dentistry, King Saud Bin Abdulaziz, University for Health Sciences, Riyadh, Saudi Arabia

**Address for correspondence** Ganesh Jeevanandan, MDS, PhD, Department of Pediatric and Preventive Dentistry, Saveetha Dental College & Hospitals, Saveetha Institute of Medical and Technical Sciences, Chennai, Tamil Nadu 600077, India (e-mail: helloganz@gmail.com).

Prabhadevi Maganur, Department of Preventive dental science, Division of Pedodontics, College of dentistry, Jazan University, Jazan 45142, Saudi Arabia (e-mail: prabhadevi.maganur@gmail.com).

Eur J Gen Dent 2024;13:247–254.

## Abstract

**Objective** Pediatric endodontics has become popular due to advancements in cleaning, shaping, and irrigation systems, resulting in faster and effective removal of infected pulp, saving time, and creating a pathogen-free environment. The patented rotary file system, Kedo S, designed for primary teeth, introduced a single file generation for efficient pulp therapy. However, there are currently no studies assessing canal preparation in primary mandibular canine using nano-computed tomography (nano-CT). This study aims to evaluate the efficacy of rotary file systems (Kedo S plus, Kedo SG blue) against traditional hand files in root canal preparation of primary mandibular canines using nano-CT.

**Materials and Methods** This *in vitro* study was performed in extracted primary mandibular canine based on certain inclusion and exclusion criteria. Samples were prepared and working length was determined before the preoperative scan using a high-resolution nano-CT device (SkyScan 2214, Bruker, Kontich, Belgium). A single well-experienced pediatric dentist prepared the canals using three file systems: Kedo S plus, Kedo SG blue, and hand K-files. A postoperative scan was performed similar to preoperative scan. Image reconstruction was performed with NRecon software for three-dimensional volumetric visualization and analysis of the root canals.

**Results** Kedo S plus displayed significant alterations in volumetric, surface area, and instrumented areas postpreparation compared with Kedo SG blue and hand files.

## Keywords

- ▶ volumetric changes
- ▶ pediatric endodontics
- ▶ mandibular canines
- ▶ nano-CT
- ▶ rotary files

Statistical analysis revealed significant differences in volumetric and surface changes between Kedo S plus and hand files.

**Conclusion** Rotary file systems, especially Kedo S plus, resulted in increased canal volume and surface area with minimal uninstrumented areas, showing promise for primary dentition root canal preparations. Further clinical assessments are warranted to validate these findings.

## Introduction

The treatment outcomes for dental caries in primary dentition range from preventive resin restoration to pulpectomy, contingent upon the severity of the condition. In the pediatric population, pulpectomy is viewed as an invasive procedure, encompassing multiple steps such as local anesthesia administration, tooth isolation, caries removal, access opening, establishment of canal patency, determination of working length, cleaning and shaping, obturation, and provision of an appropriate coronal seal.<sup>1,2</sup>

The prognosis of teeth is influenced by the comprehensive set of steps outlined earlier.<sup>3,4</sup> Continuous updates to these procedures contribute to enhancing the overall outlook for the tooth. The prognosis of pulpectomy holds significance as it contributes to maintaining the tooth in its position until natural exfoliation occurs. Early loss of the tooth can result in various consequences, including challenges in chewing food, loss of space for incoming teeth, and difficulties in pronunciation.<sup>5</sup>

The cleaning and shaping step is subject to continuous refinement by researchers, reflecting ongoing efforts to enhance and optimize this aspect of dental procedures.<sup>6-8</sup> Traditionally, instruments were conventionally crafted from stainless steel metallurgy, known for its stiffness, which posed challenges in accessing curved canals. Subsequently, the advent of nickel-titanium instruments brought about a notable improvement, offering increased flexibility and significantly reducing procedural errors.<sup>9,10</sup>

In the past, practitioners relied on a hand filing system, a method that demanded a high level of technique sensitivity. When these instruments are not employed with due caution, they can result in ledging of the canal and apical blockage caused by inadequately recaptured dentinal shavings. Additionally, the process is time-consuming and lacks ergonomic benefits for the operator. The introduction of the engine-driven filing system represents a significant advancement in the field of endodontics, offering notable benefits and efficiency.<sup>11</sup> Engine-driven files, produced by various manufacturers globally, come in diverse metallurgies, lengths, diameters, and cross-sections. Operators choose these files based on the specific anatomy and length of the canal, with considerations that can significantly differ in primary dentition.<sup>12,13</sup>

Until 2017, there were no dedicated rotary files available for pediatric endodontics. The pioneering Kedo S rotary file system marked the first instance of tools specifically crafted to accommodate the unique anatomy of canals in primary dentition, with a specialized focus on pulpectomy procedures.<sup>14</sup> The manufacturer has introduced multiple generations of files,

each incorporating different metallurgies, cross-sections, and diameters. Kedo SG blue, a third-generation rotary file system, features heat-treated titanium-coated metallurgy and is designed as a two-file system for molar use.<sup>15-17</sup> The fifth and latest generation, Kedo S plus, represents a single-file system that combines two metallurgies. Ongoing advancements in file systems, integrating dynamic and innovative technologies, necessitate periodic evaluations for their efficiency through both laboratory and clinical assessments.

The constant evolution of imaging techniques is from simple two-dimensional (2D) images to three-dimensional (3D) imaging systems that is from simple radiographs, cone-beam computed tomography (CT) images, micro-CT images. The micro-CT images are nondestructive and 3D reconstructable that helped to assess the various files and filing techniques.<sup>18-20</sup>

Approximately four decades ago, X-ray micro-CT surfaced as a groundbreaking technique for assessing root canal preparation. In contrast to traditional methods, micro-CT is nondestructive and provides a reproducible 3D technique for assessment, eliminating the risk of permanent changes to specimens associated with traditional approaches.<sup>21</sup> In the last two decades, micro-CT technology has played a transformative role in revolutionizing the development and evaluation of rotary file systems within the fields of dentistry and endodontics.<sup>22</sup> In recent times, nano-CT devices boasting remarkably high spatial resolution, with a nano-focal spot source of less than 400 nm, have been introduced. These devices have found widespread use in the medical field, particularly for visualizing intricate details such as bone cells, cartilage, and vascular networks.<sup>23</sup> The advanced capabilities of nano-CT devices, featuring a precision rotational unit, flat panel detector, and exceptional contrasting features, position them as potentially superior to micro-CT devices. Despite the established use of nano-CT in dental research, particularly in areas such as implants and restorative dentistry, there is currently a lack of studies examining its application in assessing canal preparation in primary teeth. In this nano-CT investigation, alterations in root canal structure following preparation with various conventional and rotary files in primary teeth were assessed and compared.

## Materials and Methods

### Study Design

This was an *in vitro* investigation conducted at the dental college and hospital's department of pediatric and preventive dentistry. The sample size calculation was performed using the G power algorithm. This was performed from the

data obtained from the results of the previously published research conducted with a similar methodology at 95% power with a significance level of 0.05.<sup>24</sup> The calculated sample consisted of 45 primary mandibular canines across three groups (fifteen teeth per group). Ethical approval for this study was obtained from the institutional human ethical committee for dental research with the approval number IHEC/SDC/PEDO-2103/22/135.

### Study Samples

The samples used in the study were primary mandibular canines. The teeth were extracted due to retained primary teeth (orthodontic treatment) and symptomatic decayed teeth in which the parents were not willing for pulp therapy for their child. The parents or guardian were informed that the extracted teeth would be used for research purposes and a consent form was signed by the parents or the guardian. The extracted teeth were rinsed under tap water. The soft and hard tissue debris were removed using ultrasonic scaler tips. Disinfection was done using 10% formalin solution in which the teeth were kept for 1 minute and the samples were transferred to specimen containers filled with distilled water till the initiation of the study.<sup>25</sup> All the teeth were subjected to visual and radiographic examination to assess theory suitability in this study. A radiograph inside the mouth was captured for the extracted teeth using two distinct angles: one perpendicular to the tooth's long axis and the other slightly toward the mesial or distal side from the previous angle. The teeth included for the study did not show any degree of physiologic resorption.

The teeth were excluded if external/physiologic resorption was noticed by visual examination; if internal resorption was noticed; presence of pulp stones; presence of calcified root canals; presence of any aberrant canal anatomy; and presence of more than one canals

### Teeth Sample Preparation

Access preparation was completed using no. 6 round diamond bur (Mani Inc., Tochigi, Japan) using a high-speed air-rotor handpiece. Canal patency was checked using a size 10 K-file (Mani. Inc., Tochigi, Japan). The working length for each tooth was measured using a size 15 K-file (Mani. Inc., Tochigi, Japan) until the tip of the file was visible at the apical foramen. The rubber stopper was adjusted to the most stable point at the coronal region. The length was measured using a ruler and the working length determined was kept at 1 mm short of the apical foramen. Normal saline was used to irrigate the canals to remove all the tissue debris from the canal space. Complete irrigation for all the groups was executed using a total of 5 mL of normal saline.

The average working length of the samples was kept approximately between 12 and 14 mm for maintaining uniformity during the preparation of the canal space.

### Preoperative Scan

All the prepared samples were numbered before subjecting to scanning procedure. After the initial preparation of the samples, they were subjected to initial scanning using a

high-resolution nano-CT (SkyScan 2214, Bruker, Kontich, Belgium). A 20 putty (3\*15 = 45 teeth) index was made, and three teeth were mounted to each putty index as the scanner allows only three samples to be scanned at a time. The putty index was also numbered as they will be used during postoperative scan. The samples scanned 360 degrees around the vertical axis in specific rotation steps of 0.3 degrees. The voltage for the X-ray source is set at 80kV and current of 110  $\mu$ A with voxel size of 1.58 $\mu$ m. During the imaging process, each degree of rotation was maintained for 1,200 ms, using a detector consisting of 1280  $\times$  1280 pixels. This detector was selected to ensure the highest level of image accuracy. The scanning procedure of the samples approximately took 4 hours per putty index used. Ensuring the accuracy of the imaging results involved adhering meticulously to the manufacturer's guidelines for beam hardening correction and setting optimal contrast boundaries. These adjustments were fine-tuned after conducting preliminary scans and reconstruction tests. Subsequent to the initial scan, the samples were randomly divided into three groups (comprising 15 primary mandibular canines each) using a block randomization technique.

### Root Canal Preparation

Root canals were prepared using the following instrumentation protocol. The initial preparation of all samples involved the use of a size 15/0/02 taper K-file (Mani. Inc., Tochigi, Japan) according to the manufacturer's recommendation, before introducing rotary files into the canal. When changing the file sequence in all groups, irrigation was performed using saline solution. Postpreparation canals were dried using suitable paper points. In this study, new files were employed to prepare each tooth sample; that is, one pack of files were used to prepare three tooth samples with three canals. Canal preparation employed three distinct file systems in the following manner:

Group 1 utilized the Kedo S plus rotary file from Kedo Dental, India, following the manufacturer's guidelines. The Kedo S plus (A1-plus) file, used at 300 rpm and 2 Ncm torque with an electronic endomotor (XSmart, DENTSPLY India Pvt. Ltd., Delhi, India), applied a crown-down technique using pecking motions toward the apex until reaching the working length. After reaching this point, brushing motions were performed both buccally and lingually twice to clear any remaining debris in the canal.

Group 2 employed Kedo SG blue rotary files from Kedo Dental, India, following the manufacturer's instructions. These files, operated at 300 rpm and 2 Ncm torque using an electronic endo motor (XSmart, DENTSPLY India Pvt. Ltd., Delhi, India), involved first using the Kedo SG blue E1 file in a pecking motion toward the working length. Saline irrigation was performed, followed by utilizing the Kedo SG blue U1 file in a similar pecking motion. Upon reaching the working length, brushing motions were conducted both buccally and lingually to eliminate any residual debris.

Group 3 employed hand K-files from Mani Inc., Japan, using a biomechanical preparation method that included quarter turn and pull motions with stainless steel hand K-files. The instrumentation sequence involved sizes

25/0.02 taper, 30/0.02 taper, 35/0.02 taper, and 40/0.02 taper until reaching the predetermined working length. Irrigation was performed for each increase in file size during canal preparation.

### Postoperative Scan

After the completion of the root canal preparation, the samples were carefully placed back into their respective putty indices. Subsequently, the samples underwent nano-CT scanning, following a similar protocol as the preoperative scan analysis described earlier. During the scanning process, the volume of each canal in all the samples was calculated, starting from the canal orifice, and extending 1 mm short of the apical foramen to compare the change of volume from the preoperative scan of the uninstrumented teeth samples. This volumetric analysis allowed for a quantitative assessment of the changes in canal volume resulting from the root canal preparation procedure.

### Imaging Reconstruction and Processing

The process of imaging reconstruction involved the use of NRecon software (ver. 2.1.0.2, SkyScan, Kontich, Belgium). This software employed a specific algorithm to create 2D axial images at a resolution of  $1,000 \times 1,000$  pixels. Throughout the reconstruction, adjustments for ring artifact correction and smoothing remained at zero, preserving the original image data with minimal alteration. Consequently, these images offered a precise and clear view of the 3D root canal anatomy.

Subsequent to image reconstruction, CTAn software (ver. 1.21.2.0, Skyscan, Aartselaar, Belgium) was utilized for comprehensive 3D volumetric visualization and analysis of the root canals. This software facilitated thorough examination and measurement of canal volumes, enabling a detailed analysis of morphological changes like volumetric changes ( $\text{mm}^3$ ), surface area changes ( $\text{mm}^2$ ), and uninstrumented area (%) resulting from the root canal preparation procedures. The combined use of NRecon and CTAn software ensured accurate, detailed, and 3D visualization and analysis of the root canal structures.

### Data Collection and Statistical Analysis

The gathered volumetric data from the prepared root canals were tabulated and structured within a Microsoft Excel spreadsheet. Both preoperative and postoperative canal volumes were logged, and the disparity in volume for each sample was computed. Following this, the data underwent analysis and was presented as mean values alongside their corresponding standard deviations. Statistical analyses were performed using the Statistical Package for Social Sciences software (SPSS version 17, SPSS Inc., Chicago, Illinois, United States). To evaluate significance within and between groups, one-way analysis of variance and posthoc tests were employed. A *p*-value below 0.05 was indicative of a notable statistical difference between the compared groups or conditions.

## Results

The mean working length of the teeth samples was  $13 \pm 0.6$  mm. When assessing postpreparation changes in volumetric and surface area modifications among instrumentation files (Kedo S plus, Kedo SG blue, hand file), it is evident that the Kedo S plus file showcases the most significant alterations. This file demonstrates a notable percentage change of 3.53% in volumetric adjustments, implying a more pronounced transformation in the canal's surface compared with both Kedo SG blue (3.33%) and the hand file (1.61%). There is no statistical significance seen in the volumetric changes among three groups ( $p > 0.05$ ) that is in accordance with the null hypothesis of this study.

Similarly, in the evaluation of surface area modifications postpreparation among these files, the Kedo S plus file presents a substantial alteration, showing a percentage change of 2.27%. This signifies a distinct change in the canal's surface, surpassing the impact seen with Kedo SG blue (1.21%) and the hand file (0.59%). There is a statistical significance seen in surface area changes between the three groups ( $p < 0.05$ ).

In terms of uninstrumented area modifications postpreparation, the Kedo S plus file demonstrates the most substantial effect, showcasing a percentage change of 20.83%. This suggests a more considerable influence in leaving uninstrumented areas compared with both Kedo SG blue (20.85%) and the hand file (32.20%). There is a statistical significance seen in uninstrumented areas between the three groups ( $p < 0.05$ ).

The preparation of the canal resulted in amplified volume and surface area within the root canals of primary teeth. Among the instrumentation files, the Kedo S plus group exhibited the most considerable increase in both volume and surface area while leaving a lesser uninstrumented area ( $p < 0.001$ ). These findings are summarized in **Table 1**, providing a clear overview of the differences in canal volume changes among the different file systems used in the study.

Intergroup comparison based on volumetric alterations revealed that the most significant difference was observed between Kedo S plus and the hand file ( $p = 0.003$ ), showing stronger evidence against the null hypothesis compared with other comparisons involving Kedo SG blue (**Table 2**). Intergroup comparison based on surface area changes reported that the most notable difference existed between Kedo S plus and the hand file ( $p = 0.004$ ), with a stronger level of significance than the difference between Kedo SG blue and the hand file ( $p = 0.009$ ; **Table 3**). Intergroup comparison based on uninstrumented area modifications indicated that the most significant difference was found between Kedo S plus and the hand file ( $p = 0.003$ ), with a higher level of significance than the difference between Kedo SG blue and the hand file ( $p = 0.012$ ; **Table 4**).

The 3D processed representative image of the sample tooth model prepared using different file systems used in this study can be interpreted in **Figs. 1 to 3**.

**Table 1** Comparison of preoperative and postoperative volumetric, surface area and uninstrumented area changes among three different instrumentation techniques

Variable	Groups	Mean preoperative	Mean postoperative	Mean difference	Percentage of change	p-Value
Volumetric changes (mm <sup>3</sup> )	Kedo S plus	3400.000	3520.000	120.000	3.53%	0.053
	Kedo SG blue	2700.000	2790.000	90.00	3.33%	
	Hand file	3100.000	3150.00	50.00	1.61%	
Surface area changes (mm <sup>2</sup> )	Kedo S plus	928.303	949.378	21.075	2.27%	0.041
	Kedo SG blue	1374.127	1390.673	16.546	1.21%	
	Hand file	1056.283	1062.54	6.257	0.59%	
Uninstrumented area (%)	Kedo S plus	1535.500	1855.00	320.00	20.83%	0.021
	Kedo SG blue	1485.00	1795.00	310.00	20.85%	
	Hand file	1250.00	1652.50	402.50	32.20%	

Abbreviation: SD, standard deviation.  
 p < 0.05.

**Table 2** Intergroup comparison of preoperative and postoperative volumetric changes among three different instrumentation techniques

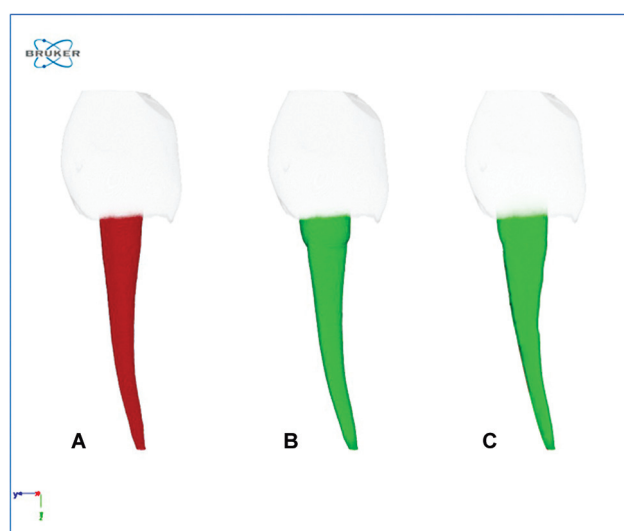
Group	Mean difference (I-J)	p-Value
Group 1 (Kedo S plus)	Group 2 (Kedo SG blue)	0.025
	Group 3 (Hand K-file)	0.003
Group 2 (Kedo SG blue)	Group 1 (Kedo S plus)	0.025
	Group 3 (Hand K-file)	0.007
Group 3 (Hand K-file)	Group 1 (Kedo S plus)	0.003
	Group 2 (Kedo SG blue)	0.007

**Table 3** Intergroup comparison of preoperative and postoperative surface area among three different instrumentation techniques

Group	Mean difference (I-J)	p-Value
Group 1 (Kedo S plus)	Group 2 (Kedo SG blue)	0.022
	Group 3 (Hand K-file)	0.004
Group 2 (Kedo SG blue)	Group 1 (Kedo S plus)	0.022
	Group 3 (Hand K-file)	0.009
Group 3 (Hand K-file)	Group 1 (Kedo S plus)	0.004
	Group 2 (Kedo SG blue)	0.009

**Table 4** Intergroup comparison of preoperative and postoperative uninstrumented area changes among three different instrumentation techniques

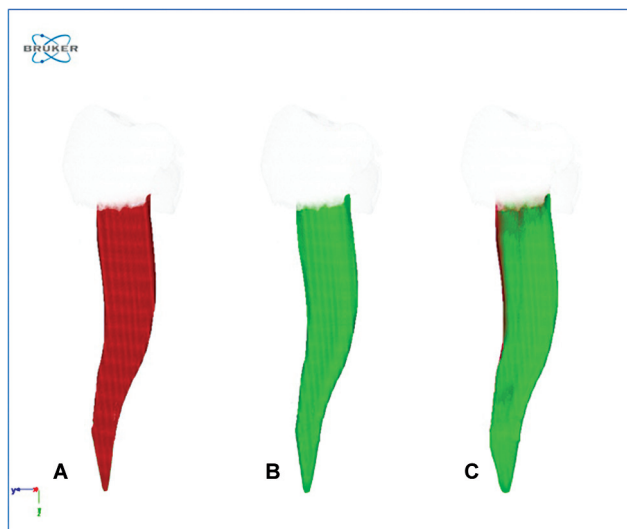
Group	Mean difference (I-J)	p-Value
Group 1 (Kedo S plus)	Group 2 (Kedo SG blue)	0.043
	Group 3 (Hand K file)	0.003
Group 2 (Kedo SG blue)	Group 1 (Kedo S plus)	0.043
	Group 3 (Hand K file)	0.012
Group 3 (Hand K file)	Group 1 (Kedo S plus)	0.003
	Group 2 (Kedo SG blue)	0.012



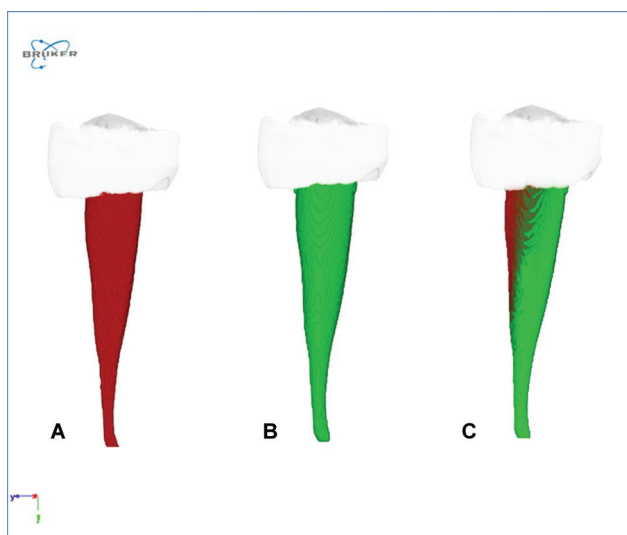
**Fig. 1** Three-dimensional processed image of the tooth model prepared using the file system Kedo S plus: (A) Preoperative image; (B) postoperative image; (C) superimposed image of pre- and postoperative images. Note the middle and apical thirds of the canal space had untouched regions, while the coronal third showed complete preparation of the canal.

### Discussion

The diverse benefits provided by rotary instruments warrant the examination of novel rotary systems as a natural progression in refining clinical practices in pediatric endodontics. This research scrutinized both a multifile rotary system and a single-file rotary system, sharing comparable properties, in contrast to traditional hand files. The evaluation focused on overall changes in morphology, to enable clinically relevant comparisons. Chemomechanical preparation uses various chemical irrigating agents and the mechanical preparation uses endodontic files that helps to eliminate biofilm from the canal space, thereby ensuring a disinfected canal space that is ready to receive suitable filling material.<sup>26-28</sup> For pediatric endodontics, the usage of permanent rotary files has become very popular. Previous study has proven that better cleaning



**Fig. 2** Three-dimensional processed image of the tooth model prepared using the file system Kedo SG blue: (A) Preoperative image; (B) postoperative image; (C) superimposed image of pre- and postoperative images. Note the preparation appears more extensive and uniform along all the surfaces of the root canal.



**Fig. 3** Three-dimensional processed image of the tooth model prepared using the file hand K-file system: (A) Preoperative image; (B) postoperative image; (C) superimposed image of pre- and postoperative images. Note that there was minimal preparation and a greater number of untouched regions.

and shaping was achieved using adult rotary file (ProTaper) for coronal preparation and hand file for apical preparation in primary root canals.<sup>29</sup> In the end, various research works neither reject or approve the usage of permanent rotary files for pediatric endodontics.<sup>30</sup>

Our study employed advanced third- and fifth-generation rotary Kedo Files as integral components. These innovative tools, known as Kedo SG blue and Kedo S plus, both 17mm in length and crafted from NiTi, underwent precise heat treatment featuring a variable-variable taper. The Kedo SG blue set comprises three distinct files: D1, designed for narrow canals in primary molars; E1, tailored for wider canals in primary molars; and U1, with a 0.40mm tip diameter

specifically for anterior teeth. These files are coated with titanium oxide, enhancing their flexibility and bolstering fracture resistance.<sup>31,32</sup> In contrast, the Kedo S plus set includes two specialized files: A1 plus for anterior teeth canals and P1 plus for posterior teeth canals. These files incorporate a unique dual metallurgy design. The coronal half undergoes heat treatment, while the apical half receives additional heat treatment combined with a titanium oxide coating. This distinctive construction results in a stiffer coronal section, enabling efficient orifice opening for precise placement of obturating material. Meanwhile, the titanium oxide-coated apical portion's flexibility facilitates smoother preparation of the intricate canals typically found in primary teeth. The introduction of these groundbreaking designs necessitates ongoing evaluation to gauge their effectiveness in treating primary teeth, potentially simplifying the tasks of dental practitioners.<sup>33</sup>

Hülsmann et al proposed several parameters for assessing the cleaning and shaping ability of endodontic instruments, such as canal transportation, untouched surface area, and working time. In this particular study, the change in volume, surface area, and uninstrumented surfaces of the canal was chosen as the parameter, as it is completely dependent on the design of the file being used.<sup>34</sup> The findings of the study can be solely attributed to the design of the file system used since all the preparations were performed by a single operator. Primary mandibular canines were selected to assess the files' performance in preparing the canal spaces, thus enabling the evaluation of the file designs' ability in canal preparation. Nano-CT is an emerging radiographic technology that provides highly defined voxels and more accurate imaging compared with micro-CT. With advancements in ultra-high spatial resolution, nano-CT offers a more detailed visualization of cellular structures. This advanced technology was employed for the first time in dental research to examine canal preparation in primary teeth.

According to the present findings, the null hypotheses related to root canal volume and surface need to be refuted. The utilization of both rotary file systems notably amplified both the root canal volume and surface in primary teeth. These results are consistent with recent studies that evaluated various rotary files against hand files in primary teeth, suggesting that the increased conicity of rotary instruments might have contributed to more effective removal of dentin in the upper part of the canal. Consequently, this resulted in an increased root canal volume and surface after preparation, reducing the percentage of unprepared areas when employing rotary file systems. Stvileci's assessment of root canal preparation using micro-CT showed that ProTaper rotary files exhibited greater effectiveness than manual hand files, significantly reducing untouched root canal surface across the coronal, middle, and apical sectors ( $p < 0.001$ ).<sup>35</sup>

A well-prepared canal is defined as a canal that does not have any untouched areas of the rotary or hand file and maintains the original canal configuration and taper. However, the findings of our investigation demonstrated the presence of untouched regions in canals prepared using both rotary files and hand files. This finding aligns with

the results of a previous study that also reported similar outcomes. In the Kedo S plus group, untouched areas were observed at the middle and apical thirds of the root canals, specifically on the mesial or distal surfaces. This may be attributed to the brushing motion performed in the buccolingual direction during canal preparation, which resulted in effective preparation in that specific direction. However, the coronal third of the canals in the Kedo S plus group did not exhibit any unprepared surfaces. On the other hand, the Kedo SG blue group showed uniform preparation along all surfaces, which can be attributed to the wider design and cross-section of the Kedo SG blue files compared with Kedo S plus. Canals prepared using hand K-files displayed a greater number of untouched regions, indicating under-preparation of the canals when conventional hand files were used. This finding is consistent with the results reported by Metzger et al<sup>36</sup> and Zhao et al<sup>37</sup> who also mentioned that hand files show more untouched surfaces. One possible explanation for this observation is the structural nature of the primary mandibular molars used in our study. Since primary molars tend to have narrower and tortuous canals (compared with single rooted primary teeth), hand filing may not adequately prepare the canal walls 3D and tend to under-prepare the canal space. In this study, both hand files and rotary files exhibited noteworthy and consistent canal shaping. The mean volume difference was observed to be greater for Kedo S plus compared with Kedo SG blue. This disparity can be linked to the variable taper of Kedo S plus, allowing for more extensive coronal preparation and minimal apical preparation, akin to the characteristics of hand files. On the other hand, Kedo SG blue displayed moderate volumetric changes attributed to its bulky core, resulting in a uniform preparation of the root canal across all dimensions.

In this research, we applied nano-CT for the inaugural investigation into volumetric alterations in canal preparation within primary mandibular canines. Our findings demonstrated a notable volume increase when rotary files were compared with hand files. The slender mesiodistal proportions of ribbon-shaped canals in primary teeth impose constraints on extensive enlargement to prevent potential lateral perforations. Thus, employing a file system that minimizes canal preparation yet effectively eliminates infected debris could prove an appropriate choice. However, our study has limitations, including a relatively modest sample size and the utilization of teeth with broader canals. Analyzing the preparation of canals in narrower roots, such as primary canine, would provide a broader perspective on the effectiveness of the preparation. It is important to note that although this *in vitro* nano-CT analysis favored the use of the Kedo S plus pediatric rotary file system, further *in vivo* analysis is required to assess postoperative pain, obturation quality, and the incidence of file fractures.

## Conclusion

Taking into account the constraints of this study, it was observed that rotary file systems led to a notable enlargement of canals indicating increased volumetric and surface area changes when compared with hand files. Specifically,

Kedo S plus files exhibited more coronal preparation with minimal apical preparation, resembling the characteristics of hand files. Conversely, Kedo SG blue files demonstrated consistent canal preparation from the cervical to apical regions. Nevertheless, it is crucial to emphasize that further clinical evaluations are essential to gain a deeper understanding of how these findings can be applied in real-world clinical scenarios. Additional research conducted in a clinical setting would offer valuable insights into the performance and outcomes of these file systems.

### Authors' Contributions

B.S., G.J., and V.R. designed the research study. B.S. performed the research. G.J. and V.R. provided help and advice for the research. V.R. analyzed the data. B.S., G.J., and V.R. wrote the manuscript. All authors contributed to editorial changes in the manuscript. All authors read and approved the final manuscript.

### Ethical Approval and Consent to Participate

The study was conducted in accordance with the Declaration of Helsinki and approved by the Institutional Review Board (or Ethics Committee) of Saveetha Dental College IHEC/SDC/PEDO-2103/22/135. Consent to participate is not available for this study.

### Funding

None.

### Conflict of Interest

Ganesh Jeevanandan serves as the director of Kedo Dental. His involvement in the study included drafting the manuscript, proofreading, and procuring materials. All other authors declare no conflicts of interest and have no financial relationships with any organization.

### Acknowledgment

We sincerely thank the laboratory technicians and nano-CT engineer for their help during the research process.

## References

- Goyal A, Nishant, Morankar R, Gauba K, Jaiswal M. Awareness among pediatricians regarding oral health care in children including those with special health care needs: across-sectional survey. *J Family Med Prim Care* 2020;9(08):4151–4155
- Smaïl-Faugeron V, Glennay AM, Courson F, Durieux P, Muller-Bolla M, Fron Chabouis H. Pulp treatment for extensive decay in primary teeth. *Cochrane Database Syst Rev* 2018;5(05):CD003220
- Dou G, Wang D, Zhang S, Ma W, Xu M, Xia B. A retrospective study on the long-term outcomes of pulpectomy and influencing factors in primary teeth. *J Dent Sci* 2022;17(02):771–779
- Coll JA, Sadrian R. Predicting pulpectomy success and its relationship to exfoliation and succedaneous dentition. *Pediatr Dent* 1996; 18(01):57–63
- Spodzieja K, Olczak-Kowalczyk D. Premature loss of deciduous teeth as a symptom of systemic disease: a narrative literature review. *Int J Environ Res Public Health* 2022;19(06):3386
- Reddy ER, Raju SS, Sandipamu T, Kiranmayi M, Mudusu SP, Saraswati SD. Modified conventional root canal shaping

- technique in primary teeth: an *in vivo* study. *Int J Clin Pediatr Dent* 2022;15(Suppl 1):S8–S11
- 7 Schachter D, Blumer S, Sarsur S, et al. Exploring a paradigm shift in primary teeth root canal preparation: an *ex vivo* micro-CT study. *Children (Basel)* 2023;10(05):792
  - 8 Rajain T, Tsomu K, Namdev R. Evaluation and comparison of effectiveness of Kedo-S pediatric rotary files vs manual instrumentation for root canal treatment in primary molars. *Int J Clin Pediatr Dent* 2023;16(01):22–29
  - 9 Alves RAA, Souza JB, Gonçalves Alencar AH, Pécora JD, Estrela C. Detection of procedural errors with stainless steel and NiTi instruments by undergraduate students using conventional radiograph and cone beam computed tomography. *Iran Endod J* 2013;8(04):160–165
  - 10 Zupanc J, Vahdat-Pajouh N, Schäfer E. New thermomechanically treated NiTi alloys - a review. *Int Endod J* 2018;51(10):1088–1103
  - 11 Liang Y, Yue L. Evolution and development: engine-driven endodontic rotary nickel-titanium instruments. *Int J Oral Sci* 2022;14(01):12
  - 12 Katge F, Dixit UB. Root and root canal anatomy of primary mandibular central incisor, lateral incisor, and canine in Indian children: a cone beam computed tomography study. *Int J Dent* 2022;2022:7191134
  - 13 Ahmed HMA, Musale PK, El Shahawy OI, Dummer PMH. Application of a new system for classifying tooth, root and canal morphology in the primary dentition. *Int Endod J* 2020;53(01):27–35
  - 14 Jeevanandan G. Kedo-S paediatric rotary files for root canal preparation in primary teeth - case report. *J Clin Diagn Res* 2017;11(03):ZR03–ZR05
  - 15 Sruthi S, Jeevanandan G, Govindaraju L, Subramanian E. Assessing quality of obturation and instrumentation time using Kedo-SG blue, Kedo-SH, and reciprocating hand K-files in primary mandibular molars: a double-blinded randomized controlled trial. *Dent Res J (Isfahan)* 2021;18:76
  - 16 Hadwa SM, Ghouraba RF, Kabbash IA, El-Desouky SS. Assessment of clinical and radiographic efficiency of manual and pediatric rotary file systems in primary root canal preparation: a randomized controlled clinical trial. *BMC Oral Health* 2023;23(01):687
  - 17 Kohli A, Chhabra J, Sharma K, Katyayan R, Bhatnagar P, Sharma A. Comparative evaluation of instrumentation time and quality of obturation amongst pediatric rotary endodontic system: an *in vivo* study. *Int J Clin Pediatr Dent* 2023;16(02):338–343
  - 18 Karatas OH, Toy E. Three-dimensional imaging techniques: a literature review. *Eur J Dent* 2014;8(01):132–140
  - 19 Mao T, Neelakantan P. Three-dimensional imaging modalities in endodontics. *Imaging Sci Dent* 2014;44(03):177–183
  - 20 Acar B, Kamburoğlu K, Tatar İ, et al. Comparison of micro-computerized tomography and cone-beam computerized tomography in the detection of accessory canals in primary molars. *Imaging Sci Dent* 2015;45(04):205–211
  - 21 Azevedo MAD, Silva TGD, Fernandes Â, Piasecki L, Fariniuk LF, Silva Neto UXD. Endodontic retreatment using a single instrument from four nickel-titanium systems - a micro-CT study. *Braz Dent J* 2020;31(06):605–610
  - 22 Erpaçal B, Adıgüzel Ö, Cangül S. The use of micro-computed tomography in dental applications. *Int Dent Res* 2019;9(02):78–91
  - 23 Ahmed HMA. Nano-computed tomography: current and future perspectives. *Restor Dent Endod* 2016;41(03):236–238
  - 24 Jeevanandan G, Thomas E. Volumetric analysis of hand, reciprocating and rotary instrumentation techniques in primary molars using spiral computed tomography: an *in vitro* comparative study. *Eur J Dent* 2018;12(01):21–26
  - 25 Sandhu SV, Tiwari R, Bhullar RK, et al. Sterilization of extracted human teeth: a comparative analysis. *J Oral Biol Craniofac Res* 2012;2(03):170–175
  - 26 Selvakumar H, Kavitha S, Thomas E, Anadhan V, Vijayakumar R. Computed tomographic evaluation of K3 rotary and stainless steel K file instrumentation in primary teeth. *J Clin Diagn Res* 2016;10(01):ZC05–ZC08
  - 27 Barasuol JC, Alcalde MP, Bortoluzzi EA, Duarte MAH, Cardoso M, Bolan M. Shaping ability of hand, rotary and reciprocating files in primary teeth: a micro-CT study *in vitro*. *Eur Arch Paediatr Dent* 2021;22(02):195–201
  - 28 Vora MS, Nihal NK, Ramachandra JA. Root canal irrigants in primary teeth. *World J Dent* 2015;6(04):229–234
  - 29 Nazari Moghaddam K, Mehran M, Farajian Zadeh H. Root canal cleaning efficacy of rotary and hand files instrumentation in primary molars. *Iran Endod J* 2009;4(02):53–57
  - 30 Mehlawat R, Kapoor R, Gandhi K, Kumar D, Malhotra R, Ahuja S. Comparative evaluation of instrumentation timing and cleaning efficacy in extracted primary molars using manual and NiTi rotary technique - *in vitro* study. *J Oral Biol Craniofac Res* 2019;9(02):151–155
  - 31 Bhattacharjee A, Singh RK, Patil RK, et al. Comparative assessment of cleaning efficacy of two exclusive paediatric rotary files in root canals of primary teeth: an *in vitro* study. *Int J Paediatr Dent* 2024;34(04):474–484
  - 32 Lakshmanan L, Jeevanandan G. Microbial evaluation of root canals after biomechanical preparation with manual K-files, manual H-files, and Kedo-SG Blue rotary files: an *in vivo* study. *Int J Clin Pediatr Dent* 2022;15(06):687–690
  - 33 Suresh B, Jeevanandan G, Ravindran V, et al. Comparative evaluation of extrusion of apical debris in primary maxillary anterior teeth using two different rotary systems and hand files: an *in vitro* study. *Children (Basel)* 2023;10(05):898
  - 34 Hülsmann M, Peters OA, Dummer PMH. Mechanical preparation of root canals: shaping goals, techniques and means. *Endod Topics* 2005;10(01):30–76
  - 35 Stavileci M, Hoxha V, GÖrdüysus Ö, et al. Evaluation of root canal preparation using rotary system and hand instruments assessed by micro-computed tomography. *Med Sci Monit Basic Res* 2015;21:123–130
  - 36 Metzger Z, Zary R, Cohen R, Teperovich E, Paqué F. The quality of root canal preparation and root canal obturation in canals treated with rotary versus self-adjusting files: a three-dimensional micro-computed tomographic study. *J Endod* 2010;36(09):1569–1573
  - 37 Zhao D, Shen Y, Peng B, Haapasalo M. Root canal preparation of mandibular molars with 3 nickel-titanium rotary instruments: a micro-computed tomographic study. *J Endod* 2014;40(11):1860–1864