



# Sumatriptan for Postcraniotomy Headache after Minimally Invasive Craniotomy for Clipping of Aneurysms: A Prospective Randomized Controlled Trial

Lashmi Venkatraghavan<sup>1</sup> Evan Shao<sup>1</sup> Kristof Nijs<sup>1</sup> Michael Dinsmore<sup>1</sup> Tumul Chowdhury<sup>1</sup>

<sup>1</sup>Department of Anesthesia and Pain Management, University of Toronto, Toronto Western Hospital, University Health Network, Toronto, Canada

Asian J Neurosurg 2024;19:250–255.

Address for correspondence Lashmi Venkatraghavan, MD, FRCA, FRCPC, Department of Anesthesia, University of Toronto, Toronto Western Hospital, University Health Network, 399 Bathurst Street, Toronto, Ontario, M5T 2S8, Canada (e-mail: lashmi.venkatraghavan@uhn.ca).

## Abstract

**Introduction** Postcraniotomy headaches are often underestimated and undertreated. This study aimed to identify if postoperative administration of sumatriptan after minimally invasive craniotomy for clipping an unruptured aneurysm could reduce postcraniotomy headache and improve the quality of postoperative recovery.

**Settings and Design** Tertiary care center, single-center randomized double-blind placebo-controlled trial.

**Materials and Methods** Patients who complained of postoperative headaches after minimally invasive craniotomy for clipping of unruptured aneurysms were randomized to receive subcutaneous sumatriptan (6 mg) or placebo. The primary outcome was the quality of recovery measured 24 hours after surgery. Secondary outcomes were total opioid use and headache score at 24 hours after surgery. Data were analyzed using a Student's *t*-test or the chi-square test.

**Results** Forty patients were randomized to receive sumatriptan ( $n = 19$ ) or placebo ( $n = 21$ ). Both groups had similar demographics, comorbidities, and anesthesia management. The Quality of Recovery 40 score was higher for patients receiving sumatriptan compared to placebo, however, not statistically significant (173 [156–196] vs. 148 [139–181],  $p = 0.055$ ). Postoperative opioid use between sumatriptan and placebo was lower, but not significant (5.4 vs. 5.6 mg morphine equivalent,  $p = 0.71$ ). The severity of headache was also not statistically different between the two groups (5 [4–5] vs. 4 [2–5],  $p = 0.155$ ).

**Conclusion** In patients undergoing minimally invasive craniotomies for aneurysm clipping, sumatriptan given postoperatively has a nonsignificant trend for a higher quality of recovery. Similarly, there was a nonsignificant trend toward lower postcraniotomy headache scores and opioid scores for the patient given sumatriptan.

## Keywords

- ▶ sumatriptan
- ▶ postcraniotomy headache
- ▶ craniotomy
- ▶ pain management
- ▶ aneurysm clipping

article published online  
June 6, 2024

DOI <https://doi.org/10.1055/s-0044-1786702>.  
ISSN 2248-9614.

© 2024. Asian Congress of Neurological Surgeons. All rights reserved.

This is an open access article published by Thieme under the terms of the Creative Commons Attribution-NonDerivative-NonCommercial-License, permitting copying and reproduction so long as the original work is given appropriate credit. Contents may not be used for commercial purposes, or adapted, remixed, transformed or built upon. (<https://creativecommons.org/licenses/by-nc-nd/4.0/>)

Thieme Medical and Scientific Publishers Pvt. Ltd., A-12, 2nd Floor, Sector 2, Noida-201301 UP, India

## Introduction

Unruptured intracranial aneurysms have a high prevalence (3.2%) and are increasingly diagnosed with the evolution of imaging tools.<sup>1</sup> The management strategy for clipping or coiling of unruptured aneurysms is made after multidisciplinary evaluation.<sup>2</sup> Minimally invasive craniotomy for clipping an unruptured aneurysm has become a common surgical procedure to improve early discharge from the hospital.<sup>2</sup>

The postoperative pain after minimally invasive craniotomy can be either somatic pain from the surgical site or headaches similar in nature to a migraine.<sup>3</sup> Though minimally invasive craniotomy is often associated with lower somatic pain from the surgical site, postoperative headache is common and often difficult to manage, preventing early discharge from the hospital. Postcraniotomy headaches are often underestimated and undertreated and have an incidence of 70 to 90%.<sup>3</sup> Though conventional analgesics can help with somatic pain, they are not effective for postcraniotomy headaches. Further, conventional opioids may impact further postoperative recovery as they can confound neurological examination and increase nausea and vomiting.<sup>4</sup>

The mechanism for postcraniotomy headaches is not fully elucidated but involves meningeal irritation mediated by trigeminal afferents involving serotonin-based molecular mechanisms.<sup>5</sup> This may be due to direct incision of the dura, dural tension, and possibly loss of cerebrospinal fluid (CSF) especially with minimally invasive craniotomy.<sup>6</sup> Sumatriptan, a serotonin receptor agonist, is commonly used to treat primary headaches, such as acute migraines,<sup>5</sup> and may benefit patients with postcraniotomy headaches.<sup>4-6</sup> The mechanism of action of sumatriptan in the treatment of migraine headache is by (1) direct effect on the vascular smooth muscle of the meningeal vessel resulting in vasoconstriction, (2) inhibition of vasoactive neuropeptide (calcitonin gene-related peptide [CGRP]) release that acts on the trigeminal pathway, and (3) inhibition of pain transmission in the brainstem.<sup>7</sup> Thus, activating serotonin receptors inhibits neuropeptide release and decreases vasodilation thus blunting the meningeal nociceptive process and blunts pain transmission through the trigeminovascular system regardless of the underlying stimuli.

Previous studies have shown that sumatriptan effectively reduces postcraniotomy headache after microvascular decompression for trigeminal neuralgia<sup>5</sup> and craniotomy for supratentorial tumor resection.<sup>4</sup> However, the potential effect of subcutaneous sumatriptan has not yet been investigated after minimally invasive craniotomy for clipping an unruptured aneurysm. In this randomized controlled trial, we investigated whether the postoperative administration of subcutaneous sumatriptan after minimally invasive craniotomy for clipping an unruptured aneurysm would reduce postcraniotomy headache and improve the quality of postoperative recovery.

## Material and Methods

After approval by the institutional ethics review board, we conducted a single-center randomized double-blind placebo-controlled trial. Written and informed consent was obtained

from all patients. Adult patients (18–80 years), American Society of Anesthesiologists I to III, undergoing minimally invasive craniotomy for clipping of elective unruptured aneurysms were included. Exclusion criteria were pregnancy, known sensitivity to sumatriptan or sulfonamides, history of ischemic heart disease, uncontrolled hypertension, transient ischemic attacks (TIAs), stroke, peripheral vascular disease, or severe hepatic impairment. Patients with a history of migraine and current or recent use of triptans or monoamine oxidase inhibitor drugs were also excluded.

All patients received standardized anesthetic and surgical care. Intravenous induction of anesthesia was followed by tracheal intubation and insertion of an arterial line. Anesthesia was maintained using sevoflurane and remifentanyl infusion titrated to maintain mean arterial blood pressure at 20% of baseline. An additional bolus of fentanyl (25–50 mcg intravenously) was used intraoperatively for analgesia if required. Prophylactic antibiotics (cefazolin) and antiemetics (dexamethasone and ondansetron) were administered according to routine practice. Mannitol was not given to any of the patients. All operations were performed by a single neurosurgeon. The surgical site was infiltrated with 20 mL of bupivacaine 0.25% with 1:200,000 epinephrine before the incision. No other forms of regional anesthesia (e.g., scalp block) were performed. The surgical approach was a minimally invasive craniotomy consisting of either mini-pterional, supraorbital, or lateral supraorbital approaches as described before.<sup>2</sup> At the end of the procedure after awakening of the patients, they were transferred to the postanesthetic care unit (PACU).

Patients who complained of postoperative headaches in PACU were randomized to immediately receive subcutaneous sumatriptan (6 mg) or placebo (saline). A computer-based, permuted block randomization method with a 1:1 allocation ratio and a variable block size was used. Sequentially numbered, opaque, sealed envelopes were used for allocation schedules and individual assignments. The subject and the investigator who assessed subjects after surgery were blinded to group allocation, as were the anesthetist and the surgeon.

Evaluation of surgical site pain and headache severity at regular intervals was performed using a numerical rating scale from 0 to 10, where 0 was no pain and 10 was the worst pain imaginable. Patients who did not complain of headache were excluded and there was no threshold of headache before randomization. Postcraniotomy migrainous headache was defined as having either pulsing or intense throbbing sensations in the frontotemporal or occipital-nuchal regions, or both, accompanied by nausea, vomiting, or extreme sensitivity to light or sound.

All other aspects of postanesthetic care were routine. Surgical site pain was treated with a fentanyl bolus of 25 mcg intravenously and if needed hydromorphone 0.2 to 0.4 mg intravenously. Postoperative nausea and vomiting were treated using dimenhydrinate 25 to 50 mg intravenously or ondansetron 4 mg intravenously. Patients were discharged from the PACU after 2 hours to a neurosurgical ward. Analgesia on the surgical ward consisted of either oral acetaminophen 300 mg with codeine 30 mg or acetaminophen 325 mg with

oxycodone 5 mg. If oral medications were not tolerated, intravenous morphine or hydromorphone was used.

Patients' hemodynamics (heart rate, blood pressure, oxygen saturation, electrocardiogram) were monitored every 5 minutes for the first hour, every 15 minutes for the next hour, and then every 30 minutes till 24 hours postoperative period. All patients had postoperative computerized tomographic (CT) angiogram 24 hours after surgery.

The Quality of Recovery 40 (QoR-40) questionnaire was taken 24 hours after surgery. QoR-40 is a validated global measure of quality of recovery which measures five dimensions of health including patient support, comfort, emotions, physical independence, and pain.<sup>8</sup> The headache score was used (score 1–5; 5 none of the time, 1 all the time) 24 hours after surgery.<sup>5</sup>

### Outcomes

The primary outcome was the quality of recovery measured by QoR-40 score 24 hours after surgery. Secondary outcomes were total opioid use (mg morphine equivalent) and headache scores (1–5; 5 none of the time, 1 all the time) at 24 hours after surgery.

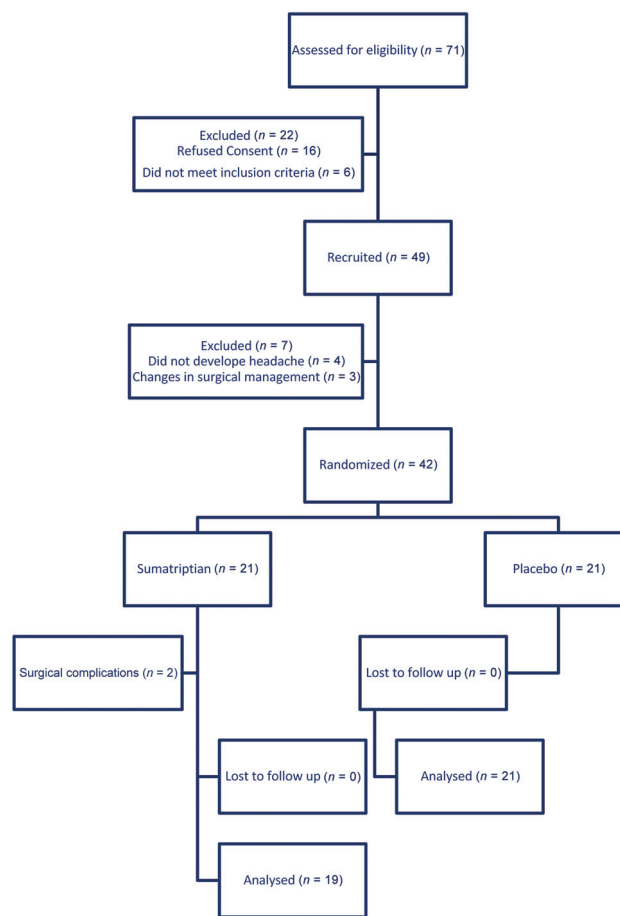
### Statistical Analysis

The sample size was calculated using data from previous studies<sup>5</sup> to be 21 patients in each group to detect a statistically significant difference between groups with  $\alpha$  of 0.05 and power of 80%. Data were tested for normality of distribution using the Kolmogorov–Smirnov test. Normally distributed continuous data are presented as the mean ( $\pm$  standard deviation) and were compared using Student's unpaired *t*-test. Ordinal data and nonnormally distributed data are presented as the median (interquartile range [IQR]). Data were compared between groups using the Mann–Whitney *U*-test. Categorical data were compared with the chi-square test or Fisher's exact test where appropriate, with a *p*-value of  $< 0.05$  used for all comparisons.

### Results

Forty-two patients were recruited with 19 randomized to receive sumatriptan and 21 randomized to receive saline (**► Fig. 1**). Two patients randomized to receive sumatriptan were excluded due to surgical complications unrelated to sumatriptan. Both groups had similar demographics, comorbidities, and anesthesia management (**► Table 1**).

The QoR-40 score was higher for patients who received sumatriptan (median 173; IQR 156–196) compared to placebo (median 148; IQR 139–181); however, this was not statistically significant ( $p = 0.055$ ) (**► Table 2**). Furthermore, the individual domains of the QoR-40 score were also not statistically significant. Postoperative opioid use was lower but not statistically significant ( $p = 0.71$ ) between patients who received sumatriptan and placebo, 5.4 versus 5.6 mg morphine equivalent, respectively (**► Table 3**). The difference in severity of headache was also not statistically different between the two groups ( $p = 0.155$ ).



**Fig. 1** Flow diagram of study participants. *n* – number.

With regards to adverse side effects of sumatriptan, none of the patients had significant changes in blood pressure in the first 24 hours. Similarly, there were no new cerebral infarcts in the CT scan before discharge from the hospital and during the 3-month follow-up period.

### Discussion

This study shows that in minimally invasive craniotomy for aneurysm clipping, subcutaneous sumatriptan had a trend toward improved postoperative recovery, postoperative opioid use, and headache severity over placebo; however, none of the outcomes show statistical significance.

The exact mechanism for postcraniotomy headache has not been well established and several mechanisms have been described.<sup>9</sup> Somatic pain can arise from the physical disruption of the neural supply of the scalp such as the cervical plexus and trigeminal nerve from incision and traction during the surgery.<sup>6,9,10</sup> Generalized diffuse headache can originate from the dura due to direct incision of the dura, dural tension, and adherence of the cervical muscles to the dura.<sup>9,10</sup> Furthermore, loss of CSF and aseptic meningitis have also been described to contribute.<sup>6</sup> It is also found that several other inflammatory/nociceptive mediators can further regulate the type, origin, and intensity of the pain.<sup>9</sup>

**Table 1** Patient demographics

	Group 1 Sumatriptan (N = 19)	Group 2 Placebo (N = 21)	p-Value
Age (y)	57.2 ± 8.4	50.7 ± 9.1	0.025 <sup>a</sup>
Gender (male:female)	4:15 (21%:79%)	5:16 (24%:75%)	0.834
BMI (kg/m <sup>2</sup> )	26.9 ± 6.9	27.1 ± 7.8	0.900
Comorbidities			
Cardiovascular	10 (53%)	11 (47%)	0.752
Respiratory	8 (42%)	8 (38%)	0.796
Endocrine	4 (21%)	3 (14%)	0.574
Smoker	8 (42%)	10 (48%)	0.726
Disease characteristics			
Previous surgery	16 (84%)	15 (71%)	0.334
Neurological deficit	8 (42%)	7 (33%)	0.567
Side of surgery			
Right	11 (58%)	7 (33%)	0.119
Left	8 (42%)	14 (67%)	0.752
Location of aneurysm			
MCA	11 (58%)	10 (48%)	0.574
ACOM	3 (16%)	4 (19%)	0.726
PCOM	5 (26%)	7 (33%)	
Intraoperative management			
Fentanyl (µg)	167 ± 91	165 ± 64	0.892
Propofol (mg)	386 ± 622	277 ± 84	0.081
Rocuronium (mg)	51 ± 12	61 ± 16	0.066
Fluids given (mL)	1389 ± 737	893 ± 889	0.076
Blood loss (mL)	61 ± 98	83 ± 133	0.818

Abbreviations: ACOM, anterior communicating artery; BMI, body mass index; MCA, middle cerebral artery; PCOM, posterior communicating artery. Note: Data are shown as numbers (%) and mean ± standard deviation.

**Table 2** QoR-40 scores in different dimensions

QoR-40 score dimensions	Group 1 Sumatriptan (n = 19)	Group 2 Placebo (n = 21)	p-Value
Physical comfort	52 [43–56]	51 [40–53]	0.147
Emotional state	40 [34–45]	39 [29–42]	0.147
Physical independence	20 [18–25]	18 [14–20]	0.062
Patient support	35 [32–35]	34 [31–35]	0.364
Pain	35 [31–35]	31 [24–33]	0.159
Total score	173 [156–196]	148 [139–181]	0.055

Abbreviation: QoR-40, Quality of Recovery 40. Note: Values are in median [interquartile range].

Sumatriptan is typically used to treat acute migraines and it is believed to reduce headache through serotonin-receptor antagonist mechanism.<sup>4,7</sup> It is a selective agonist for serotonin (5-HT<sub>1B</sub> and 5-HT<sub>1D</sub>) on sensory nerves of the trigeminal nerve and can cause vasoconstriction of intracranial dural vessels directly or through vasoactive peptides (GCRP).<sup>11</sup> Furthermore, sumatriptan has also been used successfully to treat headaches caused by subarachnoid hemorrhage<sup>12</sup> and aseptic meningitis by blocking presynaptic meningeal inflammation and inhibiting transmission of nociceptive impulses from inflamed meninges to trigeminal-

nuclear complex.<sup>13</sup> It has been hypothesized that following craniotomy and breaching the dura and leptomeninges, sumatriptan might have an anti-CGRP effect and thus contribute to decreasing the activation of the trigeminovascular system.<sup>14</sup>

The use of sumatriptan has been studied previously for microvascular decompression for trigeminal neuralgia<sup>6</sup> and craniotomy for supratentorial tumor resection.<sup>5</sup> Both these studies showed that sumatriptan was safe and effective at reducing postcraniotomy headaches.<sup>5,6</sup> Looking at our data, we see that our study's placebo group showed higher QoR-40

**Table 3** Opioid consumption and headache score

	Group 1 Sumatriptan (n = 19)	Group 2 Placebo (n = 21)	p-Value
PACU opioid use (mg morphine equivalent)	1.34 ± 2.61	0.71 ± 1.42	0.745
Ward opioid use (mg morphine equivalent)	4.05 ± 5.33	4.93 ± 6.15	0.655
Total opioid use (mg morphine equivalent)	5.40 ± 5.05	5.64 ± 7.22	0.715
Headache score (scale 1–5; 5 none of the time, 1 all the time)	5 [4–5]	4 [2–5]	0.155

Abbreviation: PACU, postanesthetic care unit.

Note: Long-acting opioid use (mg morphine equivalent) and headache score (median [interquartile range]).

scores than the microvascular decompression study's placebo group (133 vs. 148), which indicates a higher quality of recovery. The increase in the placebo group's quality recovery may have accounted for the failure to achieve statistical significance. This increase in quality of recovery may have been due to the difference in the mechanism of postcraniotomy headache between the two procedures. Another possible explanation could be the difference in surgical approach between the two procedures with different muscle groups that were surgically disrupted. Patients who had frontal craniotomy described less pain than those with frontotemporal, temporal, parietal, and occipital craniotomies<sup>15</sup> and the difference in postoperative pain is likely related to the size of the muscle group involved. Minimally invasive craniotomies for aneurysms are typically frontal craniotomies<sup>1</sup> while microvascular decompressions are typically rectosigmoid craniotomies.<sup>16</sup> Furthermore, the difference in CSF loss, where more CSF may have been lost during microvascular decompression, may have also contributed to the increase in quality of recovery for aneurysm clipping.<sup>17,18</sup>

Sumatriptan has a direct effect on the vascular smooth muscle resulting in vasoconstriction.<sup>7</sup> Hence, there is a risk of coronary, renal, and cerebral vasoconstriction and ischemia with sumatriptan administration. Although there are reports of cerebrovascular events after sumatriptan use, studies have shown that triptan treatment is not associated with an increased risk of stroke, even in the setting of overuse.<sup>19,20</sup> A review of data from the Intensive Medicines Monitoring Programme in New Zealand identified a small number of cerebrovascular events, at a rate of 1 per 1,000 patients.<sup>21</sup> The U.S. Food and Drug Administration (FDA) drug safety data on sumatriptan states that "Cerebrovascular events have occurred in patients treated with triptan drugs. However, in several cases, it appears that the cerebrovascular events were primary, the triptan drugs having been administered in the incorrect belief that the symptoms experienced were a consequence of migraine when they were not."<sup>22</sup> Further, the FDA recommends that sumatriptan injection is contraindicated in patients with a history of stroke or TIA. In our study, we excluded patients who had previous coronary, cerebral, renal, and peripheral vascular diseases. Further, all patients were monitored for 24 hours for coronary or cere-

bral ischemia. None of the patients had hemodynamic changes with sumatriptan and there were no cerebral infarcts in the postoperative imaging.

The study has some limitations. First, postcraniotomy headache and pain are multifactorial and can be acute (early) and chronic (late). Hence, it is difficult to differentiate between different types of postcraniotomy headaches. However, in this study, we only looked at the immediate postoperative phase. Though this study showed expanding indications for the CGRP inhibitory effect of sumatriptan, this study targets only immediate postoperative pain, which makes it difficult to measure CGRP, and hence the study is still incomplete, and its validity is still questionable. A second limitation of the study is the inability to differentiate surgical site pain and postcraniotomy headache. We attempted to minimize this by explaining the difference to the patient during the informed consent process and asking the patient to localize the location of the pain in the PACU; however, this can still be a confounder of this study. Third, the initial sample size was estimated using numbers from a previous study<sup>5</sup> to 21 in each arm. Due to the baseline higher QoR-40 score in our placebo group, leading to a decrease in the effect size, this study was likely not adequately powered. Furthermore, this study would also have been not adequately powered for the secondary measure such as total opioid use and headache scores. We believe that large randomized controlled multicenter studies are needed to evaluate the safety and efficacy of sumatriptan after craniotomy for clipping of unruptured aneurysms. Finally, the vasoconstrictive effect of sumatriptan might affect the scalp blood flow and hence the wound healing. However, wound healing was not assessed in this study. Since the study period was only 24 hours, wound assessment was not part of the study. To our knowledge, there were no patients who presented for wound washout and debridement because of poor wound healing within 3 months after the surgery.

## Conclusion

In conclusion, in patients undergoing minimally invasive craniotomies for aneurysm clipping, sumatriptan given postoperatively has a shred of weak evidence for a trend for a

higher quality of recovery. Similarly, there was a trend toward lower headache scores and opioid scores for the patient given sumatriptan. Further research is required to determine which intracranial surgery is sumatriptan most effective at reducing headaches.

#### Note

Postcraniotomy headaches are often underestimated and undertreated and have an incidence of 70 to 90%. This study shows that in minimally invasive craniotomy for aneurysm clipping, subcutaneous sumatriptan had a trend toward improved postoperative recovery, postoperative opioid use, and headache severity over placebo. Further research is required to determine which intracranial surgery is sumatriptan most effective at reducing headaches.

#### Ethical Approval

UHN REB # 12-0139-B, 15<sup>th</sup> July 2013.

TRIAL REGISTRATION: <http://clinicaltrials.gov>; registration ID NCT01632657.

#### Funding

This study was funded by Canadian Anesthesiology Society Research Award in Neuroanesthesia in memory of Adrienne Cheng.

#### Conflict of Interest

None declared.

#### References

- Pierot L, Gawlitza M, Soize S. Unruptured intracranial aneurysms: management strategy and current endovascular treatment options. *Expert Rev Neurother* 2017;17(10):977–986
- Wong JHY, Tymianski R, Radovanovic I, Tymianski M. Minimally invasive microsurgery for cerebral aneurysms. *Stroke* 2015;46(09):2699–2706
- Rocha-Filho PAS, Gherpelli JLD, de Siqueira JTT, Rabello GD. Postcraniotomy headache: characteristics, behaviour and effect on quality of life in patients operated for treatment of supratentorial intracranial aneurysms. *Cephalalgia Int J Headache* 2008;28(01):41–48
- Patel KS, Laiwalla AN, DiCesare JAT, Garrett MC, Wang AC. Subcutaneous sumatriptan: association with decreases in postoperative pain and opioid use after elective cranial surgery. *J Neurosurg* 2020;1:1–9
- Venkatraghavan L, Li L, Bailey T, Manninen PH, Tymianski M. Sumatriptan improves postoperative quality of recovery and reduces postcraniotomy headache after cranial nerve decompression. *Br J Anaesth* 2016;117(01):73–79
- Rocha-Filho PAS. Post-craniotomy headache: a clinical view with a focus on the persistent form. *Headache* 2015;55(05):733–738
- De Felice M, Ossipov MH, Wang R, et al. Triptan-induced enhancement of neuronal nitric oxide synthase in trigeminal ganglion dural afferents underlies increased responsiveness to potential migraine triggers. *Brain* 2010;133(Pt 8):2475–2488
- Gornall BF, Myles PS, Smith CL, et al. Measurement of quality of recovery using the QoR-40: a quantitative systematic review. *Br J Anaesth* 2013;111(02):161–169
- Chowdhury T, Garg R, Sheshadri V, et al. Perioperative factors contributing the post-craniotomy pain: a synthesis of concepts. *Front Med (Lausanne)* 2017;4:23
- Molnár L, Simon É, Nemes R, Fülesdi B, Molnár C. Postcraniotomy headache. *J Anesth* 2014;28(01):102–111
- Asgar MS, Hansen AE, Kapijimpanga T, et al. Dilation by CGRP of middle meningeal artery and reversal by sumatriptan in normal volunteers. *Neurology* 2010;75(17):1520–1526
- Rosenberg JH, Silberstein SD. The headache of SAH responds to sumatriptan. *Headache* 2005;45(05):597–598
- Prokhorov S, Khanna S, Alapati D, Pallimalli SL. Subcutaneous sumatriptan relieved migraine-like headache in two adolescents with aseptic meningitis. *Headache* 2008;48(08):1235–1236
- Licina A, Russell J, Silvers A, Jin X, Denny J. Subcutaneous sumatriptan for the treatment of postcraniotomy pain (SUPS trial): protocol for a randomised double-blinded placebo controlled trial. *BMJ Open* 2019;9(08):e032388
- Thibault M, Girard F, Moumdjian R, Chouinard P, Boudreault D, Ruel M. Craniotomy site influences postoperative pain following neurosurgical procedures: a retrospective study. *Can J Anaesth* 2007;54(07):544–548
- Jannetta PJ, McLaughlin MR, Casey KF. Technique of microvascular decompression. Technical note. *Neurosurg Focus* 2005;18(05):E5
- Teo MK, Eljamel MS. Role of craniotomy repair in reducing postoperative headaches after a retrosigmoid approach. *Neurosurgery* 2010;67(05):1286–1291
- de Gray LC, Matta BF. Acute and chronic pain following craniotomy: a review. *Anaesthesia* 2005;60(07):693–704
- Hall GC, Brown MM, Mo J, MacRae KD. Triptans in migraine: the risks of stroke, cardiovascular disease, and death in practice. *Neurology* 2004;62(04):563–568
- Wammes-van der Heijden EA, Rahimtoola H, Leufkens HG, Tijssen CC, Egberts AC. Risk of ischemic complications related to the intensity of triptan and ergotamine use. *Neurology* 2006;67(07):1128–1134
- Cerebrovascular events with sumatriptan. Accessed January 10, 2024 at: <https://www.medsafe.govt.nz/profs/PUarticles/sumatriptan.htm>
- Highlights of prescribing information on Sumatriptan. Accessed January 10, 2024 at: [https://www.accessdata.fda.gov/drugsatfda\\_docs/label/2021/020080s0541bl.pdf](https://www.accessdata.fda.gov/drugsatfda_docs/label/2021/020080s0541bl.pdf)