



Microneurosurgery for Ruptured Aneurysm of Distal Intracranial Vertebral Artery: A Case Report

Tushar V. Soni¹ Shreyansh Patel¹  Varshesh Shah¹ Sandip Singh¹ Nirav Shah¹

¹Department of Neurosurgery, Smt. NHL Municipal Medical College, Ahmedabad, Gujarat, India

Address for correspondence Shreyansh Patel, Resident Doctor, MCh Neurosurgery, Department of Neurosurgery, Smt. NHL Municipal Medical College, Ahmedabad, Gujarat, 380006, India (e-mail: shreyanshpatel1110@gmail.com).

Asian J Neurosurg

Abstract

The International Subarachnoid Aneurysm Trial led to a shift from clipping to endovascular coiling as the primary therapy for cerebral aneurysm particularly in the management of posterior circulation aneurysm. However, endovascular therapy is often unavailable in low-resource settings, emphasizing the importance of maintaining surgical skill sets in resource-poor countries. This article presents a detailed case report on the successful microneurosurgical management of a 65-year-old female with a history of headache and weakness with past history of hypertension and a right posterior cerebral artery territory infarct who was diagnosed with a ruptured aneurysm situated within the intracranial vertebral artery. Patient was operated with the far lateral approach and clipping of the aneurysm. This case report elucidates the intricate surgical techniques employed, and the challenges neurosurgeons encountered in treating posterior circulation intracranial aneurysms, particularly those with ruptured complications. The aneurysms' intricate anatomy and increased rupture risk necessitate a meticulous microneurosurgical approach. The severity of subarachnoid hemorrhage from ruptured aneurysms increases morbidity and mortality rates.

Keywords

- ▶ vertebral artery
- ▶ subarachnoid hemorrhage
- ▶ microneurosurgery
- ▶ endovascular coiling
- ▶ far lateral approach

Introduction

Approximately 0.19 to 1.5% of the general population is affected by posterior circulation intracranial aneurysm. Among these aneurysms, the basilar apex is the most common location, representing around 10% of all intracranial aneurysms.¹ Vertebral artery (VA) aneurysms constitute 0.5 to 3% of intracranial aneurysms and 20% of posterior circulation aneurysms.² The treatment of posterior circulation aneurysms poses significant challenges due to the intricate anatomy of the brainstem and cranial nerves, as well as the increased likelihood of rupture compared to anterior circulation aneurysms.¹ The unique anatomical location of these

aneurysms, coupled with their potential life-threatening ramifications, necessitates a meticulous microneurosurgical approach. The surgical management of these aneurysms is compounded by the inherent difficulty in approach, further exacerbated by the relative lack of experience among neurosurgeons due to their infrequency. Consequently, surgical intervention for posterior circulation aneurysms is associated with higher rates of morbidity and mortality compared to anterior circulation aneurysms.¹ The severity of subarachnoid hemorrhage (SAH) resulting from ruptured aneurysms amplifies the clinical challenge, with grim prognostic implications. Half of the patients succumb to the hemorrhage within 1 month, and among those who survive beyond this

DOI <https://doi.org/10.1055/s-0044-1786704>.
ISSN 2248-9614.

© 2024. Asian Congress of Neurological Surgeons. All rights reserved.

This is an open access article published by Thieme under the terms of the Creative Commons Attribution-NonDerivative-NonCommercial-License, permitting copying and reproduction so long as the original work is given appropriate credit. Contents may not be used for commercial purposes, or adapted, remixed, transformed or built upon. (<https://creativecommons.org/licenses/by-nc-nd/4.0/>)

Thieme Medical and Scientific Publishers Pvt. Ltd., A-12, 2nd Floor, Sector 2, Noida-201301 UP, India

critical period, 40% of patients face a persistent state of dependency.² The urgency of these cases is underscored by the fact that approximately 15% of patients with aneurysmal SAH do not survive to reach the hospital.³

Case Presentation

A 65-year-old female presented to the Neurosurgery Department with a history of headache and generalized weakness for 10 days. Relatives reported a preceding episode of seizure followed by an unconsciousness lasting 10 to 15 minutes 20 days ago, and a subsequent episode of giddiness resulting in a fall in the bathroom 13 days ago. Patient was managed conservatively at another hospital for history of seizures and giddiness; on further work-up, she was diagnosed with ruptured aneurysm located in the V4 segment of the right VA. Consequently, the patient was referred to our hospital for further intervention. The patient's medical history includes hypertension for the last 10 years on treatment and history of right posterior cerebral artery territory infarct 4 years ago. Upon presentation, the patient was hemodynamically stable, with a pulse rate of 90 beats per minute, blood pressure measuring 160/90 mmHg, and an oxygen saturation level of 94% on room air. Her neurological status, as assessed by the Glasgow Coma Scale, was 14/15. Pupillary examination revealed bilateral 3 mm pupils reacting to light. Power in the upper limbs was graded as 4– on the Medical Research Council (MRC) scale bilaterally, while the power in the lower limbs was graded as 4 MRC. Bilateral plantar reflexes were elicited as downgoing. Prior imaging conducted at the referring institute consisted of a Plain + Contrast magnetic resonance imaging of the brain, indicating acute intraventricular hemorrhage with SAH and variable age lacunar infarcts. Subsequent computed tomography (CT) cerebral angiography further delineated the vascular pathology, identifying a saccular aneurysm in the distal V4 segment of the right VA with a lateral orientation (→Figs. 1 and 2). The SAH was classified as Hunt and Hess Scale 3, and Modified Fischer CT Grade 2 at the time of presentation to our institute. The complex clinical scenario emphasizes the critical nature of timely and comprehensive management in addressing the underlying vascular pathology and associated sequelae. Classic Hockey stick incision begins at the level of the C3 spinous process and ascends along the midline aponeurosis (avascular area) until reaching 2 cm superior to the nuchal line, curving laterally and parallel to the superior nuchal line and then inferiorly to approach the mastoid tip. The suboccipital musculature was cut and retracted in a single bundle inferolaterally. The spinous processes of C1 and C2 are identified, followed by the C2 lamina and the C1 posterior arch. Right lateral suboccipital craniotomy, extended to the posterolateral edge of the foramen magnum until the posteromedial tip of the occipital condyle, and a C1 hemilaminectomy were done. VA was mobilized and proximal control taken. The dura opened in a curved fashion centered on the region extending from the VA entrance to the jugular tubercle. Intracranial segment of VA along with aneurysm was identified. Proximal control was taken using a temporary clip (→Fig. 3). Aneurysm

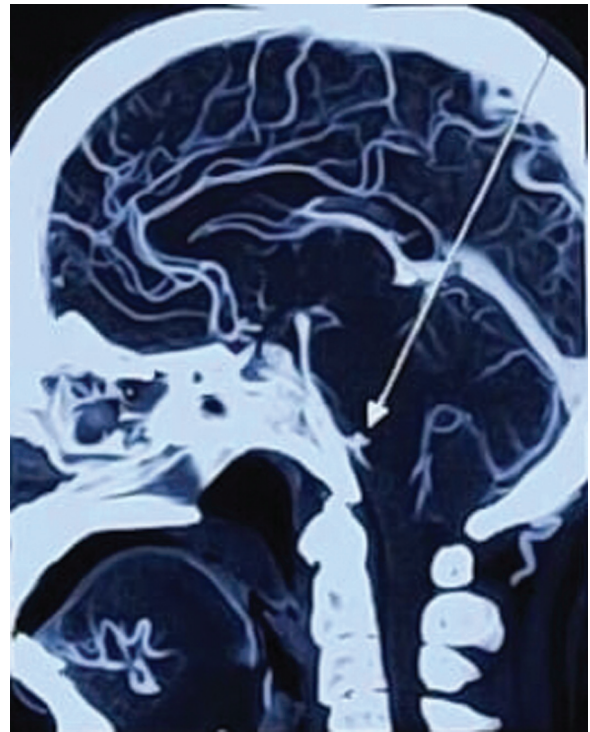


Fig. 1 Intracranial vertebral artery aneurysm: sagittal section.

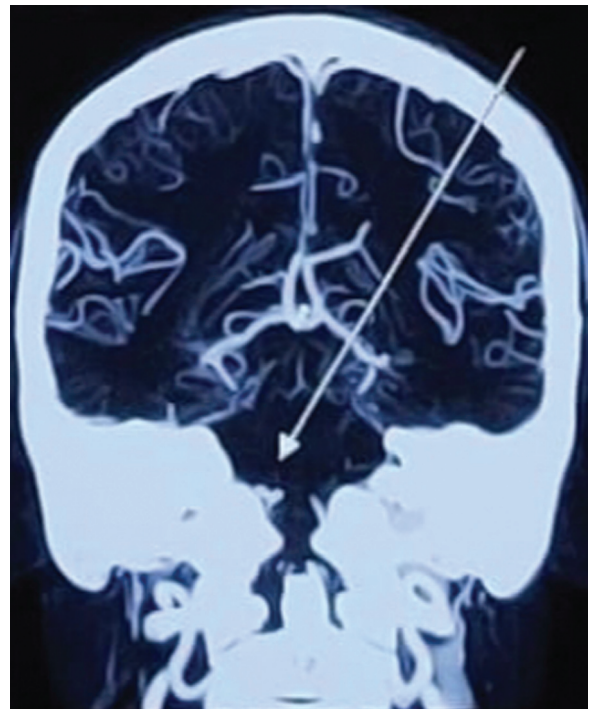


Fig. 2 Intracranial vertebral artery aneurysm: coronal section.

neck was dissected using corridor afforded and permanent clip applied at the neck of an aneurysm (→Fig. 4). Distal patency was checked. Temporary clip was removed. Dura was closed in a water-tight manner. Skin incision was closed in layers (→Figs. 5 and 6). Postoperative imaging studies, including CT angiography, demonstrated adequate clipping

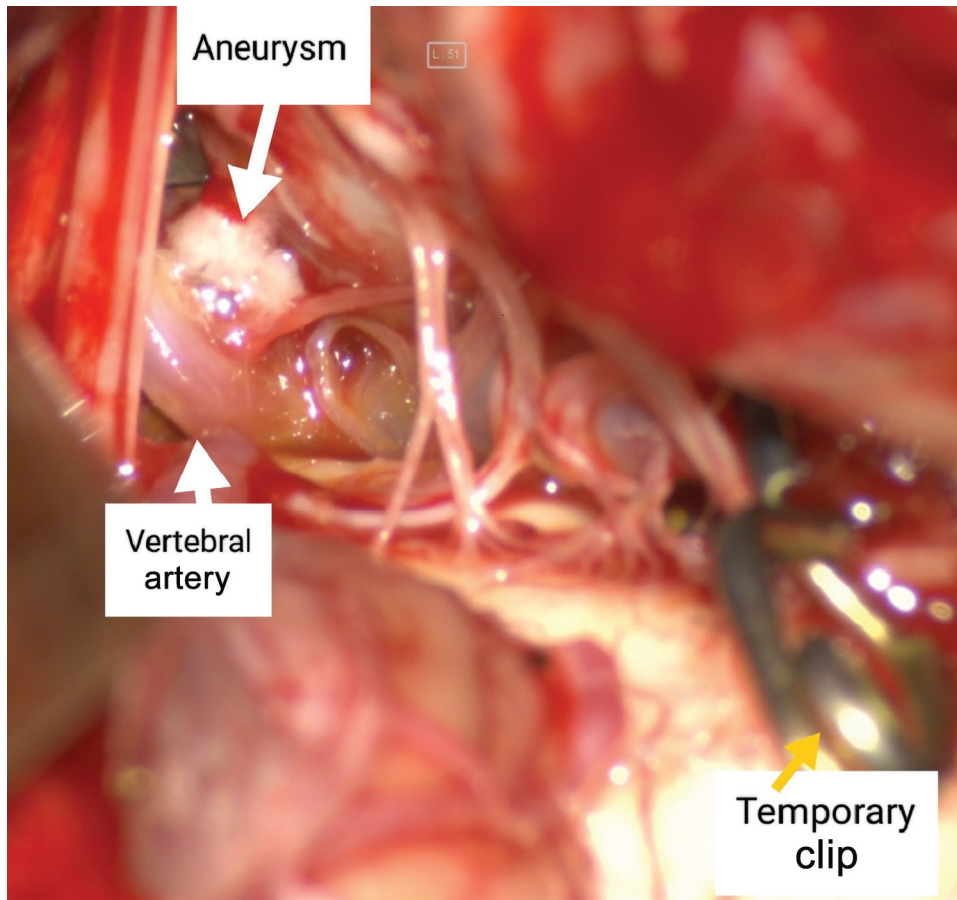


Fig. 3 Intraoperative image of vertebral artery aneurysm after application of temporary clip.

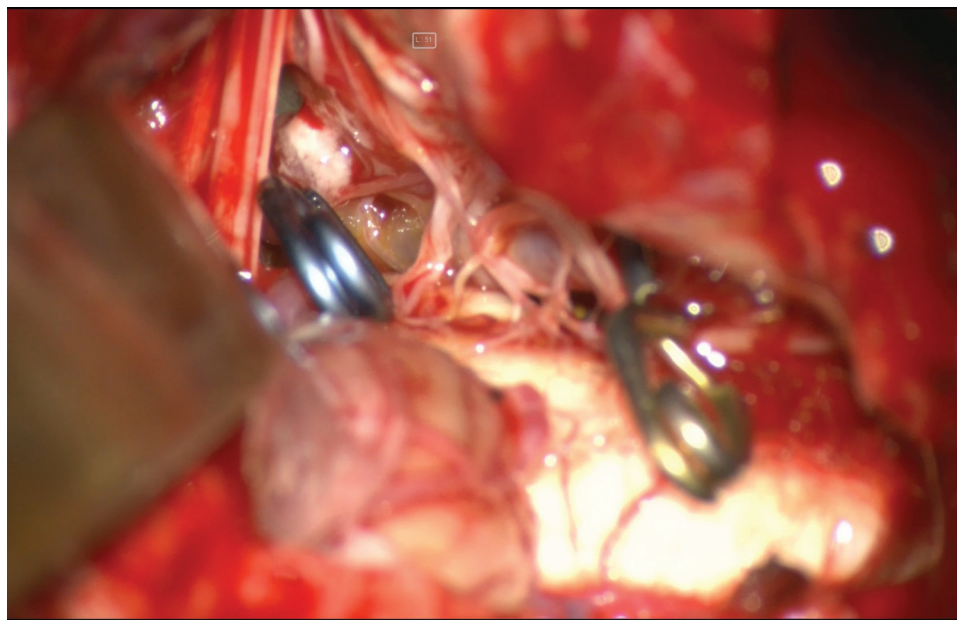


Fig. 4 Intraoperative image of permanent clip and temporary clip in situ.

of the aneurysm with patent distal flow in the VA. There were no signs of acute infarction or hemorrhage on imaging, and the surgical site appeared well-healed without evidence of complications such as infection or cerebrospinal fluid leak-

age. The patient exhibited a favorable postoperative course. Initially the patient was kept in the Neuro Intensive Care Unit where close monitoring of vital signs was done and regular neurological assessments conducted. In the course of

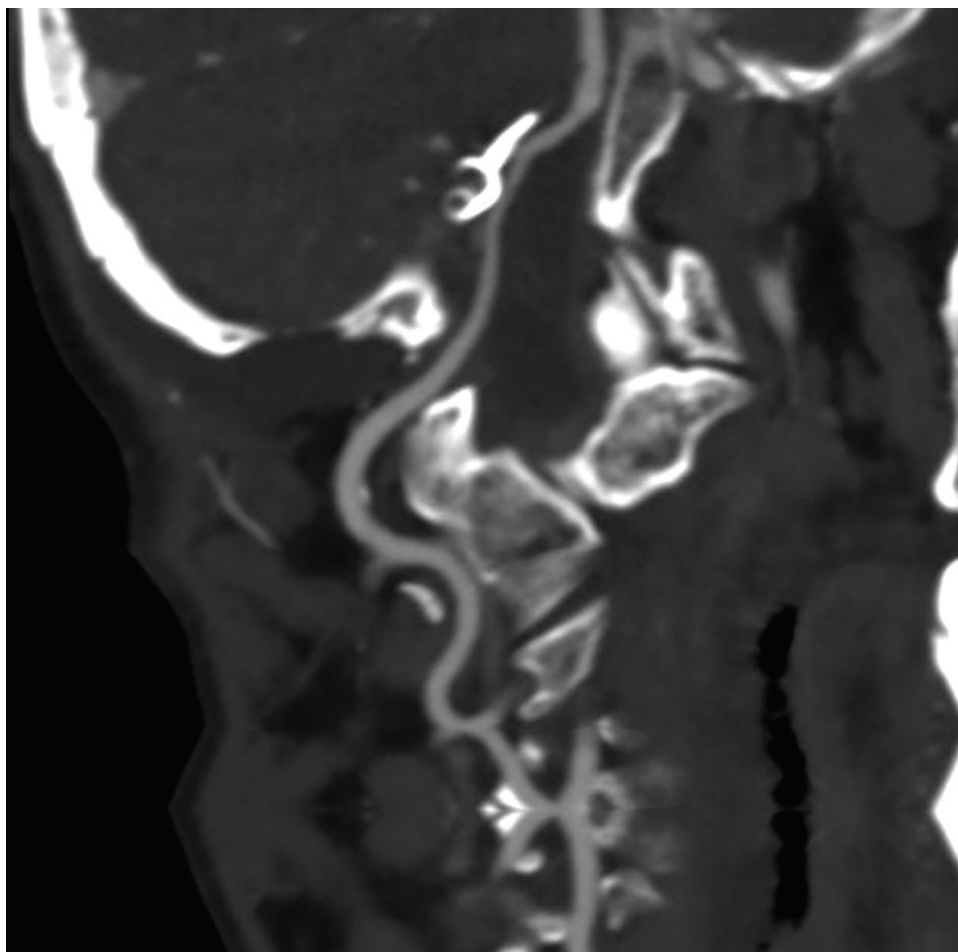


Fig. 5 Postoperative image with patent distal flow of vertebral artery with permanent clip in situ: right lateral view.

treatment due to development of lower cranial nerve deficit leading to poor cough and gag reflex and for the better management of respiratory status, the patient was tracheostomized. Upon completion of the hospital course, the patient was discharged with appropriate postoperative care instructions and medications to optimize recovery. Close follow-up appointments were scheduled to monitor the patient's progress and ensure optimal management of her underlying medical conditions, including hypertension and the history of cerebral infarction.

Discussion

In the presented case, the patient experienced the rupture of an intracranial portion of a VA aneurysm. VA aneurysms are relatively uncommon, comprising 0.5 to 3% of all intracranial aneurysms. The spectrum of these aneurysms includes VA-PICA (posterior inferior cerebellar artery) aneurysms, vertebrobasilar junction aneurysms, distal PICA aneurysms, and those located along the distal VA. Notably, two-thirds of these aneurysms are situated on the intracranial VA adjacent to the origin of the PICA. Instances of distal VA aneurysms and giant aneurysms in this specific location are considered rare.⁴⁻⁶ The primary modality of treatment for intracranial VA aneurysms, including those in the distal VA, remains

microsurgical clipping of the neck—a standard approach applied to all intracranial aneurysms.⁷ However, ruptured posterior circulation aneurysms, due to their intricate location, pose technical challenges in exposure and clipping. Endovascular treatment is being preferred over clipping for the treatment of both ruptured and unruptured cerebral aneurysms. The diagnosis of incidental unruptured aneurysms is witnessing a significant rise. Mortality rates for ruptured aneurysms are showing improvement irrespective of the treatment method used, while mortality rates for unruptured aneurysms are only improving with surgical clipping.⁸ Consequently, the management of these aneurysms and the surgical outcomes associated with their treatment tend to be less favorable when compared to anterior circulation aneurysms.⁹ Given the complexity of these cases, proficiency in various skull base approaches becomes imperative to optimize exposure, minimize brain retraction, and enhance overall surgical outcomes. In our case, the far lateral inferior suboccipital approach, as originally described by Heros,¹⁰ was employed. This surgical technique proved highly effective, providing an excellent exposure that facilitated successful clipping of the aneurysms with minimal brain retraction. The far lateral approach, an inferolateral extension of the lateral suboccipital approach, was initially designed for aneurysms situated at the vertebrobasilar

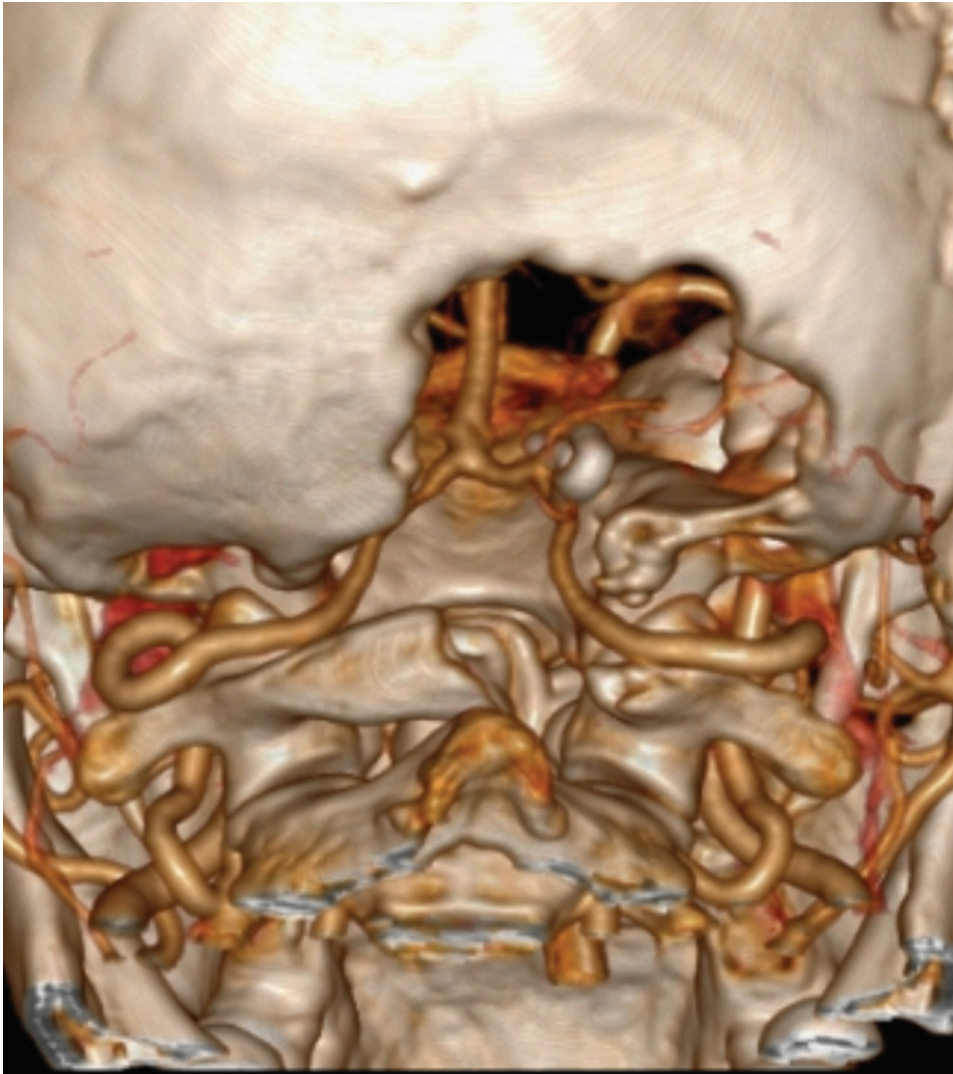

Fig. 6 Postoperative three-dimensional reconstructed image of craniectomy with C1 hemilaminectomy with aneurysm clip in situ.

junction and proximal segments of the PICA. Over time, it has evolved into a versatile approach, widely utilized for addressing ventral foramen magnum meningiomas and other intradural lesions located anterior to the dentate ligament.⁵ Regarding the total group of patients in both ruptured and unruptured, in terms of operative mortality and late mortality, there was no superiority of the coiling over clipping. It is not the first time that surprisingly concluded no superiority of one method over the other in terms of mortality, studying posterior circulation intracranial aneurysms.¹¹ Clipping appears to outperform coiling in terms of the need for further intervention among the entire patient cohort. The long-term findings of the International Subarachnoid Aneurysm Trial (ISAT) offer valuable insights, indicating that the rate of rebleeding is significantly higher in patients with recurrent aneurysms (due to incomplete coiling) compared to those with complete occlusion of their aneurysms. Moreover, the mortality rate following rebleeding is substantially elevated at 70%.¹² Typically, it appears that younger individuals tend to experience greater advantages when utilizing microsurgical techniques, as they yield

superior long-term outcomes, taking into account the necessity for further intervention.¹³ Patients with ruptured intracranial aneurysms who are eligible for either endovascular coiling or neurosurgical clipping have a higher likelihood of achieving independent survival at the 1-year mark with endovascular coiling. This survival advantage persists for a minimum of 7 years. Although the risk of late rebleeding is relatively low, it is more prevalent following endovascular coiling compared to neurosurgical clipping.¹² Despite the inherent challenge of dissection amid the rootlets of lower cranial nerves, leading to transient lower cranial nerve paresis, the overall outcomes of the far lateral approach in this case were deemed satisfactory, emphasizing its efficacy in managing complex cases of ruptured VA aneurysms.

Conclusion

In the era of modernization of technology and after publication of ISAT and in post-ISAT era, endovascular therapy is becoming the primary modality of treatment for management of cerebral aneurysm especially in posterior circulation

aneurysm. However, endovascular therapy is frequently unavailable in low-resource countries, emphasizing the necessity of maintaining surgical skill sets to address aneurysm microsurgically. This case report highlights the successful microneurosurgical management of a ruptured distal VA aneurysm. Utilizing the far lateral approach, we effectively addressed the challenges associated with the intricate anatomy of posterior circulation aneurysms, emphasizing the importance of maintaining surgical skill sets in resource-limited settings where endovascular therapy may not be readily available. While acknowledging the advancements in endovascular intervention technology, this case report underscores the ongoing relevance of microsurgical techniques, particularly in cases where endovascular therapy may not be feasible or affordable. This case report contributes to the growing body of literature on the management of posterior circulation aneurysms, highlighting the significance of a multidisciplinary approach in optimizing patient outcomes. Moving forward, further research and collaboration are needed to continue advancing understanding and refining treatment strategies for complex cerebrovascular pathologies. By integrating evolving technologies with established surgical expertise, a neurosurgeon can strive to improve patient care and outcomes, particularly in underserved regions where access to advanced medical interventions may be limited.

Conflict of Interest

None declared.

References

- 1 Bonneville F, Sourour N, Biondi A. Intracranial aneurysms: an overview. *Neuroimaging Clin N Am* 2006;16(03):371–382, vii
- 2 Ausman JI, Sadasivan B. Posterior inferior cerebellar artery vertebral artery aneurysms. In: Apuzzo MLJ, ed. *Brain Surgery: Complication Avoidance and Management*. New York: Churchill Livingstone; 1993:1879–1894
- 3 Hop JW, Rinkel GJ, Algra A, van Gijn J. Case-fatality rates and functional outcome after subarachnoid hemorrhage: a systematic review. *Stroke* 1997;28(03):660–664
- 4 Schievink WI, Wijdicks EF, Parisi JE, Piepgras DG, Whisnant JP. Sudden death from aneurysmal subarachnoid hemorrhage. *Neurology* 1995;45(05):871–874
- 5 Day DJ, Giannotta SL. Surgical management of vertebral-PICA aneurysms. In: Schmidek HH, Sweet WH, eds. *Operative Neurosurgical Techniques*. Philadelphia: WB Saunders Company; 1995: 1103–1111
- 6 Kurokawa Y, Okamura T, Watanabe K. Transcerebellar thrombectomy for the successful clipping of thrombosed giant vertebral artery–posterior inferior cerebellar artery aneurysm: case report. *Surg Neurol* 1990;33(03):217–220
- 7 Nichols DA, Brown RD Jr, Thielen KR, Meyer FB, Atkinson JL, Piepgras DG. Endovascular treatment of ruptured posterior circulation aneurysms using electrolytically detachable coils. *J Neurosurg* 1997;87(03):374–380
- 8 Luther E, McCarthy DJ, Brunet M-C, et al. Treatment and diagnosis of cerebral aneurysms in the post-International Subarachnoid Aneurysm Trial (ISAT) era: trends and outcomes. *J Neurointerv Surg* 2020;12(07):682–687
- 9 Madsen JR, Heros RC. Giant peripheral aneurysm of the posterior inferior cerebellar artery treated with excision and end-to-end anastomosis. *Surg Neurol* 1988;30(02):140–143
- 10 Heros RC. The far lateral inferior suboccipital approach. In: Wilkins RH, Rengachary SS, eds. *Neurosurgery*. New York: McGraw-Hill; 1996:2357–2360
- 11 Lai L, Morgan KM. Surgical management of posterior circulation aneurysms: defining the role of microsurgery in contemporary endovascular era. In: Signorelli F, ed. *Explicative Cases of Controversial Issues in Neurosurgery*. . Great Portland Street: London, W1W 5PF, United Kingdom. ISBN: 978–953–51–0623–4; 2012
- 12 Molyneux AJ, Kerr RSC, Birks J, et al; ISAT Collaborators. Risk of recurrent subarachnoid haemorrhage, death, or dependence and standardised mortality ratios after clipping or coiling of an intracranial aneurysm in the International Subarachnoid Aneurysm Trial (ISAT): long-term follow-up. *Lancet Neurol* 2009;8(05):427–433
- 13 Tsiانaka E, Al-Shawish A, Potapov A, Fountas K, Spyrou M, Kononov N. Clipping versus coiling in posterior circulation intracranial aneurysms: a meta-analysis. *Chin Neurosurg J* 2019;5:16