



Utility of Fat Grafting in Chronic Wounds

Om Prakash¹ Sheikh Sarfraz Ali¹ Mohd Yaseen¹ Indrajith K. Sudhy¹ Pavan K. Venkateshwar¹
Y. Ranga Kishore¹

¹Department of Plastic Surgery, Jawaharlal Nehru Medical College and Hospital, Aligarh Muslim University, Aligarh, Uttar Pradesh, India

Indian J Plast Surg

Address for correspondence Om Prakash, MCh, Department of Plastic Surgery, Jawaharlal Nehru Medical College and Hospital, Aligarh Muslim University, Aligarh 202002, Uttar Pradesh, India (e-mail: dromktm@gmail.com).

Abstract

Introduction The history of wounds dates back to the evolution of mankind. Throughout the centuries, management modalities of wounds have undergone drastic changes. With the advent of technology, we have multiple options for wound care, but none of them can be called the gold standard of wound care. Autologous fat grafting (AFG) is one of the most routinely performed procedures in aesthetic surgery. Fat grafting has shown beneficial effects in the healing of wounds. The regenerative potential of autologous fat is contributed by the adipose-derived stem cells present within the stromal vascular fraction, which are capable of differentiating into multiple cell types. This study aims to analyze the usefulness of AFG in cutaneous wound healing.

Materials and Methods This prospective, study was conducted in our institute between April 2021 and May 2023. Eighteen patients with nonhealing wounds were included in the study. For assessing wound healing all the patients were first managed with conventional dressing for 2 weeks before surgery. After routine preoperative workup, the procedure was performed under local anesthesia in most cases. Fat was harvested from the lower abdomen and after emulsification, was injected into the edge and floor of the ulcer. The dressing was changed on the third postoperative day and the outcome was assessed.

Results Eighteen patients (M:F ratio 8:1), with a mean age of 35.61 ± 12.64 years (range 10–65 years), were included in this study. The most common etiology was trauma (44%), others being postop infection (17%), veno-lymphatic ulcer (17%), burns (11%), insect bite (5%), and trophic ulcer (5%). Majority of the wounds (95%) healed without the need for any extra intervention. The mean period taken for complete wound healing was 5.05 weeks.

Conclusion Complete wound healing was achieved in majority of the patients without any complications. We recommend the usage of AFG for nonhealing wounds, as the procedure is relatively simple and can be performed after basic training. Larger-scale randomized controlled trials should be conducted to prove their efficacy in the management of complicated wounds.

Keywords

- ▶ fat grafting
- ▶ nonhealing wounds

DOI <https://doi.org/10.1055/s-0044-1787174>.
ISSN 0970-0358.

© 2024. Association of Plastic Surgeons of India. All rights reserved.
This is an open access article published by Thieme under the terms of the Creative Commons Attribution-NonDerivative-NonCommercial-License, permitting copying and reproduction so long as the original work is given appropriate credit. Contents may not be used for commercial purposes, or adapted, remixed, transformed or built upon. (<https://creativecommons.org/licenses/by-nc-nd/4.0/>)
Thieme Medical and Scientific Publishers Pvt. Ltd., A-12, 2nd Floor, Sector 2, Noida-201301 UP, India

Introduction

Wounds can have a profound influence on the daily routine of an individual. Most wounds heal within a certain timeframe, by providing standard wound care measures and by correction of the causative factor. The human body's response to tissue injury in a healthy individual is a complex, but sequential process, that brings about timely wound healing, with full reepithelialization, resolution of pus discharge, and return to normal function of the affected part.

If the wound does not heal within the expected timeframe, it can be quite bothersome to the affected individual. Chronic wounds, however, do not follow this sequence and the healing process often halts in some phase of wound healing, usually in the inflammatory phase, without progression to the next phase.¹ Even though there are no specific guidelines that specify the duration of a wound that defines chronicity, wounds that do not heal or fail to show any signs of healing even after 6 weeks of standard wound care measures are defined as chronic wounds. Patients affected by chronic wounds often suffer from chronic pain, loss of function of the injured part, restriction of mobility, unaccountable stress, and often get isolated from the outer world. Increased financial burden may arise as the affected individuals are often unable to carry on with their livelihood activities.²⁻⁵

For health care providers, often it is a difficult puzzle to solve using conventional wound care measures. As the wounds are becoming more sophisticated, the treating physician's armamentarium should be equipped with more options for wound care. With the evolution of time, management options available for wound care have also increased. But despite all the developments achieved in wound care, we are still unable to define the gold standard modality for wound care.

Autologous fat grafting (AFG) is a routinely performed procedure in plastic surgery. The procedure is preferred for its advantages like versatility, easy harvestability, and negligible donor site morbidity. Contouring of soft tissue defects is the most common application of AFG. Recent studies have demonstrated its clinical applicability for a wider variety of purposes. Of late, there has been increasing interest in the regenerative capabilities of autologous fat. Plenty of research has been done and a lot more studies are still going on worldwide in this subject. The regenerative potential of autologous fat is due to the presence of adipose-derived stem cells (ADSCs) contained within the stromal vascular fraction (SVF).⁶

Cutaneous wound healing is achieved by the differentiation of ADSCs into various terminal cell phenotypes (like keratinocytes, fibroblasts, and endothelial cells).⁶ Growth factors and cytokines that are present within adipocytes promote cell migration, reduce inflammation, and promote angiogenesis subsequently resulting in improved healing of wound.^{7,8} However, to date, there has been no comprehensive evaluation of its efficacy in the healing of chronic wounds.

Given the significant number of patients with chronic nonhealing wounds presenting to our hospital, this study was conducted to analyze the usefulness of AFG in wound healing.

The goal of the study was to analyze the usefulness of AFG in the healing of chronic nonhealing wounds. Complete healing of the wound was considered as the final outcome.

Materials and Methods

Study Design

The study was designed as a prospective study and was performed in our institute which is a tertiary level center. The period of study was from April 2021 to May 2023. The study was designed as a single-surgeon study.

Eighteen patients, who fulfilled the inclusion criteria, were included in the study. Prior approval from the Institutional Ethics Committee was obtained. All the patients were given a detailed description of the procedure and consent was obtained.

Inclusion Criteria

1. Patients of any gender and age (> 5 and < 90 years) with chronic nonhealing wounds.
2. Multiple wounds in the same patient that are more than 5 cm apart were considered as a separate entry.

Patients with comorbid conditions like diabetes, hypertension, and dyslipidemia were included in the study. Patients on antiplatelet agents were taken up for the procedure after seeking a cardiology opinion, then withholding the medication for 5 days before the procedure.

Exclusion Criteria

1. Patients who were not willing for the study
2. Uncooperative patients
3. Ulcers measuring more than 25 cm²
4. Extremes of age (< 5 and > 90 years)
5. Malignant ulcers/suspicious of malignancy
6. Patients with bleeding disorders

For assessing normal innate wound healing in all the patients selected for the study, the study participants were managed with conventional dressing for 2 weeks before surgery. During this period preoperative evaluations were conducted simultaneously. This also helped us to overcome the shortness of having no control group. During this period pus cultures were sent.

All the patients were administered a single shot of cefuroxime as preop antibiotic prophylaxis. We followed the standard fat grafting procedure as described by Coleman. Fat was harvested from a defined donor site usually the lower abdomen, applying negative pressure to extract fat via specially designed fat grafting cannulas. The obtained fat was then centrifuged at 3,000 revolutions per minute for 3 minutes to allow separation of the lipoaspirate (oil layer) and the infranatant (blood, water, and aqueous solution).

After centrifugation, we obtained three separate layers inside the syringe. The topmost layer of oil was absorbed by tissue strips and the lowermost layer was removed by controlled removal of cap of the syringe. After emulsification, fat was transferred from 10 ml syringes to smaller Luer lock

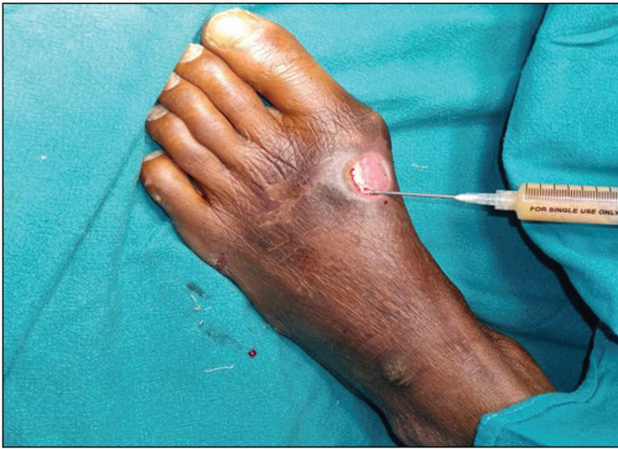

Fig. 1 Fat Injection into wound edges.

syringes, for precise control of the amount of fat to be injected and better handling. The fat graft was injected at the dermal-hypodermal junction at the wound edges (► **Fig. 1**); in addition, fat was injected into the wound bed and occlusive dressings were placed. On average, we injected approximately 1 mL of fat for an area of 2.5 cm². Postprocedure patients were administered a short course of oral cefuroxime irrespective of their previous culture reports.

For a better assessment of wound healing, we used the wound bed score (WBS). The WBS is a noninvasive visual

evaluation score that is used to determine prognosis and changes in the management of wounds. The WBS was devised by Falanga et al. The WBS classification system has scores for eight parameters. Each parameter is given a separate score from 0 (minimum) to 2 (maximum). All individual parameter scores were added for a total score. Each wound can have a maximum score of 16, to a minimum score of 0.⁹ The WBS is a useful tool for evaluating the progression of healing in chronic wounds. In our study, the WBS was recorded twice, initially before AFG and 2 weeks after the procedure.

All the patients were followed up weekly and the progress of wound healing was assessed (► **Figs 2A–D, 3A–C, 4A–C, 5A–D**).

Follow-up visits were continued for a minimum period of 3 months. Complete wound healing was considered the final outcome.

Results

In our study, 18 patients who fulfilled the inclusion criteria were included. One patient had three wounds.

For assessing normal innate wound healing, all the patients were managed with conventional dressing for 2 weeks before surgery. None of the wounds showed any progressive signs of wound healing during this phase.

Postprocedure, the patients were followed up weekly and evaluation of progress was done. The main parameters

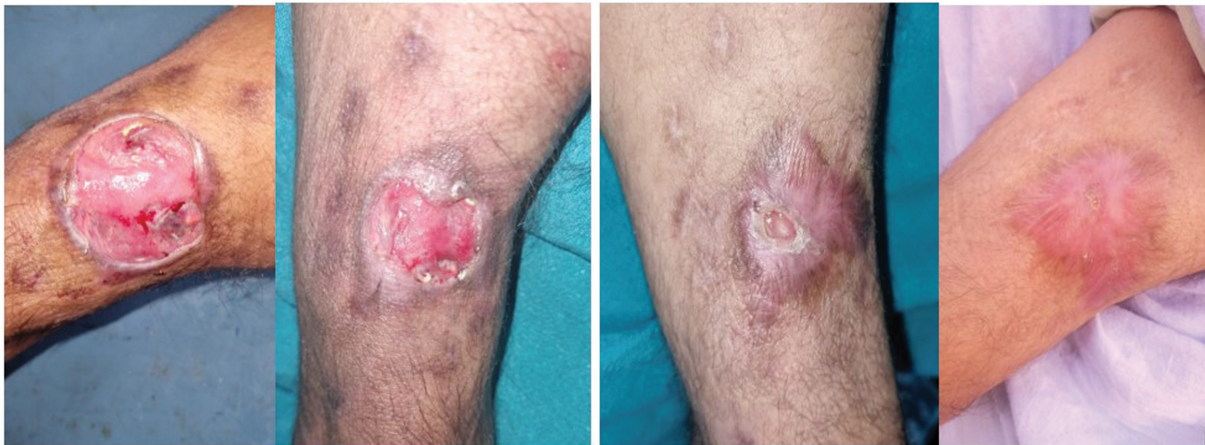


Fig. 2 Patient photograph showing weekly progress of healing.

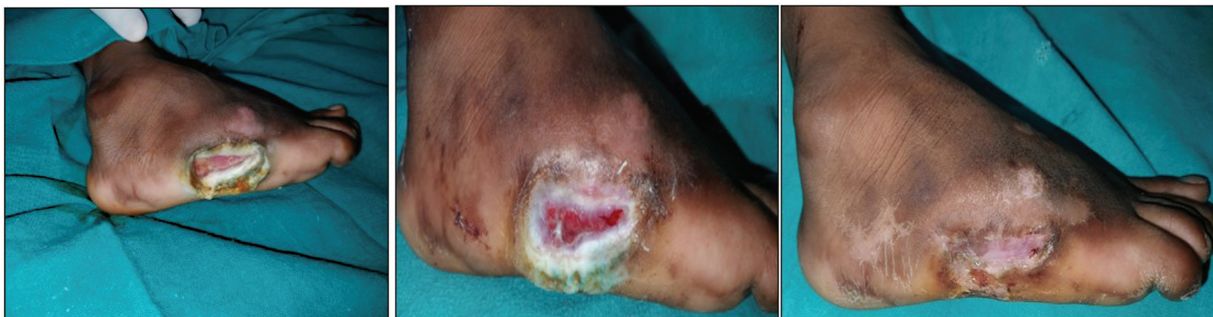

Fig. 3 Patient photograph showing weekly progress of healing.

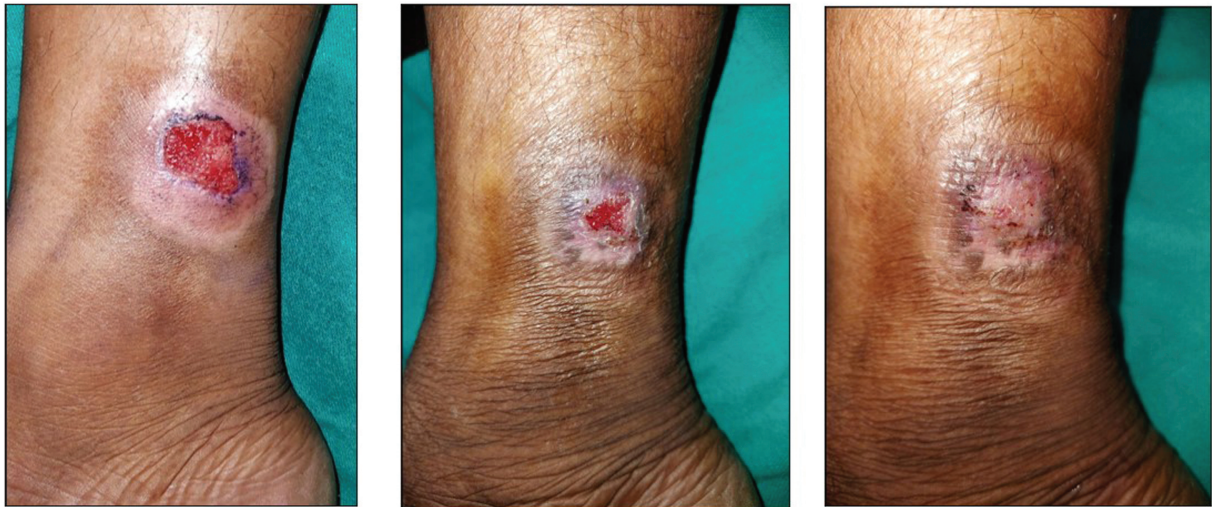

Fig. 4 Patient photograph showing weekly progress of healing.

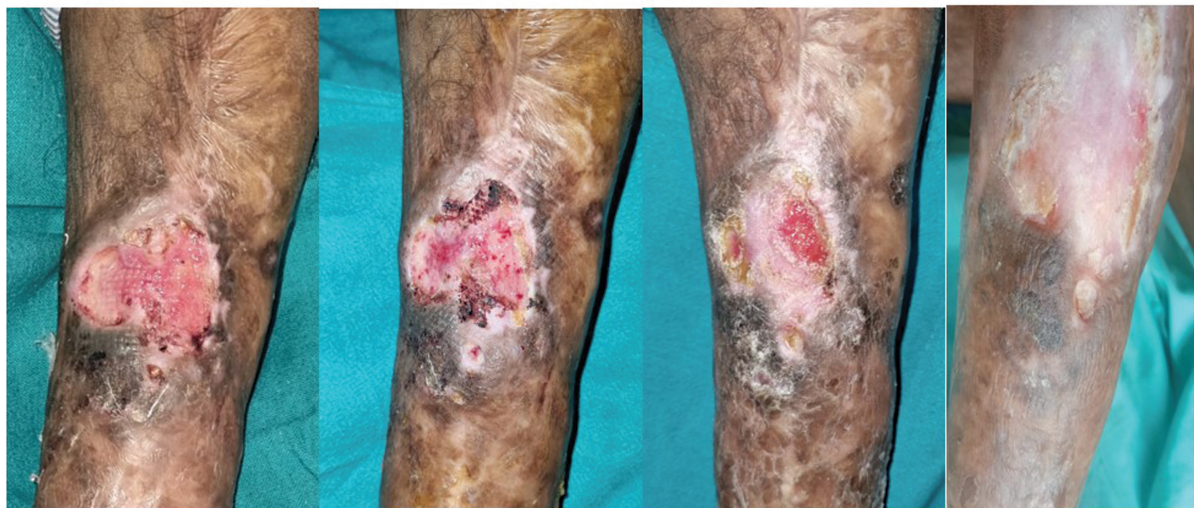

Fig. 5 Patient photograph showing weekly progress of healing.

assessed were granulation tissue coverage, epithelialization, and surface area of the wound.

Patient Demographics

The average age of the study population at presentation was 35.56 years (standard deviation [SD] 12.6, median 35, range 10–65 years) (► **Fig. 6**).

There were 2 female patients (11%) and 16 male patients (89%).

Wounds following trauma were significantly higher (44%), the other causes being postop infection (17%), veno-lymphatic ulcer (17%), burns (11%), insect bite (5%), and trophic ulcer (5%) (► **Fig. 7**).

The average size of the wounds was 9.75 cm², with a range of 1 to 20 cm² (► **Table 1**).

In our study, 66% of patients had these ulcers for more than 6 months and in rest of the patients the duration of the wounds was between 3 and 6 months.

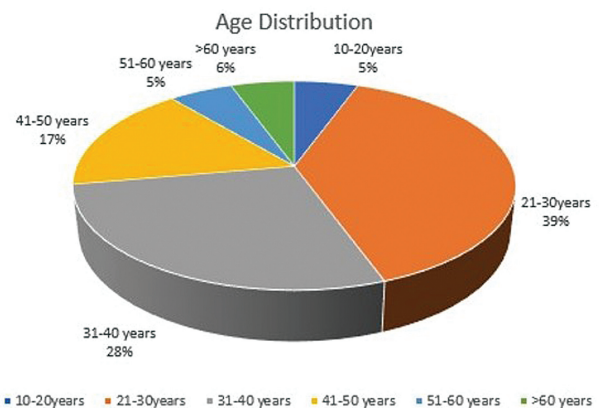


Fig. 6 Pie chart showing age distribution of patients.

In pus culture the predominant isolates were *Pseudomonas aeruginosa* (45%), followed by *Klebsiella pneumoniae* (27%) and *Proteus mirabilis* (18%).

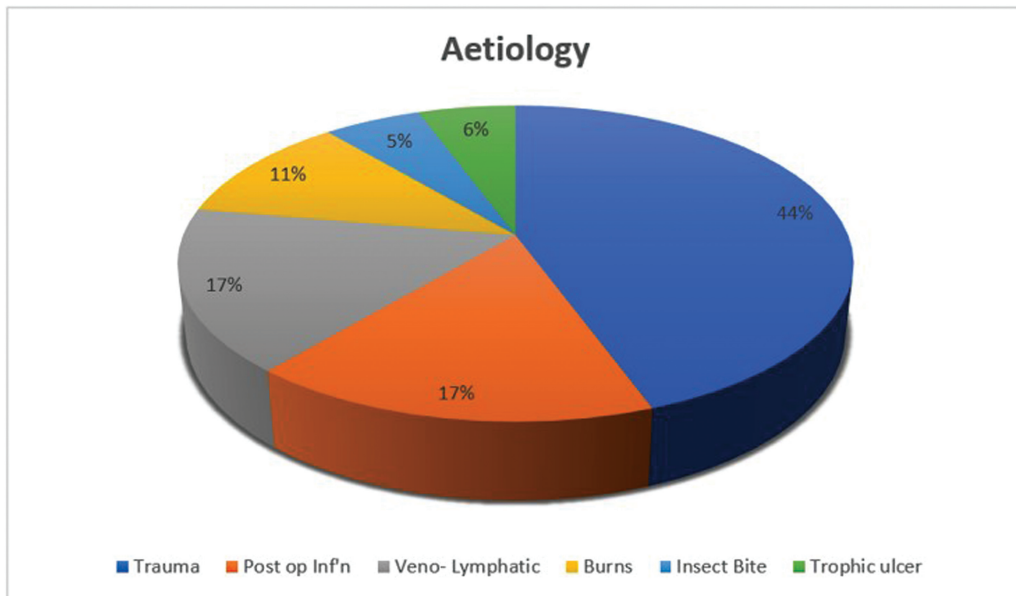


Fig. 7 Pie chart showing etiology of wounds.

Table 1 Table showing wound size and healing period

Patient no.	1	2	3	4	5	6	7	8	9	10	11	12	13	14	15	16	17	18
Area in cm ²	1	4	4.5	8	9	9	4	16	12	15	20	4	9	9	16	9	16	16
Healing period (wk)	4	3	4	4	5	3	6	8	4	5	10	4	6	6	5	5	4	5

The majority of the cases were done under local anesthesia, as a daycare procedure. Only one case was done under anesthesia considering the low age of the patient.

The average time for complete healing of the wound was 5.05 weeks (range 3–10 weeks) (► **Fig. 8**). Complete healing of majority of the wounds was obtained, without the need for

any secondary procedure. The healing period had strong correlation with the wound size (*R*-value 0.30).

The average amount of fat injected was 8 mL (range 5–18 mL). One patient needed a second sitting of AFG, which was performed 6 weeks after the first procedure. The decision for need of a second procedure was taken after noticing

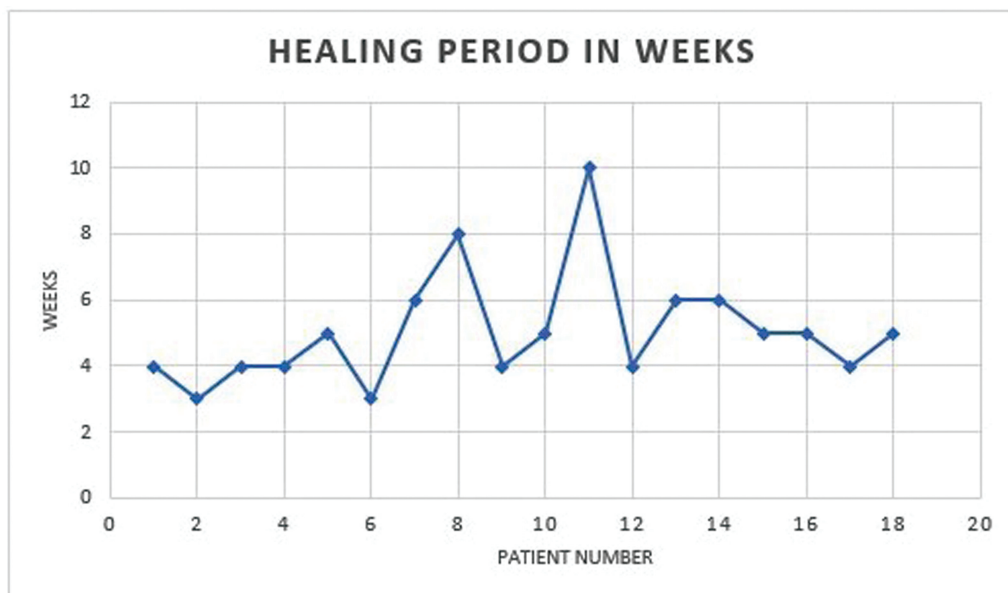


Fig. 8 Line diagram showing healing time of wounds.

Table 2 WBS 1 (before AFG) and WBS 2 (2 weeks after AFG)

Case no.	1	2	3	4	5	6	7	8	9	10	11	12	13	14	15	16	17	18
WBS-1	4	5	7	3	7	9	3	3	3	4	3	6	5	4	5	4	6	5
WBS-2	9	9	13	10	13	14	11	10	10	10	6	12	11	12	11	11	13	12

Abbreviations: AFG, autologous fat grafting; WBS, wound bed score.

nonprogression wound healing in that patient. The above said patient had nonhealing wound over the posterior arm following an insect bite.

The WBS was recorded twice, initially before AFG and 2 weeks after the procedure. This helped in comparing the progression of wound healing (► **Table 2**).

All the wounds showed progressive signs of wound healing after the procedure, the granulation tissue became healthier and showed improved coverage and all the wounds were epithelialized, leading to complete wound healing.

Discussion

Our study was conducted to evaluate the usefulness of autologous fat in the healing of chronic wounds. Chronic wounds often lead to increased morbidity and they can have a profound influence on the quality of life of the affected person.¹⁰⁻¹²

AFG was introduced as a cosmetic procedure in aesthetic plastic surgery.¹³ Since then, the spectrum of usage of autologous fat has widened. It was Zuk who first described ADSCs present within the autologous fat. The ADSCs contained within SVF, obtained after centrifugation of autologous fat, have a vital regenerative function.¹⁴ ADSCs bring on the paracrine secretion of several factors such as vascular endothelial growth factor, hepatocyte growth factor, and transforming growth factor-β, in response to various stimuli hypoxia, and have a profound influence on the differentiation of stem cells, resulting in increased angiogenesis, stimulate the remodeling of tissues, and helps in healing of wounds.¹⁵

It was Riggoti who first demonstrated the healing potential of autologous fat.¹⁶

Caviggioli et al performed AFG in a difficult to heal wound. In their study, they showed that complete wound healing was achieved by 4 weeks after AFG and the results were long-lasting and the integrity of the healed tissue was intact even after 1 year.¹⁷ The healing period of 5 weeks and the integrity of healed tissue in our study are comparable with the results of their study.

Smith et al in 2020 conducted their study on 18 patients. It was a single-center study, 17 months was the duration of the study, and patients were followed up for 21 months. Whereas in our study, we recruited 18 patients over 24 months and subsequently followed up for 12 months (some patients are still under follow-up). No adverse events were observed during our study, whereas five adverse events were reported by Smith et al in their study.¹⁸

Smith et al also performed a comprehensive analysis of all the available literature and mentioned that the mean time needed for complete wound healing was approximately

15 weeks after the intervention. The results obtained by this study (mean period of 5.05 weeks) are far better than the mean period described by prior studies.

Chopinaud et al conducted their study on 10 patients with hypertensive leg ulcers. The primary endpoint was set as wound closure and the wound was assessed at each follow-up visit. The secondary endpoints were changes in wound characteristics, pain pattern assessment, and development of any adverse events, if any. The median wound closure rate of the 10 patients was 63.2%. Percentages of fibrin and necrosis decreased and granulation tissue increased significantly. There was rapid and significant alleviation of pain. No recurrence or adverse events were observed. The authors suggested that AFG results in reduction of pain and promotes wound healing.¹⁹

In our study, 66% of patients had these ulcers for more than 6 months and in some patients, adjunct wound care measures like vacuum dressings were done, but did not yield favorable results. In one patient even skin grafting was performed, from an outside hospital, but had graft loss as he did not follow the advice of the surgeon. In our study, postprocedure majority of the wounds healed completely, one patient needed a second sitting of AFG, which was done 6 weeks after the first procedure.

The leg was the commonly involved area in majority of the patients. Detailed site-wise analysis showed that the wounds were over the lower leg in 10 cases (56%), the wound was over the foot in 6 cases (33%), and in 2 cases (11%) the wound was around the elbow.

The WBS was recorded twice, first before intervention (WBS-1) and during follow-up after 2 weeks (WBS-2). The mean score of WBS at the initial assessment was 6.59 (SD 1.69). The mean score of WBS at the second assessment was 10.89 (SD 1.93). On data analysis, the *p*-value was < 0.05%, which is statistically significant. This difference in WBS is suggestive of progression of wound healing in the earlier refractile wounds (► **Table 2**).

Study participants were followed up weekly, until the final result was obtained. Wound care advice was given. There were no complications (major/minor) reported by any of the study participants. There was also no need for any secondary procedure in majority of the patients. The superior results of our study can be attributed to careful patient selection, preoptimization, performance of the procedure by trained personnel, and appropriate postoperative care.

The patients were followed up to 1 year postsurgery and none of them reported any recurrence of ulceration.

Limitations of our study were the lack of a proper control group and the smaller sample size. This was mainly because patients initially designated for the control group did not

turn up for follow-ups. Our sample size was relatively smaller. This was partly due to a lack of awareness among other medical practitioners regarding the potential beneficial effect of autologous fat on wound healing.

Conclusion

AFG has shown promising results in our study. The WBS that was recorded before AFG and after AFG showed significant change in all our patients. The healing period of the wounds had strong correlation to the wound size. We were able to achieve complete wound healing in all the patients included in the study.

We strongly suggest the usage of AFG for nonhealing wounds, as the procedure is relatively simple and can be performed easily after basic training without the need for any sophisticated infrastructure and can be repeated, if needed.

Conflict of Interest

None declared.

References

- Anderson K, Hamm RL. Factors that impair wound healing. *J Am Coll Clin Wound Spec* 2014;4(04):84–91
- Saroha R, Langer V. Fat grafting; an adjunct in management of chronic leg ulcers. *Int Surg J* 2023;10(02):268–274
- Guo S, Dipietro LA. Factors affecting wound healing. *J Dent Res* 2010;89(03):219–229
- Menke NB, Ward KR, Witten TM, Bonchev DG, Diegelmann RF. Impaired wound healing. *Clin Dermatol* 2007;25(01):19–25
- Agale S. Chronic leg ulcers: epidemiology, aetiopathogenesis, and management. *Ulcers* 2013;2013:x
- Bellini E, Grieco MP, Raposio E. The science behind autologous fat grafting. *Ann Med Surg (Lond)* 2017;24(24):65–73
- Coleman SR. Structural fat grafting: more than a permanent filler. *Plast Reconstr Surg* 2006;118(3, Suppl):108S–120S
- Naderi N, Combellack EJ, Griffin M, et al. The regenerative role of adipose-derived stem cells (ADSC) in plastic and reconstructive surgery. *Int Wound J* 2017;14(01):112–124
- Falanga V, Saap LJ, Ozonoff A. Wound bed score and its correlation with healing of chronic wounds. *Dermatol Ther* 2006;19(06):383–390
- Planat-Benard V, Silvestre JS, Cousin B, et al. Plasticity of human adipose lineage cells toward endothelial cells: physiological and therapeutic perspectives. *Circulation* 2004;109(05):656–663
- Cherubino M, Rubin JP, Miljkovic N, Kelmendi-Doko A, Marra KG. Adipose-derived stem cells for wound healing applications. *Ann Plast Surg* 2011;66(02):210–215
- Escandon J, Vivas AC, Tang J, Rowland KJ, Kirsner RS. High mortality in patients with chronic wounds. *Wound Repair Regen* 2011;19(04):526–528
- Coleman SR. Structural fat grafts: the ideal filler? *Clin Plast Surg* 2001;28(01):111–119
- Zuk PA, Zhu M, Ashjian P, et al. Human adipose tissue is a source of multipotent stem cells. *Mol Biol Cell* 2002;13(12):4279–4295
- Simonacci F, Bertozzi N, Grieco MP, Grignaffini E, Raposio E. Procedure, applications, and outcomes of autologous fat grafting. *Ann Med Surg (Lond)* 2017;20:49–60
- G Riggotti, Marchi A, Galiè M, et al. Clinical treatment of radiotherapy tissue damage by lipoaspirate transplant: a healing process mediated by adipose-derived adult stem cells. *Plast Reconstr Surg* 2007;119(05):1409–1422
- Cavaggioli F, Klinger FM, Vinci V, Cornegiani G, Klinger M. Treatment of chronic posttraumatic leg injury using autologous fat graft. *Case Rep Med* 2012;2012:648683
- Smith OJ, Leigh R, Kanapathy M, et al. Fat grafting and platelet-rich plasma for the treatment of diabetic foot ulcers: a feasibility-randomised controlled trial. *Int Wound J* 2020;17(06):1578–1594
- Chopinard M, Labbé D, Creveuil C, et al. Autologous adipose tissue graft to treat hypertensive leg ulcer: a pilot study. *Dermatology* 2017;233(2-3):234–241