



# Desmoplastic Small Round Cell Tumor of the Spinal Canal: A Rare Presentation in a Female Pediatric Patient

Sana Ahuja<sup>1</sup> Shaivy Malik<sup>1</sup> Vivek Yadav<sup>2</sup> Charanjeet Ahluwalia<sup>1</sup>

<sup>1</sup>Department of Pathology, Vardhman Mahavir Medical College and Safdarjung Hospital, New Delhi, India

<sup>2</sup>Department of Neurosurgery, Vardhman Mahavir Medical College and Safdarjung Hospital, New Delhi, India

**Address for correspondence** Charanjeet Ahluwalia, DNB, Department of Pathology, Vardhman Mahavir Medical College and Safdarjung Hospital, New Delhi 110029, India (e-mail: charanjeetahluwalia70@gmail.com).

Indian J Neurosurg 2025;14:283–285.

## Abstract

Desmoplastic small round cell tumor (DSRCT) is a rare and aggressive malignancy primarily affecting young individuals, typically originating in the abdominal cavity. While spinal involvement by DSRCT is exceedingly rare, especially in pediatric patients, recognizing such atypical presentations is crucial for optimal management. Here, we present a case of DSRCT involving the spinal canal in a 3-year-old female child, representing one of the youngest documented instances in the literature. Initial symptoms included weakness, lower limb pain, and urinary incontinence. Magnetic resonance imaging revealed an enhancing soft tissue lesion in the spinal canal, prompting tumor excision and histopathological examination. The tumor exhibited characteristic features of DSRCT, including small round cells within a desmoplastic stroma. Immunohistochemistry confirmed the diagnosis, showing positivity for Wilms tumor 1, epithelial membrane antigen, desmin, and synaptophysin. This case highlights the challenges in diagnosing and managing rare tumors like spinal DSRCT, emphasizing the importance of a comprehensive approach to differential diagnosis and individualized treatment strategies.

## Keywords

- ▶ desmoplastic small round cell tumor
- ▶ female pediatric
- ▶ spinal canal

## Introduction

Desmoplastic small round cell tumor (DSRCT) is a rare and highly aggressive malignancy characterized by its distinct histopathological features and unique molecular alterations.<sup>1</sup> Typically originating in the abdominal cavity, particularly among adolescents and young adults, DSRCT poses significant diagnostic challenges and carries a dismal prognosis due to its propensity for widespread metastasis and resistance to conventional therapies.<sup>2,3</sup> While primary occurrences of DSRCT within the spinal canal are exceptionally rare, particularly in pediatric patients, understanding such atypical presentations is crucial for optimizing diagnostic and therapeutic strategies.

In this report, we present a case of DSRCT affecting the spinal canal in a 3-year-old female child. To our knowledge, this case represents the first and only case of spinal DSRCT in a child in the existing literature. To date, no case of spinal DSRT has been reported. We aim to delineate the clinical presentation, diagnostic dilemmas, therapeutic modalities, and subsequent clinical outcomes in this unique pediatric case. Additionally, we provide an overview of recent advancements in the understanding of DSRCT, including insights into its molecular pathogenesis, novel diagnostic techniques, and evolving treatment paradigms.

article published online  
October 10, 2024

DOI <https://doi.org/10.1055/s-0044-1790532>.  
ISSN 2277-954X.

© 2024. The Author(s).

This is an open access article published by Thieme under the terms of the Creative Commons Attribution License, permitting unrestricted use, distribution, and reproduction so long as the original work is properly cited. (<https://creativecommons.org/licenses/by/4.0/>)  
Thieme Medical and Scientific Publishers Pvt. Ltd., A-12, 2nd Floor, Sector 2, Noida-201301 UP, India

## Case Report

A 3-year-old female presented to the outpatient department with complaints of weakness and pain in bilateral lower limbs with urinary incontinence for 3 months. Magnetic resonance imaging (MRI) was done which exhibited an intensely enhancing soft tissue lesion in the spinal canal from D12 to L2 levels predominantly on the right side extending into the right neural foramina. It is also seen extending posteriorly in the right paraspinous region. Thus, it was an intradural extramedullary tumor and a possibility of a tumor of neural origin was suggested. Gross total tumor resection (including both intradural and paraspinous components) was done and sent for histopathological examination. It was firm, gray white in appearance and adhered to the cord. Sections examined exhibited a tumor arranged in nests, cords, and trabeculae with extensive desmoplastic stroma. The tumor cells had scant cytoplasm, round to ovoid nuclei with finely stippled chromatin, inconspicuous nucleoli, and a high nuclear/cytoplasmic ratio with indistinct cellular borders, imparting a syncytial appearance to the tumor. Mitotic figures were frequently observed, indicative of the tumor's high proliferative activity. On immunohistochemistry, the tumor cells exhibited positive immunostaining for epithelial membrane antigen (EMA), Wilms tumor 1 (WT1), vimentin, desmin, and synaptophysin with a Ki-67 proliferation index of 40%. Based on the above histopathological findings and expression of epithelial (EMA), mesenchymal (vimentin, desmin, and WT1), and neuronal markers (synaptophysin), a final diagnosis of DSRCT of the spinal canal, World Health Organization grade 4 was made (– Fig. 1). Postoperatively, she received systemic chemotherapy consisting of a multidrug regimen tailored to DSRCT protocols, including ifosfamide, doxorubicin, and etoposide. Subsequent follow-up positron emission tomography-computed tomography and MRI showed no evidence of any other metabolically avid lesion elsewhere in the body. The patient is currently under follow-up for 1 year with no signs of regional or distant metastasis.

## Discussion

This case of DSRCT involving the spinal canal in a 3-year-old female child is exceptionally rare and underscores the importance of considering rare malignancies in the differential diagnosis, particularly in pediatric patients presenting with unusual symptoms.

DSRCT primarily manifests in the abdominal cavity, with occurrences in the spinal canal being exceedingly uncommon, especially in young children. It is essentially a tumor seen in young and adolescent males.<sup>3,4</sup> The instances of DSRCT reported in females have primarily involved the abdomen, pelvic cavity, and kidneys.<sup>5,6</sup> Notably, there have been no reported cases of DSRCT affecting the spinal cord to date.

This rarity poses significant challenges in both diagnosis and management, often leading to delayed recognition and treatment initiation. In our case, the initial symptoms of back pain and gait abnormalities were nonspecific and initially

attributed to common pediatric musculoskeletal issues. However, persistent symptoms and inconclusive initial evaluations prompted further investigation, ultimately leading to the unexpected diagnosis of spinal DSRCT. Surgical steps and precautions while operating such a tumor would likely involve careful manipulation to avoid damage to the spinal cord and nerve roots. Given the tumor's location within the spinal canal and its extension into the neural foramina, the surgical approach would likely involve meticulous dissection to separate the tumor from surrounding neural structures. Precautions may include intraoperative neuromonitoring to assess nerve function and ensure preservation, as well as the use of microsurgical techniques to precisely remove the tumor while minimizing trauma to adjacent tissues.

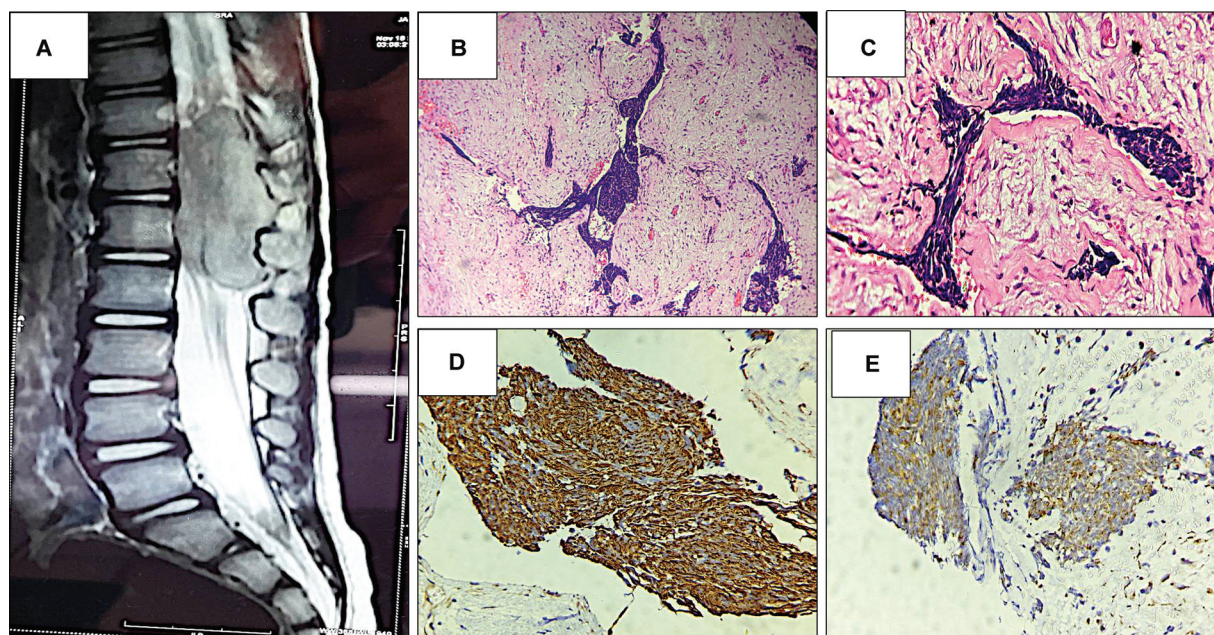
The diagnostic process for rare tumors like spinal DSRCT requires a systematic approach, including thorough clinical evaluation, advanced imaging modalities, and histopathological examination. Despite advancements in diagnostic techniques, such as immunohistochemistry and molecular studies, definitive diagnosis may remain elusive without a high index of suspicion and comprehensive evaluation. Intraoperative frozen section examination could help in making a diagnosis of small round cell tumor; however, a final diagnosis can be arrived at only after histopathological and immunohistochemical examination.

The differential diagnoses for a tumor presenting in this location could include other types of spinal cord tumors such as neurofibroma, schwannoma, or ependymoma. However, based on the histopathological findings described in the article (nesting pattern with desmoplastic stroma, small round cells with high mitotic activity, and immunostaining positive for epithelial, mesenchymal, and neuronal markers), DSRCT was the final diagnosis.

Molecular techniques, such as fluorescence in situ hybridization and reverse transcription-polymerase chain reaction, can detect the distinctive EWS-WT1 fusion gene, aiding in the diagnostic process.<sup>2,3</sup> Additionally, the rarity of spinal DSRCT presents challenges in developing standardized treatment protocols. Management typically involves aggressive surgical resection, when feasible, followed by adjuvant chemotherapy and/or radiation therapy. However, the optimal therapeutic approach for spinal DSRCT remains unclear due to limited data and variable responses to treatment.<sup>4</sup>

The prognosis is generally poor, with overall survival rates ranging from approximately 15 to 30% at 5 years, despite aggressive treatment approaches including surgery, chemotherapy, and radiation therapy.<sup>4</sup> Our case highlights the need for individualized treatment strategies tailored to the patient's clinical presentation, tumor characteristics, and response to therapy.

Clinicians should maintain a broad differential diagnosis when evaluating pediatric patients with spinal cord tumors, especially when conventional imaging studies fail to provide definitive answers. Rare tumors, such as DSRCT, should be considered even in the absence of typical clinical features or imaging findings. Early recognition of rare malignancies is crucial for timely initiation of appropriate treatment, potentially improving patient outcomes and quality of life.



**Fig. 1** Radiological and pathological images. (A) Magnetic resonance imaging (MRI) dorsolumbar spine exhibiting an intensely enhancing soft tissue lesion in the spinal cord from D12 to L2 and extending to the right paraspinal region. (B, C) Histopathological photomicrographs depicting a malignant tumor with well-defined nests of small round cells separated by desmoplastic stroma. The cells are uniform with small hyperchromatic nuclei, scant cytoplasm, and indistinct cytoplasmic borders ( $100\times$ ,  $400\times$  magnification). (D, E) Immunohistochemistry depicts positive expression for Wilms tumor 1 (WT1) and desmin ( $400\times$ ).

## Conclusion

The rarity of spinal DSRCT in pediatric patients emphasizes the importance of maintaining a comprehensive and inclusive approach to differential diagnosis. Clinicians should remain vigilant for rare malignancies, even in cases with atypical presentations, to ensure timely diagnosis and appropriate management. Collaboration among multidisciplinary teams and ongoing research efforts are essential to improve our understanding of rare tumors like spinal DSRCT and optimize patient care.

### Informed Consent

The authors certify that they have obtained all appropriate patients' consent forms.

### Authors' Contribution

All authors equally contributed to the conceptualization and design of the study. S.A. provided the definition of intellectual content and performed the literature search. S.A., S.M., V.Y., and C.A. contributed to data acquisition. S.A. and C.A. were involved in data analysis, while C.A. acted as the guarantor for the study. S.A. led the manuscript preparation, with S.M., V.Y.,

and C.A. contributing to manuscript editing. Manuscript review was carried out by S.A., V.Y., and C.A.

### Conflict of Interest

None declared.

## References

- 1 Gerald WL, Rosai J. Desmoplastic small cell tumor with multiphenotypic differentiation. *Zentralbl Pathol* 1993;139(02):141–151
- 2 Cao L, Ni J, Que R, Wu Z, Song Z. Desmoplastic small round cell tumor: a clinical, pathological, and immunohistochemical study of 18 Chinese cases. *Int J Surg Pathol* 2008;16(03):257–262
- 3 Mello CA, Campos FAB, Santos TG, et al. Desmoplastic small round cell tumor: a review of main molecular abnormalities and emerging therapy. *Cancers (Basel)* 2021;13(03):498
- 4 Yamauchi K, Owari M, Kimura K, Ishii T, Wakasa T, Yonekura T. Desmoplastic small round cell tumor: a case report and literature review. *J Pediatr Surg Case Rep* 2023;96:102691
- 5 Cacciotti C, Samji N, Cox S, et al. Desmoplastic small round cell tumor with ascending intraspinal metastasis at recurrence: case report and review of the literature. *J Pediatr Hematol Oncol* 2022;44(02):e561–e566
- 6 Ertoy Baydar D, Armutlu A, Aydin O, Dagdemir A, Yakupoglu YK. Desmoplastic small round cell tumor of the kidney: a case report. *Diagn Pathol* 2020;15(01):95