



# Diagnostic Dilemmas in Fetal Scalp Cystic Lesions: A Case Series

Omkar Potdar<sup>1</sup> Indrani Suresh<sup>2</sup> Vijayalakshmi Raja<sup>2</sup> Sakshi Yadav<sup>3</sup>

<sup>1</sup>Department of Fetal Medicine, Ansh Fetal Medicine Centre, Sangli, Maharashtra, India

<sup>2</sup>Department of Fetal Medicine, Mediscan Systems, Chennai, Tamil Nadu, India

<sup>3</sup>Department of Clinical Genetics and Fetal Medicine, Faith Diagnostic and Fetal Centre, Mohali, Punjab, India

Address for correspondence Omkar Potdar, MBBS, MS (OBG), Ansh Fetal Medicine Centre, Sangli, Maharashtra, India (e-mail: dromkarptdr@gmail.com).

J Fetal Med 2024;11:188–192.

## Abstract

Fetal Scalp cystic lesions are occasionally encountered during the routine mid trimester scan. Some may be benign scalp cysts like an epidermal or dermal cyst, and some may contain neural tissue with associated calvarial defects like meningocele or encephalocele. Prenatally, differentiating them and arriving at an exact diagnosis is challenging. This case study describes seven cases diagnosed with fetal scalp cysts and normal intracranial anatomy. Seven cases with normal intracranial anatomy were included. Out of seven cases, four turned out to be scalp cysts, two turned out to be meningocele, and one was atretic encephalocele. Of four cases of scalp cysts, three regressed spontaneously and one required surgical excision. All instances of meningocele and encephalocele required surgical correction. In the case of fetal scalp cystic lesions, the presence of normal intracranial anatomy and head circumference, the absence of other associated anomalies, and the use of high frequency ultrasound transducers to rule out calvarial defects can aid in delineating the diagnosis of benign fetal scalp cysts.

## Keywords

- ▶ calvarial defect
- ▶ fetal scalp cyst
- ▶ meningocele
- ▶ ultrasound technique
- ▶ three dimensional ultrasound

## Introduction

During antenatal scans, we seldom come across cystic lesions in the fetal scalp. Once a cystic lesion in the fetal scalp is encountered, the differentials include epidermal cyst, hemangioma, lymphangioma, sinus pericranii, meningocele, encephalocele, atretic cephalocele, or encephalocystocele.<sup>1</sup> Large sized meningoceles with abnormal intracranial anatomy are easy to diagnose. In contrast, small sized lesions with normal intracranial anatomy and head circumference can pose a diagnostic uncertainty between the scalp cyst, which is innocuous, and small meningoceles with very tiny calvarial defects.<sup>2</sup> Sometimes, when the ultrasound beam is parallel to the vault, it can fail to identify a calvarial defect. Correct diagnosis is cardinal for prognostication and antenatal

counseling. Judicial use of ultrasound techniques can make tiny calvarial detection evident, prevent false positives, and thus resolve diagnostic dilemmas.

## Methods

This was a retrospective study. All patients with antenatal diagnoses of fetal scalp cysts and normal intracranial anatomy from 2014 to 2019 were included. All the clinical information about the patients and relevant ultrasound images were retrieved from the in-house stored data. High resolution ultrasound machine equipped with a 3 to 5 MHz transducer (Voluson E6) was used for ultrasound examination. The follow up was recorded telephonically from the patients.

article published online  
October 3, 2024

DOI <https://doi.org/10.1055/s-0044-1791489>.  
ISSN 2348-1153.

© 2024. Society of Fetal Medicine. All rights reserved.

This is an open access article published by Thieme under the terms of the Creative Commons Attribution-NonDerivative-NonCommercial-License, permitting copying and reproduction so long as the original work is given appropriate credit. Contents may not be used for commercial purposes, or adapted, remixed, transformed or built upon. (<https://creativecommons.org/licenses/by-nc-nd/4.0/>)

Thieme Medical and Scientific Publishers Pvt. Ltd., A-12, 2nd Floor, Sector 2, Noida-201301 UP, India

If the pregnancy was terminated, the autopsy images were collected from the pathology department after the patient's consent.

### Case 1

Thirty years, second gravida at 18 weeks was referred for cyst in the left aspect of the skull. On ultrasound examination, there was a  $1.4 \times 1.2$ -cm sized scalp cyst in the left temporal region above and anterior to the ear (**Fig. 1A**). Intracranial anatomy was normal. Considering the location of the cyst and its appearance, a scalp cyst diagnosis was proposed. During her follow up visits, there was a progressive increase in cyst size: from  $3.4 \times 2.6$  cm at 28 weeks to  $4.9 \times 3.4$  cm at 32 weeks (**Fig. 1B**).<sup>3</sup> Head circumference remained normal till term. There was a full term vaginal delivery, and the perinatal and postnatal periods were uneventful.

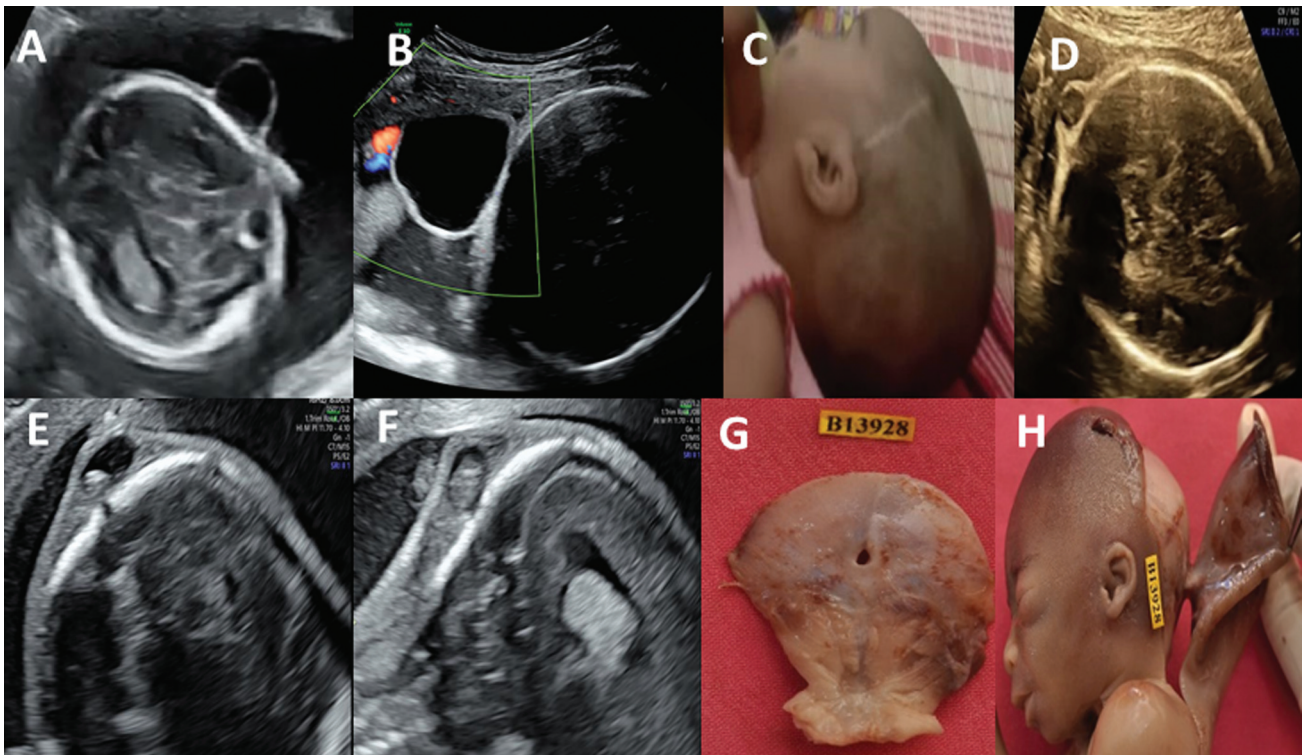
Postnatal magnetic resonance imaging (MRI) was performed because of the large cyst size and a provisional diagnosis of temporal meningocele was considered. The baby was operated on day 35, and a small intracranial communication was excised. The baby is now 2 years old and doing well. All developmental milestones were achieved at an appropriate age (**Fig. 1C**). This case illustrates a very unusual location for a meningocele.

### Case 2

Twenty nine years, primigravida at 27.5 weeks was referred for encephalocele/dermoid cyst of the fetal scalp. On ultrasound examination, a thick walled cystic lesion with echogenic material, measuring  $1.2 \times 0.7$  cm, was noted in the scalp of the occipital region (**Fig. 1D**) with normal intracranial anatomy and head circumference. A differential diagnosis of occipital encephalocele or epidermal scalp cyst was made. During the follow up visit at 32 weeks, the cyst had regressed in size. Postnatally, the baby was operated at 3rd month of age. The histopathological report suggested that the fragments of fibrocollagenous tissue with many foci show neurological tissue that is compatible with a diagnosis of atretic encephalocele.<sup>4</sup> The child is 4 years old now with normal milestones.

### Case 3

Twenty nine years, primigravida at 20 weeks was referred for a thick walled scalp cyst. On ultrasound examination, the head circumference was at the 5th centile for the period of gestation, and the intracranial anatomy was normal. Using a high frequency endovaginal transducer, a small rent in the occipital bone with herniation of meninges was seen,



**Fig. 1** (A–C) Case 1: (A) Transabdominal ultrasound image of the fetal head at 18.2 weeks showed a  $1.4 \times 1.2$  cm cystic structure in the left temporal region above and anterior to the left ear. Intracranial anatomy was normal. (B) At 32 weeks, the cyst increased, measuring  $4.9 \times 3.4$  cm. (C) Postnatal surgical excision done at day 35, small intracranial communication was excised. (D) Case 2: Transabdominal ultrasound image of the fetal head at 27.5 weeks showing  $1.2 \times 0.7$  cm thick walled cystic lesion with echogenic material is seen in the scalp of the occipital region with normal intracranial anatomy and head circumference. (E–H) Case 3: (E, F) High frequency transvaginal ultrasound image of fetal head showing small rent in the occipital bone with herniation of meninges seen measuring  $0.9 \times 0.7$  cm. Head circumference was falling at the 5th centile. (G, H) Autopsy images revealed a tiny calvarial defect of 2 mm size with herniation of meninges.

measuring  $0.9 \times 0.7$  cm ( $\rightarrow$ Fig. 1E, F). Diagnosis of occipital meningocele with normal intracranial anatomy was considered.<sup>5</sup> Given head circumference at the 5th centile and concerns regarding evolving abnormalities, pediatric neurologist consultation was suggested to understand the postnatal implications. The patient opted against the continuation of pregnancy. The fetus was sent for a detailed histopathological examination and autopsy, which revealed a tiny calvarial defect of 2 mm in size with herniation of meninges ( $\rightarrow$ Fig. 1G, H).

#### Case 4

Twenty four years, primigravida at 31 weeks was referred for meningocele in the occipital region. On ultrasound examination, we noted a  $2.3 \times 2.2$  cm sized, thick walled cystic lesion in the left cervical occipital region with normal intracranial anatomy and head circumference ( $\rightarrow$ Fig. 2A). The cyst resolved spontaneously after birth. The child is 2 years old now and doing well.

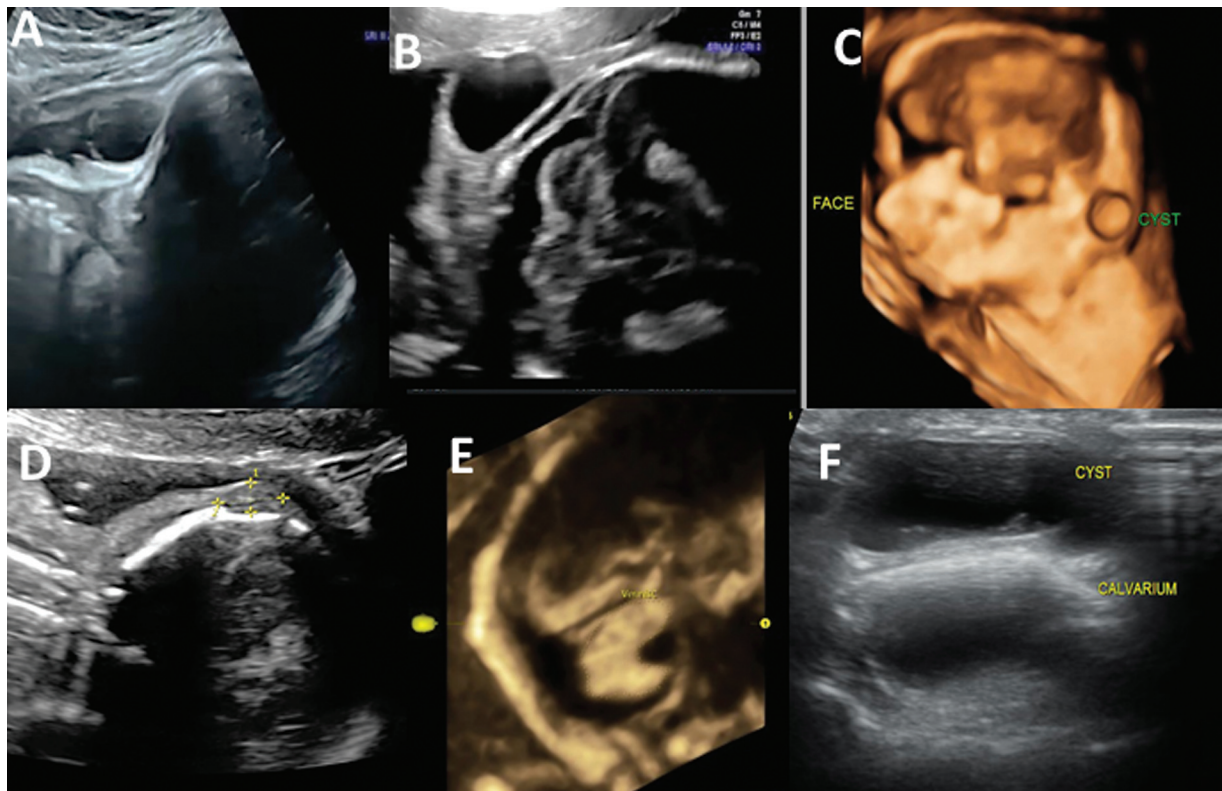
#### Case 5

Twenty five years, second gravida at 22 weeks was referred for scalp cyst. Ultrasound examination revealed a cystic

lesion measuring  $1.7 \times 1.6$  cm over the lower end of the occipital bone, toward the left side, behind the ear, with normal head circumference and intracranial anatomy ( $\rightarrow$ Fig. 2B, C). The cyst was seen in the scalp with an intact calvarium and a diagnosis of a scalp cyst was strongly suspected. Postnatally, small swelling persisted for a few days after birth, regressing spontaneously. Accordingly, no investigations were planned. The child is 4 years old now with normal milestones.

#### Case 6

Thirty years, second gravida at 23 weeks was referred for a posterior fossa cyst. On ultrasound examination, we noted prominent fourth ventricle communication with cisterna magna with normal vermian morphology and biometry ( $\rightarrow$ Fig. 2D). Along with this, a cyst measuring  $0.6 \times 1.2$  cm was noted in the occipital region over the scalp; a diagnosis of an epidermal cyst of the scalp was considered ( $\rightarrow$ Fig. 2E). Head circumference and the rest of the intracranial anatomy were normal. Follow up visit at 30 weeks, the cyst regressed in size and Blake's pouch cyst was seen. Cyst regressed entirely after birth, thus not evaluated. The child is now 4 years old with normal milestones.



**Fig. 2** (A) Case 4: Transabdominal ultrasound image of the fetal head at 31 weeks showing  $2.3 \times 2.2$  cm sized, thick walled cystic lesion in the left cervico-occipital region with normal intracranial anatomy and head circumference. (B, C) Case 5: (B) Transabdominal ultrasound image of fetal head at 22.2 weeks showing  $1.7 \times 1.6$  cm sized cystic lesion is seen over the lower end of the occipital bone, toward the left side, behind the left ear with normal head circumference and intracranial anatomy. (C) Three dimensional (3D) surface rendering of the same cyst. (D, E) Case 6: (D) Transabdominal ultrasound image of fetal head at 23 weeks showing  $0.6 \times 1.2$  cm sized cyst seen in the occipital region over the scalp with normal intracranial anatomy and head circumference. (E) 3D Omni view reconstruction of the posterior fossa of the brain shows Blake's pouch cyst. (F) Case 7: Postnatal ultrasound of skull showing epidermal cyst with intact calvarium.



### Case 7

Thirty one years, second gravida at 21 weeks was referred for a routine target scan. An ultrasound examination showed a cystic mass measuring 0.8 × 0.8 cm on the scalp, over the occipital region, with normal head circumference and intracranial anatomy (►Fig. 2F). Diagnosis of epidermal cyst of the scalp was considered.<sup>6</sup> Postnatal ultrasound gave the diagnosis of an epidermal cyst. The baby was operated on for the same. The child is 9 years old and doing well.

Antenatal scan findings and postnatal outcomes of the abovementioned cases of scalp cysts have been summarized in ►Table 1.

### Discussion

Fetal scalp cystic lesions are seen infrequently during routine mid trimester scans. Primarily, they are encountered while measuring the biometry of the head. One should be aware of the variety of differential diagnoses of cystic lesions of the scalp (►Fig. 3). The use of power Doppler and localizing the tiny calvarial defect will help to arrive at a definite diagnosis.

The cases reported here are those with normal intracranial anatomy with different diagnoses; almost all had normal neurodevelopmental outcomes. Of the seven cases described above, the diagnostic odyssey in case 3 was solved using a high frequency endovaginal probe where the presence of perpendicular ultrasound beams assisted in detecting the calvarial defect and meninges as its content.

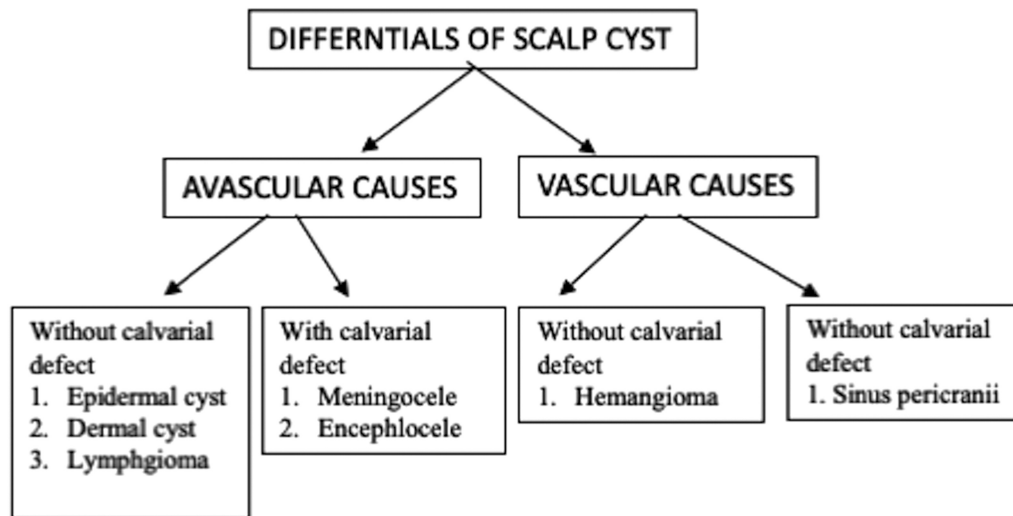
Hence, the antenatal diagnosis of occipital meningocele was considered, and the autopsy confirmed the same findings. In cases 5, 6, and 7, antenatal diagnosis of scalp cyst was strongly suspected; in case 7, the postnatal ultrasound also confirmed the diagnosis of scalp cyst, and in cases 5 and 6, the cyst regressed completely in the postnatal period, where the outcome was obtained on telephonic conversation. Cases 1, 2, and 4 are cases where a differential diagnosis was given because of a diagnostic dilemma. Cyst in case 1 in itself is unique owing to its very unusual temporal location, which, on follow up, progressed in size but maintained normal intracranial anatomy throughout the pregnancy. Thus, it was a misleading sign to label it as meningocele. Moreover, because of its temporal location, the diagnosis of scalp cysts was considered. Postnatal MRI diagnosed it as temporal meningocele.<sup>3</sup> In cases 2 and 4, differential diagnoses were given as meningocele/scalp cyst during the antenatal period, of which case 2 turned out to be atretic cephalocele. In case 4, the cyst resolved postnatally.

To the best of our knowledge, this is the largest case series on cystic lesions of the fetal scalp reported to date. Okaro et al described two case reports, both of which were thought of as meningocele antenatally, but postnatally, one turned out to be a plexiform skin lesion and the other an epidermal scalp cyst. They stressed the use of the color Doppler and the finding of the calvarial defect.<sup>6</sup> Ogle and Jauniaux reported a case where there was a cystic lesion near the anterior fontanelle, differential diagnosis of small cephalocele or scalp cyst, which turned out to be a dermoid scalp cyst

**Table 1** Clinical profile and post natal outcome in fetuses with scalp cysts

Case no.	Gestational age (wk)	Location (cm)	Size	Vascularity	Content	Progression	Intracranial anatomy	Diagnosis		Outcome
								Prenatal	Postnatal	
1	18.2	Left temporal	1.4 × 1.2	No	Clear	Yes	Normal	Scalp cyst	MRI: Temporal meningocele	Operated at day 35. Normal milestones.
2	27.5	Occipital	1.2 × 0.7	No	Echogenic	No	Normal	Occipital meningocele/Scalp cyst	Histopathological report: Atretic encephalocele	Operated at 3rd month of age. Baby doing well
3	20	Occipital	0.9 × 0.7	No	Meninges	No	Normal	Occipital meningocele	Autopsy: Occipital meningocele	TOP
4	31	Left occipitocervical	2.3 × 2.2	No	Clear	No	Normal	Occipital meningocele/Scalp cyst	Not evaluated	Cyst resolved spontaneously
5	22.2	Left lower occipital	1.7 × 1.6	No	Clear	No	Normal	Scalp cyst	Not evaluated	Cyst regressed. Baby doing well
6	23	Occipital	0.6 × 1.2	No	Echogenic	No	Normal	Epidermal cyst	Not evaluated	Cyst regressed. Baby doing well
7	21	Occipital	0.8 × 0.8	No	Clear	No	Normal	Epidermal cyst	Postnatal USG: Epidermal cyst	Cyst excised. Baby is doing well

Abbreviations: MRI, magnetic resonance imaging; USG, ultrasound; TOP, top-termination pregnancy.



**Fig. 3** Flowchart for differential diagnosis of fetal scalp cyst.

with a good postnatal outcome.<sup>2</sup> Timor-Tritsch et al described two cases of meningoceles where, in one case, MRI failed to show the tiny 1.8 mm bony defect. In another case, high frequency transducer and three-dimensional (3D) tomographic ultrasound imaging (TUI) demonstrated a tiny bony defect.<sup>7</sup> Sepulveda et al reported one case where they explained the value of 3D multiplanar and TUI imaging in aiding the diagnosis of a case of meningocele.<sup>8</sup> Singh and Kaur reported three cases where they proposed the diagnostic algorithm for cystic lesions of the fetal scalp and stressed the optimal use of two-dimensional and 3D imaging techniques and MRI as an adjunct to arrive at a diagnosis.<sup>1</sup>

This shows the diagnostic dilemma and uncertainty while approaching a case of a cystic lesion of the fetal scalp. On reviewing the literature on cystic lesions of the fetal scalp to date, we propose the optimal use of a high frequency transducer with a beam perpendicular to the vault, 3D multiplanar, TUI to find out the tiny calvarial defect.<sup>1,6-8</sup> In cases of poor acoustic window, unsatisfactory central nervous system examination, or associated intracranial abnormalities, antenatal MRI has better contrast resolution and thus aids in achieving the diagnosis.

## Conclusion

Cystic lesions of the fetal scalp have a variety of differential diagnoses. Optimal use of a high frequency transducer should be made to look for the tiny calvarial defect. Cases with normal intracranial anatomy and head circumference with no associated extracranial abnormalities can have near normal outcomes postnatally. Isolated atretic cephalocele can also have normal neurodevelopmental outcomes.<sup>4</sup> In case of a progressive increase in the size of the cystic lesion, one should suspect meningocele.<sup>3</sup> Correct diagnosis determines the exact prognosis, which is paramount for proper prenatal counseling.

## Authors' Contributions

O.P. and S.Y. have contributed substantially to acquiring data and drafting the manuscript. I.S. and V.R. revised it critically and gave the final approval for the version to be published.

## Conflict of Interest

None declared.

## Acknowledgments

We acknowledge that all the patients and families were ready to participate in the study and contributed by providing follow up.

## References

- Singh D, Kaur L. Cystic lesion in the fetal scalp: a systematic approach. *J Foetal Med* 2019;6(03):155–157
- Ogle RF, Jauniaux E. Fetal scalp cysts–dilemmas in diagnosis. *Prenat Diagn* 1999;19(12):1157–1159
- Dahlgren RM, Baron EM, Vaccaro AR. “Pathophysiology, diagnosis, and treatment of spinal meningoceles and arachnoid cysts”. 2007). Department of Orthopaedic Surgery Faculty Papers. Paper 4. Accessed September 12, 2024 at: <https://jdc.jefferson.edu/orthofp/4>
- Tokatly Latzer I, Roth J, Constantini S, et al. Neurodevelopmental outcome of children born with an isolated atretic cephalocele. *Childs Nerv Syst* 2021;37(04):1295–1300
- Nawaz A, Turnbull I, MacDonald S, et al. “Encephalocele imaging.”. Medscape; May 2020
- Okaro E, Broussin B, Ville Y. Prenatal diagnosis of atypical cystic lesions of the fetal scalp. *Ultrasound Obstet Gynecol* 1998;12(06):442–444
- Timor-Tritsch IE, Monteagudo A, Santos R. Fine-tuning the diagnosis of fetal scalp cysts: the value of high-frequency sonography. *J Ultrasound Med* 2008;27(09):1363–1368
- Sepulveda W, Wong AE, Sepulveda S, Corral E. Fetal scalp cyst or small meningocele: differential diagnosis with three-dimensional ultrasound. *Fetal Diagn Ther* 2011;30(01):77–80