

# Follicular Dendritic Cell Sarcoma of the Thyroid Gland: A Rare Case Report

Mayadevi Poojari<sup>1</sup> Irappa Madabhavi<sup>2,3,4</sup> Jaydeep Pol<sup>5</sup> Sharad Desai<sup>6</sup>

<sup>1</sup>Department of Radiation Oncology, Mahatma Gandhi Cancer Hospital, Miraj, Maharashtra, India

<sup>2</sup>Department of Medical and Pediatric Oncology and Hematology, J. N. Medical College, Belgaum, Karnataka, India

<sup>3</sup>Kerudi Cancer Hospital, Bagalkot, Karnataka, India

<sup>4</sup>Department of Medical and Pediatric Oncology and Hematology, Nanjappa Hospital, Shimoga, Karnataka, India

<sup>5</sup>Department of Oncopathology, Mahatma Gandhi Cancer Hospital, Miraj, Maharashtra, India

<sup>6</sup>Department of Surgical Oncology, Mahatma Gandhi Cancer Hospital, Miraj, Maharashtra, India

**Address for correspondence** Mayadevi Poojari, MBBS, DMRT, DNB, Department of Radiation Oncology, Mahatma Gandhi Cancer Hospital, Miraj 416410, Maharashtra, India (e-mail: mayapoojari29@gmail.com).

## South Asian J Cancer

### Abstract



Mayadevi Poojari

**Introduction** Follicular dendritic cell sarcoma (FDCS) is a rare neoplasm of antigen-presenting cells within the reticuloendothelial system primarily originating in lymph nodes, but in almost one-third of the patients, extranodal sites are involved including oral cavity, tonsil, gastrointestinal tract, soft tissue, and breast. The thyroid gland is an extremely rare location for FDCS and very few cases are reported in the literature.

**Case Report** Here, we present a 39-year-old man who presented with a swelling in the neck for 3 months and difficulty in breathing for 15 days. Following left hemithyroidectomy, histopathologically and immunohistologically, he was diagnosed as FDCS of thyroid arising in Castleman's disease. He received adjuvant radiation treatment. The patient had favorable prognosis with no evidence of disease for 6 years after treatment till date.

**Conclusion** The aim of this report was to present the rare site of FDCS arising in the thyroid gland, the vital role of immunohistochemistry in diagnosis, and effectiveness of multimodality treatment for favorable prognosis.

### Keywords

- ▶ follicular dendritic cell sarcoma
- ▶ extranodal
- ▶ thyroid
- ▶ Castleman's disease
- ▶ thyroidectomy
- ▶ radiotherapy

DOI <https://doi.org/10.1055/s-0044-1791958> ISSN 2278-330X

**How to cite this article:** Poojari M, Madabhavi I, Pol J, et al. Follicular Dendritic Cell Sarcoma of the Thyroid Gland: A Rare Case Report. *South Asian J Cancer* 2024;00(00):00–00.

© 2024. MedIntel Services Pvt Ltd. All rights reserved.

This is an open access article published by Thieme under the terms of the Creative Commons Attribution-NonDerivative-NonCommercial-License, permitting copying and reproduction so long as the original work is given appropriate credit. Contents may not be used for commercial purposes, or adapted, remixed, transformed or built upon. (<https://creativecommons.org/licenses/by-nc-nd/4.0/>)

Thieme Medical and Scientific Publishers Pvt. Ltd., A-12, 2nd Floor, Sector 2, Noida-201301 UP, India

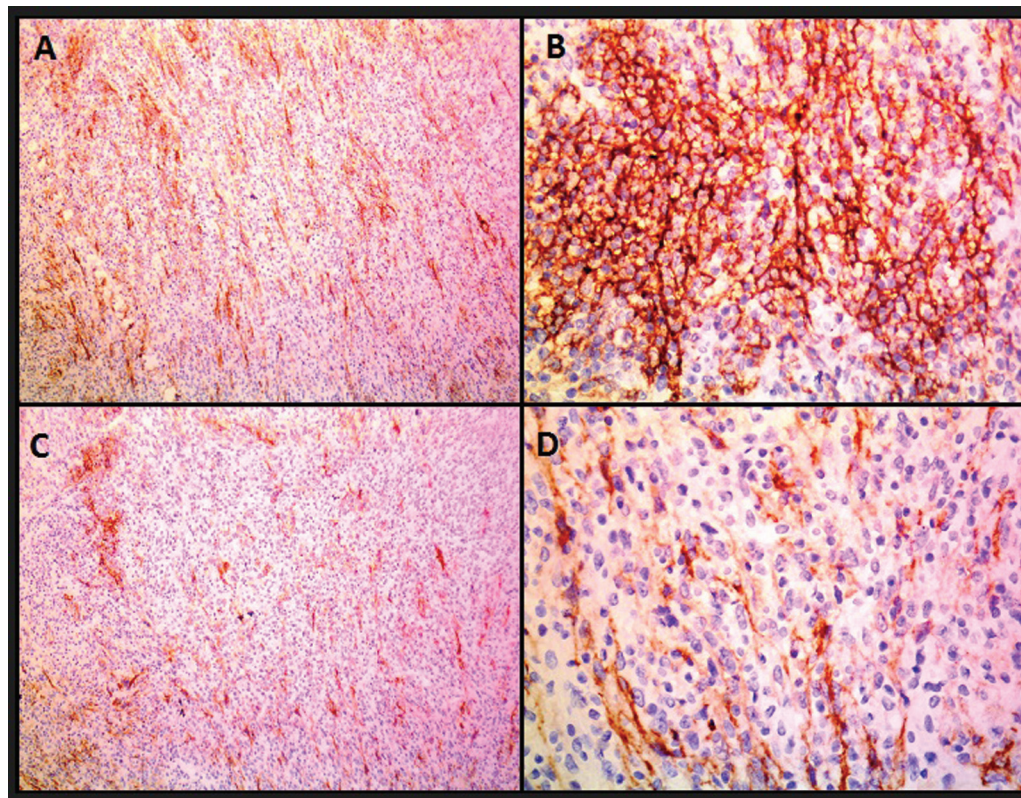
## Introduction

Follicular dendritic cell sarcoma (FDCS) was first described by Monda et al in 1986, which was based on four cases of unilateral cervical lymphadenopathy.<sup>1</sup> It is an uncommon lymph node malignancy of antigen-presenting cells of the B cell follicles. Most patients present with cervical or axillary lymphadenopathy; however, extranodal sites may be involved, including oral cavity, tonsil, gastrointestinal tract (GIT), soft tissue and breast, in almost one-third of the patients.<sup>2</sup> In 1994, Chan et al reported the first two cases of extranodal FDCS, both involving the oral cavity. The thyroid is an extremely rare location for primary FDCS to occur. To the best of our knowledge, there are only five reported cases of thyroid FDCS in the literature published in English to date. Here, we present a case of extranodal FDCS arising in thyroid in a 39-year-old man who presented with a swelling in the neck for 3 months and difficulty in breathing for 15 days. Following left hemi-thyroidectomy, a histopathological and immunohistological diagnosis was confirmed as FDCS arising in thyroid gland with Castleman's disease. He received adjuvant radiation treatment. The patient had favorable prognosis with no evidence of disease for 6 years after treatment till date.

## Case Report

A 39-year-old male presented with the complaints of swelling in the neck for 3 months and difficulty in breathing for 15 days. On evaluation, there was nodule in the left lobe of

thyroid measuring 8 × 5 cm. He underwent left hemi-thyroidectomy in an outside hospital. Postoperative histopathological report showed as grossly a well-circumscribed nodular gray tan mass measuring 8 × 6 × 4 cm and another separate brownish soft mass measuring 2.5 × 2 × 1.2 cm with five lymph nodes, with the largest measuring 2 × 1 × 0.5 cm. Microscopically, the first gray tan mass composed of diffuse sheets of spindle-shaped cells with pleomorphic vesicular, folded nuclei with focally prominent nucleoli and moderate eosinophilic cytoplasm on the background of stroma with diffuse infiltration by lymphocytes and plasma cells forming lymphoid follicles with regressively transformed germinal centers resembling Castleman's disease. Mitosis was sparse. The inked peripheral surgical margins were involved by the lesion. The brownish mass showed thyroid follicles with focal Hurthle cell change and the lymph nodes with reactive lymphoid hyperplasia. So, there were two differential diagnoses: (1) FDCS arising in Castleman's disease; (2) inflammatory myofibroblastic tumor and immunohistochemistry (IHC) was advised. On IHC, the tumor cells expressed CD 35 (dim), CD 21 (focal), CD 23 (focal), fascin, LCA, vimentin, EMA, S-100 protein, and D2-40 (podoplanin; **-Fig. 1**), whereas they were immuno-negative for CD 20 and CD 3; hence they were diagnosed as FDCS of the thyroid gland. As the thyroid lesion was malignant, further evaluation was done. Positron emission tomography (PET) computed tomography (CT) showed postoperative inflammation in the operative bed with small regional nodes in left level IV measuring 4 mm with SUVmax of 1.45, which was not significant; there was no metastatic disease elsewhere in the body.



**Fig. 1** Immunohistochemistry images showing tumor cells expressing CD21 (A, B) and CD23 (C, D) (A and C: ×100; B and D: ×400).

Then he was referred to the Radiation Oncology department of our institute. He was planned for adjuvant radiation treatment. A head and neck immobilization device with hands by the side of body in supine position was used. CT simulation was done with intravenous contrast from vertex to T4 with 3 mm slice cuts. The images were imported to TPS. He was planned and treated with external beam radiotherapy at a dose of 60 Gy in 30 fractions to the primary tumor bed at 2 Gy per fraction and 54 Gy in 30 fractions to the bilateral neck level II to IV at 1.8 Gy per fraction for 5 days a week using the Rapid Arc technique. He tolerated the treatment well. At the end of treatment, he had grade 2 dermatitis and radiation therapy-induced hoarseness.

He was referred to a medical oncologist for opinion of adjuvant chemotherapy. He was advised observation and follow-up. The patient is on regular follow-up every 3 months thereafter. On the first follow-up, his thyroid function tests (TFTs) were within normal limits. On the second follow-up, 6 months postradiation, he had complaints of facial swelling since 1 week and bilateral lower limb and low back pain. He was clinically locoregionally controlled but features of hypothyroidism were present, so was evaluated with TFTs: T3 = 0.1 ng/mL, T4 = 0.42 µg/dL, TSH ≥ 150 uIU/mL. He was started on Tab Eltroxin 50 mcg once a day (OD) and reviewed after 3 months with TFT and serum calcium levels. But his TSH was >150 uIU/mL, T3 = 0.6 ng/mL, T4 = 3.5 µg/dL, and S calcium = 7.1 mg/dL; hence the dose of Tab Eltroxin was increased to 100 mcg OD and calcium supplements started. He was reviewed 3 monthly for 2 years then 6 monthly for the next 3 years and then annually thereafter with TFT 3 monthly and radiological imaging (CT/PET CT) 6 monthly. Latest TFT showed T3 = 1.12 ng/mL, T4 = 6.88 µg/dL, and TSH = 19.33 uIU/mL. He is doing good with no evidence of disease for 6 years after treatment till date and is on thyroid and calcium supplements.

## Discussion

Dendritic cell neoplasms are extremely rare tumors arising from antigen-presenting cells. There are four types of dendritic cells in lymph nodes: follicular, interdigitating, Langerhans, and histolytic/fibroblastic cells. Accordingly, the World Health Organization (WHO) has classified dendritic cell neoplasms into five groups: Langerhans cell histiocytosis, Langerhans cell sarcoma, interdigitating dendritic cell sarcoma, FDCS, and not specified otherwise.<sup>3</sup> FDCS was first described by Monda et al in 1986.<sup>1</sup> It has been defined as a low-grade sarcoma with follicular dendritic cell differentiation by the WHO. It is a rare neoplasm of antigen-presenting cells within the reticuloendothelial system primarily originating in lymph nodes, but in almost one-third of the patients, extranodal sites are involved, including oral cavity, tonsil, GIT, soft tissue, and breast. The thyroid gland is an extremely rare location for FDCS and very few cases are reported in the literature (→Table 1).

Thyroid FDCS primarily involves patients 36 to 65 years old, and the average age of diagnosis for FDCS is 50 years.

Based on previous reports, it occurs more commonly in women. Clinically, they present with a single, slow growing, well-circumscribed mass in the neck, without a history of pain, dysphagia, hoarseness, or loss of weight and appetite. Positivity for Epstein–Barr virus in situ hybridization and Castleman's disease are considered as known risk factors for FDCS. Castleman's disease is a lymphoproliferative disorder, frequently characterized as giant lymph node hyperplasia. However, these risk factors were not found in most of the reported cases.

Diagnosis of thyroid FDCS is extremely challenging. Radiologically, imaging studies including ultrasonography of the neck and contrast-enhanced CT scan which gives details of tumor size and lymph nodal status are used. Ultrasonography-guided fine-needle aspiration cytology is a valuable tool for diagnosing thyroid FDCS. On gross examination, thyroid FDCS is usually described as a single and well-circumscribed mass and the cut surface of the tumor shows a homogeneous gray tissue. Histologically, the thyroid FDCS is primarily a spindle cell tumor composed of spindle- or oval-shaped cells demonstrating a storiform or whorled growth model, organized in sheets, nets, and focal fascicles. IHC is a very essential indicator for accurate diagnosis of thyroid FDCS. Thyroid FDCS cells are typically positive for CD21, CD23, CD35, and vimentin, show variable positivity for CD68, CD45, S100, and epithelial membrane antigen, and are negative for cytokeratin, smooth muscle actin, CD34, and CD3. Recently, it was demonstrated that podoplanin (D2–40) is a mucin-type transmembrane glycoprotein that shows strong expression in FDCS but is not expressed in normal or neoplastic lymphoid cells. Clusterin is another apoptosis-related glycoprotein that is highly expressed in FDCS and could be used to distinguish FDCS.

Although the optimal treatment for FDCS is not known because of the limited experience, the current approach is to apply therapeutic guidelines similar to that for soft tissue sarcomas of high grade. Complete surgical resection is the treatment of choice, with the possibility of adjuvant radiation or chemotherapy. Adjuvant radiotherapy prolongs disease-free survival and consolidation improves local control rates in incompletely or completely resected FDCS. A definitive dose of 5,400 cGy at 180 to 200 cGy per day 5 days per week is used to a completely resected involved field. Radiation can also be used for palliating signs and symptoms from primary or at the metastatic sites.<sup>4</sup>

## Conclusion

Thyroid is an extremely rare site for extranodal FDCS. Here, we present a 39-year-old male who presented with swelling in the neck and breathing difficulty, underwent left hemithyroidectomy with lymph node excision, and was diagnosed as FDCS in the background of Castleman's disease. IHC plays a very vital role in the diagnosis as the diagnosis is very challenging. Complete surgical excision is the treatment of choice. The role of adjuvant radiotherapy and chemotherapy is undetermined but it prolongs disease-free survival

**Table 1** List of published papers of FDGS of the thyroid gland

Sr. No.	Sex/age (years)	Treatment	IHC positivity	Adjuvant treatment	Follow-up	Reference
1	Female/65	Total thyroidectomy + right modified radical neck dissection	CD21, vimentin	Radiotherapy	36 months, NED	<sup>5</sup>
2	Female/58	Subtotal thyroidectomy	CD35, vimentin, CD68, lysozyme, S100, fascin, CD45, CD45RO, HLA-DP, DQ, DR	NA	NA, NA	<sup>5</sup>
3	Female/44	Total thyroidectomy, central compartment dissection, parathyroid implantation	CD21, CD23, vimentin, clusterin, fascin, podoplanin, CXCL13	Radiotherapy	NA, NA	<sup>5</sup>
4	Female/63	Total thyroidectomy + B/L modified radical neck dissection	CD4, CD21, CD35, CD43, CD45 (LCA), CD68, and CD123	Chemotherapy	8 months, NED	<sup>5</sup>
5	Female/48	Total thyroidectomy + left modified radical neck dissection	CD21, CD35, CD23, vimentin, CD68, S100 (partial), CD5, and terminal deoxynucleotidyl transferase (TdT)	None	11 months, NED	<sup>5</sup>
6	Male/39	Left hemithyroidectomy	CD 35 (dim), CD 21 (focal), CD 23 (focal), LCA, vimentin, EMA, S- 100 protein, fascin and D2-40	Radiotherapy	72 months, NED	Present case

Abbreviation: FDGS, follicular dendritic cell sarcoma.

and consolidation improves local control. He received adjuvant radiotherapy and is with no evidence of disease for 72 months till date, hence adjuvant radiation improves the local control rate and prolongs disease-free survival.

#### Author Contributions

M.P., I.M., J.P., and S.D. conceived and designed the article, made critical revisions, and approved the final version. M.P. and I.M. collected data and literature and wrote the first draft of the manuscript. M.P., I.M., and J.P. contributed to the writing of the manuscript. M.P. and I.M. drew the tables. All authors reviewed and approved the final version of the manuscript.

#### Conflict of Interest

None declared.

#### References

- Monda L, Warnke R, Rosai J. A primary lymph node malignancy with features suggestive of dendritic reticulum cell differentiation. A report of 4 cases. *Am J Pathol* 1986;122(03):562-572
- Chan JK, Fletcher CD, Nayler SJ, Cooper K. Follicular dendritic cell sarcoma. Clinicopathologic analysis of 17 cases suggesting a malignant potential higher than currently recognized. *Cancer* 1997;79(02):294-313
- Madabhavi I, Patel A, Modi G, Anand A, Panchal H, Parikh S. Interdigitating dendritic cell tumor: a rare case report with review of literature. *J Cancer Res Ther* 2018;14(03):690-693
- Fareed MM, Memon MA, Rashid A, et al. Follicular dendritic cell sarcoma of the neck with pulmonary metastases. *J Coll Physicians Surg Pak* 2011;21(09):561-563
- Seyed-Alagheband S-A, Shahmoradi M-K, Adeli O-A, Shamsi T, Soholi M, Shekouhi R. Follicular dendritic cell sarcoma of the thyroid gland in a patient with preexisting Hashimoto's thyroiditis: a rare case report with a literature review. *Case Rep Oncol* 2021;14(03):1698-1705