Expert Exchange

Pedal Bypass for Critical Limb Ischemia

MODERATOR: Frank J. Veith, M.D.
PANELISTS: Enrico Ascher, M.D.
Peter Gloviczki, M.D.
Audra Noel, M.D.

ABSTRACT **This case panel discussion addresses some of the problems and judgment decisions required in a patient with extensive forefoot gangrene, a stenosis of the superficial femoral artery (SFA), and occlusions of all three leg arteries in the mid and upper leg. With extensive foot debridement to the transmetatarsal level, balloon angioplasty of the SFA, and a vein bypass to the distal anterior tibial artery, a functional foot remnant was saved. The timing of the various procedures, technical details regarding them, and other issues are discussed.**

Keywords **Pedal bypass, foot gangrene, foot ischemia, vein bypass, transmetatarsal amputation**

Moderator: Dr. Audra Noel, a vascular fellow at the Mayo Clinic, will start our discussion with the case presentation. Dr. Noel?

Dr. Noel: A 49-year-old diabetic, hypertensive man presented with right foot gangrene. He has had progressive infection and tissue loss of the right foot over the past two months, despite surgical debridement, oral, and intravenous antibiotics, and was offered below-knee amputation at an outside hospital. He denies rest pain or claudication. He has had diabetes for 15 years, which is currently poorly controlled on oral agents, and he takes one antihypertensive medication. He is a non-smoker and has no history of hyperlipidemia.

F.J.V., Professor and Chief, Vascular Surgery Services, Department of Surgery, Division of Vascular Surgery, Montefiore Medical Center, Albert Einstein College of Medicine, Bronx, NY; E.A., Professor of Surgery, SUNY Health Science Center at Brooklyn; Director, Vascular Surgery Services, Maimonides Medical Center, Brooklyn, NY; P.G., Professor of Surgery, Mayo Medical School, Chair, Division of Vascular Surgery, Mayo Clinic, Rochester, MN; A.N., Vascular Fellow, Division of Vascular Surgery, Mayo Clinic, Rochester, MN.
 0894-8046,p; 2000,12,2,131,150,ftx,en;pvs00075

On physical examination, he was afebrile. Femoral pulses were 3+ (out of 4) bilaterally, the left popliteal pulse was 2+, and the left pedal pulses were 1+-2+. The affected right leg had no distal pulses, only monophasic Doppler signals were present in the posterior tibial and dorsalis pedis. The pedal arteries were non-compressible and the transcutaneous oxymetry value (T_cP0_2) was 41 mmHg at the right forefoot with a decrease to 35 after 3 minutes of elevation. Light touch and sensation were diminished in both feet. There was severe wet gangrene of the distal plantar forefoot with gangrene of the second and third toes (Figs. 1A,B).

A B

Fig. 1 Right foot at time of admission. **(A)** Extensive right plantar gangrene with exposed 2nd and third metatarsal bones. **(B)** Dorsum of right foot with gangrene of 2nd and 3rd toes.

The patient was given intravenous antibiotics and underwent operative debridement of the foot (Fig. 2). Angiography was then performed (Figs. 3A-G), which confirmed stenosis of the superficial femoral artery and severe infrapopliteal occlusive disease.

Moderator: Dr. Noel, you have clearly presented the case with excellent pictures and reproductions of the arteriograms. I would like to start by asking Dr. Ascher what is his opinion about the initial treatment at the other hospital over the past two months?

Fig. 2 Right foot after initial debridement and amputation of 2nd and 3rd toes.

Dr. Ascher: This is an appropriate question. I would have had a different approach to the initial treatment. I believe that minor debridements and antibiotic therapy, even when given intravenously, would not suffice for this patient's healing potential.

Moderator: Let me ask one more follow-up question. If just the toes, the second and third, were gangrenous and there was some drainage, how would you go about debriding that foot?

Dr. Ascher: First, before debriding it I would like to know whether the patient has wet gangrene or just a dry gangrene. Even if it is wet gangrene and localized to the distal portion of the foot, I will give a tremendous priority to the circulation of the foot. I would examine the pulses, understanding that if the arteries are calcified circumferentially, I may be misled by the pulse exam, and certainly I would like to have noninvasive testing to assure that this patient has enough circulation to heal the debridement site. Circulation is a priority in this situation.

Moderator: And if the circulation was, in your opinion, diminished, what would you do?

Dr. Ascher: If the patient has localized gangrene, I will work him up with either an arteriography or duplex arterial mapping prior to performing the debridement.

Moderator: We will get to our other panelists in a moment, but the question I wanted to ask, if in fact the two toes were gangrenous and obviously

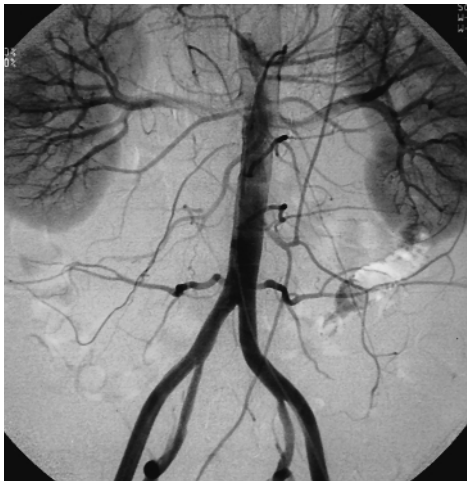

A

B

C

Fig. 3 Aortogram with right lower extremity run-off. **(A)** Normal abdominal aorta with normal bilateral iliac arteries. **(B)** Right common femoral, proximal superficial femoral (SFA) and profunda femoris are patent without disease. **(C)** Mid-SFA stenosis.

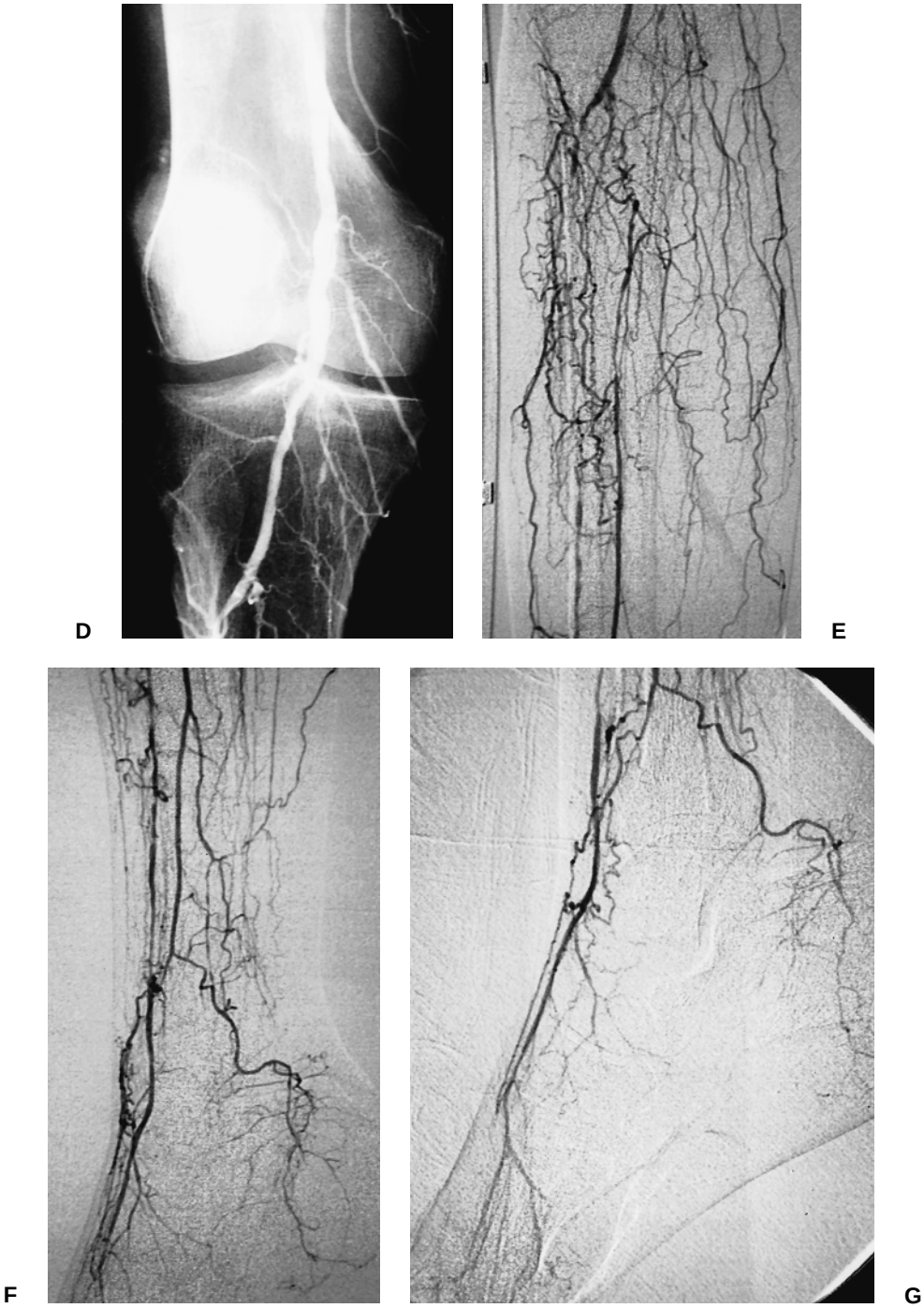

Fig. 3 *continued.* **(D)** Popliteal artery is patent with minimal disease. **(E)** Below-knee popliteal artery with occlusion of tibial arteries. Reconstruction of diseased peroneal and anterior tibial arteries in the distal leg. **(F)** Diseased peroneal and anterior tibial arteries at the ankle with reconstitution of the dorsalis pedis artery. **(G)** Magnified image of dorsalis pedis artery.

there was infection associated with it, would you consider any possible debridement that this patient had as adequate treatment? In other words, what would be a *sine qua non* about debridement?

Dr. Ascher: Of course, the debridement would have to include all the obviously involved segments of the foot, not only the toes.

Moderator: So what you are saying is that, at the very least, the toes must go. Let me ask Dr. Gloviczki, what instrument do you use for doing your debridement?

Dr. Gloviczki: I would probably use everything that the orthopedic surgeons would use, but certainly forceps, knife, scissors, and a good bone cutter.

Moderator: What I was trying to get at is that, we use rongeurs of various sizes. We use the rongeurs to take out the chunks of dead and infected, gangrenous tissue, and, of course, the associated bones, tendons, etc. As an instrument the rongeur works very well because it holds the tissue and when the grasped tissue doesn't come out, you can just cut it out with a scalpel.

Dr. Ascher: Dr. Veith, can you just perhaps remind us about thrombosed veins and some of your other suggestions for gauging how much tissue you have to remove?

Moderator: One of the things we have always talked about is that as one cuts through infected tissue, one sees these little purple dots, about a millimeter in diameter with a halo of purple around them. These are thrombosed blood vessels, and the vessels get thrombosed because of the coagulase released by the bacteria. If one gets rid of all the fat containing those little blood vessels, one will be beyond the infection. Thus, the debridement is often much more extensive in the deeper tissues underlying the skin than it is of the skin. However, it is vital to get rid of all presumably infected fat and necrotic tissue, even when the fat itself looks fairly normal. Dr. Gloviczki, have you ever noticed these little purple spots?

Dr. Gloviczki: Despite arterial bleeding, that segment with the thrombosed veins has to come out, otherwise the wound may not heal. We have seen that and it is an important point to make.

Moderator: Dr. Gloviczki, looking at the pictures of this foot [see Figs. 1A,B], particularly the plantar aspect, do you think this foot is salvageable?

Dr. Gloviczki: Primary amputation certainly crossed my mind numerous times when I saw the patient. In this picture (Fig.1A,B), it looks pretty dry, but I can tell you there was pus, not only from the plantar surface, and it just smelled terrible, but pus was dripping out from the dorsum of the foot, from under the skin. Truly, this was the worst foot I have seen in a few years, and I am sure it is among the serious ones both of you have seen in New York. I did not make any promises to the patient. The plan was to drain the pus first and also debride the necrotic tissue and see what was viable and what was not. As you know, diabetic patients may have extensive superficial necrosis but still have some viable tissue underneath. The forefoot is potentially a part

of the foot that you can live without, and the heel in this foot was the only thing that looked a little promising.

Moderator: So, you felt the foot was possibly salvageable but not for sure? Dr. Ascher, would you agree with that?

Dr. Ascher: Yes, I agree, I think it is a pretty badly infected foot. I would like to ask Dr. Noel if the patient had any suspicion of gas gangrene, because that is an important point to bring up.

Dr. Noel: He didn't have crepitus. He did have x-rays of the foot but they did not show evidence of gas gangrene.

Moderator: What if the foot films did show gas? Would that make the diagnosis of gas gangrene?

Dr. Gloviczki: I would say, if the smell is sweet and the crepitus is there, amputation is the way to go.

Moderator: I think the important point to make, is that with some infected diabetic feet there can be a lot of gas in the tissues, but it is not a true "clostridial" infection. The way I rule in a "clostridial" infection is that, if the patient is very toxic and very sick, then one has to start worrying about a gas infection. If the patient is not terribly sick, with a high fever, tachycardia, or confusion, then I disregard gas in the tissue, even if it shows up on the x-ray.

Dr. Gloviczki: Should we ask Dr. Noel about the patient's general condition?

Moderator: How sick was the patient? Obviously, he couldn't have been too sick, he had this condition for two months.

Dr. Noel: He was afebrile, not septic or toxic.

Moderator: So, Dr. Gloviczki, would you agree, even if there was gas in the tissue, you wouldn't consider this a clostridial infection?

Dr. Gloviczki: Not necessarily, but I certainly want to get a gram stain quickly and if there were gram positive rods that would make me suspicious.

Moderator: We have not seen a true clostridial gas infection of the foot in the last ten years in our institution. However, we have seen many infected feet that have air in them.

Now, to get back to the question of: "should you debride this foot?", assuming that circulation is poor on the basis of the pulse exam and noninvasive evaluation. Would you do a debridement first-excising all infected tissue-we call it excision and drainage? (That is where the rongeur comes in.) Would you do that before you did an arteriogram, or would you do the arteriogram first?

Dr. Gloviczki: No. Clearly, if there is a wet gangrene with abscess or phlegmon, I would drain that first and then do the arteriogram.

Dr. Ascher: I would agree in part with that. The definition of wet gangrene is not too clear to me at times. If you have an open wound and the skin here is totally uncovered and the area is necrotic, the wound is already open. Perhaps he has a deep-seated abscess and an MRI would probably be a good idea if you are concerned about this. But, it is a somewhat chronic

indolent wound at this point, despite the apparent drainage, so I would treat this more as a chronic large ulceration with a scary foot, rather than a wet or gas forming type of infection. I would be more inclined to study this patient's arterial circulation, either at the same time or prior to removing the infected tissue.

Moderator: All three of us agree that early arteriography and management of this patient's foot would be indicated. Dr. Gloviczki, you wouldn't disagree with that?

Dr. Gloviczki: I would not. However, this patient clearly had an abscess.

Moderator: One other point—we don't make much of a differentiation between wet and dry gangrene. Obviously, if there is pus dripping from the foot, with cellulitis and swelling, it is infected; but even when that is not the case, there can be deep-seated abscesses and infection in the foot. And until you get to the OR and actually open the wound-you will not know what the degree of infection and ischemia is precisely. Would any of you take issue with that?

Dr. Gloviczki: If it is a very localized dry gangrene I would not necessarily do a separate operation before the revascularization.

Moderator: We all three agree with that. We all agree this is a possibly salvageable foot, but that the patient will more than likely end up losing the entire forefoot and end up with a forefoot amputation at a level proximal to the metatarsals. Is that a fair statement? What I would like to ask, starting with Dr. Gloviczki, is just whether or not salvaging some of the tarsal bones and the heel is a worthwhile thing to do?

Dr. Gloviczki: That is an important question. Just looking at the foot, not knowing how much healthy tissue is going to remain, it is difficult to answer. I was hoping that we could preserve the proximal portions of the metatarsal bones. Certainly a Chopart amputation doesn't provide you with as much of a walking surface as a proximal transmetatarsal would.

Moderator: Dr. Ascher, do you believe in the named transtarsal amputations-the Chopart or the Lisfranc amputations?

Dr. Ascher: I feel that in the presence of extensive gangrene of the foot, excising the dead tissue should be the goal. Described techniques, such as Symes, Chopart, or Lisfranc, may entail removing potentially healthy tissue. The wound may also heal by allowing more surface area for the patient to walk on than the areas obtained with more standard techniques.

Moderator: Just to summarize, all of us believe that the heel and some portion of the tarsal bones constitute a worthwhile remnant of a foot in most of these elderly patients. Such a radical forefoot amputation is better than a below-knee amputation. Although there is a school of thought that says if you can't salvage at least a transmetatarsal amputation, you are better off doing a below-knee amputation. The three of us don't agree with that and yet it is a universally held view. Dr. Gloviczki, would you agree with that?

Dr. Gloviczki: I would agree with that. A lot depends on the potential of functional recovery, the age and the motivation of the patient, as well. This was a young, motivated patient and if he would need a Chopart or Lisfranc, that is enough to keep the foot suitable for ambulation.

Moderator: While we are on the subject of local short or extensive amputations of the foot, if you do a transtarsal amputation of some form, Dr. Gloviczki, do you cut the Achilles tendon to prevent the pressure, necrosis on the distal end of the plantar flap?

Dr. Gloviczki: Not routinely.

Dr. Ascher: In my experience, many of these patients will develop severe contraction of the Achilles tendon, which causes plantar flexion, and eventually will be the culprit for breakdown of the amputation site. So I probably would transect the Achilles tendon.

Moderator: Just a little subcutaneous cutting with a #11 blade?

Dr. Ascher: Yes. What would you do?

Moderator: We do it when we think about it. If we do not, the patients sometimes get an ulcer on the end of the foot. Then we go back and cut the tendon under local anesthesia. But, it is certainly something to at least consider.

Let's get to the interesting aspect of the vascular reconstruction in this patient. We all have the arteriograms in front of us and there is little doubt that the circulation that we see shows fairly straightline flow to the distal popliteal with the one exception that in the mid-superficial femoral there appears to be a fairly high grade lesion (see Fig. 3C). Would you agree with that Dr. Ascher?

Dr. Ascher: I agree, but I would like to add one other observation. If you look at the popliteal artery, just above the knee, there is a slight dilatation of the artery, which makes me suspect that this patient may have a small popliteal aneurysm (see Fig. 3D). Do you agree?

Dr. Gloviczki: I agree, there is a little bit of dilatation. I was also wondering if the distal popliteal was a true popliteal or if there is a high origin of an anterior tibial artery.

Moderator: That is a very good point. There is really no way of knowing that. The size alone would make me think that it is probably a distal popliteal, and not an anterior tibial arising at the level of the knee joint. It would be a pretty big anterior tibial if that were the case, but it could be that. We can also see the high grade stenosis in the mid-SFA. To summarize, we now have a patient with a diminished popliteal pulse, secondary to a high grade stenosis in the SFA, and then good circulation down to the trifurcation. Then all the main arteries in the leg are occluded at one point or another. Do we agree? (yes). Dr. Ascher, are there any other studies that you would get? You have not done anything with the foot at this point.

Dr. Ascher: I would get a duplex arterial mapping of his infrainguinal circulation prior to debriding the foot. Of course, I would agree with an arteriogram if the former test was not possible.

Moderator: Let's say you get the arteriogram that we have seen. Are there any other studies that you would undertake before proceeding with some form of operative intervention?

Dr. Ascher: I would probably obtain a pulse volume recording of the foot just to confirm that the circulation at the forefoot level is poor. But really that would not dissuade me from going ahead and planning to revascularize this patient.

Moderator: You wouldn't pay much attention to them?

Dr. Ascher: No.

Moderator: Dr. Noel, did you get any kind of additional pulse volume recording or pulse waves in the forefoot or the toes?

Dr. Noel: We had the transcutaneous oxygen levels; we did not obtain pulse volume recordings.

Moderator: Tell us what those transcutaneous oxygen levels mean. Are they bad or good?

Dr. Noel: His values were actually higher than we would anticipate, especially with the amount of edema in the leg. They were above 40, and those values would predict healing. The values decreased slightly with elevation.

Dr. Gloviczki: We have used transcutaneous oxymetry rather than toe pressures in diabetic patients to document the extent of ischemia. The absolute oxygen pressures tell us more than the foot/chest index. In our experience if the $TcPO_2$s are between 20 and 40, that shows diminished perfusion and questionable wound healing. If they are less than 20, then the chances of healing of amputation at this level are low. We do a 3-minute elevation test, which is a stress test. In those patients, who have values between 20 and 40, if their values drop down close to zero after elevation, then chances of healing after amputation are poor.

Dr. Ascher: Can I ask, whether you think that the mapping of the foot with transcutaneous PCO_2 is more reliable than one single measurement?

Dr. Gloviczki: We normally measure it at two sites and on the dorsum of the foot. We do more measurements if we use it for evaluation of amputation levels.

Moderator: Dr. Gloviczki, there is a pretty rich collateral network in the upper portion of the leg where all three arteries are occluded (see Fig. 3E). You have what you consider by your standards pretty good transcutaneous PO_2s in the foot. Do you think that perhaps local excision of all the necrotic material, leaving the viable skin, might result in a wound that could be healed?

Dr. Gloviczki: I think clearly the measurements here were probably taken on the mid-dorsum of the foot and I just don't see how this would heal.

Moderator: If it was a trivial amputation, like a toe amputation, it might heal, but with this extent of gangrene, infection, and necrosis, you would agree that in all likelihood you have got to get the maximal amount of blood

to the foot that you can. That would require some form of bypass of the obstructive segments of the tibial arteries. Is that your feeling?

Dr. Gloviczki: This patient had occlusion of all tibial and peroneal vessels, at least in segments. The peroneal is the only good artery that shows up for a while, but the posterior perforating branch of the peroneal is the better one, which has no visible plantar vessel run-off. The anterior tibial and dorsalis pedis artery is clearly usable for a bypass only at the level of the ankle and a little bit lower.

Moderator: But the point is, you don't think that one should do just a debridement. What you really need is straightline flow to the foot. Would that be your opinion?

Dr. Gloviczki: Yes.

Moderator: And Dr. Ascher, would you agree with that?

Dr. Ascher: Yes, absolutely.

Moderator: Now, are there any other tests that you get before you take this patient to the OR?

Dr. Ascher: No, I would not test further. I think we have enough evidence that this patient needs revascularization and extensive debridement of the foot.

Moderator: You assume that he has not had any vein utilization; you would not do a duplex of the saphenous veins or study his heart?

Dr. Ascher: No, we have the ability or at least request an arterial mapping by duplex, and we always include the venous mapping. I think it is very important because it can change the type of operation that we would be doing.

Moderator: You would do venous mapping, Dr. Gloviczki?

Dr. Gloviczki: I would always do venous mapping.

Moderator: Let's say the venous mapping showed that the greater saphenous in the thigh was 2 mm in diameter.

Dr. Gloviczki: That influences me a lot, but I have explored 2-mm veins and they turned out to be 3–4.

Moderator: Right, they usually end up 30–50% larger because they are not fully distended when you measure them on duplex. In any event, Dr. Gloviczki, would you study the patient's heart?

Dr. Gloviczki: In general, we do. Now, in this patient, obviously because of the abscess and the serious ischemia, this was not our priority. This patient, in addition, had no significant history of cardiac disease and had only one of the Eagle's criteria. So while we are very liberal in studying the heart in these patients, we do that selectively. This patient clearly was ready for an operation.

Moderator: Now, we get to the question, what operation should be done? First, could I ask Dr. Noel if you did a saphenous vein mapping?

Dr. Noel: We did, and the right great saphenous vein, along its entire length was greater than 3 mm in size.

Moderator: Good, and it went from the saphenofemoral junction down to the ankle?

Dr. Noel: Yes.

Moderator: So, it is a great vein—something that we almost never see in the Bronx. In any event, that gives you a lot of options. Let's say for purposes of discussion the vein wasn't that good. Would you consider doing an angioplasty of the SFA lesion? Bad vein, or vein only good in the thigh, and the SFA lesion with high grade stenosis, would you be willing to do an angioplasty first or not, Dr. Ascher?

Dr. Ascher: If the length of the vein is not sufficient to reach above the SFA lesion then I will consider an angioplasty and a short vein bypass. I am concerned about the possibility of this being a small popliteal aneurysm, so I would attempt to obtain inflow from the above-knee popliteal artery. I will definitely get a duplex scan of the popliteal artery to make sure it is not lined with clots.

Moderator: Good point. Dr. Gloviczki, would you favor doing an angioplasty of the SFA lesion to allow one to do a shorter bypass?

Dr. Gloviczki: Yes, if the lesion is very favorable and focal, I prefer short grafts to long grafts. Rather than going to the proximal third of the SFA, if I can stay in the distal popliteal, I would do that.

Moderator: I would, too. In fact, I would probably do that preferentially. Dr. Noel, was that done here?

Dr. Noel: Yes. See Figure 4, which shows the superficial femoral artery after percutaneous angioplasty.

Fig. 4 Mid-SFA after balloon angioplasty of stenotic lesion.

Dr. Ascher: Let me ask Dr. Veith a question. Why would you do that preferentially over a proximal SFA to distal vessel bypass?

Moderator: Because so few of our veins are perfect throughout their length.

Dr. Ascher: Assuming that you had a good vein, would you still do an angioplasty and short bypass over a longer bypass?

Moderator: It depends. If the patient is a sick old person, I probably would; if it was a young relatively healthy patient with a bad foot, I might choose to do the long bypass. But, that is certainly the minority of cases that we see. We have a lot of old sick people and a high incidence of bad veins.

Dr. Ascher: Would you originate your bypass below the knee or above?

Moderator: I preferentially would start below the knee. There are many advantages to doing a short bypass. It is a shorter operation; it is easier; there is no worry about kinking; and there is less chance of encountering a bad segment of vein. One can use the thigh vein and have the best vein that the patient has in the place where he has the most serious occlusive disease. In our patient today, as in many others, this vein is probably in the upper third of the extremity.

All right, so you did an angioplasty, and Dr. Noel, I assume it was successful?

Dr. Noel: Yes, it was.

Moderator: And you now had a bounding popliteal pulse?

Dr. Noel: We had a 2–3+ (out of 4+) palpable pulse.

Moderator: That would be in accord with what both Dr. Ascher and I would have done. Now, the next question, Dr. Ascher, is what would be your operation of choice, accepting the fact that you have looked at the popliteal artery with the duplex and it is not aneurysmal? Just dilated?

Dr. Ascher: If the saphenous vein is good below the knee, I will use this segment for the bypass.

Moderator: You would use the below-knee segment?

Dr. Ascher: Yes. I will preferentially do the in situ technique with multiple small incisions. My preference is to do the inflow from the popliteal below the knee and the outflow would be the anterior tibial just above the ankle—assuming, of course, that the popliteal is not aneurysmal.

Moderator: Dr. Gloviczki, why not use the peroneal artery, which is a pretty good artery, and do a shorter bypass?

Dr. Gloviczki: I have used the peroneal artery multiple times, if it looks like a good vessel that goes down to the foot. Honestly, in recent years I have preferred a good dorsalis pedis to a good peroneal artery. This patient, in my mind, needs pulsatile flow to the foot and the dorsalis pedis looks pretty good. I elected to go to the dorsalis pedis artery with the distal anastomosis.

Moderator: There is another reason why in this case we probably would use the anterior tibial artery: we try our best to make our distal anastomosis as far away from the foot as possible. From what I can see on this subtraction arteriogram, we would place the distal anastomosis above the ankle joint. The artery is actually widest 3 cm above the ankle joint. We would make every

effort to not go into the foot because of all the infection this patient has. We would go to the distal anterior tibial for the reasons that you mentioned and because the peroneal is a more difficult artery to expose.

Are there any other things you would do at the end of your procedure, Dr. Ascher?

Dr. Ascher: The branches of the peroneal are diseased. The terminal branches are not optimal, and the posterior tibial is not really filling via this connecting branch. The branch to the anterior tibial appears to be too small, so I would not consider the peroneal to be the outflow of choice. The anterior tibial artery is better, but I would be concerned about severe calcification of the vessel. Here is a patient who is diabetic and his arteries can be circumferentially calcified; and if I may ask a question of Dr. Gloviczki, if he finds a heavily calcified artery, how would he manage the problem locally?

Dr. Gloviczki: If the artery is circumferentially calcified, I would explore it proximally and distally, although I would not extend my incision tremendously. I use a tourniquet for control of bleeding intraoperatively, and if needed I use a second thigh and calf tourniquet. I use Visiblack needles with 7/0 or 6/0 prolene to suture through the calcium. When I open the artery and there is bleeding in spite of all this, then I usually clamp the artery distal to the proximal anastomosis as an adjunct; if there is still bleeding, I use a #2 Fogarty catheter to control the lumen.

Moderator: Getting a dry field after the arteriotomy is made can be one of the most difficult parts of the operation. How often does the tourniquet not work, what percent of the time, Dr. Gloviczki?

Dr. Gloviczki: In about 5–10% you may have some bleeding, but I have been very impressed that even very calcified vessels can be controlled by proximal tourniquets.

Moderator: We are not discouraged by calcified vessels, although they are somewhat more difficult to work on. In a paper that Dr. Ascher and I wrote several years ago, we showed that tibial bypass patency is good with heavily calcified vessels (Am J Surg 1986; 152:220).

Dr. Ascher: As a matter of fact, they are equal to noncalcified vessels. Occasionally, we are very frustrated by the fact that we want the tourniquet to work and it doesn't, and eventually we have to fracture the vessels partially and clamp then.

Moderator: I would say it is about 15–20% of the time that we are frustrated by the tourniquet not working perfectly. When it does work perfectly, it is a Godsend. Now, one other question. At the end of your procedure, once you have done your bypass, are there any procedures that you do at the end to assure a good result, Dr. Ascher?

Dr. Ascher: If we have trouble performing the anastomosis in a calcified vessel, as we expect the vessel to be, then I like to do a completion angiogram. Otherwise, I do not perform completion angiograms routinely.

Dr. Gloviczki: Let me get back a little to the technique. We prefer using nonreversed translocated graft and try to do short grafts. So, as in this patient

I would take saphenous vein, mostly from the thigh and move it down to avoid a skin incision at the ankle. I do not like the in situ technique at the ankle. I think that is a potential source of wound healing problems. You are ending up with two skin incisions, and I make a very strong point that I only have one skin incision in the distal third of the calf and foot-and that is the incision for the anastomosis. That is the technique I favor rather than the in situ technique or taking the calf vein. Our long-term results have been very acceptable using mostly translocated vein grafts (Fig. 5).

Moderator: Where would you place the tunnel for the graft in this patient? Would you place the graft in the anatomic location by tunneling through the interosseous membrane and coming down anterior to it, or would you go around the medial aspect of the tibia, subcutaneously?

Dr. Gloviczki: I prefer the proximal dorsalis pedis over the distal anterior tibial artery. My favorite site is a couple of centimeters distal to the ankle joint where the extensor hallucis longus tendon no longer covers the dorsalis pedis. I would do just a short 3 cm skin incision right over the dorsalis pedis that I localize with a hand-held Doppler.

Moderator: That is a good point. However, in this case, I might do a little bit more work to dissect out and use the distal anterior tibial. The thing that would prompt me to do so is the degree of infection in the foot. I would be very worried that the distal wound might get infected, so I would make an effort to go as far away from the foot as I could. If I did that I would take the time to tunnel through the interosseous membrane. This requires another incision in the anterolateral aspect of the leg and careful tunneling through the interosseous membrane. The graft then descends under the fascia in the

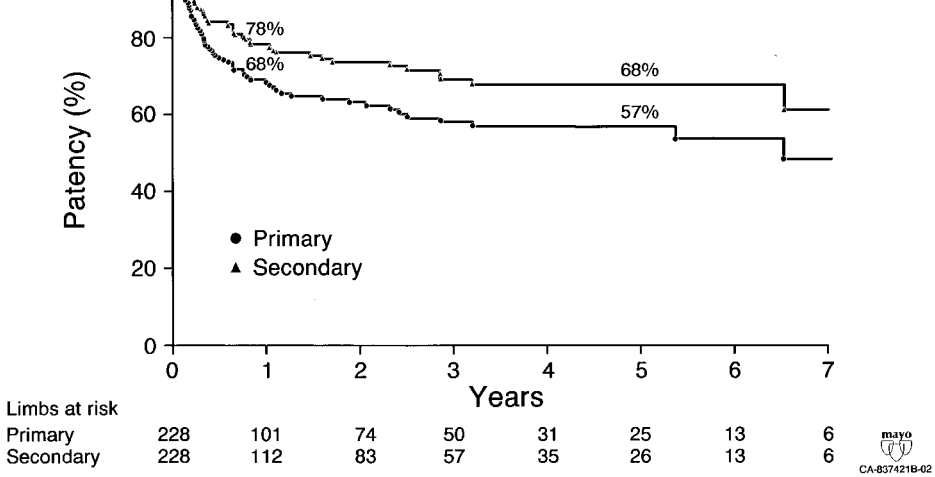

Fig. 5 Results of graft patency. (By permission from Am J Surg 1999;178:151–155, Ref. 12.)

anterior compartment. I agree the tendons can get in the way, but they can be cut. Dr. Ascher, you would have no problem tunneling because you are using an in situ graft, right?

Dr. Ascher: But, even if I use a reverse vein, I would rather go-at least my preference would be-to go over the bone subcutaneously, and subfascially for the remainder of the tunnel, rather than laterally or through the interosseous membrane.

Moderator: It is difficult to get to the distal anterior tibial when you tunnel the graft subcutaneously around the distal tibia. There is an angulation as you go deep to get to the distal anterior tibial. I agree completely that, when you are going to the dorsalis pedis, this subcutaneous tunnel works very well.

Are there any other points regarding your operative approach, Dr. Ascher?

Dr. Ascher: If the extensor hallucis longus is in the way of a smooth tunneling, would you hesitate in transecting it? I have done that several times.

Moderator: We never hesitate to cut any obstructing tendon. This is particularly true in this patient. There is not going to be a great toe for the tendon to go to. Cutting this tendon does not matter at all. One certainly doesn't want any of these tendons to compress the graft. Dr. Noel, why don't you tell us what you did and what happened to this patient after your operation?

Dr. Noel: As stated earlier, after initial debridement of the right foot (see Fig. 2), the patient underwent percutaneous angioplasty of the right superficial femoral artery (see Fig.4). Two days later he had a right popliteal to dorsalis pedis artery graft with reversed right greater saphenous vein harvested

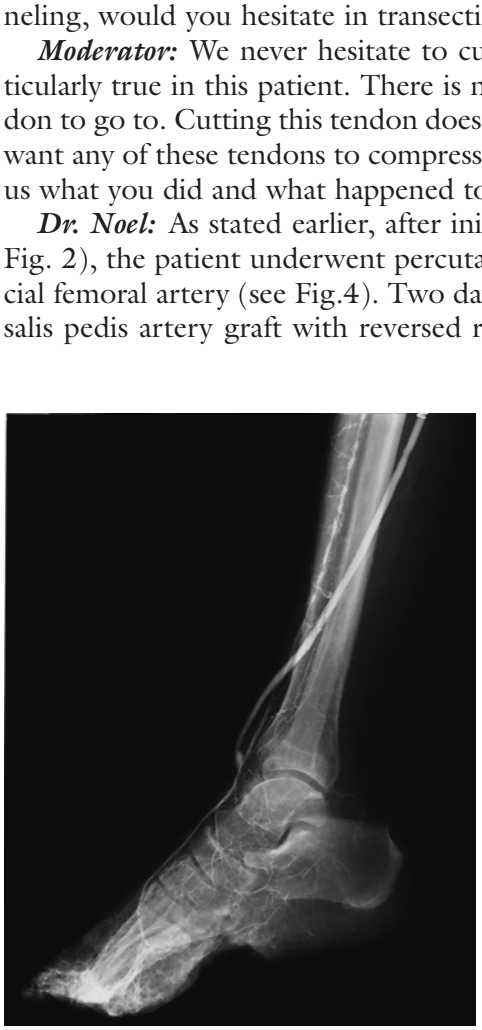

Fig. 6 Intraoperative arteriogram.

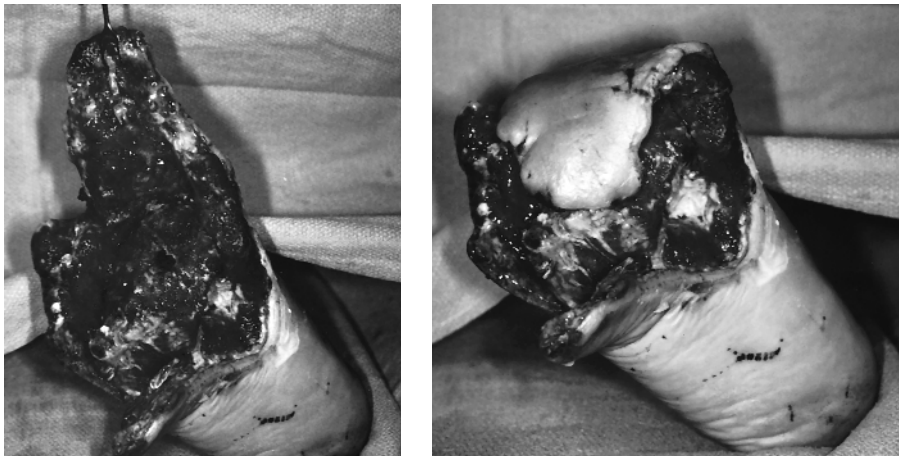

Fig. 7 **(A)** Right foot after transmetartasal amputation with preservation of dorsal skin flap. **(B)** Partial closure of amputation with dorsal skin flap.

from the thigh. The pedal anastomosis was done with tourniquet control (total time: 46 min) and operative microscope magnification. Vein graft flow was 90 cc/min. Intraoperative arteriogram showed a patent graft and no stenosis (Fig. 6). At the conclusion of the bypass procedure, he had further debridement of necrotic tissue from the foot.

Subsequently, the patient underwent multiple reconstructive procedures of the foot by Dr. Craig H. Johnson from our Division of Plastic Surgery, and Dr. Thomas C. Shires, from our Department of Orthopedic Surgery. The patient had a right transmetatarsal amputation with preservation of a dorsal skin flap 6

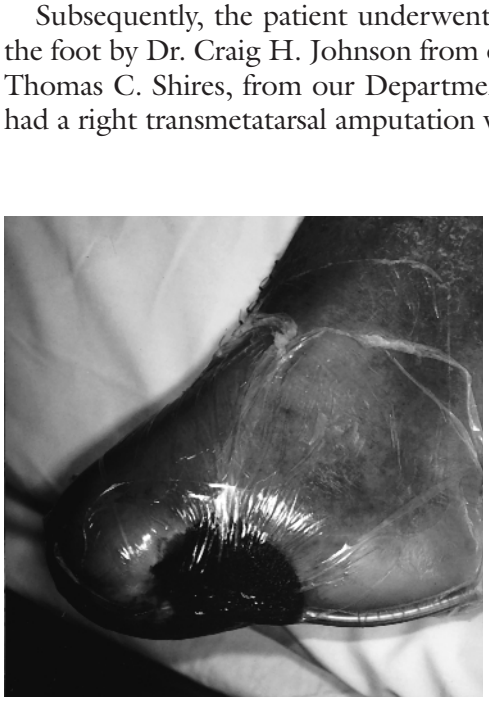

Fig. 8 Treatment of remaining open amputation site with vacuum system.

Fig. 9 Split-thickness skin graft to remaining open wound.

days after arterial reconstruction (Fig. 7A). He required further debridement and irrigation in the operating room five days later, and then had approximation of skin flaps (Fig. 7B) and placement of a wound vacuum closure device (Fig. 8). After 2 weeks of treatment with the vacuum device, he had placement of a split-thickness skin graft to the well-granulating tissue (Fig. 9). This skin graft healed well and the patient was able to ambulate with a walker.

Moderator: Thank you, Dr. Noel, for your excellent case report, and thank you all for your participation.

SELECTED READINGS

1. Ascer E, Veith FJ, Gupta SK. Bypass to plantar arteries and other tibial branches: an extended approach to limb salvage. J Vasc Surg 1988;434–441
2. Andros G, Harris RW, Salles-Cunha SX, et al. Lateral plantar artery bypass grafting: defining the limits of foot revascularization. J Vasc Surg 1989;10:511–521
3. Harris HW, Rapp JH, Reilly LM, et al. Saphenous vein bypass to pedal arteries: an aggressive strategy for foot salvage. Arch Surg 1989;124:1232–1236
4. Taylor LM, Edwards JM, Porter JM. Present status of reversed vein bypass grafting: five-year results of a modern series. J Vasc Surg 1990;11:193–206
5. Veith FJ, Gupta SK, Wengerter KR, et al. Changing arteriosclerotic disease patterns and management strategies in lower-limb-threatening ischemia. Ann Surg 1990;212:402–414
6. DeFrang RD, Taylor LM Jr, Porter JM. Basic data related to amputations. Ann Vasc Surg 1991;5:202–207
7. Tannenbaum GA, Pomposelli FB, Marcaccio EJ, et al. Safety of vein bypass grafting to the dorsalis pedis artery in diabetic patients with foot infections. J Vasc Surg 1992; 15:982–990
8. Schneider JR, Walsh DB, McDaniel MD, et al. Pedal bypass versus tibial bypass with autogenous vein: a comparison of outcome and hemodynamic results. J Vasc Surg 1993;17:1929–1038
9. Gloviczki P, Bower TC, Toomey BJ, et al. Microscope-aided pedal bypass is an effective and low-risk operation to salvage the ischemic foot. Am J Surg 1994;168:76–84
10. Pomposelli FB, Marcaccio EJ, Gibbons GW, et al. Dorsalis pedis arterial bypass: durable limb salvage for foot ischemia in patients with diabetes mellitus. J Vasc Surg 1995;21: 375–384

11. Leers SA, Reifsnyder T, Delmonte R, Caron M. Realistic expectations for pedal bypass grafts in patients with end-stage renal disease. J Vasc Surg 1998;28:976–983
12. Rhodes JM, Gloviczki P, Bower TC, Panneton JM, Canton LG, Toomey BJ. Failing or failed pedal bypass grafts: are secondary interventions worthwhile? Am J Surg 1999; 178:151–155
13. Rutherford RB, Baker JD, Ernst C, et al. Recommended standards for reports dealing with lower extremity ischemia: revised version. J Vasc Surg 1997;26:517–538
14. TransAtlantic Inter-Society Consensus (TASC). Management of peripheral vascular disease (PAD). J Vasc Surg 2000;31(Part 2)