

A Pill Turned into a Foreign Body in a Patient in a Hurry

M. Tuncer¹, Y. Erzin¹, A. F. Celik¹,
U. Korman², N. Mandel¹, E. Oktay¹

¹ Dept. of Internal Medicine,
Division of Gastroenterology,
Cerrahpasa Medical Faculty,
Istanbul University, Istanbul, Turkey

² Dept. of Radiology,
Division of Gastroenterology,
Cerrahpasa Medical Faculty,
Istanbul University, Istanbul, Turkey

Corresponding Author

A. F. Celik, M.D.
Dept. of Internal Medicine
Division of Gastroenterology
Cerrahpasa Medical Faculty
Irfaniye sok
Manolya apt. No. 11/3
Yeşilköy 34800
Istanbul
Turkey
Fax: + 90-212-5743186
E-mail: dryusuf@doruk.net.tr

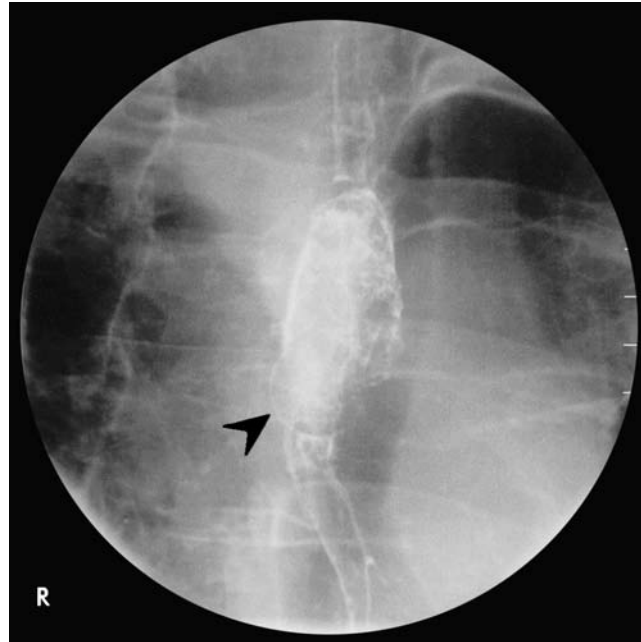


Figure 1 A 55-year-old woman was referred to our endoscopy unit with a 1-month history of continuous retrosternal pain, dysphagia, and odynophagia located in the upper half of the esophagus. She had been suffering from these symptoms after swallowing three pills at once because of a troublesome headache. As she was in a hurry, she did not notice that one of them was still in its plastic cover. On barium meal examination, the pill was seen as a sharply radiolucent, round, filling defect (indicated by black arrowhead) in the upper thoracic esophagus. It was removed by endoscopy.

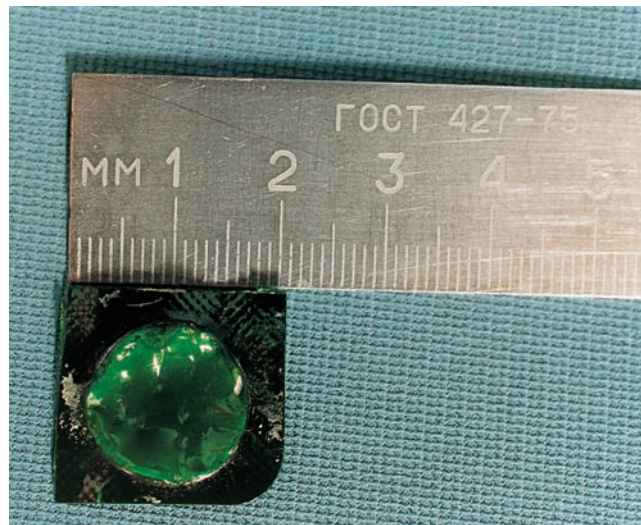


Figure 2 The size of the plastic-covered pill, 2 cm in diameter.