

Anal Leukoplakia: An Unusual Case of Anal Stenosis

Causes of secondary anal stenosis that have been reported include trauma, Crohn's disease, tuberculosis, actinomycosis, lymphogranuloma, Bowen's disease, Paget's disease, epidermoid carcinoma, and actinic causes [1]. We report here an unusual case of anal stenosis caused by extensive anal leukoplakia, which (so far as we are aware) is the first such case to be reported.

A 64-year-old woman was first admitted to our department two years ago, with a diagnosis of anal cancer. She was having difficulty in evacuation, with a decreasing stool caliber and tenesmus. She denied any history of rectal trauma, pruritus, laxative use, perianal abscess, or fistula. The clinical examination and laboratory data were normal. A digital examination revealed anal tightness and a granular, hard sensation in the anal canal. Endoscopy showed a white and firm circumferential lesion in the anal canal, extending cephalad from the anal verge to the pectinate line (Figure 1). The anal canal was stenotic, and could not be passed with the endoscope. A biopsy of the lesion revealed hyperkeratosis and acanthosis, with a mild inflammatory reaction (Figure 2). No dysplastic changes were identified.

The patient declined to undergo surgery for the anal stenosis. It was decided to follow her up with serial observations and biopsies; she returned in June 2000 for evaluation of leukoplakia. Four-quadrant biopsies showed findings similar to those of the previous histological diagnosis. Dysplasia and dyskeratosis were absent.

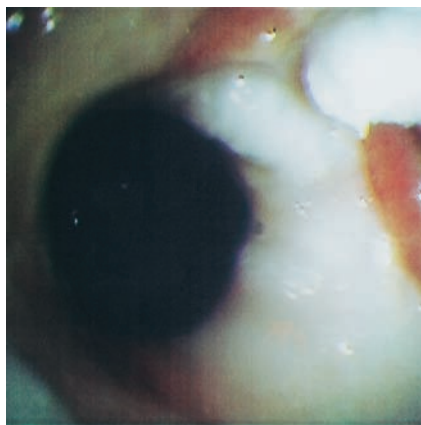


Figure 1 Endoscopic image showing thickened white epithelium extending cephalad from the anal verge to the pectinate line

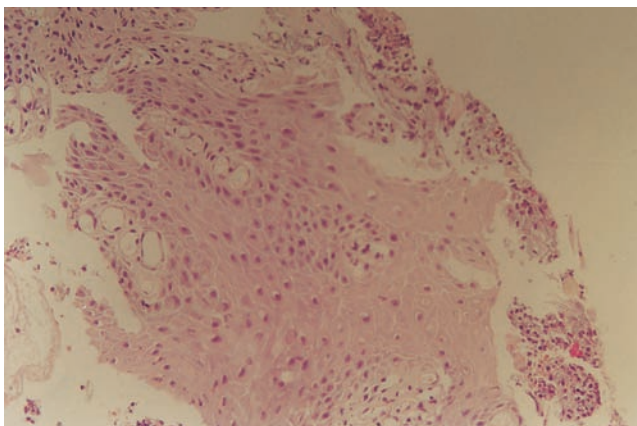


Figure 2 There is marked hyperkeratosis and hyperplastic acanthotic epithelium, accompanied by a mild inflammatory reaction (hematoxylin-eosin, original magnification $\times 200$)

Anal leukoplakia has previously been described rarely and in little detail. Rosser [2] cited three cases reported in the Scandinavian literature up to the 1930s, and in a 1960 report, Gabriel [3] had observed ten cases – but again, these were not well described. Bender and Lechago [4] described two cases of leukoplakia of the anal canal which were asymptomatic and were discovered by routine rectal examination. Morson and Dawson [5] describe leukoplakia in their textbook, but give no figures for the incidence. Other authoritative sources [6, 7] make no mention of anal leukoplakia.

There is little evidence that leukoplakia of the anal canal is a premalignant condition, but patients should be carefully followed up, as the natural course of this rare lesion is unknown. A review of the literature confirms our clinical experience that anal leukoplakia is a rare entity and a previously unreported cause of anal stenosis.

P. Katsinelos¹, K. Christodoulou¹, I. Pilpildis¹, A. Papagiannis¹, F. Patakiouta², P. Xiarchos¹, P. Amperiadis¹, N. Eugenidis¹

¹Dept. of Gastroenterology, Theagenion Institute of Cancer, Thessaloniki, Greece

²Dept. of Histopathology, Theagenion Institute of Cancer, Thessaloniki, Greece

References

- Khubchandani IT. Anal stenosis. *Surg Clin North Am* 1994; 74: 1353–1360
- Rosser C The etiology of anal cancer. *Am J Surg* 1931; 11: 328–333
- Gabriel WB. Discussion on squamous cell carcinoma of anus and anal canal. *Proc R Soc Med* 1960; 53: 403–409
- Bender MD, Lechago J Leukoplakia of the anal canal. *Dig Dis* 1976; 21: 867–872
- Morson BC, Dawson IMP. *Morson and Dawson's gastrointestinal pathology*. Oxford: Blackwell Scientific, 1990: 621–624
- Kirsner JB, Shorter RG. *Diseases of the colon, rectum, and anal canal*. Baltimore: Williams and Wilkins, 1988
- Feldman M, Sleisenger MH, Scharshmidt BF, Klein S (eds). *Sleisenger and Fordtran's gastrointestinal and liver disease*. Philadelphia: Saunders, 1998

Corresponding Author

P. Katsinelos, M.D.

Dept. of Gastroenterology
Theagenion Institute of Cancer
Marathonos 14
TT 546 38 Thessaloniki
Greece

Fax: +30-51-257070

E-mail: per_amp@yahoo.com